Article published online: 2024-04-21

Bilobed Prepontine White Epidermoid Cyst Camouflaged as Tubercular Abscess: A Case Report

Foram Gala[1] Vaishali Madhariya[2]

[1] Department of Radiology, Bai Jerbai Wadia Hospital for Children, Mumbai, Maharashtra, India
[2] Department of Radiology, Tata Memorial Hospital, Mumbai, Maharashtra, India

Address for correspondence Foram Gala, Department of Radiology, Bai Jerbai Wadia Hospital, Parel 400014, Mumbai, Maharashtra, India (e-mail: drforamgala@gmail.com).

Indian J Radiol Imaging 2024;34:770–772.

Abstract

Epidermoid cysts are ectodermally derived benign extra-axial lesions that have typical imaging characteristics following cerebrospinal fluid (CSF) signal intensity, but occasionally show unusual hyperintensity on T1-weighted images (T1WI), known as white epidermoid, thus posing a diagnostic challenge. We report an unusual case of bilobed prepontine white epidermoid masquerading as tuberculous abscess in a known case of tubercular meningitis.

Keywords
- white epidermoid cyst
- tubercular abscess

Introduction

Epidermoid cysts are benign extra-axial, slow-growing lesions derived from ectodermal elements. These are usually located in the parasellar region and cerebellopontine angle and typically exhibit T1 hypointense and T2 hyperintense signal intensities with restricted diffusion.

White epidermoid cysts have distinct radiopathological characteristics and appear hypointense on T1-weighted images (T1WIs) and hyperintense on T2WIs with no diffusion restriction.[1] We present a case of bilobed prepontine mass in a patient with known tubercular meningitis, which was a white epidermoid cyst as opposed to the usual perception of an abscess.

Case Summary

A 15-year-old adolescent girl patient, diagnosed outside with tuberculous meningitis (cerebrospinal fluid [CSF] study was done at the time of diagnosis and GeneXpert was positive for *Mycobacterium tuberculosis*), was undergoing treatment. Magnetic resonance imaging (MRI) at initial presentation (►**Figs. 1** and **2**) showed leptomeningeal enhancement along the bilateral parieto-occipital convexities, more on the right side, and along the cerebellar folia. Also, a well-defined extra-axial butterfly-shaped lobulated lesion was seen in the prepontine region with near-complete encasement of the basilar artery. It was T1 hyperintense, with two distinct components on T2WIs and diffusion weighted imaging (DWI). The right-sided component was isointense on T2 and hyperintense on DWI, whereas the left component was hypointense on T2WI and isointense on DWI. On apparent diffusion coefficient (ADC) maps, the lesion showed a drop in signal with a mean of 0.6. There was no edema in the underlying brainstem. The patient was treated for tubercular meningitis with an abscess.

Five months later, the patient presented to our hospital with complaints of persistent occipital headaches and dizziness. On examination, there were no neurologic deficits. Repeat MRI showed complete resolution of leptomeningeal enhancement; however, the prepontine mass was persistent, with an unchanged size and similar signal characteristics as before (►**Figs. 3** and **4**). Hence, this lesion was thought to be a white epidermoid cyst or a neuroenteric cyst.

The patient underwent partial excision of a right-sided lesion with histopathology findings of tissue fragments lined by stratified squamous epithelium filled with acellular keratinized material, suggestive of an epidermoid cyst (►**Fig. 5**). There was no evidence of infection or inflammation.

article published online
April 21, 2024

DOI https://doi.org/10.1055/s-0044-1780525.
ISSN 0971-3026.

© 2024. Indian Radiological Association. All rights reserved.
This is an open access article published by Thieme under the terms of the Creative Commons Attribution-NonDerivative-NonCommercial-License, permitting copying and reproduction so long as the original work is given appropriate credit. Contents may not be used for commercial purposes, or adapted, remixed, transformed or built upon. (https://creativecommons.org/licenses/by-nc-nd/4.0/)
Thieme Medical and Scientific Publishers Pvt. Ltd., A-12, 2nd Floor, Sector 2, Noida-201301 UP, India

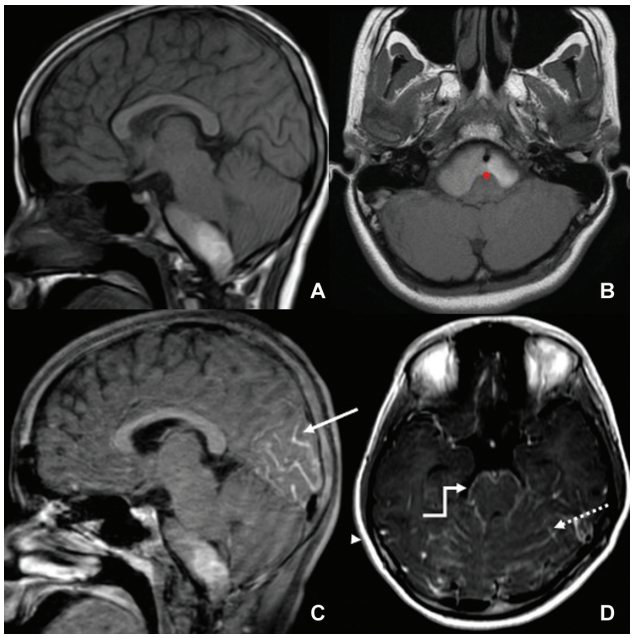

Fig. 1 Initial scan: axial T1 (**A**,**B**) precontrast and (**C**,**D**) postcontrast magnetic resonance imaging (MRI) of the brain shows leptomeningeal enhancement along the sulci (*arrow*), around the brainstem (*elbow arrow*) and cerebellar folia (*dotted arrows*). Precontrast sequences show absence of T1 hyperintensity, which rules out dermoid rupture.

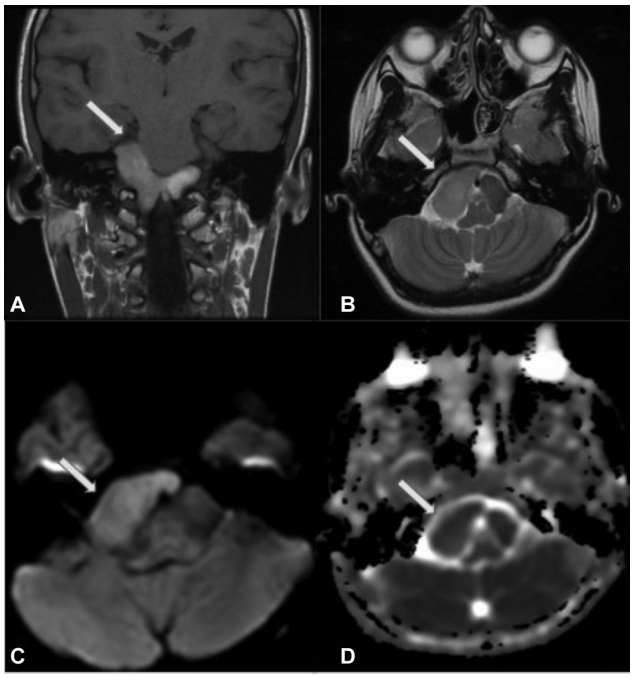

Fig. 4 Follow-up scan after 6 months. Magnetic resonance imaging (MRI) of the brain with coronal (**A**) T1, (**B**) axial T2, (**C**) diffusion weighted imaging (DWI), and (**D**) apparent diffusion coefficient (ADC) map images shows persistent prepontine mass (*arrow*), unchanged in size and signal characteristics as before.

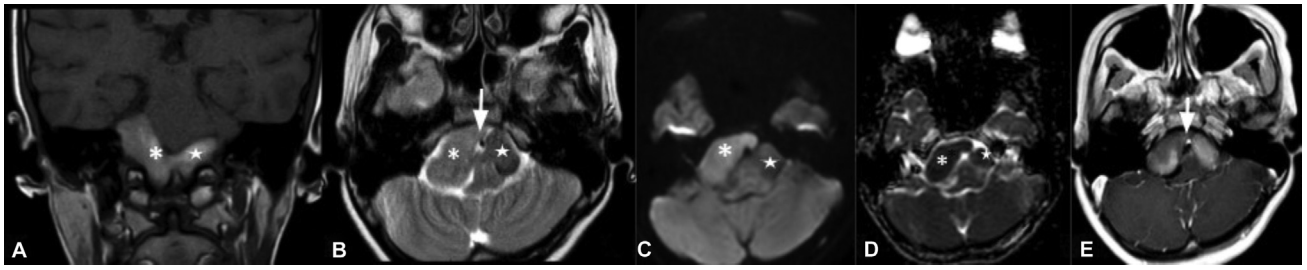

Fig. 2 Initial scan: magnetic resonance imaging (MRI) of the brain with (**A**) coronal T1, (**B**) axial T2, (**C**) diffusion weighted imaging (DWI), (**D**) apparent diffusion coefficient (ADC) map, and (**E**) axial T1 postcontrast images demonstrates a well-defined butterfly-shaped lobulated extra-axial lesion in the prepontine cistern with hyperintense signal intensity on T1 and two different signal intensity in right-sided (*asterisk*) and left-sided component (*star*) on axial T2-weighted (T2W) and DWI images. There is near complete encasement of the basilar artery by the lesion (*arrow*).

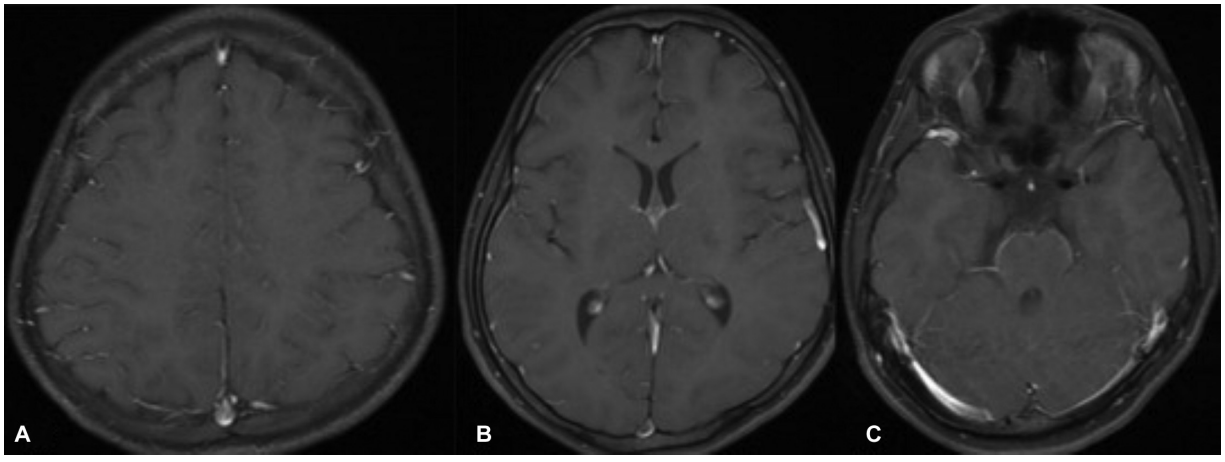

Fig. 3 Follow-up scan after 6 months of antituberculosis treatment. (**A–C**) Magnetic resonance imaging (MRI) of the brain with axial T1 postcontrast images shows complete resolution of previously seen leptomeningeal enhancement along the sulci and cerebellar folia.

 © 2024. Indian Radiological Association. All rights reserved.

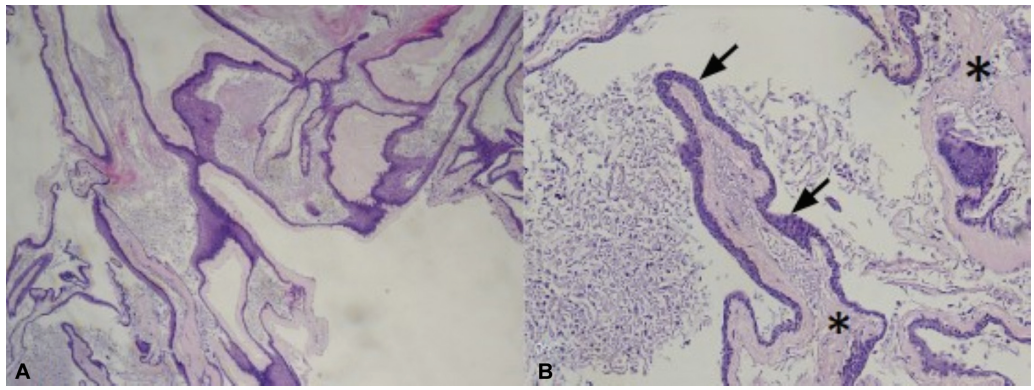

Fig. 5 Microscopic images with a resolution of (**A**) 2.5x and (**B**) 10x show fibroconnective wall tissue fragment lined by the squamous epithelium (*arrow*) and filled with acellular keratinized material (*asterisks*), suggestive of benign epidermoid cyst.

Discussion

As opposed to typical epidermoid cysts, which are well-delineated "pearly tumours"[2] and follow CSF signal intensity, appearing hypointense on T1WI and hyperintense on T2WI with diffusion restriction and drop on the ADC map, white epidermoid cysts, being atypical variants, are defined as those with spontaneous hyperintensity on T1WI. They constitute up to 3% of all epidermoid cysts, are hyperintense on T1WI and hypointense on T2WI, and show no diffusion restriction. This MRI appearance is due to higher concentration of protein and triglycerides,[3] which causes high viscosity, resulting in a loss of signal intensity on T2WI, also known as the "shading sign."[4]

In our case, the patient had tubercular meningitis with a large prepontine mass that was not responding to treatment. It was a well-defined bilobed lesion with two components with different signal characteristics, as described in ►**Table 1**.

Another atypical finding in our case was the presence of diffusion restriction in the right half of the lesion, although white epidermoid does not have diffusion restriction.

The main differentials were white epidermoid cyst and neuroenteric cyst, and a less likely abscess. A remote possibility of coexistent white and classic epidermoid in each locule was also considered. Tubercular abscess shows hypointensity on T1WI, hyperintensity on T2WI, and rim enhancement with surrounding inflammation due to edema and adhesions.[5] In our case, points against abscess were the presence of homogenous T1 hyperintensity and lack of rim enhancement and inflammation. Neuroenteric cysts with squamous metaplasia are also T1 hyperintense; however, they show T2 hyperintensity and diffusion restriction.[6]

Table 1 Imaging characteristics of two different components of bilobed prepontine mass

Images	Imaging characteristic of right-sided component	Imaging characteristic of left-sided component
T1-weighted images	Hyperintense	Hyperintense
T2-weighted images	Isointense	Hypointense
Fluid attenuated inversion recovery	Heterogenous	Hyperintense
Diffusion-weighted imaging	Hyperintense	Hypointense
Apparent diffusion coefficient	Hypointense	Hypointense

Conclusion

On imaging, a bilobed prepontine mass with a homogenously T1 hyperintense signal, T2 shading sign with variable diffusion restriction, and a white epidermoid cyst should be considered as the first differential diagnosis.

Funding
None.

Conflict of Interest
None declared.

References

1 Matsumoto H, Shinya Y, Miyawaki S, et al. White epidermoid cyst transformation after stereotactic radiosurgery: illustrative case. J Neurosurg Case Lessons 2023;5(24):CASE2376
2 Gao PY, Osborn AG, Smirniotopoulos JG, Harris CP. Radiologic-pathologic correlation. Epidermoid tumor of the cerebellopontine angle. Am J Neuroradiol 1992;13(03):863–872
3 Diyora B, Nayak N, Kale D, Kamble H, Sharma A. Frontal intraparenchymal "White epidermoid cyst": a rare occurrence. J Neurosci Rural Pract 2010;1(02):125–127
4 Puranik A, Sankhe S, Goel N, Mahore A. Cerebral shading sign in a giant intraparenchymal white epidermoid. Neurol India 2012;60(02):265–266
5 Luthra G, Parihar A, Nath K, et al. Comparative evaluation of fungal, tubercular, and pyogenic brain abscesses with conventional and diffusion MR imaging and proton MR spectroscopy. Am J Neuroradiol 2007;28(07):1332–1338
6 Medhi G, Saini J, Pandey P, Mahadevan A, Prasad C. T1 hyperintense prepontine mass with restricted diffusion: a white epidermoid or a neuroenteric cyst? J Neuroimaging 2015;25(05):841–843

 © 2024. Indian Radiological Association. All rights reserved.