



# Malignant Infantile Osteopetrosis Masquerading as Isolated Fetal Femoral Fracture: First Indian Case Report and Review of Literature

Balusamy Sathyalakshmi<sup>1</sup> Vanathi Thangavelu Jothi<sup>2</sup>

<sup>1</sup> Department of Radiodiagnosis, Erode Fetal Medicine Centre, Erode, Tamil Nadu, India

<sup>2</sup> Department of Radiodiagnosis, Government Medical College, The Nilgiris, Tamil Nadu, India

**Address for correspondence** Vanathi Thangavelu Jothi, MBBS, MD, Government Medical College, The Nilgiris, Ooty 643005, Tamil Nadu, India (e-mail: vanathithangavelu@gmail.com).

J Fetal Med

## Abstract

### Keywords

- ▶ isolated fetal femoral fracture
- ▶ malignant infantile osteopetrosis
- ▶ osteopetrosis
- ▶ prenatal genetic testing
- ▶ skeletal dysplasias

Malignant infantile osteopetrosis is a rare case of isolated fetal femoral fracture, a scarcely documented phenomenon in medical literature. Through detailed examination and genetic testing, it unveils malignant infantile osteopetrosis as an unexpected etiology, challenging existing diagnostic paradigms. This groundbreaking case emphasizes the critical role of genetic testing in unraveling complex fetal anomalies and underscores the necessity for comprehensive approaches in prenatal diagnostics, offering new insights into prenatal manifestations of skeletal dysplasias.

## Introduction

Isolated fetal femoral fracture is a rare event during fetal life. To the best of our knowledge, only seven cases have been reported in literature.<sup>1</sup> Maternal trauma, skeletal dysplasias, and metabolic disorders are the possible etiologies. We report the first case of malignant infantile osteopetrosis as an etiology for isolated femoral fracture in the fetus unveiled by genetic testing.

## Case Report

A 27-year-old primigravida was referred for a mid-trimester fetal anomaly scan at 21 weeks of gestation. The nuchal translucency scan at 12 weeks was normal. Aneuploidy screening for Down syndrome was negative. She had no remarkable

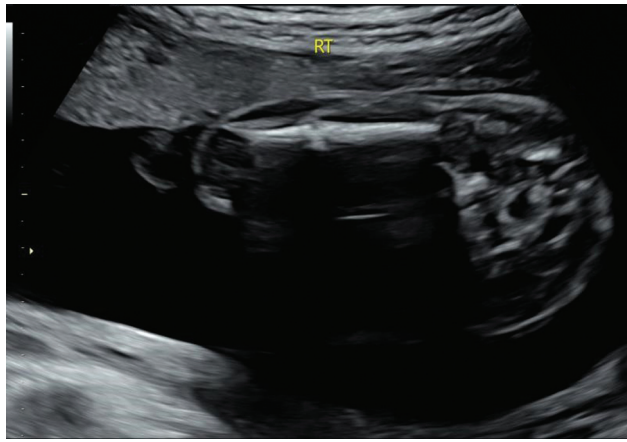
medical or surgical history. She is in a third-degree consanguineous marriage and there was no significant family history.

An ultrasound revealed a single viable fetus with fetal growth appropriate for gestational age. Detailed fetal anatomical evaluation done as per the current International Society of Ultrasound in Obstetrics & Gynecology (ISUOG) guidelines was normal except for a discontinuity in the mid-shaft of the right femur with callus formation suggestive of fracture; there was no bowing and the left femur was normal (→ **Fig. 1**). Detailed skeletal evaluation showed that all other long bones appeared normal in length, contour, and echogenicity. The cranium, spine, and ribs were normal. Femur to foot length and thoracic to abdominal circumference ratios were within normal limits.

The family was extensively counseled regarding the possible etiologies and a pediatric orthopaedic consultation was

DOI <https://doi.org/10.1055/s-0044-1780491>.  
ISSN 2348-1153.

© 2024. Society of Fetal Medicine. All rights reserved.  
This is an open access article published by Thieme under the terms of the Creative Commons Attribution-NonDerivative-NonCommercial-License, permitting copying and reproduction so long as the original work is given appropriate credit. Contents may not be used for commercial purposes, or adapted, remixed, transformed or built upon. (<https://creativecommons.org/licenses/by-nc-nd/4.0/>)  
Thieme Medical and Scientific Publishers Pvt. Ltd., A-12, 2nd Floor, Sector 2, Noida-201301 UP, India



**Fig. 1** Ultrasound image showing discontinuity in mid-shaft of right femur with surrounding callus formation.

suggested. The family opted for genetic testing and amniocentesis was performed; the sample was sent for whole exome sequencing that revealed a homozygous missense variation in exon 19 of the *CLCN7* gene, suggesting a likely pathogenic variant associated with osteopetrosis. Post-test counseling was done and the couple chose to terminate the pregnancy but declined fetal autopsy. Parental carrier screening was done and both the parents were found to be carriers of the mutation in the exon 19 of the *CLCN7* gene.

## Discussion

Long bone evaluation is a vital part of the routine mid-trimester fetal anomaly scan. For accurate imaging, the beam needs to be perpendicular to the bone axis<sup>2</sup> and measurement should only include the diaphysis. Assessment should include presence, length, contour, and echogenicity of all three segments of both upper and lower limbs. Limb abnormalities include absence, shortening, altered shape, fracture, and increased or decreased echogenicity of bones.

Antenatal long bone fractures are uncommon with the femur being the most commonly involved. Maternal trauma, skeletal dysplasias like osteogenesis imperfecta (OI), and campomelic dysplasia and metabolic disorders such as hypophosphatasia are the differential diagnoses. OI is the most

common skeletal dysplasia associated with intrauterine long bone fracture that usually presents with bowing and shortening of bones, decreased thoracic circumference, multiple intrauterine fractures, and decreased mineralization of the cranium and spine.

In literature, five out of seven fetal femoral fractures have been labeled as spontaneous after ruling out other etiologies based on history and postnatal follow-up in some cases (► **Table 1**). Genetic testing was done by Raabe et al and Tetla et al which had normal results.<sup>1,3</sup>

This case is the eighth case of isolated fetal femoral fracture reported in literature and the first case of osteopetrosis presenting as an isolated fetal femoral fracture.

Osteopetrosis is a rare sclerosing skeletal dysplasia characterized by failure of osteoclasts that are responsible for bone resorption.<sup>4</sup> This results in osteosclerosis with bony fragility, marrow failure resulting in pathological fractures, pancytopenia, hepatosplenomegaly, and cranial neuropathies.

At least 10 genetic mutations have been associated with osteopetrosis that can be inherited through autosomal dominant, recessive, or X-linked traits. The autosomal recessive form is the most severe but least common (1:250000) and the dominant form is the least severe but most common (1:20000).<sup>5</sup>

Autosomal recessive osteopetrosis (ARO), also known as malignant infantile form of osteopetrosis, is caused by loss of function mutations in *TCIRG1*, *CLCN7*, *OSTM1*, *PLEKHM1*, and *SNX10* genes resulting in an osteoclast rich version, presenting within the first 2 years of life.<sup>5</sup> *TCIRG1* is the most commonly affected gene in ARO. In our case, *CLCN7* gene coding for chloride channel 7 was affected, thereby resulting in defective acidification of the ruffled border of osteoclasts. *CLCN7* mutations have been identified in both autosomal recessive and dominant forms, displaying varying degrees of severity, ranging from lethal to asymptomatic and can show evidence of neurodegeneration in recessive form.<sup>6</sup>

To date, around eight cases of osteopetrosis have been antenatally diagnosed; all of them had at least one postnatally diagnosed index case (affected sibling/family member). Antenatally reported findings include communicating hydrocephalus, ventriculomegaly, and hyperechogenicity of bones and calvaria. Postnatal identification of a genetic locus in a cohort of multiple osteopetrosis cases in four

**Table 1** Review of cases of isolated fetal femoral fracture

Author	Gestational age at detection	Management and outcome
Senanayake et al 2003 <sup>9</sup>	26 wk	Genetic testing not done, follow-up upto 6 years—surgical correction of limb length discrepancy (3 cm)
Arioz et al 2008 <sup>10</sup>	34 wk	Genetic testing not done, follow-up—not reported
Hwang et al 2009 <sup>11</sup>	23 wk	Genetic testing not done, follow-up—normal upto 9 months
Raabe et al 2013 <sup>3</sup>	20 wk, 5 d	Normal karyotype, mutation in <i>COL1A1</i> and <i>COL1A2</i> excluded, follow-up—normal
Sahin et al 2014 <sup>12</sup>	25 wk	Genetic testing not done, follow-up—not reported
Yu et al 2018 <sup>13</sup>	19 wk	Genetic testing not done, follow-up—not reported
Tetla et al 2021 <sup>1</sup>	21 wk	CGH array—normal, follow-up—normal (several months—duration not mentioned)

**Table 2** Review of literature of antenatally diagnosed osteopetrosis case reports

Author	Gestational age at diagnosis	Family history	Antenatal history	Genetic testing	Outcome
el Khazen et al 1986 <sup>14</sup>	18–24 wk	1 affected sibling	Hydrocephaly and skeletal hyper-density at 18 weeks of gestation and fetal fractures at 24 weeks	Not done	Termination of pregnancy
Sen et al 1995 <sup>15</sup>	18–22 wk	2 affected siblings	Communicating hydrocephalus, increased bone echogenicity Cordocentesis showing decreased calcium, increased phosphorus levels	Not done	Termination of pregnancy
Oğur et al 1995 <sup>16</sup>	25 wk	1 affected sibling. 3 <sup>rd</sup> degree consanguineous marriage	Fetal X-ray showed osteosclerosis, metaphyseal splaying and clubbing of femurs	Not done	Termination of pregnancy
Kapelushnik et al 2001 <sup>7</sup>	10–16 wk	Multiple affected children in 4 interrelated families. Affected gene localized to chromosome 11q12–13	Prenatal genetic testing like chorionic villus sampling/amniocentesis in 7 pregnant women	Yes	5 normal; 1 terminated and 1 treated with postnatal bone marrow transplantation
Malinger 2002 <sup>17</sup>	18 wk	Two affected siblings	Increased bone echogenicity	Not done	Termination of pregnancy
Mistri et al 2014 <sup>8</sup>	11 wk	One affected sibling. Homozygous for a nonsense mutation in TCIRG1 gene	Chorionic villus sampling for TCIRG1 gene	Yes—heterozygous carrier state	Normal

interrelated families led to the performance of genetic testing by Kapelushnik et al in seven pregnancies as early as 2001; two fetuses were found to be affected.<sup>7</sup> Mistri et al diagnosed a heterozygous carrier state in the antenatal period due to a known homozygous nonsense mutation of TCIRG1 gene affected sibling.<sup>8</sup>

In contrast, our case had neither a preceding index case nor a family history suggestive of skeletal dysplasias nor any reported ultrasound features of osteopetrosis (► **Table 2**). It also highlights the importance of genetic testing before labeling fetal femoral fractures as idiopathic.

## Conclusion

Skeletal dysplasias are the most common cause of fetal fractures. This case shows the importance of genetic testing in cases of isolated fetal fractures. Genetic counseling should be offered to all such cases that will help in accurate diagnosis and aid in risk prediction for subsequent pregnancies. Malignant infantile osteopetrosis is a rare autosomal recessive disorder that can present prenatally as an isolated fetal femoral fracture.

### Ethical Approval

This case report adheres strictly to the principles outlined in the Declaration of Helsinki. All identifiable and confidential patient information has been anonymized and obscured to maintain privacy. The participant has been duly informed about the nature and purpose of this report, and informed consent has been obtained.

### Authors' Contributions

Balusamy Sathyalakshmi conceived and developed the theory and supervised this work. Balusamy Sathyalakshmi and Vanathi Thangavelu Jothi wrote the manuscript. Both authors discussed and contributed to the final manuscript.

### Conflicts of Interest

None declared.

## References

- 1 Tetla R, Wiesman D, Brown M, Abu-Rustum RS, Egerman R. VP10.03: Atraumatic isolated fetal femur fracture: an unusual

- sonographic finding, diagnostic considerations and literature review. *Ultrasound Obstet Gynecol* 2021;58(S1):131
- 2 Salomon LJ, Alfirevic Z, Berghella V, et al. ISUOG Practice Guidelines (updated): performance of the routine mid-trimester fetal ultrasound scan. *Ultrasound Obstet Gynecol* 2022;59(06):840–856
- 3 Raabe E, Dammer U, Kehl S, Beckmann MW, Faschingbauer F. Spontaneous fetal femur fracture. *Ultraschall Med* 2013;34(01):1–4
- 4 Peer M, O'Donoghue K. Osteopetrosis in pregnancy: a rare case report. *Obstet Med* 2012;5(01):27–29
- 5 Bailey JR, Tapscott DC. Osteopetrosis. [Updated 2023 Apr 24]. In: StatPearls [Internet]. Treasure Island (FL): StatPearls Publishing; 2023. Accessed January 23, 2023 at: <https://www.ncbi.nlm.nih.gov/books/NBK557529/>
- 6 Di Zanni E, Palagano E, Lagostena L, et al. Pathobiologic mechanisms of neurodegeneration in osteopetrosis derived from structural and functional analysis of 14 CIC-7 mutants. *J Bone Miner Res* 2021;36(03):531–545
- 7 Kapelushnik J, Shalev C, Yaniv I, et al. Osteopetrosis: a single centre experience of stem cell transplantation and prenatal diagnosis. *Bone Marrow Transplant* 2001;27(02):129–132
- 8 Mistri M, Patel H, Tanna T, Ankleshwaria C, Sheth F, Sheth J. Prenatal diagnosis of autosomal recessive osteopetrosis: a case report. *Mol Cytogenet* 2014;7(Suppl 1):1–125
- 9 Senanayake H, Anandakumar C, de Silva MVC. Mid-trimester fracture of femur in a normal fetus. *J Obstet Gynaecol Res* 2003;29(03):186–188
- 10 Arioz DT, Koken GN, Koken R, Kose KC, Cevrioglu AS. Isolated intrauterine femoral fracture in an otherwise normal fetus. *J Obstet Gynaecol Res* 2008;34(01):92–94
- 11 Hwang JY, Lee JY, Lee DH. Diagnosis of fetal femoral fracture by midtrimester three-dimensional ultrasound. *Int J Gynaecol Obstet* 2009;104(01):69–70
- 12 Sahin S, Sari FN, Dilmen U. In utero healing femur fracture in an otherwise healthy fetus. *J Obstet Gynaecol Res* 2014;40(04):1161–1162
- 13 Yu M, Xu D, Zhang A, Shen J. Spontaneous fetal femoral fracture: a case report and literature review. *J Int Med Res* 2018;46(03):1282–1287
- 14 El Khazen N, Faverly D, Vamos E, et al. Lethal osteopetrosis with multiple fractures in utero. *Am J Med Genet* 1986;23(03):811–819
- 15 Sen C, Madazli R, Aksoy F, Ocak V. Antenatal diagnosis of lethal osteopetrosis. *Ultrasound Obstet Gynecol* 1995;5(04):278–280
- 16 Oğur G, Oğur E, Celasun B, et al. Prenatal diagnosis of autosomal recessive osteopetrosis, infantile type, by X-ray evaluation. *Prenat Diagn* 1995;15(05):477–481
- 17 Malinger G, Ornoy A, El Shawwa R, et al. Osteopetrosis 2002. Accessed March 3, 2024 at: <https://thefetus.net/content/osteopetrosis-1>