Article published online: 2024-02-08

Management of Spontaneous Spinal CSF Leaks Using Noninvasive Dynamic MR Neurography: A Case Series

Prabhat Suman[1] Rahul Lath[1] Alok Ranjan[1] Shekhar Reddy Gurrala[2] Kaushal Ipilli[1] Ravikanti Satya Prasad[3] Tarang K. Vora[1]

[1] Department of Neurosurgery, Apollo Hospital, Jubilee Hills, Hyderabad, Telangana, India
[2] Department of Neuroanesthesia, Apollo Hospital, Jubilee Hills, Hyderabad, Telangana, India
[3] Department of Radiodiagnosis, Apollo Hospital, Jubilee Hills, Hyderabad, Telangana, India

Address for correspondence Tarang K. Vora, DNB Neurosurgery, Consultant Pediatric Neurosurgeon, Department of Neurosurgery, Apollo Hospital, Jubilee Hills, Hyderabad, 500096, Telangana, India (e-mail: dr.tarangvora@gmail.com).

Indian J Neurosurg

Abstract

Spontaneous spinal cerebrospinal fluid (CSF) leak presents with orthostatic headache and may lead to formation of subdural collection. Invasive magnetic resonance imaging or computed tomography myelography is routinely used to detect these leaks. Noninvasive dynamic magnetic resonance neurography can also detect these leaks and confirm its resolution post treatment. It includes three-dimensional NerveView, a high-resolution short-tau inversion recovery sequence for better visualization of spinal nerves and leak sites. This article showcases the diagnostic and therapeutic journey of three patients with spontaneous spinal CSF leak all of whom were diagnosed with dynamic magnetic resonance neurography and treated successfully with autologous targeted epidural blood patch. In one case, epidural blood patch was repeated after 2 months for recurrence of the leak.

Keywords
- spontaneous spinal CSF leaks
- subdural hematoma
- dynamic MR Neurogram
- epidural blood patch
- spontaneous intracranial hypotension
- meningeal diverticula
- CSF-venous fistula
- orthostatic headache

Introduction

Spinal anesthesia's inception by August Karl Gustav Bier in 1898 marked the first encounter with low pressure cerebrospinal fluid (CSF) headaches. Subsequently, spontaneous intracranial hypotension (SIH) emerged as an underdiagnosed condition attributed to dural CSF leaks. SIH triggers orthostatic headaches due to diminished CSF volume or pressure, often resulting from iatrogenic events or trauma. In 1959, Dr. William Bell classified SIH into (1) spontaneous or primary, (2) postoperative, (3) head trauma, (4) post lumbar puncture or nerve sleeve tear, (5) secondary to other medical conditions like dehydration or decreased cerebral blood flow.[1] SIH prevalence and incidence were estimated to be around 1:50,000 people per year in a community-based study in United States. Higher numbers were noted in large-scale comprehensive hospitals as compared to local health centers probably due to lack of infrastructure for detecting such leaks.[2] SIH in Indian medical literature seems to be under reported in comparison to Western medical literature. It affects individuals aged between 30 and 50, with a female predominance.[3] Invasive computed tomography (CT)

DOI https://doi.org/10.1055/s-0044-1779629.
ISSN 2277-954X.

myelography or magnetic resonance (MR) myelography with tilt table is the standard technique utilized to detect spontaneous spinal CSF leaks. But it has many complications like seizure, contrast induced reactions, subarachnoid hematomas, and is cumbersome to do.[4] Noninvasive, noncontrast dynamic MR neurography was utilized by us to detect those spinal dural CSF leaks. This is the first case series reporting the use of dynamic MR neurography to the best of our knowledge.

Case Reports

Case 1

A 46-year-old male, previously healthy, presented with a persistent severe headache for 6 days. The headache was gradual in onset, diffuse, and aching. Physical examination showed normal consciousness and orientation (Glasgow Coma Scale score: 15). A CT brain revealed bilateral subdural hematomas (SDHs) with 19 mm (left) and 9 mm (right) in maximum thickness, causing a 7 mm midline shift to the right. Routine lab tests, including coagulation profile, were normal. Burr hole evacuation of the subacute SDH was performed on left frontal and parietal areas and right parietal area. Postoperatively, he was kept at strict bed rest for 48 hours. A postoperative CT brain showed pneumocranium beneath the frontal burr holes, managed with high-flow oxygen therapy. Subdural drains were removed, and he was discharged in good health. However, after 2 weeks, he returned with worsening headache that exacerbated in upright position but improved with recumbency. CT brain revealed bilateral subdural collections, prompting a redo-aspiration from previous burr holes. Due to recurrent subdural collections and orthostatic headache, SIH was suspected. MRI brain plain was done that showed venous distension sign (convex inferior margin of the transverse sinus at mid-transverse sinus level). Bern score is 7 and quantitative MRI signs showed mamillopontine distance of 4.80 mm, pontomesencephalic angle of 45 degrees, interpeduncular angle of 39.47 degrees, lateral ventricular angle of 125.34 degree, all of which were suggestive of intracranial hypotension (►**Table 1**; ►**Fig. 1**). MRI spine neurography detected CSF leaks along the left C7 and C8 root at the C6-7 and C7-T1 levels (►**Fig. 2**). CSF flow was identified along the left paraspinal region, with the rest of the spine showing no additional leaks. Epidural targeted blood patch injection was selected as the management strategy. Using fluoroscopic guidance, an 18 G Tuohy's needle was inserted at the C7-T1 interlaminar space. Autologous venous blood (10 mL) was administered into the epidural space, and the patient was monitored for adverse effects. The headache subsided by the second day post-cervical epidural blood patch (EBP) (►**Fig. 3**). After 72 hours, a dynamic CT myelogram with intrathecal iodinated contrast was done, which showed complete resolution of the leak. Unfortunately, the patient returned to the emergency department after 2 months with recurrent headache. CT brain demonstrated bilateral subdural collections. Repeated MR cervical spine with neurogram showed CSF signal along left C6, C7 nerve root. Patient was further positioned in left lateral position and MRI taken (dynamic MR neurogram), which showed exacerbation of CSF leak at the left C6-7and C7-T1 levels (►**Fig. 4**). A decision was made for a repeat EBP, with 10 mL of autologous blood, which was administered under fluoroscopic guidance. On subsequent follow-up, there was no new episodes of orthostatic headache or SDH. A 3-month follow-up MR neurogram confirmed the absence of CSF leaks at the left C6-7 and C7-T1 levels (►**Fig. 5**). At 1-year follow-up, patient remains asymptomatic.

Case 2

A 68-year-old female with a history of rheumatoid arthritis (RA) presented with headache for 3 days. The headache was gradual in onset, mild to moderate in intensity, dull and diffuse, aggravated by standing, bending forward, and

Table 1 Radiological signs of SIH—MRI brain

Serial no.	MRI findings	Case 1(►**Fig. 1**)	Case 2	Case 3
1.	Engorgement of venous sinus	+(2)	−(0)	+(2)
2.	Pachymeningeal enhancement	NA (0)	NA (0)	NA (0)
3.	Suprasellar cistern ≤ 4mm	3.32 mm (2)	2.14 mm (2)	4.97 mm (0)
4.	Subdural fluid collection	+(1)	+(1)	−(0)
5.	Prepontine cistern ≤ 5mm	3.65 mm (1)	4.56 mm (1)	4.85 mm (1)
6.	Mamillopontine distance ≤ 6.5mm	4.8 mm (1)	4.73 mm (1)	7.64 mm (0)
7.	Ponto mesencephalic angle	45 degrees	32.4 degrees	47.8 degrees
8.	Interpeduncular angle	39.4 degrees	37.6 degrees	49.4 degrees
9.	Lateral ventricular angle	125 degrees	135 degrees	139 degrees
10.	Bern score	7	5	3
11.	Risk of spinal CSF leak	High	High	Intermediate

Abbreviations: CSF, cerebrospinal fluid; MRI, magnetic resonance imaging; SIH, spontaneous intracranial hypotension.
Bern score[5]: 1,2,3 are major criteria—*2* points for each and 4,5,6 are minor criteria—1 point for each; ≤2 points—low risk, 3–4 points—intermediate risk, ≥5 points—high risk of spinal CSF leak.
As contrast scan was not done, point for pachymeningeal enhancement is taken as *0* by the authors.

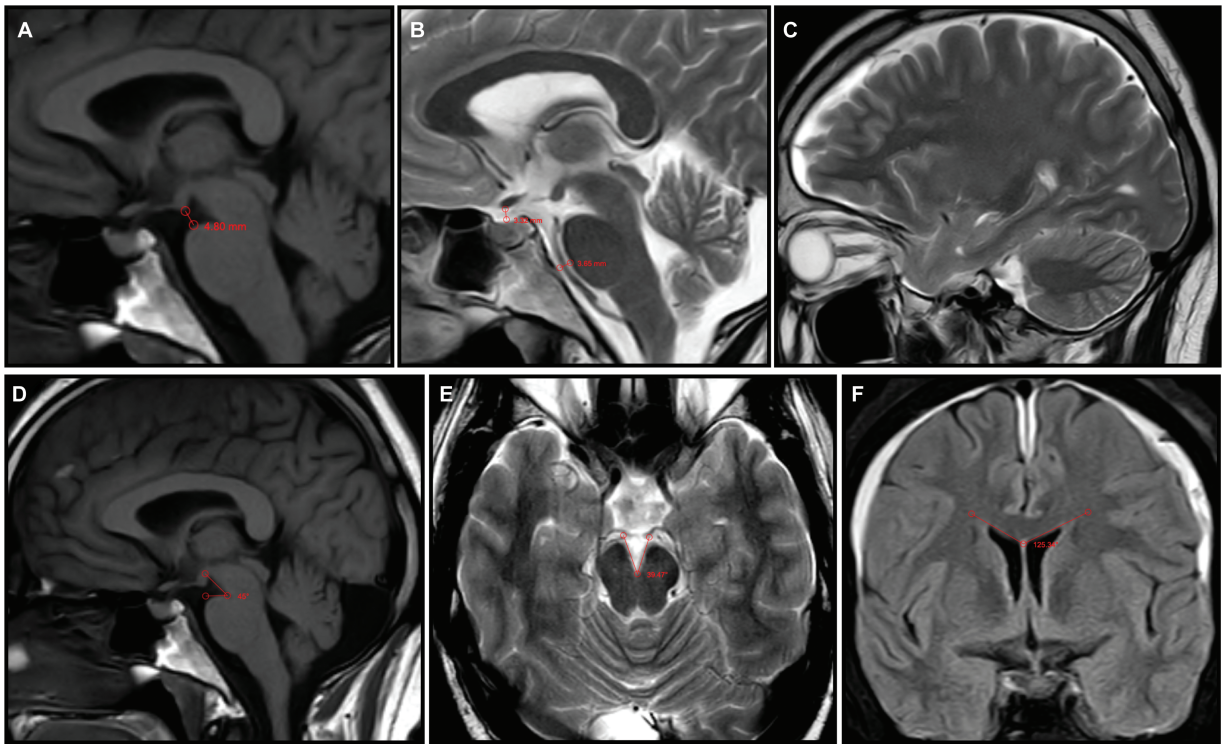

Fig. 1 Magnetic resonance imaging brain findings and various quantitative signs in case 1. (**A**) Mamillopontine distance—defined as distance between inferior aspect of mamillary bodies to the superior aspect of the pons in sagittal plane. Mean value in patients with intracranial hypotension was 4.4 mm (standard deviation [SD], ± 1.8).[6](**B**) Suprasellar cistern less than or equal to 4mm and prepontine cistern less than or equal to 5mm are more consistent with spontaneous intracranial hypotension.[5](**C**) Venous distension sign—convex inferior margin of the midportion of the dominant transverse sinus on a sagittal image. It has a diagnostic sensitivity and specificity of 94% for intracranial hypotension.[7](**D**). Pontomesencephalic angle—defined as angle between line drawn along anterior margin of midbrain and anterosuperior margin of pons. Mean value in patients with intracranial hypotension was 41.2° (SD, ± 17.4 degrees).[6](**E**) Interpeduncular angle—defined as the angle formed by the posterior half of the cerebral peduncles obtained on an axial T2-weighted image at the level of the mammillary bodies or the slice immediately below it, whichever yields a lesser value. Value less than 40.5 degrees has yielded a sensitivity of 80.0% and a specificity of 96.7% in adults.[8](**F**) Lateral ventricular angle—defined as angle between medial margins of right and left lateral ventricles (lines). This angle was measured on coronal imaging at level of fornix, third ventricle, and pituitary infundibulum. Mean value in patients with intracranial hypotension was 130.1 degrees (SD, ± 9.8 degrees).[6]

relieved by lying down. Physical examination revealed no motor or sensory deficits. A CT brain revealed a chronic subdural collection on the left hemisphere (►**Fig. 6A**). Suspecting SIH due to orthostatic headache without other evident causes, an MR neurogram was performed, indicating a CSF fistula at the T4-5 level on the left side (►**Fig. 6B**), with CSF movement along the medial pleural border (►**Fig. 6C**). The patient underwent evacuation of the SDH through left frontal and parietal burr holes, followed by a dorsal T4-5 targeted EBP using 15 mL of autologous blood. She observed strict bed rest for 48 hours and experienced gradual headache improvement. A follow-up MRI brain on postoperative day 2 showed minimal residual subdural collection with pneumocephalus. After ambulation, she was discharged in stable condition. At 1-year follow-up patient is asymptomatic and CT brain scans showed no recurrence of SDH.

Case 3

A 30-year-old male with recent history of liposuction for obesity (under general anesthesia—1 week prior) presented with sudden onset diffuse headache that was worsening upon sitting and standing for more than 5 to 10 minutes, and was partially relieving on lying down. It was also associated with feeling of nausea and back of neck pain. On examination patient was conscious and well oriented, with no gross neurological deficit. MRI brain plain showed distended convex appearance of inferior margin of midportion of dominant transverse sinus, that is, venous distension sign present, with Bern score of 3 suggesting intermediate risk for spinal CSF leak. MR neurogram was done suspecting spontaneous dural CSF leak as other causes of orthostatic headache were ruled out. It showed CSF leak at T1/T2 level bilaterally, which was managed successfully with targeted EBP at T1/2 level (►**Fig. 7**). At 1-year follow-up patient is asymptomatic.

Discussion

Pathophysiology

Schievink et al[9] described that meningeal diverticula (42%) were the most common cause of SIH, followed by ventral dural tears (27%), and CSF-venous fistula (CVF; 3%); the rest 28% were of indeterminate cause. Meningeal diverticula

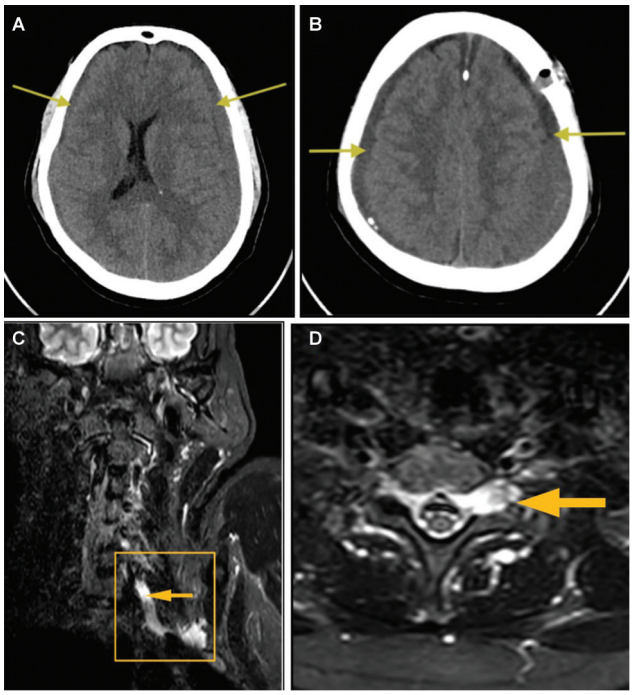

Fig. 2 (A) and (B) Axial noncontrast computed tomography scan with bilateral subdural hematoma, (C) coronal image, (D) axial image—dynamic magnetic resonance neurogram (highly T2-weighted image) with cerebrospinal fluid leak site (yellow arrow).

involve weakened areas in the dura where leptomeninges herniate, forming fragile outpouchings that has tendency to rupture, most commonly in thoracic or upper lumbar spine, either along a nerve root sleeve or at the axilla of nerve root. Ventral dural tears are caused by protruded calcified disc or sharp endplate osteophytes, producing longitudinally oriented tears, more commonly in thoracic or lower cervical spine. CVF involves a direct connection between spinal subarachnoid space and paraspinal veins (segmental spinal vein, intercostal or muscular branch or internal vertebral epidural venous plexus) allowing rapid loss of CSF into the venous circulation.[9] Schievink et al[10] classified it into four types: Type 1 leaks are due to dural tears (1a—ventral, 1b—dorsolateral), Type 2 due to meningeal diverticulum (2a—simple, 2b—complex), Type 3 is CVF, and Type 4 for patients with indeterminate spinal imaging. While the exact causes of spontaneous spinal CSF leaks are not always clear, there is evidence to suggest a significant association between these leaks and connective tissue disorders, common cases being Ehlers-Danlos syndrome, Marfan syndrome, Loeys-Dietz syndrome. It is thought that connective tissue in the dura mater may be weaker and more susceptible to small tear or defects in such conditions. ►**Table 2** is summarizing all the three cases, based on age, site, and type of leak.

Orthostatic Headache

Orthostatic headache is the most common presentation of SIH. It is characteristic by headache occurring or worsening within 15 minutes of assuming the upright position and improving within 15 to 30 minutes after lying down.[13] In the horizontal position, CSF pressures at lumbar, cisternal, and intracranial or vertex levels are equal (60–250 mm of H2O in adults). In healthy individuals, sitting greatly increases CSF pressure with CSF opening pressure values ranging from 320 to 630 mm H2O. In the vertical position, vertex pressure changes to negative, while lumbar pressure increases, hence causing headache and increasing risk of SDH. In a review of clinical features, 8% of patients had a nonorthostatic headache and 3% did not experience headaches. Headache was thought to be due to sinking of brain, causing stretch and distortion of pain sensitive suspending structures, also due to engorgement of cerebral venous sinuses and veins.[14] Other symptoms are nausea/vomiting (50.6%), neck pain/stiffness (33%), tinnitus (19%), dizziness (14%), hearing disturbances (10.7%), followed by visual disturbances, vertigo, back pain, and cognitive symptoms.[3] Rarely, cognitive changes,

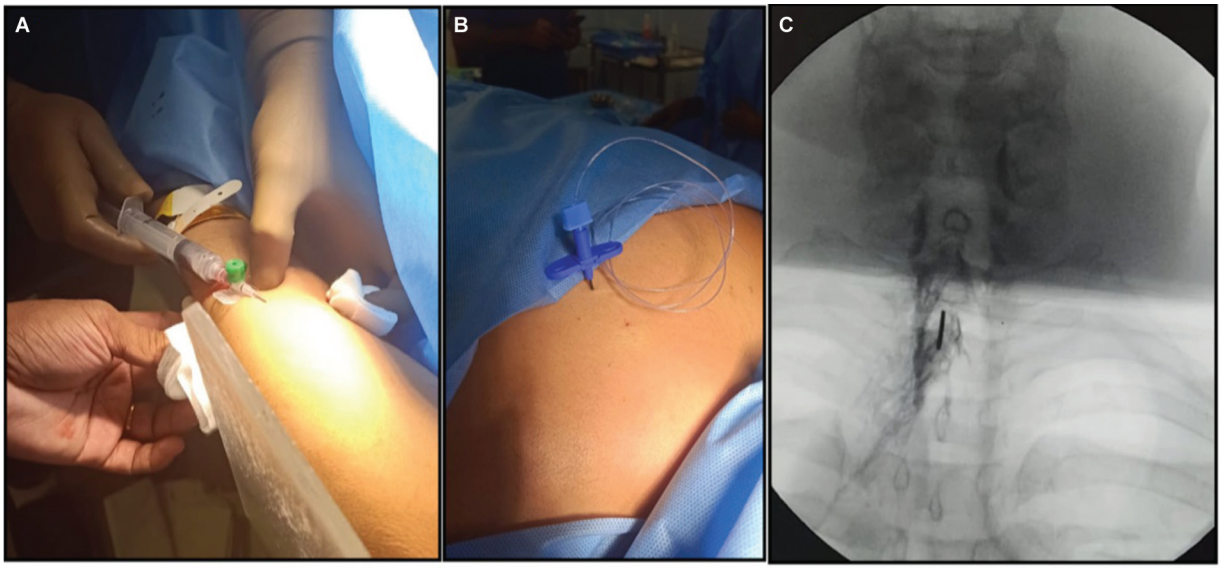

Fig. 3 (A) Collecting autologous blood, (B) epidural puncture via Tuohy needle, (C) identification of epidural space at C7-T1 interlaminar space using fluoroscopy and iodinated contrast.

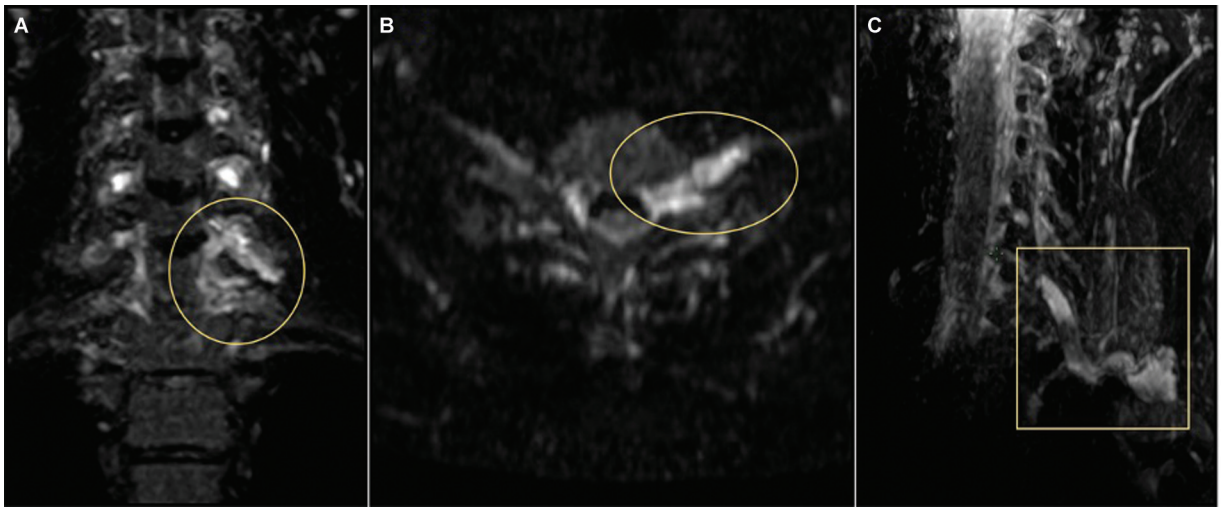

Fig. 4 Magnetic resonance (MR) neurogram (**A**) coronal section, (**B**) axial, and (**C**) dynamic MR neurogram—Patient was positioned on left lateral position. All showing fluid signal along left C7 nerve root confirming recurrent cerebrospinal fluid leak.

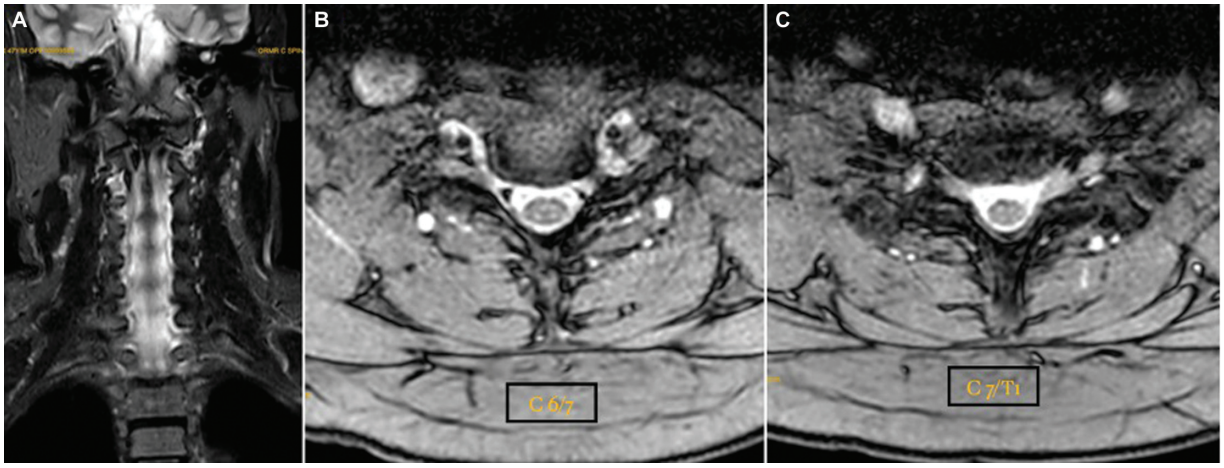

Fig. 5 Magnetic resonance neurogram (**A**) coronal (**B**) and (**C**) axial section at C6/7 and C7/T1 level, showing no cerebrospinal fluid leak as previous scan.

dementia, and even coma have been reported. Some patients do not have headache at all.[9]

MRI Brain Features in SIH

The three most characteristic features of intracranial hypotension are pachymeningeal enhancement, brain sagging (downward displacement of brain), and subdural fluid collection. Pachymeningeal enhancements are diffuse and may not be seen in all patients. There enhancements are not seen in leptomeninges, as they have blood–brain barriers and pachymeninges do not; it is only pachymeninges that enhances with gadolinium.[14] Brain sagging is more specific finding of SIH and can be identified by effacement of suprasellar cistern, bowing of optic chiasma over pituitary fossa, flattening of pons over clivus, and downward displacement of cerebellar tonsils. Study done by Schievink et al[15] showed subdural collections were present in 50% of patients with SIH (60% had subdural hygroma and 40% SDH). Most of them were present bilaterally (symmetric—85% or asymmetric—15%), unilateral (5%).[15] Other signs suggesting SIH are engorgement of venous sinuses, enlargement of pituitary, and reduction in optic nerve sheath subarachnoid space.[12,16]

Dynamic MR Neurogram

In all three cases, we saw a great role of early non-invasive and non-contrast dynamic MR neurography for diagnosis and EBP for management of spinal CSF leak and relieving associated symptoms. In case 1, we did dynamic MR neurogram to confirm our diagnosis, where CSF leak exacerbated with change in body position. Dynamic MR neurogram is typically used when a spinal CSF leak is suspected but not easily detected through standard static imaging. It is especially useful when leaks are intermittent or posture-dependent. These are heavily T2-weighted image (three-dimensional [3D] nerve isotropic sequence) with volume acquisition and reconstruction that allows for real-time visualization of the spinal cord, nerves, pooling of CSF

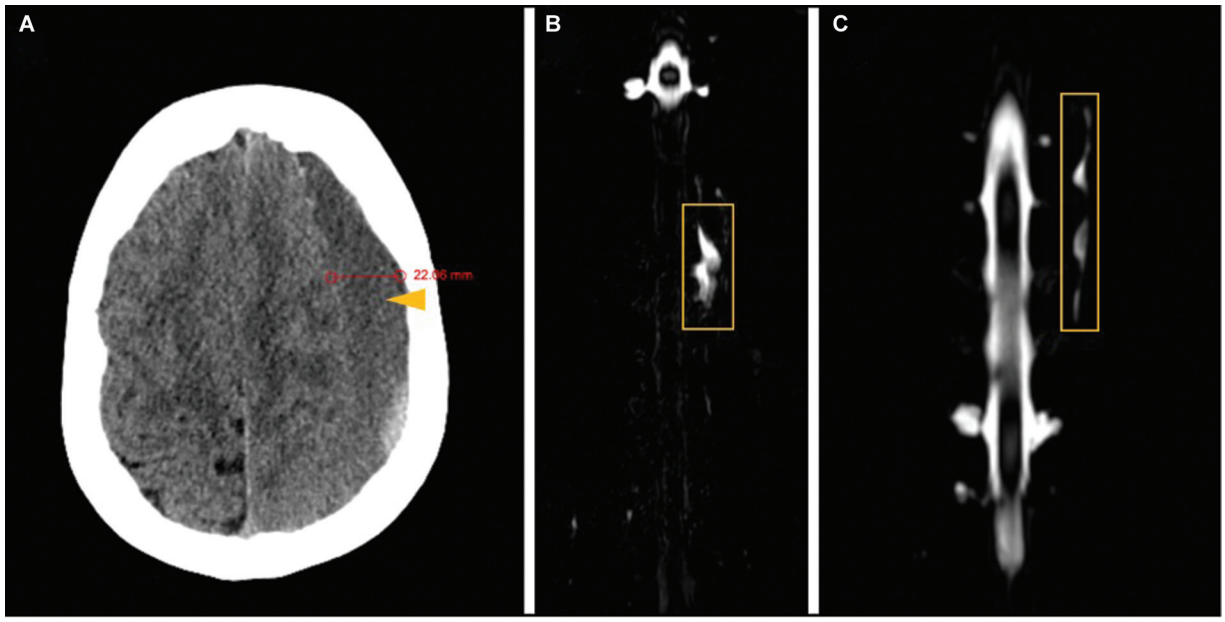

Fig. 6 (**A**) Computed tomographic brain plain showing left-sided subdural hematoma with maximum thickness of 22 mm. (**B**) and (**C**) Magnetic resonance neurogram showing fluid signal along left C7, D1 nerve root and fluid signal along medial pleural border, respectively, suggesting cerebrospinal fluid leak.

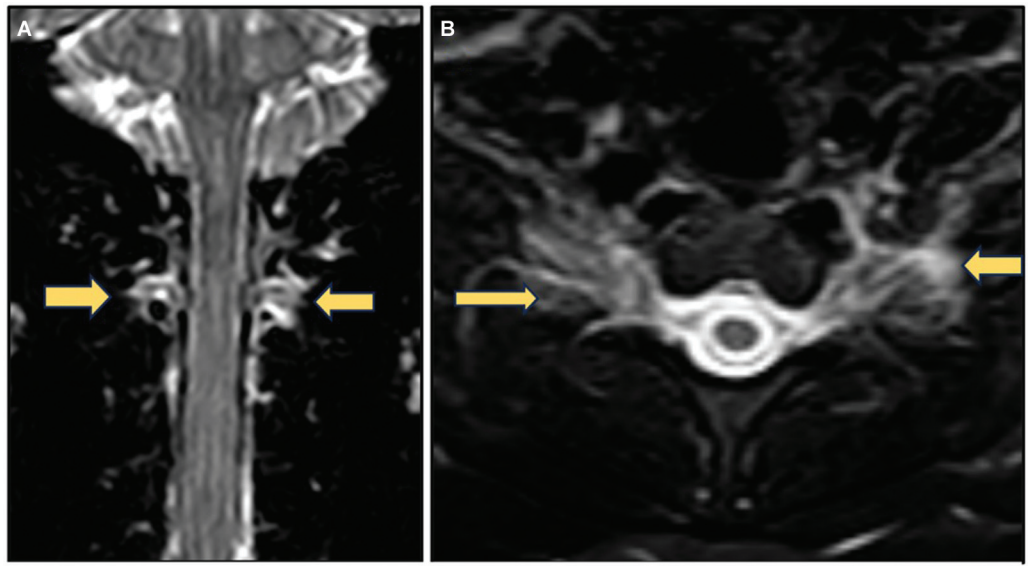

Fig. 7 (**A**) Coronal and (**B**) axial section—magnetic resonance neurogram showing cerebrospinal fluid leak at T1/2 level (bilaterally).

along the nerve, and CSF extravasation along the surrounding soft tissue. It allows the high-signal nerves to stand out from the darker fat-suppressed background soft tissues. These are high-resolution 3D short tau inversion recovery sequence with a large bandwidth that allows improved suppression in a higher range of frequencies. Motion-sensitized driven equilibrium pulse results in dephasing of moving spins, nulling unwanted signal from blood vessels

Table 2 Case synopsis

Case no.	Age/Gender (years)	Site of CSF leak	Type[10–12]	Association with SDH	Orthostatic headache	Treatment
1.	46 y/ male	Left C6-7 and C7-T1 level	Type 2a	+	+	Burr hole + EBP
2.	68 y/ female	Left T4-T5 level	Type 2a	+	+	Burr hole + EBP
3.	30 y/ male	T1-T2 level	Type 4	-	+	EBP

Abbreviations: CSF, cerebrospinal fluid; EBP, epidural blood patch; SDH, subdural hematoma.

Table 3 Three-dimensional NerveView parameters for the assessment of spinal CSF leak in Philips 1.5T MRI in our institute

TR/TI/TE, ms	2200/255/190
FOV, mm	300 × 406 × 120
Slice thickness/slice gap, mm	1.5/- 1.2
Acquired matrix	252 × 313
Acquired voxel size, mm	1.19 × 1.30 × 2.40
Reconstructed voxel size, mm	0.53 × 0.53 × 1.20
Slice oversampling	1.5
BB pulse	MSDE
Fat saturation	STIR
SENSE acceleration factor	3 × 1.2
Acquisition time, min	∼ 5:00
Fold-over suppression, mm	98 × 98

Abbreviations: BB, black blood; CSF, cerebrospinal fluid; FOV, field of view; MRI, magnetic resonance imaging; MSDE, motion-sensitized driven equilibrium; STIR, short tau inversion recovery; TSE, turbo spin echo.

that run parallel to the nerves, and reduce intralumenal signal of vessels. 3D nerve isotropic imaging method allows for reformats in any plane (including oblique) with no loss of resolution, hence improving visualization of spinal nerves and leak sites.[17] Till date there is no literature explaining role of MR neurogram for detecting spontaneous spinal CSF leak. However, both MR myelography and CT myelography are well known in detecting and localizing spinal CSF leaks. MR myelography is excellent for visualizing soft tissues and subtle leaks, while CT myelography excels at identifying bony causes of CSF leaks. In our study, we used dynamic MR neurography as primary investigation. Akbar et al showed that gadolinium MR myelogram detected higher percentage of leak as compared to CT myelogram; however, he concluded that CT myelography and MR gadolinium myelography are mostly complementary to each other, rather than duplicative.[18] The technical parameters used during MRI are summarized in ►**Table 3**.

Epidural Blood Patch, Connective Tissue Disorders, and Management Strategies

An EBP involves injecting a patient's own blood into the epidural space, which is the area outside the dura mater. The blood forms a clot and creates a seal that prevents CSF leakage. We did not find any evidence of connective tissue disorder in the case 1; however in case 2 we found an association with RA. The link between RA and spontaneous CSF leaks remains less explored in medical literature. Several theories are under consideration: chronic inflammation weakening connective tissue, possibly rendering the dura mater more susceptible to tears or leaks; RA-related vasculitis might impact the blood supply of dura, elevating the risk of tears or leaks; long-term use of corticosteroids, a common RA treatment, may weaken tissues and potentially contribute to CSF leak development. However, we could not do any genetic testing to rule out other rare conditions associated with spontaneous spinal dural CSF leak like TGFBR1/TGFBR2/SMAD3 genes for Loeys-Dietz syndrome, NF1 gene for Type 1 neurofibromatosis, GDF6/GDF3 gene in Klippel-Feil syndrome, ATP7A gene in Menkes disease, FBN1 gene in Marfan syndrome, COL5A/ COL3A/ PLOD1 gene in Ehler Danlos syndrome. A study done in Japan in 2015[19] highlights the therapeutic strategies and outcomes of 55 cases with SIH associated with chronic SDH. Conservative therapy alone was effective in 13 cases (23.6%). However, 25 cases underwent an EBP as the initial procedure, with 72.0% fully cured by the first EBP. Among the seven cases (28.0%) that needed SDH surgeries, two had a significant hematoma volume and severe symptoms, requiring surgery. Initial SDH surgery was performed in 17 cases, with 35.7% fully cured, while 64.3% needed additional treatment, such as multiple hematoma irrigations or multiple EBPs. The intracranial pressure associated with SDH was notably lower when the CSF leak was untreated, hence affecting hematoma drainage. Adequate treatment of the CSF leak led to higher intracranial pressure and improved hematoma drainage. Ultimately, all 55 cases achieved good recovery without serious complications or recurrences during the follow-up period (mean: 3.6 years). Regarding definitive management, microsurgical repair of leak site remains the last resort.[11] However, conservative measures like bed rest, hydration, coffee, analgesics, and abdominal binders should not be forgotten.[14] Repeated EBP injection seems to be reasonable option as was seen in our case 1.

Limitations

MR myelogram or CT myelogram remains the standard methods for detecting spinal CSF leak, both of which require contrast (gadolinium and iodinated contrast respectively) and are invasive techniques. MR neurography is not as widely utilized due to lack of awareness and literature lacking support for its sensitivity and specificity to detect SIH. Though dynamic MR neurography can be performed at any center having access to advanced pulse sequences, selective MRI sequence techniques like 3D nerve view also have their own set of pitfalls and artefacts.[17] Reporting dynamic MR Neurography requires a highly trained radiologist with good clinical experience in the reading the MRI sequence as well as detecting SIH.

Conclusion

Spontaneous spinal CSF leaks, while often elusive in their presentation, can lead to various complications, one of which is the development of SDH. Dynamic MR neurography emerges as a valuable diagnostic tool, offering high-resolution imaging of CSF dynamics and potential leak sites. Its noninvasive nature, coupled with its high sensitivity to subtle anatomical alterations, helps clinicians in pinpointing the exact location and extent of the leak, especially when a spinal CSF leak is suspected but it is not easy to detect through standard static imaging or when leaks are intermittent or posture-dependent. However, availability is a limitation as not all medical centers have the equipment or expertise to perform dynamic MRI neurography or myelography for spinal CSF leak

evaluation. Bern score proposed by Dobrocky et al[20] proved to be helpful in suspecting SIH. EBP, on the other hand, serves as both a therapeutic and preventive measure. By harnessing the body's innate healing mechanisms, it provides a sealing effect that counters CSF leakage. Beyond its role in treating CSF leaks, EBP holds promise as a preventive strategy postspinal procedures, thereby reducing the risk of complications. However, we also conclude that doing burr hole prior to EBP in SIH can potentially lead to worsening of symptoms with higher potential of recurrence and requiring repeat EBP[19] as we have already seen in case 1. Patients with SIH are commonly misdiagnosed (~ 94%) causing delay in initiation of treatment[16] hence, it requires increased awareness among physicians. While challenges persist in understanding the intricacies of spontaneous spinal CSF leaks, ongoing research and collaboration among medical professionals continue to refine diagnostic accuracy and optimize treatment methodology.

Consent to Publish

Informed consent was obtained from all individual participants to use MRI or CT images included in the study. Identifying information regarding participants is not included in the study.

Conflict of Interest

None declared.

References

1 Limaye K, Samant R, Lee RW. Spontaneous intracranial hypotension: diagnosis to management. Acta Neurol Belg 2016; 116(02):119–125

2 Schievink WI. Spontaneous spinal cerebrospinal fluid leaks and intracranial hypotension. JAMA 2006;295(19):2286–2296

3 D'Antona L, Jaime Merchan MA, Vassiliou A, et al. Clinical presentation, investigation findings, and treatment outcomes of spontaneous intracranial hypotension syndrome: a systematic review and meta- analysis. JAMA Neurol 2021;78(03):329–337

4 Sandow BA, Donnal JF. Myelography complications and current practice patterns. AJR Am J Roentgenol 2005;185(03):768–771

5 Luetzen N, Dovi-Akue P, Fung C, Beck J, Urbach H. Spontaneous intracranial hypotension: diagnostic and therapeutic workup. Neuroradiology 2021;63(11):1765–1772

6 Shah LM, McLean LA, Heilbrun ME, Salzman KL. Intracranial hypotension: improved MRI detection with diagnostic intracranial angles. AJR Am J Roentgenol 2013;200(02):400–407

7 Farb RI, Forghani R, Lee SK, Mikulis DJ, Agid R. The venous distension sign: a diagnostic sign of intracranial hypotension at MR imaging of the brain. AJNR Am J Neuroradiol 2007;28(08): 1489–1493

8 Wang DJ, Pandey SK, Lee DH, Sharma M. The interpeduncular angle: a practical and objective marker for the detection and diagnosis of intracranial hypotension on brain MRI. AJNR Am J Neuroradiol 2019;40(08):1299–1303

9 Kranz PG, Gray L, Malinzak MD, Amrhein TJ. Spontaneous intracranial hypotension: pathogenesis, diagnosis, and treatment. Neuroimaging Clin N Am 2019;29(04):581–594

10 Schievink WI, Maya MM, Jean-Pierre S, Nuño M, Prasad RS, Moser FG. A classification system of spontaneous spinal CSF leaks. Neurology 2016;87(07):673–679

11 Beck J, Raabe A, Schievink WI, et al. Posterior approach and spinal cord release for 360° repair of dural defects in spontaneous intracranial hypotension. Neurosurgery 2019;84(06):E345–E351

12 Schievink WI. Spontaneous intracranial hypotension. N Engl J Med 2021;385(23):2173–2178

13 Urbach H. Intracranial hypotension: clinical presentation, imaging findings, and imaging-guided therapy. Curr Opin Neurol 2014;27(04):414–424

14 Mokri B. Spontaneous intracranial hypotension. Continuum (Minneap Minn) 2015;21(4 Headache):1086–108 PubMed

15 Schievink WI, Maya MM, Moser FG, Tourje J. Spectrum of subdural fluid collections in spontaneous intracranial hypotension. J Neurosurg 2005;103(04):608–613

16 Schievink WI. Misdiagnosis of spontaneous intracranial hypotension. Arch Neurol 2003;60(12):1713–1718

17 Martín-Noguerol T, Montesinos P, Hassankhani A, Bencardino DA, Barousse R, Luna A. Technical update on MR neurography. Semin Musculoskelet Radiol 2022;26(02):93–104

18 Akbar JJ, Luetmer PH, Schwartz KM, Hunt CH, Diehn FE, Eckel LJ. The role of MR myelography with intrathecal gadolinium in localization of spinal CSF leaks in patients with spontaneous intracranial hypotension. AJNR Am J Neuroradiol 2012;33(03): 535–540

19 Takahashi K, Mima T, Akiba Y. Chronic subdural hematoma associated with spontaneous intracranial hypotension: therapeutic strategies and outcomes of 55 cases. Neurol Med Chir (Tokyo) 2016;56(02):69–76

20 Dobrocky T, Grunder L, Breiding PS, et al. Assessing spinal cerebrospinal fluid leaks in spontaneous intracranial hypotension with a scoring system based on brain magnetic resonance imaging findings. JAMA Neurol 2019;76(05):580–587

