



# Mucormycosis Associated with COVID-19

Bhavya Gajjela<sup>1</sup> Michelle Mathias<sup>1</sup> K. Sajitha<sup>1</sup>

<sup>1</sup> Department of Pathology, K.S. Hegde Medical Academy, Nitte-Deemed to be University, Mangalore, Karnataka, India

**Address for correspondence** Bhavya Gajjela, MD, K.S. Hegde Medical Academy, Nitte-Deemed to be University, Mangalore 575018, Karnataka, India (e-mail: bhavya.gajjela08@gmail.com).

J Health Allied Sci<sup>NU</sup>

## Abstract

### Keywords

- ▶ COVID-19
- ▶ diabetes
- ▶ rhinocerebral mucormycosis

Mucormycosis is an angioinvasive disease caused by fungi of the order Mucorales. In this article, three case reports of rhinocerebral mucormycosis developing after COVID-19 infection in a diabetic patient are presented. Early diagnosis and treatment of those high morbidity conditions are vital to better outcomes.

## Introduction

Coronavirus disease 2019 (COVID-19) caused by severe acute respiratory syndrome coronavirus 2 (SARS-CoV-2) first reported in Wuhan, China, rapidly spread to other regions of the world, causing a global pandemic.<sup>1,2</sup> It is associated with wide range of bacterial and fungal coinfections. The severity of the illness can vary from mild to fatal pneumonia. It has been linked to a variety of bacterial and fungal coinfections.<sup>1</sup> Mucormycosis is an acute and fatal fungal infection caused by fungi of the order Mucorales such as *Mucor*, *Rhizopus*, *Rhizomucor*, *Absidia*, and *Cunninghamella*.<sup>3</sup> Mucormycosis has an aggressive propensity for contiguous spread and is associated with poor prognosis, if it is not properly and quickly identified and treated.<sup>4</sup> Mucormycosis frequently infects the sinuses, lungs, or brain.<sup>5</sup>

The major risk factors for mucormycosis include immunocompromised conditions like uncontrolled diabetes mellitus with ketoacidosis, corticosteroid usage, hematological malignancies, stem cell, and solid organ transplantations.<sup>6</sup> In India, diabetes mellitus is the most common risk factor associated with mucormycosis.<sup>7</sup> Here we present three case reports of mucormycosis associated with COVID-19 in diabetic patients.

## Case Report

### Case 1

A 46-year-old man, recently diagnosed with type 2 diabetes mellitus on regular medications, presented with

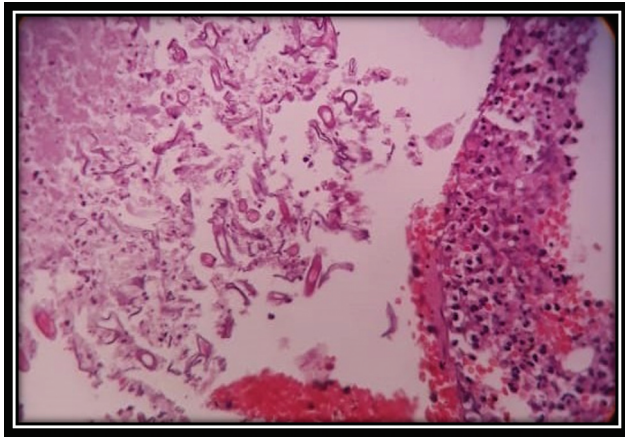
complaints of swelling and pain in the left side of the face and headache for 1 week. COVID-19 cartridge-based nucleic acid amplification test (CBNAAT) was done and he was positive and admitted to the Covid-positive ward. Anterior rhinoscopy was done, which showed bony spicules in the left middle meatus, eschar in the left inferior turbinate, and unhealthy mucosa in the left nasal mucosa. Magnetic resonance imaging (MRI) of the brain with contrast showed polypoidal mucosal thickening of bilateral maxillary sinus with air fluid level in the left maxillary sinus and erosion of the medial wall of the left maxillary sinus. Similar mucosal thickening of the bilateral frontal sinus with blurred cortical outline of the posterior wall of the left frontal sinus was noted. Mucosal thickening noted along the left inferior, middle turbinate, and along the left nasal cavity with erosion of the bilateral inferior and middle turbinates. Features were suggested as fungal sinusitis. No intracranial structural abnormality was detected. He underwent endoscopic debridement, followed by conventional amphotericin therapy, and the sample was sent to the histopathology lab. Histopathological analysis of the sample from the left nasal cavity turbinates and maxillary sinus showed colonies of fungal hyphae having broad, infrequent septa with right angle branching (▶ **Fig. 1**). Periodic acid-Schiff (PAS) stain confirmed the fungal structures. The features suggested an invasive mucormycosis of the left nasal cavity. Ophthalmology reference was given in view of the left eye pain. After completing 2 weeks of isolation, the patient was readmitted to the general ward for further continuation of treatment. Computed tomography (CT) of the paranasal sinus (PNS)

DOI <https://doi.org/10.1055/s-0044-1779615>.  
ISSN 2582-4287.

© 2024. The Author(s).

This is an open access article published by Thieme under the terms of the Creative Commons Attribution License, permitting unrestricted use, distribution, and reproduction so long as the original work is properly cited. (<https://creativecommons.org/licenses/by/4.0/>)

Thieme Medical and Scientific Publishers Pvt. Ltd., A-12, 2nd Floor, Sector 2, Noida-201301 UP, India

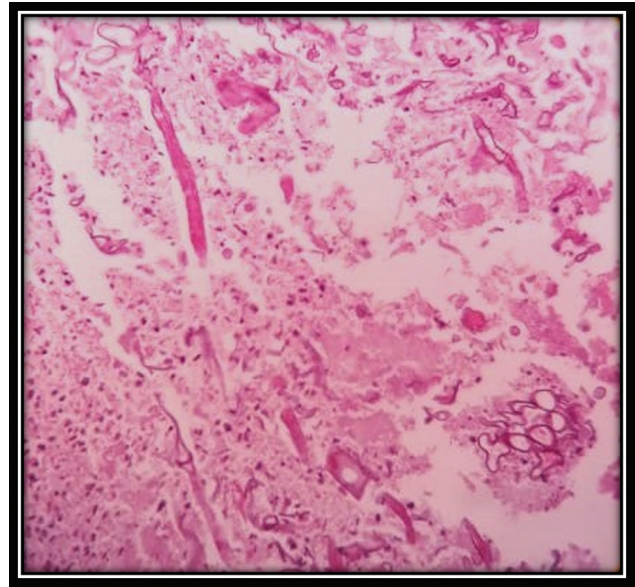


**Fig. 1** Histopathology (H & E stain) showed -mucormycosis (400X).

was done and bony erosion involving the hard palate and alveolar process of the maxilla on both sides were noted. Repeat diagnostic nasal endoscopy (DNE) was done and bilateral partial inferior maxillectomy was done.

#### Case 2

A 49-year-old man, newly diagnosed with type 2 diabetes mellitus on medication and hypertensive for 4 years on regular medications, presented with complaints of headache for 8 days and swelling in the eye for 2 days. He was Covid positive a month back and he gave a history of steroid intake. Outside MRI report showed mucosal thickening in bilateral anterior ethmoidal sinus with thinning of the cribriform plate with associated signal changes in the right basifrontal region and bilateral orbit as well as soft-tissue enhancement in the periorbital region—features suggestive of fungal etiology. Scan of the osteomeatal complex done after admission showed mucosal thickening of the bilateral ethmoid and frontal sinuses with thinning and erosion of the cribriform plates. Features were suggestive of invasive fungal sinusitis. He underwent endoscopic debridement with Hadad flap for cerebrospinal fluid (CSF) leak and sample was sent to histopathology laboratory. Histopathological analysis of the sample showed colonies of fungal hyphae, which were broad based, branched, and aseptate (**Fig. 2**). PAS stain confirmed the fungal structures. Features suggested fungal infection, mucormycosis - anterior ethmoidal polyp, fungal elements from the posterior nasal septum, middle turbinate, and septal mucosa. The patient was irregularly treated with amphotericin B injection. Nephrology reference was given in view of high creatinine, hypokalemia, and hypomagnesaemia; orders were followed. Ophthalmology reference was given in view of the right eye swelling and headache; advise was followed. DNE was done, which showed a necrosed cribriform plate. Repeat MRI was taken and diagnosed with intracranial extension of mucormycosis and the patient was advised skull base surgery. The patient was referred from our hospital to other hospital for further management.



**Fig. 2** Histopathology (H & E stain) showed -mucormycosis (400X).

#### Case 3

A 27-year-old man, newly diagnosed with type 2 diabetes, presented with complaints of left-sided headache for 1 month, left-sided facial pain for 1 week, and swelling of the left cheek for 1 week. COVID-19 reverse transcription polymerase chain reaction (RT-PCR) was done, which showed a positive result. DNE was done, which showed an S-shaped deviated nasal septum (DNS) with spur and mucopus in both nasal cavities. Outside CT showed mucosal thickening in the bilateral maxillary, sphenoid, ethmoid, and frontal sinuses. MRI showed bilateral maxillary, sphenoid left ethmoid, and left frontal sinusitis. There was DNS to the right with bony spur. Medicine reference was given in view of high sugars and COVID-19-positive status and their advice was followed. Ophthalmology reference was given in view of the left eye pain and vision was assessed, which was found normal. The patient underwent left frontoethmoid sphenoidotomy with endoscopic debridement under general anesthesia, and tissue was sent for histopathological examination. Histopathological analysis of the sample showed colonies of fungal hyphae, which were broad based, branched, and aseptate. PAS stain confirmed the fungal structures. Features suggested fungal sinusitis with angioinvasion favoring mucormycosis—left maxillary sinus and right maxillary sinus. Fungal potassium hydroxide (KOH) mount showed hyaline aseptate branching fungal hyphae. Conventional amphotericin injection was given. Nephrology reference was given in view of altered urea and creatinine values. Monitoring of blood sugars, urea, and creatinine levels was done regularly. DNE done 2 weeks later showed crusts and necrotic remnants. Postsurgery liposomal amphotericin was continued. Routine evaluation by medicine for glycemic control and evaluation by nephrology during amphotericin infusion. The patient recovered and was discharged with tablet posaconazole.

## Discussion

Mucormycosis is clinically classified as rhino-orbital-cerebral mucormycosis, pulmonary, cutaneous, gastrointestinal, disseminated, and other unusual forms based on the anatomical location.<sup>7</sup> The incidence rate of mucormycosis varies from 0.005 to 1.7 per million individuals globally. India has the highest prevalence of mucormycosis (0.14 per 1,000).<sup>8</sup> In a large 2018 meta-analysis of 851 cases with mucormycosis, diabetes mellitus was found to be an independent risk factor (odds ratio [OR]: 2.69; 95% confidence interval 1.77–3.54;  $p < 0.001$ ), and *Rhizopus* was the most often isolated species (48%).<sup>9</sup> Hematological malignancies, other malignancies, corticosteroids, prolonged neutropenia, transplantation, neonatal prematurity, illicit intravenous drug use, and malnourishment are other predisposing factors.<sup>6</sup> In our study, all three cases had high blood sugar levels at presentation, suggesting that it may be the underlying cause of mucor infection.

According to recent systematic review by John et al that was completed in April 9, 2021, which presented the findings of 41 confirmed cases of mucormycosis in individuals with COVID-19, diabetes mellitus was documented in 93% of cases, while 88% were getting corticosteroids.<sup>10</sup> In another case series by Singh et al, of the 101 mucormycosis cases in COVID-19 patients, 80% cases had preexisting diabetes and 76.3% received a course of corticosteroids. In their study, the most common risk factor for mucormycosis in persons with COVID-19 was hyperglycemia (83.3%) at presentation (due to preexisting diabetes or new-onset hyperglycemia, new-onset diabetes, or diabetic ketoacidosis), followed by malignancy (3.0%).<sup>8</sup> In study by Patel et al, the predisposing factors associated with mucormycosis in Indians include diabetes (73.5%), malignancy (9.0%), and organ transplantation (7.7%).<sup>11</sup> These findings are consistent with our study, in which all the three cases of COVID-19 with mucormycosis had a history of recent-onset diabetes.

Increased viral load due to efficient virus entry is one possible mechanism through which diabetes can increase infection risk. High blood glucose levels can increase glucose concentrations in airway secretions. Virus infection and replication may be increased by exposure of pulmonary epithelial cells to increased glucose concentrations.<sup>12</sup>

Lymphopenia is other predisposing factor for mucor infection in Covid patients with additional suppression of the immune system. Increased neutrophils and decreased lymphocytes also correlate with disease severity and death.<sup>13</sup> It is hypothesized that CD4 and CD8 T cells are involved in Covid infection pathology. Innate immune system is altered in diabetic people. In diabetic individuals, chemotaxis and phagocytosis are impaired. Proinflammatory M1 macrophages are increased and natural killer (NK) cell activity is reduced in diabetes.<sup>14</sup> Hyperinflammatory response and delay in interferon- $\gamma$  (IFN- $\gamma$ ) response in diabetics may aggravate cytokine storm and increases Covid severity.<sup>15</sup>

The treatment of COVID-19-associated mucormycosis includes a timely combination of surgery and antifungal therapy. Surgery is sinonasal debridement in most cases. In our study, all the three cases had undergone endoscopic debridement, followed by antifungal therapy.

## Conclusion

Mucormycosis is an angioinvasive disease caused by fungi of order Mucorales. Although there have always been incidences of mucormycosis, the Covid era has seen an increase in these cases. Impaired immune system is the underlying cause for Covid infection. It is essential to maintain optimal glucose levels. Histopathological examination of tissue samples confirms the diagnosis of mucormycosis. Cultures are occasionally positive. Histopathological findings of mucormycosis are nonseptate, irregular hyphae. Initial treatment requires early aggressive surgical debridement of infected tissues, along with administration of amphotericin B. Early diagnosis and treatment can reduce progression of disease and decrease mortality rate.

### Funding

None.

### Conflict of Interest

None declared.

## References

- Sarkar S, Gokhale T, Choudhury SS, Deb AK. COVID-19 and orbital mucormycosis. *Indian J Ophthalmol* 2021;69(04):1002–1004
- Farnoosh G, Alishiri G, Hosseini Zijoud SR, Dorostkar R, Jalali Farahani A. Understanding the severe acute respiratory syndrome coronavirus 2 (SARS-CoV-2) and coronavirus disease (COVID-19) based on available evidence: a narrative review. *J Mil Med* 2020; 22:1–11
- Revannavar SM, Supriya PS, Samaga L, Vineeth VK. COVID-19 triggering mucormycosis in a susceptible patient: a new phenomenon in the developing world? *BMJ Case Rep* 2021;14(04):e241663
- Ahmadikia K, Hashemi SJ, Khodavaisy S, et al. The double-edged sword of systemic corticosteroid therapy in viral pneumonia: a case report and comparative review of influenza-associated mucormycosis versus COVID-19 associated mucormycosis. *Mycoses* 2021;64(08):798–808
- Chennamchetty VK, Adimulapu S, Kola BP, et al. Post-COVID pulmonary mucormycosis: a case report. *IP Indian J Immunol Respir Med* 2021;6(01):62–66
- Sargin F, Akbulut M, Karaduman S, Sungurtekin H. Severe rhinocerebral mucormycosis case developed after COVID 19. *J Bacteriol Parasitol* 2021;12:386
- Prakash H, Chakrabarti A. Global epidemiology of mucormycosis. *J Fungi (Basel)* 2019;5(01):26
- Singh AK, Singh R, Joshi SR, Misra A. Mucormycosis in COVID-19: a systematic review of cases reported worldwide and in India. *Diabetes Metab Syndr* 2021;15(04):102146
- Jeong W, Keighley C, Wolfe R, et al. The epidemiology and clinical manifestations of mucormycosis: a systematic review and meta-analysis of case reports. *Clin Microbiol Infect* 2019;25(01):26–34

- 10 John TM, Jacob CN, Kontoyiannis DP. When uncontrolled diabetes mellitus and severe COVID-19 converge: the perfect storm for mucormycosis. *J Fungi (Basel)* 2021;7(04):298
- 11 Patel A, Kaur H, Xess I, et al. A multicentre observational study on the epidemiology, risk factors, management and outcomes of mucormycosis in India. *Clin Microbiol Infect* 2020;26(07):944.e9–944.e15
- 12 Kohio HP, Adamson AL. Glycolytic control of vacuolar-type ATPase activity: a mechanism to regulate influenza viral infection. *Virology* 2013;444(1–2):301–309
- 13 Erener S. Diabetes, infection risk and COVID-19. *Mol Metab* 2020;39:101044
- 14 Lecube A, Pachón G, Petriz J, Hernández C, Simó R. Phagocytic activity is impaired in type 2 diabetes mellitus and increases after metabolic improvement. *PLoS One* 2011;6(08):e23366
- 15 Tay MZ, Poh CM, Rénia L, MacAry PA, Ng LFP. The trinity of COVID-19: immunity, inflammation and intervention. *Nat Rev Immunol* 2020;20(06):363–374