

Fronto-Orbitary Arteriovenous Malformation Reconstruction with Latissimus Dorsi Free Flap and Anterior Serratus Fascia Anastomosed to the Nutrient Vessels of the Lesion

Ana Trapero¹  Alberto Pérez-García¹ Pedro Alvedro Ruiz¹ Belén Andresen Lorca¹
Alessandro Thione¹

¹ Department of Plastic and Reconstructive Surgery, Hospital Universitari i Politècnic La Fe, Valencia, Spain

Indian J Plast Surg

Address for correspondence Alberto Pérez-García, PhD, Department of Plastic and Reconstructive Surgery, Hospital Universitari i Politècnic La Fe, Avinguda de Fernando Abril Martorell, 106, 46026 Valencia, Spain (e-mail: albertoperezgarci@gmail.com).

Sir:

After reading the article by Balakrishnan et al,¹ we wanted to congratulate the authors for their interesting contribution regarding this topic, especially about the use of feeding vessels as recipient vessels for free flap reconstruction in arteriovenous malformations (AVMs) in the face. In addition, they have remarked the regulating paper of free flaps in these malforma-

tions, which are useful not only to provide bulk and soft tissue coverage, but also to counteract and balance their ischemic environment, which is the main reason for their recurrence.

Here in, we present a case report of a 25-year-old patient who refers a painless mass in the right upper face since the age of 11 (► **Fig. 1**). The lesion had been unsuccessfully embolized in three different occasions, using permanent agents such as glue and

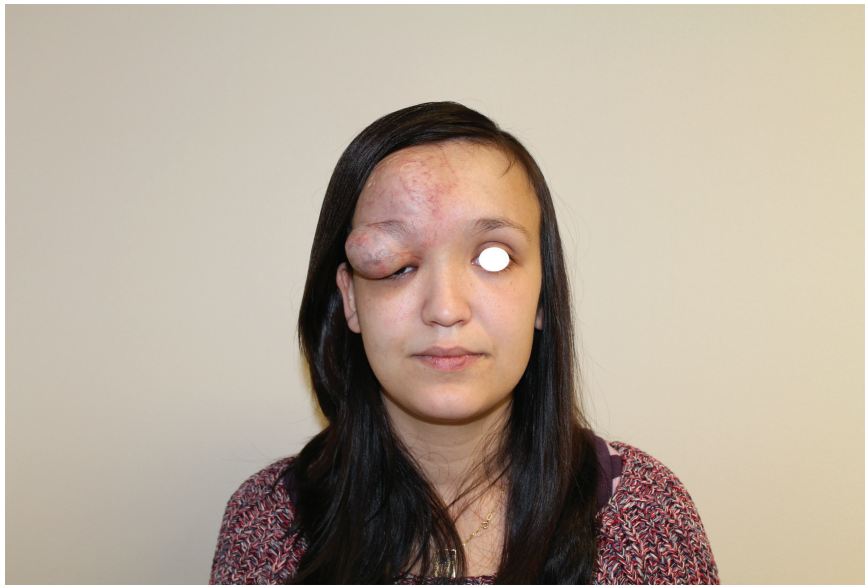

Fig. 1 Preoperative image of a 25-year-old patient with an extensive arteriovenous malformation affecting the fronto-orbitary region and upper eyelid.

DOI <https://doi.org/10.1055/s-0044-1779475>.
ISSN 0970-0358.

© 2024. Association of Plastic Surgeons of India. All rights reserved.
This is an open access article published by Thieme under the terms of the Creative Commons Attribution-NonDerivative-NonCommercial-License, permitting copying and reproduction so long as the original work is given appropriate credit. Contents may not be used for commercial purposes, or adapted, remixed, transformed or built upon. (<https://creativecommons.org/licenses/by-nc-nd/4.0/>)
Thieme Medical and Scientific Publishers Pvt. Ltd., A-12, 2nd Floor, Sector 2, Noida-201301 UP, India

Onyx. However, the AVM persisted growing and affecting the right fronto-orbital area (→**Fig. 2**). When the patient arrived at our department, we directly planned aggressive surgical treatment with previous tumor embolization. After surgical resection, which involved upper eyelid excision (preserving the posterior lamella with the upper tarsus and the conjunctiva), a free latissimus dorsi flap with anterior serratus fascia was harvested as a chimeric flap (→**Fig. 3**). The recipient vessels selected were the feeding vessels of the AVM: the frontal branch of the superficial temporal artery and the superficial temporal vein, which were anastomosed end-to-end to the subscapular artery and vena comitante. The muscle flap allowed the coverture of the wide resultant defect and face contour restoration, while the serratus fascia was employed for the reconstruction of the upper eyelid.

Two secondary procedures and scar revision surgeries were performed. The skin paddle of the flap was resected and grafted, leaving only the part of the skin paddle corresponding to the eyebrow. This would allow better quality of skin for future eyebrow tattoo. The upper eyelid reconstructed with anterior serratus fascia was reconfigured and covered with a

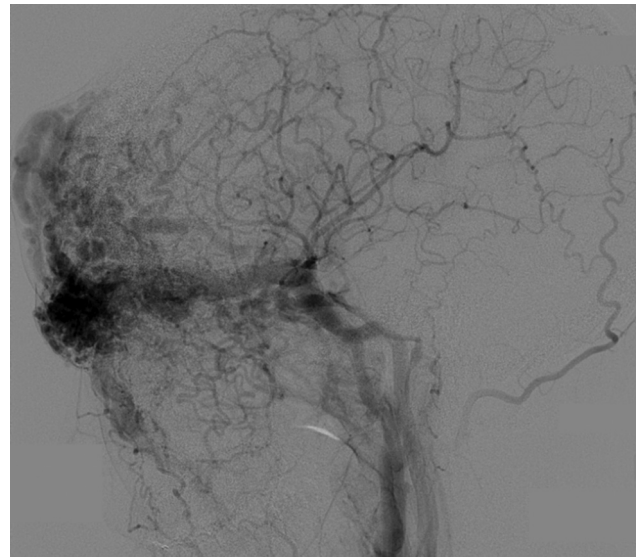


Fig. 2 Arteriography showing the vascular pattern of the tumor and its frontal component. We can observe how the superficial temporal artery is one of the main feeding vessels of the tumor.

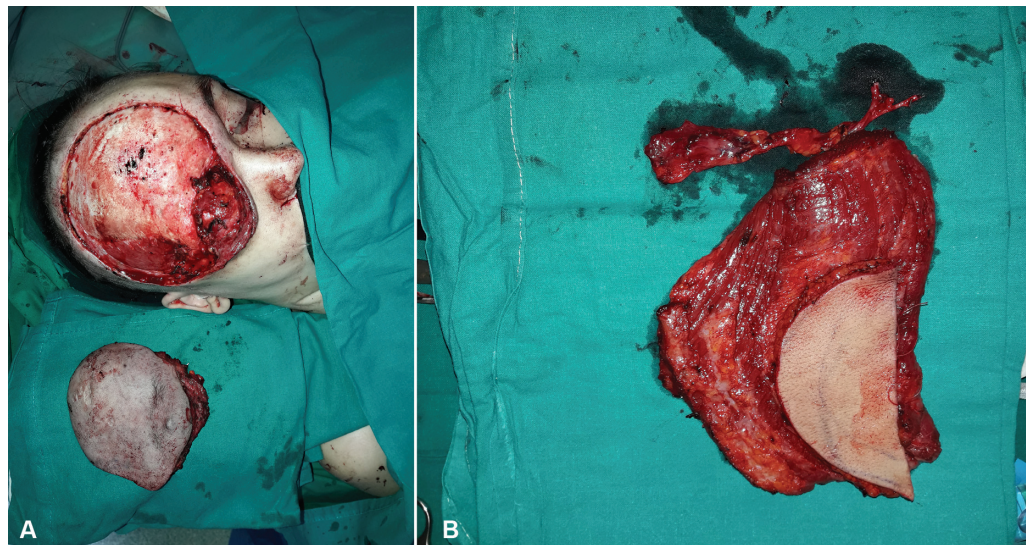


Fig. 3 (A) Soft-tissue defect after tumor resection, involving the right frontotemporal region and the upper eyelid. (B) Chimeric free latissimus dorsi flap, including the anterior serratus fascia for palpebral reconstruction.

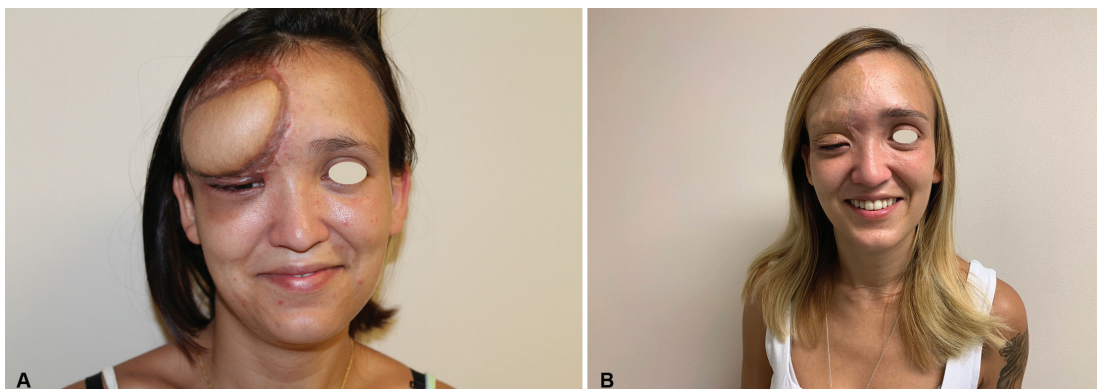

Fig. 4 (A) Image after the first surgery, prior to the revision surgeries, where we can see the skin paddle of the latissimus dorsi flap. (B) Final result 5 years after the resection of the arteriovenous malformation (AVM), with no current evidence of recurrence.

full-thickness skin graft. Posteriorly, a scalp advancement was made to improve the hairline aesthetics. A lateral canthoplasty was also performed in the same procedure.

Although the cosmetic sequelae are considerable, the aggressive AVM was totally eradicated. The patient can close the eye completely, without ocular symptoms (–**Fig. 4**). Five years after the initial surgery there is no evidence of recurrence of the tumor.

Optimal treatment of AVMs involves a combination of presurgical embolization and aggressive surgical resection made with a multidisciplinary approach.² Incomplete resections or isolated embolizations will involve recurrence due to their high risk of regrowth and invasion of neighboring tissues.³ Approaching AVMs with microvascular free tissue transfer has crucial benefits, like reducing the surrounding ischemia and therefore, avoiding the development of new arteriovenous shunts and recruitment of surrounding mesenchymal tissues which aggravate the lesion and stimulate tumor recurrence.^{1,4} For that reason, free flaps are an effective tool to guarantee definitive eradication of the malformation with safe margins while restoring face contour.

Funding

None.

Conflict of Interest

None declared.

References

- 1 Balakrishnan TM, Ilayakumar P, Vijay B, et al. regulating microvascular free flaps reconstruction in “Schobinger Stage 4” arteriovenous malformations of face. *Indian J Plast Surg* 2023;56(03): 218–227
- 2 Goldenberg DC, Hiraki PY, Caldas JG, Puglia P, Marques TM, Gemperli R. Surgical treatment of extracranial arteriovenous malformations after multiple embolizations: outcomes in a series of 31 patients. *Plast Reconstr Surg* 2015;135(02):543–552
- 3 Kohout MP, Hansen M, Pribaz JJ, Mulliken JB. Arteriovenous malformations of the head and neck: natural history and management. *Plast Reconstr Surg* 1998;102(03):643–654
- 4 Yamamoto Y, Ohura T, Minakawa H, et al. Experience with arteriovenous malformations treated with flap coverage. *Plast Reconstr Surg* 1994;94(03):476–482