Article published online: 2024-02-02

Superficial Femoral Artery Pseudoaneurysm Post-Subtrochanteric Femur Fracture

Ashref Saleh Tarhuni[1,2] Haitham Elmehdawi[3]

[1] Department of General Surgery and Vascular Surgery, Benghazi Medical Center, Benghazi, Libya
[2] Faculty of Medicine, Libyan International Medical University, Benghazi, Libya
[3] Department of General Surgery, Faculty of Medicine, Libyan International Medical University, Benghazi, Libya

Address for correspondence Ashref Tarhuni, MD, Department of surgery, Benghazi Medical Center, Benghazi, Libya, Faculty of Medicine, Libyan International Medical University, Benghazi, Libya (e-mail: tarhuniashref2@gmail.com).

Libyan Int Medical Univ J 2024;9:5–8.

Abstract

Superficial femoral artery injury due to bone fragment of femoral fracture is often overlooked as it occurs only in rare cases of femoral fractures and the onset of symptoms usually happen weeks or even months later. The deep femoral artery, in fact, is more susceptible to injuries associated with femoral fractures. Moreover, a preexisting calcification lesion of the arterial wall might enhance the chance of such arterial injury, a condition that we noticed in the case we are reporting. We will illustrate a rare case of calcified superficial femoral artery injury complicating subtrochanteric femur fracture.

Keywords
- superficial femoral artery
- deep femoral artery
- pseudoaneurysm
- proximal femur fracture

ملخص المقال باللغة العربية

تمدد الأوعية الدموية الكاذب في الشريان الفخذي السطحي

المؤلفون: أشرف الترهوني، هيثم المهدوي. كلية الطب، الجامعة الليبية الدولية للعلوم الطبية، بنغازي، ليبيا.

المؤلف المسؤول: أشرف الترهوني، البريد الإلكتروني: tarhuniashref2@gmail.com

غالبًا ما يتم التغاضي عن إصابة الشريان الفخذي السطحي بسبب جزء عظمي من كسر الفخذ، لأنها تحدث فقط في حالات نادرة من كسور الفخذ، وعادةً ما تحدث بداية الأعراض بعد أسابيع أو حتى أشهر. في الواقع، يكون الشريان الفخذي العميق أكثر عرضة للإصابات المرتبطة بكسور الفخذ. علاوة على ذلك، فإن آفة التكلس الموجودة مسبقًا في جدار الشرايين قد تزيد من فرصة حدوث مثل هذه الإصابة الشريانية، وهذا ما لاحظناه في الحالة التي نبلغ عنها. سنوضح في هذا التقرير حالة نادرة لإصابة الشريان الفخذي السطحي المتكلس مما يؤدي إلى تعقيد كسر عظم الفخذ تحت المدور.

الكلمات المفتاحية: الشريان الفخذي السطحي، الشريان الفخذي العميق، تمدد الأوعية الدموية الكاذب، كسر عظم الفخذ القريب.

article published online
February 2, 2024

DOI https://doi.org/10.1055/s-0044-1779306.
ISSN 2519-139X.

© 2024. The Author(s).
This is an open access article published by Thieme under the terms of the Creative Commons Attribution License, permitting unrestricted use, distribution, and reproduction so long as the original work is properly cited. (https://creativecommons.org/licenses/by/4.0/)
Thieme Medical and Scientific Publishers Pvt. Ltd., A-12, 2nd Floor, Sector 2, Noida-201301 UP, India

Introduction

Vascular injury following proximal femur fractures, particularly subtrochanteric fractures, is rare with an incidence of 0.2%.[1] Such injury may be missed because of late presentation.[2] Orthopaedic surgeons should be mindful of delayed onset of vascular injury resulting from proximal femur fractures.

Vascular compromise in this anatomical region can be caused by bone fragments formed either due to iatrogenic reasons or after fracture, intramedullary nail locking screws, drilling perforation, or movement of bone fragments during reduction.[3] Depending on the vessel wall defect, the lesion may cause a massive intraoperative bleeding or subacute hematoma formation with arterial pseudoaneurysm development.[3]

We report a false aneurysm of a calcified atherosclerotic right superficial femoral artery (SFA) that was unrecognized by the orthopaedic surgeon, subsequent to subtrochanteric femur fracture with displaced lesser trochanteric fragment and uneventful stabilization with open reduction and internal fixation using a cephalomedullary nail.

Case Presentation

A 75-year- old woman with history of type I diabetes mellitus (DM) presented to the emergency department with localized painful swelling of the proximal right thigh. She reported recent, 3 weeks, history of orthopaedic procedure secondary to full down subtrochanteric femur fracture with displaced lesser trochanteric fragment (►**Figs. 1** and **2**) and uneventful stabilization with open reduction and internal fixation using a cephalomedullary nail (►**Fig. 3**). The procedure was complicated by a massive bleeding.

The patient was clinically stable on examination. Her mental status, blood pressure, pulse rate, respiratory rate, and temperature were all normal.

Local clinical examination revealed a diffuse right leg swelling up to the thigh region. However, peripheral pulse could not be felt on both lower extremities with no signs of acute ischemia. Laboratory investigations showed low hemoglobin (7 mg/dL) with high creatinine (2 mg/dL) and blood urea (80 mg/dL) levels; her biochemical parameters were otherwise normal.

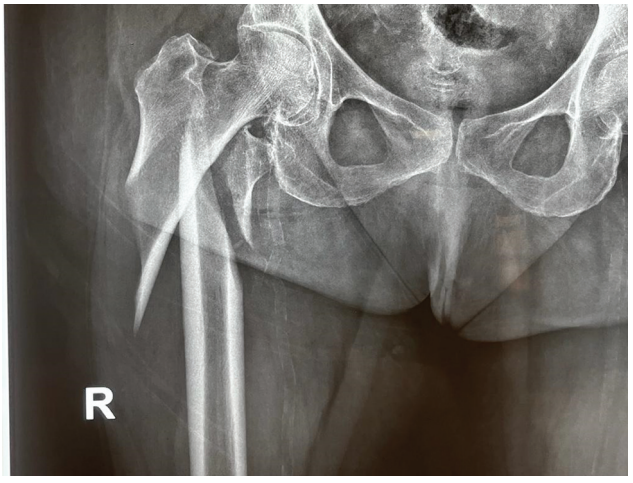

Fig. 1 Preoperative X-ray show subtrochanteric femur fracture with displaced sharp fragment of the lesser trochanter.

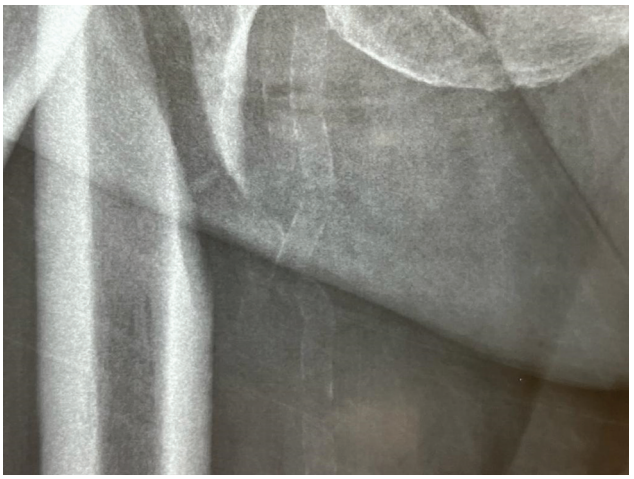

Fig. 2 Preoperative X-ray showing calcified femoral artery with disruption in continuity by sharp fragment of the lesser trochanter before fixation.

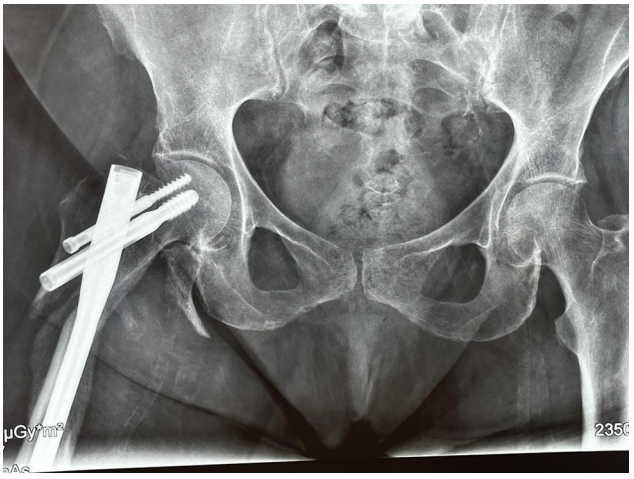

Fig. 3 X-ray showing a cephalomedullary nail fixation of the proximal femur fracture with sharp bone fragment still there.

A series of X-rays of both lower limbs along with duplex ultrasound showed a false aneurysm of the right SFA, 3 to 4 cm, with the presence of large hematoma and popliteal deep vein thrombosis (DVT).

Because of relatively high renal parameters and an associated risk of contrast-induced nephropathy, we thoroughly discussed the case with the nephrologist in charge regarding having a computed tomography (CT) angiography of the patient. The patient and her family finally refused the CT scan, not to take the possible risk.

Since our patient was vitally stable, with no signs of acute ischemia in the affected limb, and without presence of any pulsatile mass in the groin region, we decided to start heparin to treat the DVT, our potential primary diagnosis,

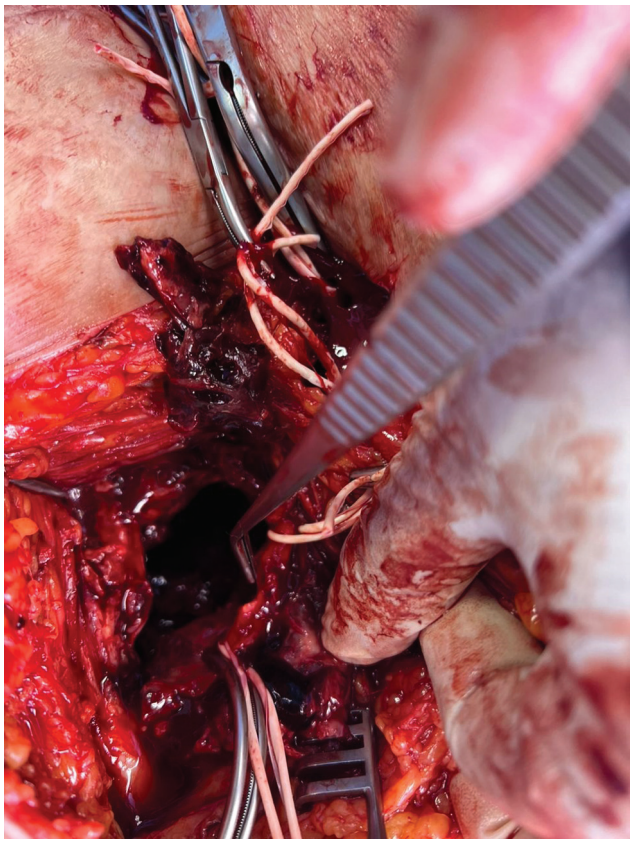

Fig. 4 Injured site of superficial femoral artery laceration indicated by the tip of the forceps.

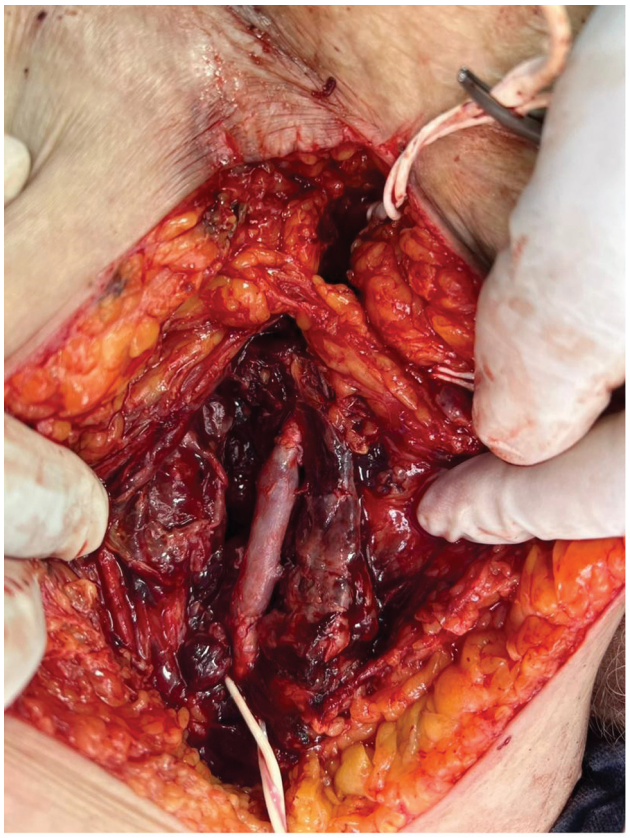

Fig. 5 Repair by reversed long saphenous vein.

along with blood transfusion to correct the hemoglobin level; a total of 2 units was transfused.

A week later, we repeated the duplex ultrasound twice with a different radiologist who confirmed that no DVT was detected. However, the reported size of the false aneurysm of the SFA had increased to 7 cm and the patient s' hemoglobin level dropped again to 7 mg/dL.

At this point, we took the decision for vascular surgical intervention.

Intraoperatively (►**Figs. 4–6**) the common femoral artery, SFA and the profunda femoral artery (PFA) were explored. A longitudinal laceration, approximately 5 mm in length, was identified in the posterolateral aspect of the SFA. A spike of bone from the lesser trochanter was directly posterior to the SFA lesion. A thin fragment of bone measuring approximately 3×4 cm was removed. A repair was then completed with reversed long saphenous vein graft from the contralateral limb. Finally, the wound was closed around a suction drain.

The patient was discharged 2 days later with no complications.

At a follow-up visit, 3 months later, the patient was seen in a completely good condition, with no swelling in the affected limb, and ambulatory with the help of a walker.

Fig. 6 X-ray after vascular repair and excision of bone fragment. The sharp bone fragment was excised after 2 weeks of fixation.

Discussion

Although it is rare, a vascular injury complication associated with subtrochanteric femoral fracture can be life-threatening or might even cause limb dysfunction over the time.[1]

False aneurysm of the femoral artery in a 72-year-old man due to a dislocated bone fragment was first described by Abraham et al in 1975.[4] Subsequently more cases of groin vascular injuries due to hip fracture treatment or displaced spiked lesser trochanter fracture have been reported.[2,5] In approximately 80% of the cases, the deep femoral artery was affected.[2,5] Only few cases, however, involved the superficial femoral vessels (~10.84%), while other arteries of the thigh were injured in even fewer incidents.[2,5]

Fracture of the proximal femur is common among elderly patients; the incidence increases with age and level of osteoporosis.[6] Typically, it is manifested with localized

pain (68%) and swelling (92%) over the affected area.[1] Additionally, the occurrence of atherosclerosis also increases with advanced age, resulting in fragile vessels and injury prone.[7]

Our patient contracted a laceration in a calcified right SFA as a complication of a subtrochanteric femur fracture, a less commonly involved vessel in such an injury. The patient presented with extensive swelling in the right lower limb with severe localized pain and low hemoglobin level.

Vascular injury could be compression with blood flow restriction, intimal flap injury with decreased distal flow, intimal or atherosclerotic plaque rupture resulting in arterial thrombosis or thromboembolism, or acute hemorrhage by laceration or transection, which produces a pseudoaneurysm or arteriovenous fistula.[3]

Vascular lesions may be caused by fracture fragments, predominantly the diverted lesser trochanter.[2] Barquet et al demonstrated seven noniatrogenic lesions produced by lesser trochanter or other bone fragments, both in patients undergoing conservative treatment and in patients who underwent a surgical fixation.[3] Some authors, therefore, recommend perioperative monitoring of the minor trochanter with medial or proximal deviation, which may require fragment reduction, fixation, or removal.

Our patient developed a late-onset complication of femoral artery lesion with pseudoaneurysm formation due to a dislocated lesser trochanter.

False aneurysm is preferably diagnosed by arterial duplex or CT angiogram, which is less invasive than conventional angiography; plain X-ray, however, is only helpful if the vessels are calcified.[8]

Therapeutic modalities vary in the literature from endovascular repair, thrombin injection guided by ultrasound or venous patch and graft.

In our case, the bony spike of the displaced lesser trochanter was removed and pseudoaneurysm was excised and repaired with a saphenous venous graft.

Conclusion

Surgeons should pay attention to any displaced bone fragments close to calcified vessels, especially in the evaluation of routine X-rays, as it represents a routine image following fracture.

This could minimize the potential life-threatening risk of delayed diagnosis. Duplex scan is recommended 2 weeks after long bone fracture to exclude false aneurysm.

Funding
None.

Conflict of Interest
None declared.

Acknowledgments
We wish to extend our special appreciation and sincere thanks to Dr. Giuma Alzewei, member of the Libyan Vascular Surgery Board (LVSB) committee, for his support, cooperation, and assistance in reporting this case.

In addition, we are deeply grateful for the help provided by people who played a role in this case presentation.

References

1 Fruhwirth J, Koch G, Mischinger HJ, Werkgartner G, Tesch NP. Vascular complications in minimally invasive surgery. Surg Laparosc Endosc 1997;7(03):251–254
2 Barquet A, Gelink A, Giannoudis PV. Proximal femoral fractures and vascular injuries in adults: incidence, aetiology and outcomes. Injury 2015;46(12):2297–2313
3 Labronici PJ, Santos FC, Diamantino YL, Loureiro E, Ezequiel MC, Alves SD. Fratura proximal do fêmur e lesão vascular em adultos-Relato de caso. Rev Bras Ortop 2019;54:343–346
4 Abraham E, Pankovich AM, Jansey F. False aneurysm of the profunda femoris artery resulting from intertrochanteric fracture. A case report. J Bone Joint Surg Am 1975;57(06):871
5 Whitehill R, Wang GJ, Edwards JR, Stamp WG. Late injuries to femoral vessels after fracture of the hip. Case report. J Bone Joint Surg Am 1978;60(04):541–542
6 Newman ED, Ayoub WT, Starkey RH, Diehl JM, Wood GC. Osteoporosis disease management in a rural health care population: hip fracture reduction and reduced costs in postmenopausal women after 5 years. Osteoporos Int 2003;14(02):146–151
7 Benetos A, Waeber B, Izzo J, et al. Influence of age, risk factors, and cardiovascular and renal disease on arterial stiffness: clinical applications. Am J Hypertens 2002;15(12):1101–1108
8 Wixon CL, Philpott JM, Bogey WM Jr, Powell CS. Duplex-directed thrombin injection as a method to treat femoral artery pseudoaneurysms. J Am Coll Surg 1998;187(04):464–466