

# Pulmonary Embolism: An Update Based on the Revised AWMF-S2k Guideline

Christian F. Opitz<sup>1</sup> F. Joachim Meyer<sup>2</sup>

<sup>1</sup> DRK Kliniken Berlin Westend, Spandauer Damm 130, Berlin, Germany

<sup>2</sup> Lungenzentrum München (Bogenhausen-Harlaching), München Klinik gGmbH, Sanatoriumsplatz 2, München, Germany

**Address for correspondence** Christian F. Opitz, PD, DRK Kliniken Berlin Westend, Spandauer Damm 130, 14050 Berlin, Germany (e-mail: c.opitz@drk-kliniken-berlin.de).

Hamostaseologie 2024;44:111–118.

## Abstract

Pulmonary embolism (PE) is the third most common acute cardiovascular disease. The risk of PE increases with age and mortality is high. Patients are stratified into hemodynamically stable versus unstable patients, as this has important implications for diagnosis and therapy. Since clinical signs and symptoms of acute PE are nonspecific, the clinical likelihood of PE is estimated to guide diagnostic pathways. D-dimer testing is performed in hemodynamically stable patients with low or intermediate probability of PE and the visualization of thromboembolism and its sequelae is commonly achieved with computed tomography pulmonary angiography (CTPA), supplemented by ultrasound techniques. With confirmed PE, another risk stratification estimates disease severity and defines intensity and setting of the ensuing treatment. The therapeutic spectrum ranges from outpatient treatment with initial oral anti-coagulation to thrombolytic or interventional treatment in the intensive care unit or catheterization laboratory. In single cases, even acute surgical thrombectomy is attempted.

## Keywords

- ▶ thrombolysis/  
thrombolytic agents
- ▶ anticoagulation
- ▶ thrombectomy

## Definition and Clinical Problems

Pulmonary embolism (PE) is a sudden, mostly partial obstruction of the pulmonary arterial vasculature, usually by embolization of a lower extremity or pelvic thrombus. Thus, PE is a potentially serious complication in the acute phase of venous thrombosis.

PE is the third most common acute cardiovascular disease (incidence: 39–115/100,000 persons per year) after myocardial infarction and stroke. The risk of PE increases with age,<sup>1,2</sup> and mortality is high (9.4–32.2/100,000 persons/y).<sup>2</sup> One-third of the nonsurvivors die within hours of diagnosis, depending on the extent of PE, presence and severity of right ventricular (RV) dysfunction, and concomitant cardiopulmonary disease.<sup>3,4</sup>

Numerous risk factors can increase the risk of PE, as well as thrombosis.

Obstruction of the pulmonary arteries disrupts both blood circulation and gas exchange in the lungs. Depending on the extent of PE, there is an increase in RV afterload, dilatation of the RV, tricuspid regurgitation, and increased wall stress in the right heart. The resulting right heart failure due to acute pressure overload (cor pulmonale) is the main cause of death in severe PE.

It is useful to stratify patients with PE primarily into hemodynamically stable versus unstable patients, as this has important implications for diagnosis and therapy.<sup>5</sup>

Patients with hemodynamic instability have a high mortality within the first hours and days. Therefore, a rapid diagnostic workup and initiation of therapy are mandatory to reduce the risk of an unfavorable outcome.

received

September 17, 2023

accepted after revision

December 14, 2023

© 2024, Thieme. All rights reserved.  
Georg Thieme Verlag KG,  
Rüdigerstraße 14,  
70469 Stuttgart, Germany

DOI <https://doi.org/10.1055/s-0044-1779011>.  
ISSN 0720-9355.

## Diagnosis of Pulmonary Embolism

### Clinical Symptoms and Pretest Probability

The clinical signs and symptoms of acute PE are nonspecific (dyspnea with sudden onset, chest pain, syncope or presyncope, etc.). The spectrum of clinical presentation ranges from asymptomatic patients to hemodynamic instability and shock.<sup>6</sup>

The clinical examination of the lungs is typically unremarkable.

If symptoms or signs suggestive of PE are present, information on history, predisposing factors, and clinical findings can be used to determine the likelihood of PE being present. In hemodynamically stable patients with suspected PE, this pretest probability determines the further diagnostic work-up and can prevent unnecessary and potentially dangerous procedures.

Clinical risk scores, such as the simplified Wells score<sup>7</sup> or the revised Geneva score,<sup>8,9</sup> help distinguish between “high” (~30%) and “low” (~12%) risk of the presence of PE.

### Laboratory Tests: D-Dimer Testing for Suspected PE

In hemodynamically stable patients with low or intermediate probability of PE, the negative predictive value of age-adjusted D-dimer findings is above 95% (for quantitative enzyme-linked immunoassays [ELISA] and enzyme-linked fluorescent assays [ELFA]).<sup>10</sup> Consequently, the unnecessary use of diagnostic imaging procedures (computed tomography pulmonary angiography [CTPA], scintigraphy, sonography) can be avoided in this patient group.

In contrast, for patients with a high clinical probability, D-dimer testing should be omitted, as the negative predictive value is not sufficient in this situation; imaging is required in these cases.<sup>11</sup>

### Imaging in Suspected Pulmonary Embolism

#### Computed Tomography Pulmonary Angiography

CTPA is almost universally available and rapidly confirms or excludes PE (sensitivity 94%, specificity 98%) or provides clues to a relevant differential diagnosis.<sup>12</sup>

In addition to PE detection, CTPA provides prognostically relevant information for estimating the hemodynamic burden of acute PE, for example, by determining the diameters of the RV and left ventricle (LV). An RV/LV ratio greater than 1.0 in transverse slices or greater than 0.9 in four-chamber reconstructions indicates RV strain and is associated with increased early mortality.<sup>13</sup>

If CTPA is not available or contraindicated, combined ventilation/perfusion (V/Q) scintigraphy of the lung (preferably using single-photon emission computed tomography [SPECT]) can be used as an alternative in hemodynamically stable patients.

Only with appropriate expertise can magnetic resonance (MR) angiography and MR perfusion be used as alternatives in individual cases (e.g., in pregnancy).

Catheter-based pulmonary angiography (usually as digital subtraction angiography [DSA]) in acute PE is only used in

the context of planned revascularization by endovascular or surgical procedures (e.g., catheter-based thrombolysis, thrombectomy) in selected situations.

### Echocardiography

#### Role of Echocardiography in the Diagnosis of Acute Pulmonary Embolism

In addition to the rare direct evidence of thromboembolism, such as visualization of thrombi in the right heart or the central portions of the pulmonary arteries, echocardiography describes indirect signs of right heart strain that can suggest the diagnosis of PE or help assess the risk in cases of proven PE.<sup>14</sup>

The RV wall is thin and distensible, so RV dilatation can occur rapidly as a result of acute afterload increase, along with impaired systolic function. Chronic RV afterload increases (as in chronic lung disease, pulmonary hypertension, or chronic thromboembolic changes) are more likely to result in complex remodeling with hypertrophy. Thus, echocardiography can help distinguish acute from chronic changes.

In the acute setting of hemodynamically unstable patients with suspected PE, point-of-care ultrasound (POCUS) is an important decision aid.<sup>15,16</sup> Thus, signs of acute RV strain in hemodynamically unstable patients may justify thrombolytic therapy even in the absence of CTPA when plausible differential diagnoses are less likely. In the absence of RV strain, high-risk PE becomes very unlikely and other diagnoses should be evaluated.

In hemodynamically stable patients with PE, exclusion or detection of right heart strain is a part of the risk stratification guiding further treatment (“intermediate care,” normal ward, outpatient treatment). In addition, echocardiography can help detect signs of preexisting chronic cor pulmonale and point to important coexisting diagnoses. Therefore, echocardiography should be a routine procedure even in stable PE patients, although it is not mandatory according to current guidelines.<sup>11</sup>

#### Echo Parameters

The most important echocardiographic parameters in patients with proven or suspected PE describe the size, morphology, and function of the RV (also in relation to the LV), alterations of the heart valves, and the estimated pressure level in the pulmonary circulation.

The size of the RV and its relation to the left ventricle (RV/LV: normal 0.67:1, pathological > 1:1) is particularly important and can be determined quickly. Other parameters, such as the tricuspid annular plane systolic excursion (TAPSE), describe the systolic function of the RV. Prognostically most important are an RV/LV ratio greater than 1 and a TAPSE less than 17 mm.<sup>17,18</sup>

The clinically important distinction of acute from chronic changes cannot reliably be done by the estimated pulmonary artery systolic pressure alone; however, an estimated systolic pulmonary artery pressure (PAP) greater than 60 mm Hg, especially in the presence of RV hypertrophy (>5 mm), is

suggestive of preexisting changes, as is the dilatation of the main pulmonary artery (>25 mm).

In addition to echocardiography, lung ultrasound (LUS) is gaining in importance and can also be used to detect PE.<sup>19,20</sup> The leading sonographic criterion is the visualization of at least two triangular or round lesions (echo-poor, homogeneous, without vascularization in color mode) located subpleural in the lung parenchyma, usually dorso-basal and with an average size of about 15 mm. However, LUS alone cannot reliably exclude PE (sensitivity 82%, specificity 89%).<sup>20</sup> Nevertheless, when LUS is combined with sonography of the leg veins and echocardiography (so-called triple sonography), a sensitivity of 90% and a specificity of 86% can be achieved for the detection of thromboembolic disease.<sup>21</sup> This combination of ultrasound examinations may be advantageous to avoid radiation and contrast agent exposure in particularly vulnerable patient groups (e.g., pregnant women, children, renal failure) and may be considered an alternative when CTPA is contraindicated. However, no patient with suspected PE should be left without further imaging (CTPA, scintigraphy) based solely on a negative sonographic finding.

In patients with symptomatic PE, venous thrombosis can be detected in 30 to 70%.<sup>11</sup> Therefore, it is reasonable to use venous duplex ultrasonography (VDUS) of the lower limbs (and shoulder–arm veins if necessary) to add diagnostic information in suspected PE. In such patients (high clinical probability of PE and/or positive D-dimer test), the detection of DVT increases the likelihood of suspected PE and justifies therapeutic anticoagulation. This is especially helpful if radiological confirmation of the diagnosis by CTPA or V/Q scintigraphy is not possible. VDUS can also be used easily (with the appropriate expertise) as part of a triple POCUS together with echocardiography and LUS.

Even if PE is already confirmed, sonographic diagnosis is essential for localizing and quantifying the source of the embolism because this can guide the type and duration of therapy. Moreover, information about the full extent of venous thromboembolism (VTE) is important for follow-up monitoring, especially in the case of recurrent VTE.

## Diagnostic Strategy

Testing for PE is performed with increasing frequency in recent years. However, this diagnosis is confirmed only in a small proportion of patients tested (about 15–25%).<sup>22</sup> The low sensitivity and specificity of the clinical signs of PE and the low predictive value of elevated D-dimers encourage rapid imaging, especially CTPA. Despite ever-improving technology, radiological procedures are still associated with radiation and contrast agent exposure. Therefore, “overdiagnosis” must be avoided. For these reasons, algorithms have been developed to standardize the diagnostic steps and minimize the use of unnecessary and burdensome diagnostic procedures. The diagnostic workup of suspected PE is mainly determined by the hemodynamic situation of the patient and the assessment of the clinical or pretest probability for the presence of PE.

**Initial diagnostic procedures** in suspected PE include the assessment of vital signs, chest X-ray, electrocardiogram (ECG), and arterial or capillary blood gas analysis. The X-ray often shows nonspecific changes but can help establish or exclude differential diagnoses. The ECG may show signs of right heart strain (e.g., negative T-waves in V1–V4, Qr in V1, S1–QIII–TIII pattern, right bundle branch block), sinus tachycardia, or atrial fibrillation, but a normal ECG does not rule out PE. Similarly, blood gas analysis may show hypoxemia, hyperventilation, or an increased alveolar–arterial gradient, but is often unremarkable. Recent data emphasize the prognostic significance of heart rate in nonhypotensive patients.<sup>23</sup>

The diagnostic and therapeutic approach to suspected PE depends on the hemodynamic situation. Hemodynamically unstable patients are defined as those with respiratory or circulatory arrest (resuscitation), shock, or sustained hypotension (systolic arterial pressure <90 mm Hg for >15 minutes without other cause).<sup>1</sup>

**Hemodynamically unstable patients** are monitored, and rapid reperfusion of the pulmonary vasculature is the priority and determines prognosis. Any delay for complex diagnostics and transport must be avoided. If CTPA cannot be performed immediately, bedside ultrasound can guide therapeutic decisions. Echocardiography can detect or exclude right heart strain and, in combination with venous and LUS (“triple POCUS”), thromboembolism can be detected.

In **hemodynamically stable patients**, diagnostic accuracy is most important. Accordingly, diagnostic algorithms have been established to reliably identify the minority of patients with PE among the group of suspected cases and reduce the number of unnecessary diagnostic procedures.

The first diagnostic step determines the clinical probability, either empirically or using established scores. The most commonly used scores (Wells score, revised Geneva score) can be applied with a simplified, two-level assessment.<sup>8,9</sup>

With low and intermediate clinical probability, D-dimers within the normal range exclude acute PE with high certainty, and imaging can be omitted.

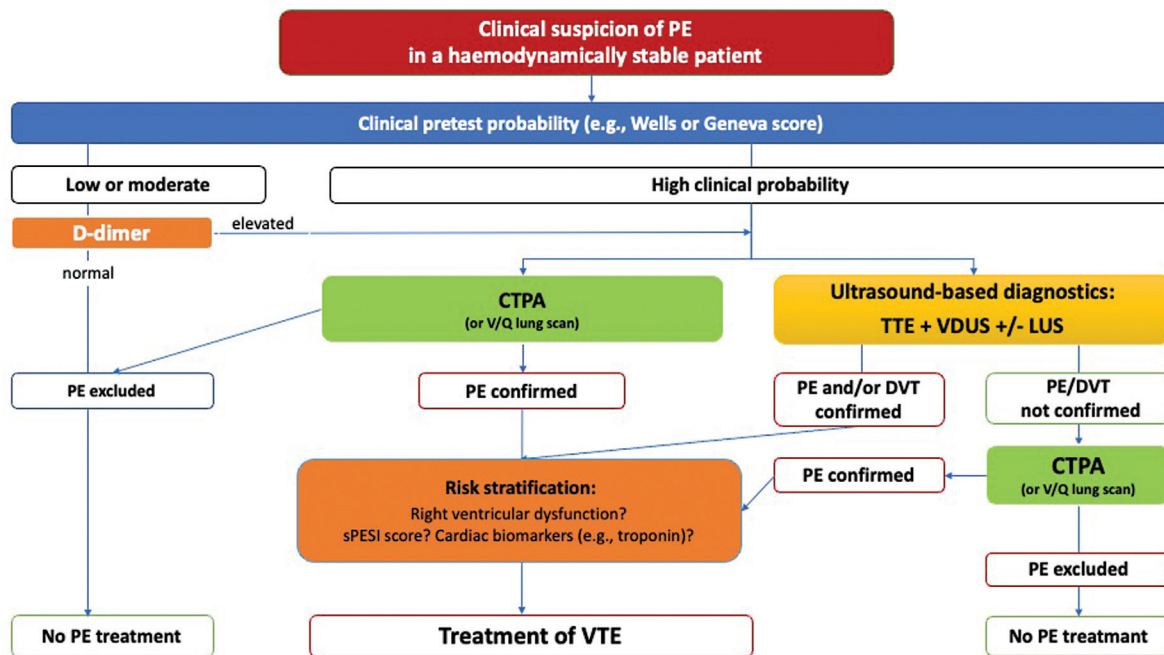
If the clinical probability of PE is high, D-dimer assessment is not useful because the negative predictive value is too low. These patients need imaging of the pulmonary vasculature to reliably diagnose or exclude PE. This is usually achieved by CTPA as the primary imaging modality. However, this does not exclude the validity of other imaging techniques (see above). With appropriate expertise, a meaningful sonography of the lungs and leg veins, combined with an echocardiography (“triple POCUS”), is also suitable for identifying patients with VTE and initiating therapy. However, if ultrasound findings are unremarkable and PE is suspected, radiological imaging (CTPA or V/Q scintigraphy) should be performed.

The diagnostic algorithm for hemodynamically stable patients with suspected PE is shown in **Fig. 1**.

## Therapy of Acute Pulmonary Embolism

### Risk Stratification

While patients with PE and cardiogenic shock or persistent hypotension are monitored and treated immediately,



**Fig. 1** Diagnostic algorithm in hemodynamically stable patients with acute pulmonary embolism (modified from [24]).

Abbr.: CTPA = computed tomography pulmonary angiography; DVT = deep vein thrombosis; PE = pulmonary embolism; PTP = pre-test probability; sPESI = simplified pulmonary embolism severity index; VDUS = venous duplex ultrasonography; V/Q = ventilation-perfusion.

hemodynamically stable patients with confirmed PE undergo risk stratification in order to adapt their therapy to the clinical and hemodynamic severity of the disease.<sup>11</sup>

Risk stratification starts with a validated prognostic score, such as the simplified Pulmonary Embolism Severity Index (sPESI).<sup>25</sup> The sPESI considers and integrates demographic factors (age), comorbidities (previous cardiac and pulmonary diseases, malignancy) and clinical findings at diagnosis (blood pressure, heart rate, arterial oxygen saturation). About one-third of all patients with acute PE have an sPESI score of 0. With adequate anticoagulation, these patients are at low risk of an adverse outcome in the acute phase (30-day mortality 1.0%; 95% confidence interval [CI]: 0.0–2.1%). In contrast, patients with an sPESI score of  $\geq 1$  have a 30-day mortality of 10.9% (95% CI: 8.5–13.2%) and thus an intermediate clinical risk.<sup>26</sup>

Further therapy is based on this risk stratification. The spectrum ranges from rapid reperfusion therapy to anticoagulation alone and potential outpatient treatment.

When using the sPESI score, it should be noted that RV function is not considered. Thus, despite an sPESI score of 0, patients may be at increased risk if signs of RV strain are present, either on echocardiography or CTPA (odds ratio [OR]: 4.2) or if troponin is elevated (OR: 6.2). Therefore, these additional parameters of RV dysfunction should be included in risk stratification.<sup>27</sup>

Echocardiographic signs of RV strain have already been described.

Among laboratory values, an elevated troponin is associated with increased mortality, even in initially hemodynamically stable patients (OR: 5.9). Similarly, normal levels of

N-terminal pro-B-natriuretic peptide (NT-proBNP; age adjusted) predict a more stable clinical course, despite a poor positive predictive value.<sup>28</sup>

Depending on the presence of RV strain and/or elevated cardiac biomarkers, patients at intermediate risk are further stratified into those at intermediate-high (both) and intermediate-low (none or one of them) clinical risk (**Table 1**). In patient at intermediate-high risk, mortality and risk of clinical deterioration within the first few days are significantly increased compared with those at intermediate-low risk.<sup>29</sup>

## Risk-Adapted Therapeutic Strategy

### Treatment of High-Risk Pulmonary Embolism

For hemodynamically unstable patients (mortality >20%), urgent reperfusion is the goal, usually attempted by systemic thrombolysis. Depending on the clinical situation and the presence of contraindications to systemic thrombolysis, endovascular reperfusion procedures or surgical embolectomy are considered.<sup>30</sup> In these patients, initial anticoagulation is preferably established with unfractionated heparin (UFH). Following hemodynamic stabilization, they can be switched to oral anticoagulation.<sup>11</sup>

With the aim of improving the acute treatment of hemodynamically compromised PE patients, multidisciplinary PE teams (“pulmonary embolism response teams” [PERT]) are increasingly being established in Europe and North America. Local treatment protocols, considering the capacity and resources available in each hospital, guide the selection of the most appropriate therapy.<sup>31</sup>

**Table 1** Risk stratification and early mortality in patients with acute pulmonary embolism (modified from <sup>24</sup>).

Early mortality risk (30 d)		Risk indicators				Proportion of patients <sup>a</sup>
		Shock or hypotension	sPESI $\geq 1$	RV dysfunction on TTE or CTPA	Elevated cardiac biomarkers	
High (>20%)		+	+	+	+	12%
Intermediate	Intermediate high	–	+	RV dysfunction and elevated biomarkers		30%
	Intermediate low	–	+	RV function and biomarkers normal or one of them abnormal		37%
Low (<1%)		–	–	–	–	22%

Abbreviation: NT-proBNP, N-terminal pro-B-natriuretic peptide; sPESI, simplified Pulmonary Embolism Severity Score; RV, right ventricular; TTE, transthoracic echocardiography.

Source: Modified from Linnemann et al.<sup>24</sup>

<sup>a</sup>From Becattini et al.<sup>28</sup>

### Treatment of Intermediate-Risk Pulmonary Embolism

Patients with intermediate-risk PE are treated as inpatients. Those with intermediate-high risk or increased likelihood of hemodynamic deterioration should initially be treated in an intermediate care or intensive care unit with therapeutic anticoagulation and monitoring (usually for 24–36 hours) to detect clinical deterioration and the need for escalation of therapy. In such a case, thrombolysis or interventional therapy is considered. For these patients, it may be beneficial to start anticoagulation with heparin for the first 2 to 3 days, a period when most deteriorations occur.<sup>11</sup>

Patients with intermediate-low risk PE should receive therapeutic anticoagulation (low-molecular-weight heparin or oral anticoagulation) and can usually be treated in a normal ward.

### Treatment of Low-Risk Pulmonary Embolism

Patients with a low risk of mortality (<1%) can be treated primarily as outpatients or as inpatients without monitoring. Anticoagulation in these patients can be initiated with a low-molecular-weight heparin or oral anticoagulation.

### Special Patient Groups

For certain patient groups, such as pregnant women or patients with cancer, special considerations apply as outlined in current guidelines.<sup>11,24,32</sup>

With the improvement of diagnostic methods such as CTPA, smaller emboli in the subsegmental arteries are increasingly being diagnosed. In the case of single subsegmental PE, the possibility of a false-positive finding should be considered, especially in the absence of corresponding clinical symptoms. In these cases, the detection of a related venous thrombosis can be helpful when deciding upon anticoagulation. Supplementary diagnostics (additional imaging, D-dimers if necessary) should be considered.

The risk of severe PE with proven thrombus in the right atrium (thromboembolic origin or catheter-associated) is 4 to 18% and mortality up to 21%.<sup>33,34</sup> In the case of a catheter-associated thrombus, removal of the catheter after initiation of therapeutic anticoagulation and continuation of anticoagulation for at least 3 months are indicated. In large

thrombi, surgical embolectomy may be considered in the absence of resolution with anticoagulation.

In patients with floating thrombi in the right heart cavities that are not catheter associated, thrombolytic treatment is an alternative to surgical embolectomy. Endovascular mechanical thrombectomy appears possible in individual cases when surgery or systemic lysis therapy is not possible.<sup>33</sup>

In view of the lack of controlled comparative studies, it remains a case-by-case decision which treatment procedure is used.

### Anticoagulant Therapy for Pulmonary Embolism

In general, the same recommendations for initial anticoagulation, maintenance therapy, and prolonged secondary prophylaxis apply to hemodynamically stable PE patients as for those with deep vein thrombosis.<sup>24,26</sup> However, important differences exist, as about 80% of recurrent VTE events after a first spontaneous PE also manifest as PE and therefore carry a higher risk.<sup>35,36</sup>

For initial therapy, either parenteral anticoagulation (preferably low-molecular-weight heparin) or oral therapy with apixaban or rivaroxaban (apixaban  $2 \times 10$  mg/d for 7 days or rivaroxaban  $2 \times 15$  mg/d for 21 days) can be considered. For maintenance therapy with dabigatran, edoxaban, phenprocoumon, or warfarin, a parenteral anticoagulant should be used initially for at least 5 days. Low-molecular-weight heparin and fondaparinux are considered to be as effective and safe as UFH, although low-molecular-weight heparin and fondaparinux are preferred in hemodynamically stable patients.

For maintenance therapy and secondary prophylaxis, the same decision criteria and dosage recommendations apply as for patients with deep vein thrombosis.

### Systemic Thrombolysis

Systemic thrombolysis can rapidly reduce thrombus burden and unload the RV.<sup>37</sup> Therapeutic success is greatest within 48 hours of symptom onset, but thrombolysis may still be beneficial after 6 to 14 days.

However, thrombolysis increases the risk of major bleeding (9.4%; OR: 2.84; 95% CI: 1.92–4.20) and especially intracranial bleeding (2%; OR: 7.59; 95% CI: 1.38–41.7).<sup>38</sup>

Against this background, thrombolysis is clearly indicated only in high-risk PE patients, as the risk of PE-related death or life-threatening complications is significantly increased in the first hours or days after diagnosis. The question of whether PE patients with an intermediate-high risk should also be given systemic thrombolysis has been controversial for years. The results of the randomized controlled Pulmonary Embolism International Thrombolysis (PEITHO) study, which included 1,005 intermediate-risk PE patients, indicate that intermediate-risk patients should not be given primary thrombolysis, but should be monitored as inpatients and receive thrombolytic therapy if hemodynamic deterioration occurs.<sup>2</sup>

Streptokinase, urokinase, and recombinant tissue plasminogen activator (rt-PA) are available in Germany for systemic thrombolysis in acute PE; absolute and relative contraindications must be considered. Whether systemic thrombolysis in reduced doses offers advantages is currently being investigated in a large multicenter study (PEITHO-3).<sup>39</sup>

### Endovascular and Surgical Reperfusion Procedures

Endovascular and surgical reperfusion procedures are therapeutic options for PE patients in whom systemic thrombolysis is not feasible or has not been successful.

The advantage of endovascular procedures is the possibility of catheter-guided application of a thrombolytic agent directly into the pulmonary vasculature. Only about 10 to 20% of the systemic dose is used, which translates into a lower risk of bleeding.<sup>40</sup> In addition, endovascular catheter techniques and open surgical procedures are available to remove thrombi directly from the pulmonary arteries, which may result in faster circulatory stabilization in the acute phase of PE. However, randomized controlled trials demonstrating mortality reduction with endovascular or surgical techniques in this patient population are still lacking. Currently, there is an increase in the number of treatment trials that include high- and/or intermediate-risk patients.<sup>30</sup>

### Catheter-Based Local Thrombolysis

Catheter-directed thrombolysis was developed to achieve an effect comparable to that of systemic thrombolysis but with a lower total dose of a fibrinolytic agent applied locally, and therefore a reduced risk of bleeding. Randomized comparative studies of systemic and local thrombolysis in high- or intermediate-risk PE patients are not yet available.

### Endovascular Thrombus Fragmentation and Thrombectomy Procedures

Endovascular mechanical procedures for thrombus fragmentation or thrombus removal use rotational, aspiration, hydrodynamic, or suction thrombectomy.<sup>41,42</sup> The aim is to improve RV function by reducing the size of the thrombus and the thrombus load. In some cases, mechanical thrombectomy is also used in combination with thrombolysis, in which case thrombolytics are usually administered in low doses, sometimes ultrasound assisted.

Again, there is a lack of randomized controlled trials comparing mechanical procedures with standard drug therapy

in high- or intermediate-high-risk PE patients. Numerous small retrospective case series, prospective registry studies, and single-arm studies have been published highlighting potential advantages of these mechanical procedures.

Until randomized data are available, recently published statements of the professional societies might guide the clinical strategy in this group of patients.<sup>30,41,42</sup>

### Surgical Thrombectomy or Embolectomy

Surgical pulmonary embolectomy is a treatment option for severely compromised patients with mainly centrally localized thrombi in whom other therapeutic options failed or are not available. The operation is usually performed via sternotomy on the heart-lung machine without the use of cardioplegic arrest.<sup>43</sup>

Recent work has reported good acute and long-term outcomes with surgical embolectomy, when compared with drug or interventional therapy, with similar 30-day mortality but fewer bleeding complications and recurrences.<sup>43</sup> However, these were retrospective studies and therefore selection bias cannot be excluded.

Furthermore, the use of extracorporeal membrane oxygenation (ECMO) can be used for hemodynamic support of circulatory function in cases of extensive embolization. In these cases, ECMO can be used as a bridge to surgical embolectomy, and possibly also for postoperative follow-up.<sup>43,44</sup>

## Conclusion

PE continues to be a frequent and still challenging disease. Appropriate suspicion and a careful diagnostic workup remain the cornerstones of successful patient identification. The diagnostic as well as the therapeutic approach must be guided by careful and evidence-based risk assessment. While timely anticoagulation (and thrombolysis in hemodynamically unstable patients) is still the basis of PE treatment, new therapeutic options are rapidly evolving and being tested in clinical trials. These new options range from reduced thrombolytic regimens, some combined with ultrasound application, to the direct aspiration and/or fragmentation of clot in the pulmonary vasculature by interventional techniques in the catheterization laboratory. If these new options improve the outcome of patients with acute PE, major changes in our current treatment algorithms can be expected.

### Funding

None.

### Conflict of Interest

FJM has received honoraria for lectures from Jansen-Cilag, Boehringer and Novartis. CO has no conflict of interest.

## References

- 1 Wendelboe AM, Raskob GE. Global burden of thrombosis: epidemiologic aspects. *Circ Res* 2016;118(09):1340–1347
- 2 Barco S, Valerio L, Ageno W, et al. Age-sex specific pulmonary embolism-related mortality in the USA and Canada, 2000–18:

- an analysis of the WHO Mortality Database and of the CDC Multiple Cause of Death database. *Lancet Respir Med* 2021;9(01):33–42
- 3 Cohen AT, Agnelli G, Anderson FA, et al; VTE Impact Assessment Group in Europe (VITAE) Venous thromboembolism (VTE) in Europe. The number of VTE events and associated morbidity and mortality. *Thromb Haemost* 2007;98(04):756–764
  - 4 Keller K, Hobohm L, Ebner M, et al. Trends in thrombolytic treatment and outcomes of acute pulmonary embolism in Germany. *Eur Heart J* 2020;41(04):522–529
  - 5 Hobohm L, Keller K, Konstantinides S. Pulmonary embolism. *Inn Med (Heidelb)* 2023;64(01):40–49
  - 6 Pollack CV, Schreiber D, Goldhaber SZ, et al. Clinical characteristics, management, and outcomes of patients diagnosed with acute pulmonary embolism in the emergency department: initial report of EMPEROR (Multicenter Emergency Medicine Pulmonary Embolism in the Real World Registry). *J Am Coll Cardiol* 2011;57(06):700–706
  - 7 Wells PS, Ginsberg JS, Anderson DR, et al. Use of a clinical model for safe management of patients with suspected pulmonary embolism. *Ann Intern Med* 1998;129(12):997–1005
  - 8 Le Gal G, Righini M, Roy PM, et al. Prediction of pulmonary embolism in the emergency department: the revised Geneva score. *Ann Intern Med* 2006;144(03):165–171
  - 9 Klok FA, Mos IC, Nijkeuter M, et al. Simplification of the revised Geneva score for assessing clinical probability of pulmonary embolism. *Arch Intern Med* 2008;168(19):2131–2136
  - 10 Weitz JI, Fredenburgh JC, Eikelboom JW. A test in context: D-dimer. *J Am Coll Cardiol* 2017;70(19):2411–2420
  - 11 Konstantinides SV, Meyer G, Becattini C, et al; ESC Scientific Document Group. 2019 ESC Guidelines for the diagnosis and management of acute pulmonary embolism developed in collaboration with the European Respiratory Society (ERS). *Eur Heart J* 2020;41(04):543–603
  - 12 Patel P, Patel P, Bhatt M, et al. Systematic review and meta-analysis of test accuracy for the diagnosis of suspected pulmonary embolism. *Blood Adv* 2020;4(18):4296–4311
  - 13 Remy-Jardin M, Ryerson CJ, Schiebler ML, et al. Imaging of pulmonary hypertension in adults: a position paper from the Fleischner Society. *Eur Respir J* 2021;57(01):2004455
  - 14 Fields JM, Davis J, Girson L, et al. Transthoracic echocardiography for diagnosing pulmonary embolism: a systematic review and meta-analysis. *J Am Soc Echocardiogr* 2017;30(07):714–723.e4
  - 15 Daley JJ, Dwyer KH, Grunwald Z, et al. Increased sensitivity of focused cardiac ultrasound for pulmonary embolism in emergency department patients with abnormal vital signs. *Acad Emerg Med* 2019;26(11):1211–1220
  - 16 Patel B, Shah M, Garg L, Agarwal M, Martinez M, Dusaj R. Trends in the use of echocardiography in pulmonary embolism. *Medicine (Baltimore)* 2018;97(35):e12104
  - 17 Alerhand S, Sundaram T, Gottlieb M. What are the echocardiographic findings of acute right ventricular strain that suggest pulmonary embolism? *Anaesth Crit Care Pain Med* 2021;40(02):100852
  - 18 Lang RM, Badano LP, Mor-Avi V, et al. Recommendations for cardiac chamber quantification by echocardiography in adults: an update from the American Society of Echocardiography and the European Association of Cardiovascular Imaging. *J Am Soc Echocardiogr* 2015;28(01):1–39.e14
  - 19 Volpicelli G, Elbarbary M, Blaivas M, et al; International Liaison Committee on Lung Ultrasound (ILC-LUS) for International Consensus Conference on Lung Ultrasound (ICC-LUS) International evidence-based recommendations for point-of-care lung ultrasound. *Intensive Care Med* 2012;38(04):577–591
  - 20 Chen W, Xu K, Li Y, et al. Clinical value of thoracic ultrasonography in the diagnosis of pulmonary embolism: a systematic review and meta-analysis. *Med Ultrason* 2022;24(02):226–234
  - 21 Zhu R, Ma XC. Clinical value of ultrasonography in diagnosis of pulmonary embolism in critically ill patients. *J Transl Int Med* 2017;5(04):200–204
  - 22 Germini F, Zarabi S, Eventov M, Turcotte M, Li M, de Wit K. Pulmonary embolism prevalence among emergency department cohorts: a systematic review and meta-analysis by country of study. *J Thromb Haemost* 2021;19(01):173–185
  - 23 Jaureguizar A, Jiménez D, Bikdeli B, et al; Registro Informatizado de la Enfermedad TromboEmbólica Investigators. Heart rate and mortality in patients with acute symptomatic pulmonary embolism. *Chest* 2022;161(02):524–534
  - 24 Linnemann BBW, Doenst T, Erbel C, et al. Diagnostics and Therapy of Venous Thrombosis and Pulmonary Embolism. The revised AWMF S2k Guideline. *Vasa* 2023 Oct; 52(S111):1–146 PMID: 37904504. DOI: 10.1024/0301-1526/a001089
  - 25 Jiménez D, Aujesky D, Moores L, et al; RIETE Investigators. Simplification of the pulmonary embolism severity index for prognostication in patients with acute symptomatic pulmonary embolism. *Arch Intern Med* 2010;170(15):1383–1389
  - 26 Stevens SM, Woller SC, Baumann Kreuziger L, et al. Executive summary: antithrombotic therapy for VTE disease—second update of the CHEST Guideline and Expert Panel Report. *Chest* 2021; 160(06):2247–2259
  - 27 Barco S, Mahmoudpour SH, Planquette B, Sanchez O, Konstantinides SV, Meyer G. Prognostic value of right ventricular dysfunction or elevated cardiac biomarkers in patients with low-risk pulmonary embolism: a systematic review and meta-analysis. *Eur Heart J* 2019;40(11):902–910
  - 28 Becattini C, Agnelli G, Lankeit M, et al. Acute pulmonary embolism: mortality prediction by the 2014 European Society of Cardiology risk stratification model. *Eur Respir J* 2016;48(03):780–786
  - 29 Klok FA, Ageno W, Ay C, et al. Optimal follow-up after acute pulmonary embolism: a position paper of the European Society of Cardiology Working Group on Pulmonary Circulation and Right Ventricular Function, in collaboration with the European Society of Cardiology Working Group on Atherosclerosis and Vascular Biology, endorsed by the European Respiratory Society. *Eur Heart J* 2022;43(03):183–189
  - 30 Ghanem A, Andrassy M, Dürschmied D, et al. Interventionelle Therapie und multidisziplinäre Managementstrategien für die akute Lungenembolie. *Kardiologie* 2023;17(03):141–159
  - 31 Hobohm L, Farmakis IT, Keller K, et al. Pulmonary embolism response team (PERT) implementation and its clinical value across countries: a scoping review and meta-analysis. *Clin Res Cardiol* 2023;112(10):1351–1361
  - 32 !!! INVALID CITATION !!! }
  - 33 Khosla A, Mojibian H, Assi R, Tantawy H, Singh I, Pollak J. Right heart thrombi (RHT) and clot in transit with concomitant PE management: approach and considerations. *Pulm Circ* 2022;12(02):e12080
  - 34 Quezada CA, Bikdeli B, Barrios D, et al. Meta-analysis of prevalence and short-term prognosis of hemodynamically unstable patients with symptomatic acute pulmonary embolism. *Am J Cardiol* 2019;123(04):684–689
  - 35 Murin S, Romano PS, White RH. Comparison of outcomes after hospitalization for deep venous thrombosis or pulmonary embolism. *Thromb Haemost* 2002;88(03):407–414
  - 36 Mearns ES, Coleman CI, Patel D, et al. Index clinical manifestation of venous thromboembolism predicts early recurrence type and frequency: a meta-analysis of randomized controlled trials. *J Thromb Haemost* 2015;13(06):1043–1052
  - 37 Zuo Z, Yue J, Dong BR, Wu T, Liu GJ, Hao Q. Thrombolytic therapy for pulmonary embolism. *Cochrane Database Syst Rev* 2021;4(04):CD004437
  - 38 Barilli M, Tavera MC, Valente S, Palazzuoli A. Structural and hemodynamic changes of the right ventricle in PH-HFpEF. *Int J Mol Sci* 2022;23(09):4554

- 39 Sanchez O, Charles-Nelson A, Ageno W, et al; PEITHO-3 Investigators. Reduced-dose intravenous thrombolysis for acute intermediate-high-risk pulmonary embolism: rationale and design of the Pulmonary Embolism International THrOmbolysis (PEITHO)-3 trial. *Thromb Haemost* 2022;122(05):857–866
- 40 Zhang Z, Zhai ZG, Liang LR, Liu FF, Yang YH, Wang C. Lower dosage of recombinant tissue-type plasminogen activator (rt-PA) in the treatment of acute pulmonary embolism: a systematic review and meta-analysis. *Thromb Res* 2014;133(03):357–363
- 41 Pruszczyk P, Klok FA, Kucher N, et al. Percutaneous treatment options for acute pulmonary embolism: a clinical consensus statement by the ESC working group on pulmonary circulation and right ventricular function and the European Association of Percutaneous Cardiovascular Interventions. *EuroIntervention* 2022;18(08):e623–e638
- 42 Götzinger F, Lauder L, Sharp ASP, et al. Interventional therapies for pulmonary embolism. *Nat Rev Cardiol* 2023;20(10):670–684
- 43 Zieliński D, Dyk W, Wróbel K, Biederman A. Surgical pulmonary embolectomy: state of the art. *Kardiochir Torakochirurgia Pol* 2023;20(02):111–117
- 44 Loyalka P, Ansari MZ, Cheema FH, Miller CC III, Rajagopal S, Rajagopal K. Surgical pulmonary embolectomy and catheter-based therapies for acute pulmonary embolism: a contemporary systematic review. *J Thorac Cardiovasc Surg* 2018;156(06):2155–2167