

Management of Severe Colitis and Toxic Megacolon

Marjorie R. Liggett, MD¹ Hasan B. Alam, MD¹

¹Department of Surgery, Feinberg School of Medicine, Northwestern University, Chicago, Illinois

Clin Colon Rectal Surg

Address for correspondence Hasan B. Alam, MD, FACS, Department of Surgery, Feinberg School of Medicine, Northwestern University, Northwestern Memorial Hospital, 676 N. St. Clair Street, Suite 2320, Chicago, IL 60611 (e-mail: hasan.alam@nm.org).

Abstract

Keywords

- ▶ toxic colitis
- ▶ toxic megacolon
- ▶ subtotal abdominal colectomy with end ileostomy

Severe colitis is a well-defined condition encompassing several etiologies but is most often caused by severe ulcerative colitis or *Clostridioides difficile* infection. Severe colitis can evolve into toxic colitis, or toxic megacolon when associated with bowel dilation and systemic manifestations, resulting in a life-threatening scenario where multidisciplinary management is often required. Medical management continues to play an important role in the initial treatment of toxic megacolon. However, timely surgical intervention can be lifesaving.

Toxic megacolon (TM) is a potentially fatal condition that can result from a wide range of infectious and inflammatory etiologies. The diagnosis of TM is made clinically and radiographically. The best-accepted clinical criteria for diagnosis of TM were described by Jalan et al in 1969 and include any three of the following: fever greater than 101.5°F (>38.6°C), heart rate greater than 120 beats/min, white blood cell count greater than 10.5 ($\times 10^9/L$), or anemia as well as altered mentation, dehydration, hypotension, or electrolyte derangements.^{1,2} These criteria reflect the systemic inflammatory manifestations of the colonic pathology. Radiographically, toxic dilation is defined as nonobstructing dilation of the colon (≥ 5.5 cm), with abnormal haustral appearance.³⁻⁶ This dilation tends to be most common in the transverse and ascending colons. Precise data on the epidemiology for TM are scarce, but recent studies show that inflammatory bowel disease (IBD), particularly ulcerative colitis (UC), remains the most common cause of TM, followed by infectious colitis due to *Clostridioides difficile* infection and, rarely, ischemic colitis.^{7,8} The mortality rate for TM varies based on the underlying cause. When caused by fulminant infections, mortality rates can be as high as 80%.⁹⁻¹¹ It is for this reason that all gastrointestinal surgeons must be aware of the indications for surgery and the surgical options available. Here we review the diagnosis and medical and surgical treatments of the most common causes of TM: severe acute UC and fulminant *C. difficile* infection.

Severe Acute Ulcerative Colitis

Diagnosis

UC is a chronic immune-mediated inflammatory condition affecting the colon and rectum that has continued to increase in incidence worldwide.¹² Acute severe ulcerative colitis (ASUC), historically referred to as “fulminant” or “toxic” colitis, represents a severe form of acute colitis involving more than six bloody stools per day accompanied by at least one systemic sign of toxicity including tachycardia, fever, anemia (hemoglobin <10.5 g/dL), or elevated erythrocyte sedimentation rate (ESR) greater than 30 mm/h.^{12,13} Approximately one-quarter of patients with UC may develop ASUC requiring hospitalization, with 40% of the patients requiring a colectomy.^{14,15} TM complicates the presentation of ASUC in approximately 5% of patients.^{11,16}

Initial evaluation of the patient with suspected ASUC should begin with a thorough history and physical examination followed by appropriate laboratory, radiographic, and potential endoscopic assessment (▶ **Fig. 1**). In addition to standard laboratory tests, all patients meeting the criteria for ASUC should undergo testing for *C. difficile*. Patients with UC and *C. difficile* infection are known to have significantly higher mortality rates and higher rates of medical escalation, and are at higher risk of colectomy.^{12,17-19} UC patients often lack the traditional risk factors for *C. difficile* infection and a high index of suspicion for its presence is paramount.

Imaging continues to play a significant role in the diagnosis of ASUC and TM. As has been described elsewhere, the presence of colonic dilation of greater than 5.5 cm, particularly of the transverse colon, on plain radiographs is concerning for TM and indicative of a worse prognosis. Additionally, one study suggested that the presence of three or more dilated small bowel loops on plain radiograph indirectly reflected the increased severity of colitis, and was predictive of the need for colectomy.²⁰ Daily abdominal radiographs should be obtained until there is evidence of decreasing dilation or surgical intervention is planned.¹⁶ On computed tomography (CT) scan, colonic dilation, segmental wall thinning, and an abnormal haustral pattern are more likely to occur in ASUC complicated by TM.⁴ Uncomplicated ASUC is often characterized by diffuse colonic wall thickening and submucosal edema (“target sign”).⁵ While CT scans provide valuable information regarding the extent of disease, occult complications of disease, and underlying etiology in patients without prior history of colitis (i.e., UC vs. Crohn’s colitis), results of CT scan are not shown to influence the decision to perform a colectomy in these patients.²¹ The decision to operate is more often driven by the systemic manifestation of inflammatory processes (e.g., severity of shock, need for vasopressors, development of distant organ dysfunction, etc.).

Endoscopic evaluation remains an important diagnostic tool for the evaluation of patients with ASUC by establishing the severity of inflammation and confirming underlying etiology via colon appearance and biopsies. A complete colonoscopy comes with an elevated risk of perforation and development of TM, and therefore patients with suspected ASUC should undergo flexible sigmoidoscopy with minimal insufflation by an expert endoscopist. Ideally, endoscopy should be performed within 24 hours of admission.¹² There is no standardized severity scoring system specific for ASUC; however, studies have shown that the presence of deep ulcerations and an Ulcerative Colitis Endoscopic Index of Severity (USEIS) score greater than 5 are suggestive of high risk of requiring rescue therapy or colectomy.^{22–24}

Medical Management

The mainstay of medical management of ASUC is intravenous (IV) corticosteroids. Recent guidelines from the American College of Gastroenterology recommend using methylprednisolone 60 mg/d or hydrocortisone 100 mg three to four times daily to induce remission.¹² In addition, patients with ASUC should receive IV hydration/resuscitation, electrolyte replacement as indicated, deep vein thrombosis (DVT) prophylaxis, blood transfusions as needed, and total parenteral nutrition if malnourished. Nonsteroidal anti-inflammatory medications, anticholinergic medications, antidiarrheal agents, and opiates should be avoided. The development of systemic toxicity, abdominal distension, peritonitis, frequency of bowel movements, and presence of melena or hematochezia should be assessed daily. Early surgical consultation should be obtained if the patient has any indica-

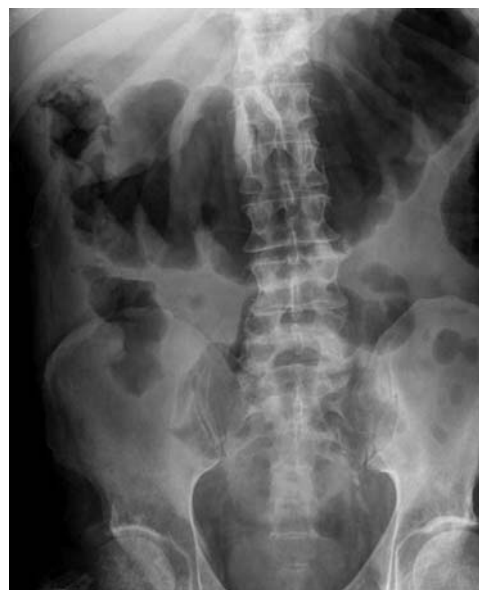

Fig. 1 Plain film of toxic megacolon demonstrating dilated transverse colon.

tions for an emergent operation such as worsening peritonitis, pneumoperitoneum, worsening shock despite appropriate resuscitation, or development of distant organ dysfunction, etc. The Oxford index is the most commonly used method to identify nonresponders to therapy. More than eight bowel movements per day on day 3 of corticosteroid treatment or three to eight bowel movements along with a C-reactive protein (CRP) greater than 45 mg/L predicted colectomy in 85% of patients.²⁵ Additionally, the presence of hypoalbuminemia, colonic dilation, ESR greater than 75 mm/h, and fever greater than 38°C predicted failure of steroids.²⁶ If patients fail to respond by 3 to 5 days of steroid therapy, medical rescue should be initiated using either infliximab or cyclosporine.¹² At this time, randomized control trial data show similar efficacy and complication profiles of each medication, and therefore selection is provider dependent.^{27,28} It should be noted that therapy with infliximab or cyclosporine is *not* associated with increased risk of surgical complications.²⁹ Surgical consultation should be obtained when patients fail steroid treatment and have started medical rescue therapy. If patients continue to fail medical therapy by days 5 to 8 with cyclosporine or infliximab, surgical intervention is recommended (► Fig. 2).¹⁶

Four clinical trials examined the role of broad-spectrum antibiotics in hospitalized patients with ASUC. In each of these studies, there was no difference in the need for surgery or failure of medical therapy with the use of adjunct antibiotics.^{30–33} As such, IV antibiotics should be reserved for patients with suspected extraluminal complications or systemic signs of toxicity.

Surgical Management

Patients with severe medically refractory ASUC, TM, massive hemorrhage, or colonic perforation should undergo surgical therapy.³⁴ Given that many of these patients have been

undergoing days of immunosuppressive therapy, the typical signs, and symptoms of impending or contained perforation may be lacking. However, mortality rates increase with longer time intervals between colonic perforation and surgical intervention, especially in the setting of multisystem organ failure. Therefore, prompt surgical evaluation and intervention should be undertaken.

The operation of choice continues to be subtotal abdominal colectomy with end ileostomy. Proctectomy should be avoided in the acute setting to preserve future reconstructive options, reduce operative time, and reduce postoperative complications.^{16,34,35} To prevent rectal stump dehiscence and leak, most surgeons elect to leave a transanally placed rectal tube for decompression. Other alternatives include implanting the rectal stump into the subcutaneous tissues, creating a mucous fistula, and/or thoroughly irrigating the stump to clear any retained stool.^{34,36} Reconstruction with ileal pouch-anal anastomosis (IPAA) at the time of initial surgery should be avoided given patients are often critically ill, have been on high-dose steroids, and have higher operative morbidity when IPAA is performed in the semi-urgent and urgent settings.^{8,37–39} An operative approach using either open or laparoscopic techniques should be based on the hemodynamic stability of the patient, the friability of the colonic mucosa and risk of iatrogenic perforation, degree of colonic and small bowel dilation, and expertise of the operating surgeon.

While decompressive procedures alone carry a significant morbidity when compared with subtotal colectomy and end ileostomy, a Turnbull blowhole colostomy can be considered in patients with prohibitive comorbidities, a hostile abdomen, or a pregnant patient with acute severe colitis.^{16,36,40} This is performed by creating a transverse colostomy for colonic decompression flush with the skin and a loop ileostomy. However, this is considered a suboptimal treatment option. While it will decompress the distended colon, the diseased colon will continue to drive the systemic inflammatory response.

Fulminant *Clostridioides difficile* Colitis

Diagnosis

Clostridioides difficile (previously *Clostridium difficile*) is an anaerobic, spore-forming, gram-positive, bacillus bacterium that is often a normal inhabitant of the human colon. Alteration in the microbiota, most often due to antibiotic exposure (even single surgical prophylactic doses), results in overgrowth of the *C. difficile* bacteria and induction of pathologic behavior. *C. difficile* produces toxins A and B that induce colonic inflammation that can range from mild to life threatening. *C. difficile* typically produces a pseudomembranous colitis affecting the large bowel but can rarely also affect the small intestines. A highly virulent strain BI/NAP1/027/toxinotype III has been linked to life-threatening *C. difficile* infections.⁴¹ Luckily, the incidence of total burden of *C. difficile* in the health care setting has decreased by 24% between 2011 and 2017; however, overall incidence in the community and in-hospital deaths has remained unchanged.⁴²

The diagnosis of *C. difficile* is made based on clinical suspicion and subsequent laboratory testing. Patients who have had three or more unexplained watery bowel movements within 24 hours should undergo *C. difficile* testing via stool nucleic acid amplification (NAAT) testing to identify toxin, followed by toxin enzyme immunoassay assays in a two-step approach.^{43,44} Stool cultures for the bacteria alone are inaccurate and do not reflect active infection.^{44,45} In a patient with severe *C. difficile* infection causing ileus, perirectal swabs can be used in lieu of stool samples.⁴³ Radiographic investigations have limited utility in the diagnosis of *C. difficile* colitis, although CT scans are often obtained to rule out perforation or the presence of megacolon. CT findings typically demonstrate a thick colonic wall, fat stranding, colonic dilation, and inflamed mucosa, although these findings are not specific to *C. difficile* infection.^{43,45} Endoscopy to assess for the presence of pseudomembranes can be utilized when clinical suspicion is high, but laboratory testing is negative for *C. difficile* toxin or if there is an urgent need for diagnosis. It is important to note that pseudomembranes are seen in only 50% of confirmed cases of *C. difficile* infection.⁴⁶

The severity of *C. difficile* colitis is not well defined but has traditionally been based on confirmation of infection, degree of leukocytosis, and systemic signs of toxicity. Nonsevere infection is defined as a leukocytosis of less than $15 \times 10^3/\mu\text{L}$ with a creatinine less than 1.5 mg/dL. Severe infection is defined as leukocytosis greater than $15 \times 10^3/\mu\text{L}$ with evidence of renal dysfunction. Severe complicated or fulminant *C. difficile* infection is defined by leukocytosis greater than $15 \times 10^3/\mu\text{L}$ with associated shock, sepsis, multiorgan failure, ileus, or megacolon.^{45,47} Medical therapy is driven by clinical severity and surgical intervention is typically reserved for cases refractory to medical management or complicated by perforation or ischemia.

Medical Management

When a diagnosis of *C. difficile* colitis has been made, the first step in management is to discontinue the inciting antibiotics. Recent studies have demonstrated that oral vancomycin is superior to IV metronidazole in the treatment of mild, moderate, and severe *C. difficile* infections.^{48–51} Fidaxomicin has been shown to be superior to oral vancomycin; however, it is often cost prohibitive.⁴⁸ In the case of fulminant *C. difficile* colitis, oral vancomycin should be initiated at a dose of 500 mg four times daily by mouth or nasogastric tube. The oral vancomycin is not absorbed and works by directly targeting the *C. difficile* bacteria in the colonic lumen. IV metronidazole at a dose of 500 mg every 8 hours can also be added in the case of ileus. Additionally, rectal vancomycin enemas at a dose of 500 mg in 500 mL normal saline every 6 hours can be considered in severe cases, or if the presence of ileus is likely to slow the delivery of oral medication to the colon (► Fig. 3).^{44,45}

Surgical Management

The surgical management for patients with severe, fulminant *C. difficile* infection should be reserved for patients with

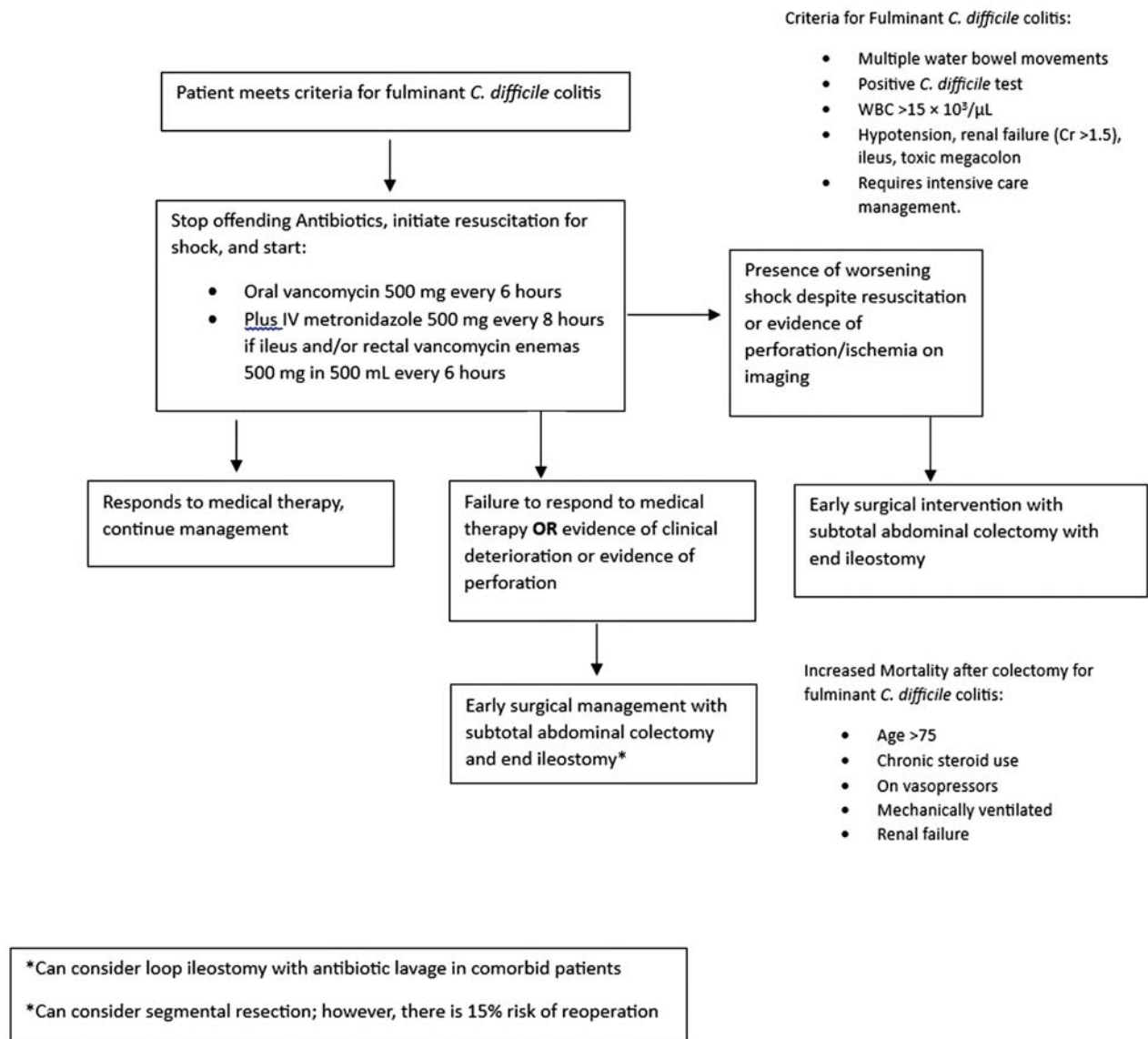


Fig. 2 Management algorithm of acute severe ulcerative colitis (UC).

Abbreviations: CRP, C-reactive protein; CT, computed tomography; ESR, erythrocyte sedimentation rate; IV, intravenous; NSAIDs, nonsteroidal anti-inflammatory drugs.

colonic perforation or severe colitis that is not improving with medical therapy. Approximately 1% of patients with *C. difficile* infection and 30% of patients with fulminant infection will require surgery. The mortality rate of patients undergoing colectomy for fulminant *C. difficile* colitis is high, around 30 to 50%⁵²⁻⁵⁴. However, multiple studies have shown that early surgical intervention prior to development of septic shock improves mortality compared with prolonged medical therapy, particularly in patient with TM.^{45,53,55-58} While there are no high-level studies describing the optimal time for surgical intervention, one retrospective study showed that patients with fulminant *C. difficile* infection who were admitted to a surgical service received colectomy faster than those admitted to a medical service (within an average of 1.0 day of admission to a surgery team and immediately on admission to a surgical intensive care unit [ICU] compared with an average of 3.4 days after admission to a medical team and 1.7 days after admission

to a medical ICU). The patients in this study who were treated by a nonsurgical service had a 3.4-fold higher mortality rate than those admitted to a surgical service. This is thought to be at least in part due to delayed operative intervention.⁵⁸ Retrospective studies have attempted to identify predictors of mortality after emergency surgery for *C. difficile*. While there is no widely used and validated scoring system, patients with the following tend to have higher mortality after emergency colectomy for fulminant *C. difficile* colitis: shock requiring vasopressors, respiratory failure requiring mechanical ventilation, electrolyte derangement, renal failure, chronic steroid use, and/or advanced age (>75 years old).^{53,54,59-61} The timing of surgery is critically important. Therefore, it is essential to obtain an early surgical consultation so that the patient can receive a lifesaving operation before requiring vasopressors for shock and development of multiorgan failure.

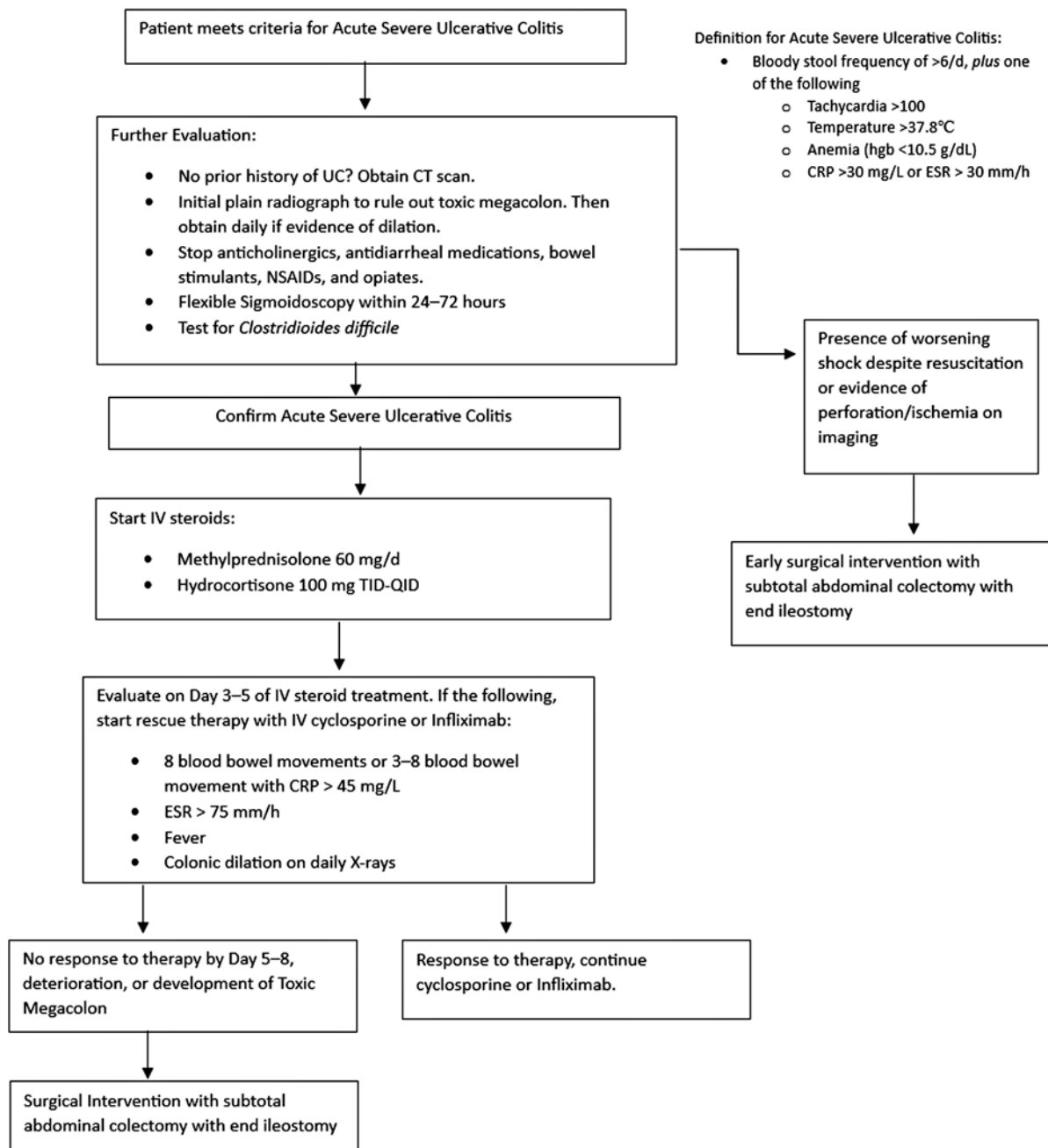


Fig. 3 Management algorithm of fulminant *Clostridioides difficile* colitis. Abbreviations: IV, intravenous; WBC, white blood cell.

The operative procedure of choice is a subtotal abdominal colectomy with end ileostomy, typically via an open approach given the severity of illness in this patient population.^{43,45} However, while prior studies suggested increased morbidity and mortality with partial resection compared with total abdominal colectomy,⁵³ two recent studies using the American College of Surgeons National Surgical Quality Improvement Program (ACS-NSQIP) data showed no difference in mortality, postoperative complication rate, or hospital length of stay in patients undergoing partial colectomy for fulminant infection compared with total abdominal colectomy.^{52,62} Given that *C. difficile* is a mucosal-based disease, a reliable assessment of the extent and severity of disease cannot

typically be made by assessing the serosal surface of the bowel, and for this reason, most national guidelines continue to recommend a subtotal colectomy over a partial resection.

There is some evidence to suggest that loop ileostomy with antegrade antibiotic lavage can serve as a colon sparing alternative to subtotal colectomy. This technique involves a laparoscopic creation of a loop ileostomy followed by antegrade lavage of polyethylene glycol solution via the ileostomy followed by antibiotic lavage with vancomycin and IV antibiotics. An early prospective trial by Neal et al showed a 19% mortality with this technique compared with 50% mortality after subtotal colectomy.⁶³ However, this was not a randomized study and they used historical controls, which made it

difficult to fairly compare the groups. Since the publishing of that trial, larger scale studies analyzing ACS-NSQIP⁶⁴ and National Inpatient Sample (NIS)⁶⁵ data showed similar survival in the loop ileostomy group compared with subtotal colectomy, but lower complication rates.⁶⁴ Results from a recent meta-analysis also suggest no mortality difference between loop ileostomy and lavage compared with subtotal abdominal colectomy (26.2 vs. 31.3%, $p = 0.22$).⁶⁶ While further data are required, loop ileostomy and lavage may be considered as a potential alternative to colectomy in select patients.

Conclusion

Severe colitis associated with systemic toxicity and significant bowel dilation (TM) can quickly develop into a life-threatening condition with high morbidity and mortality. The most common causes of TM today are ASUC and fulminant *C. difficile* infection. While both conditions can be initially managed with medical therapy, early surgical intervention with subtotal abdominal colectomy and end ileostomy can be lifesaving.

Authors' Contribution

M.R.L. was the primary author of the manuscript. H.B.A. was the primary reviewer of the manuscript.

Funding

None.

Conflict of Interest

None declared.

References

- Jalan KN, Sircus W, Card WI, et al. An experience of ulcerative colitis. I. Toxic dilation in 55 cases. *Gastroenterology* 1969;57(01):68–82
- Sheth SG, LaMont JT. Toxic megacolon. *Lancet* 1998;351(9101):509–513
- Ippolito S, Tonolini M, Villa C. Radiographic and CT imaging assessment of acute exacerbations and surgical complications. In: Tonolini M, ed. *Imaging of Ulcerative Colitis*. Milan: Springer; 2014:43–50
- Moulin V, Dellon P, Laurent O, Aubry S, Lubrano J, Delabrousse E. Toxic megacolon in patients with severe acute colitis: computed tomographic features. *Clin Imaging* 2011;35(06):431–436
- Imbriaco M, Balthazar EJ. Toxic megacolon: role of CT in evaluation and detection of complications. *Clin Imaging* 2001;25(05):349–354
- Jones JH, Chapman M. Definition of megacolon in colitis. *Gut* 1969;10(07):562–564
- Doshi R, Desai J, Shah Y, Decter D, Doshi S. Incidence, features, in-hospital outcomes and predictors of in-hospital mortality associated with toxic megacolon hospitalizations in the United States. *Intern Emerg Med* 2018;13(06):881–887
- Ausch C, Madoff RD, Gnant M, et al. Aetiology and surgical management of toxic megacolon. *Colorectal Dis* 2006;8(03):195–201
- Longo WE, Mazuski JE, Virgo KS, Lee P, Bahadursingh AN, Johnson FE. Outcome after colectomy for *Clostridium difficile* colitis. *Dis Colon Rectum* 2004;47(10):1620–1626
- Klipfel AA, Schein M, Fahoum B, Wise L. Acute abdomen and *Clostridium difficile* colitis: still a lethal combination. *Dig Surg* 2000;17(02):160–163
- Gan SI, Beck PL. A new look at toxic megacolon: an update and review of incidence, etiology, pathogenesis, and management. *Am J Gastroenterol* 2003;98(11):2363–2371
- Rubin DT, Ananthkrishnan AN, Siegel CA, Sauer BG, Long MD. ACG clinical guideline: ulcerative colitis in adults. *Am J Gastroenterol* 2019;114(03):384–413
- Truelove SC, Witts LJ. Cortisone in ulcerative colitis; final report on a therapeutic trial. *BMJ* 1955;2(4947):1041–1048
- Dinesen LC, Walsh AJ, Protic MN, et al. The pattern and outcome of acute severe colitis. *J Crohn's Colitis* 2010;4(04):431–437
- Bojic D, Radojicic Z, Nedeljkovic-Protic M, Al-Ali M, Jewell DP, Travis SPL. Long-term outcome after admission for acute severe ulcerative colitis in Oxford: the 1992–1993 cohort. *Inflamm Bowel Dis* 2009;15(06):823–828
- Strong SA. Management of acute colitis and toxic megacolon. *Clin Colon Rectal Surg* 2010;23(04):274–284
- Navaneethan U, Mukewar S, Venkatesh PG, Lopez R, Shen B. *Clostridium difficile* infection is associated with worse long term outcome in patients with ulcerative colitis. *J Crohn's Colitis* 2012;6(03):330–336
- Ananthkrishnan AN, Issa M, Binion DG. *Clostridium difficile* and inflammatory bowel disease. *Med Clin North Am* 2010;94(01):135–153
- Chen Y, Furuya-Kanamori L, Doi SA, Ananthkrishnan AN, Kirk M. *Clostridium difficile* infection and risk of colectomy in patients with inflammatory bowel disease: a bias-adjusted meta-analysis. *Inflamm Bowel Dis* 2017;23(02):200–207
- Chew CN, Nolan DJ, Jewell DP. Small bowel gas in severe ulcerative colitis. *Gut* 1991;32(12):1535–1537
- da Luz Moreira A, Vogel JD, Baker M, Mor I, Zhang R, Fazio V. Does CT influence the decision to perform colectomy in patients with severe ulcerative colitis? *J Gastrointest Surg* 2009;13(03):504–507
- Corte C, Fernandopulle N, Catuneanu AM, et al. Association between the Ulcerative Colitis Endoscopic Index of Severity (UCEIS) and outcomes in acute severe ulcerative colitis. *J Crohn's Colitis* 2015;9(05):376–381
- Carbonnel F, Lavergne A, Lémann M, et al. Colonoscopy of acute colitis. A safe and reliable tool for assessment of severity. *Dig Dis Sci* 1994;39(07):1550–1557
- Xie T, Zhang T, Ding C, et al. Ulcerative Colitis Endoscopic Index of Severity (UCEIS) versus Mayo endoscopic score (MES) in guiding the need for colectomy in patients with acute severe colitis. *Gastroenterol Rep (Oxf)* 2018;6(01):38–44
- Travis SP, Farrant JM, Ricketts C, et al. Predicting outcome in severe ulcerative colitis. *Gut* 1996;38(06):905–910
- Ho GT, Mowat C, Goddard CJR, et al. Predicting the outcome of severe ulcerative colitis: development of a novel risk score to aid early selection of patients for second-line medical therapy or surgery. *Aliment Pharmacol Ther* 2004;19(10):1079–1087
- Laharie D, Bourreille A, Branche J, et al; Groupe d'Etudes Thérapeutiques des Affections Inflammatoires Digestives. Long-term outcome of patients with steroid-refractory acute severe UC treated with ciclosporin or infliximab. *Gut* 2018;67(02):237–243
- Ordás I, Domènech E, Mañosa M, et al. Long-term efficacy and safety of cyclosporine in a cohort of steroid-refractory acute severe ulcerative colitis patients from the ENEIDA registry (1989–2013): a nationwide multicenter study. *Am J Gastroenterol* 2017;112(11):1709–1718
- Nelson R, Liao C, Fichera A, Rubin DT, Pekow J. Rescue therapy with cyclosporine or infliximab is not associated with an increased risk for postoperative complications in patients hospitalized for severe steroid-refractory ulcerative colitis. *Inflamm Bowel Dis* 2014;20(01):14–20
- Chapman RW, Selby WS, Jewell DP. Controlled trial of intravenous metronidazole as an adjunct to corticosteroids in severe ulcerative colitis. *Gut* 1986;27(10):1210–1212
- Mantzaris GJ, Hatzis A, Kontogiannis P, Triadaphyllou G. Intravenous tobramycin and metronidazole as an adjunct to corticosteroids in acute, severe ulcerative colitis. *Am J Gastroenterol* 1994;89(01):43–46

- 32 Mantzaris GJ, Petraki K, Archavlis E, et al. A prospective randomized controlled trial of intravenous ciprofloxacin as an adjunct to corticosteroids in acute, severe ulcerative colitis. *Scand J Gastroenterol* 2001;36(09):971–974
- 33 Dickinson RJ, O'Connor HJ, Pinder I, Hamilton I, Johnston D, Axon AT. Double blind controlled trial of oral vancomycin as adjunctive treatment in acute exacerbations of idiopathic colitis. *Gut* 1985; 26(12):1380–1384
- 34 Holubar SD, Lightner AL, Poylin V, et al; Prepared on behalf of the Clinical Practice Guidelines Committee of the American Society of Colon and Rectal Surgeons. The American Society of Colon and Rectal Surgeons clinical practice guidelines for the surgical management of ulcerative colitis. *Dis Colon Rectum* 2021;64(07):783–804
- 35 Autenrieth DM, Baumgart DC. Toxic megacolon. *Inflamm Bowel Dis* 2012;18(03):584–591
- 36 Arnell TD. Surgical management of acute colitis and toxic megacolon. *Clin Colon Rectal Surg* 2004;17(01):71–74
- 37 Ordás I, Domènech E, Mañosa M, et al; ENEIDA registry of GETECCU. Post-operative morbidity and mortality of a cohort of steroid refractory acute severe ulcerative colitis: nationwide multicenter study of the GETECCU ENEIDA registry. *Am J Gastroenterol* 2018;113(07):1009–1016
- 38 McKenna NP, Bews KA, Mathis KL, Lightner AL, Habermann EB. Surgery during admission for an ulcerative colitis flare: should pouch formation be considered? *J Surg Res* 2019;239:216–223
- 39 Berg DF, Bahadursingh AM, Kaminski DL, Longo WE. Acute surgical emergencies in inflammatory bowel disease. *Am J Surg* 2002; 184(01):45–51
- 40 Ooi BS, Remzi FH, Fazio VW. Turnbull-Blowhole colectomy for toxic ulcerative colitis in pregnancy: report of two cases. *Dis Colon Rectum* 2003;46(01):111–115
- 41 O'Connor JR, Johnson S, Gerding DN. *Clostridium difficile* infection caused by the epidemic BI/NAP1/027 strain. *Gastroenterology* 2009;136(06):1913–1924
- 42 Guh AY, Mu Y, Winston LG, et al; Emerging Infections Program Clostridioides difficile Infection Working Group. Trends in U.S. burden of *Clostridioides difficile* infection and outcomes. *N Engl J Med* 2020;382(14):1320–1330
- 43 Sartelli M, Di Bella S, McFarland LV, et al. 2019 update of the WSES guidelines for management of *Clostridioides (Clostridium) difficile* infection in surgical patients. *World J Emerg Surg* 2019;14(01):8
- 44 McDonald LC, Gerding DN, Johnson S, et al. Clinical Practice Guidelines for *Clostridium difficile* Infection in Adults and Children: 2017 Update by the Infectious Diseases Society of America (IDSA) and Society for Healthcare Epidemiology of America (SHEA). *Clin Infect Dis* 2018;66(07):987–994
- 45 Poylin V, Hawkins AT, Bhamra AR, et al; Prepared by the Clinical Practice Guidelines Committee of The American Society of Colon and Rectal Surgeons. The American Society of Colon and Rectal Surgeons clinical practice guidelines for the management of *Clostridioides difficile* infection. *Dis Colon Rectum* 2021;64(06): 650–668
- 46 Burkart NE, Kwaan MR, Shepela C, et al. Indications and relative utility of lower endoscopy in the management of *Clostridium difficile* infection. *Gastroenterol Res Pract* 2011;2011:626582
- 47 Khanna S, Shin A, Kelly CP. Management of *Clostridium difficile* infection in inflammatory bowel disease: expert review from the clinical practice updates committee of the AGA institute. *Clin Gastroenterol Hepatol* 2017;15(02):166–174
- 48 Nelson RL, Suda KJ, Evans CT. Antibiotic treatment for *Clostridium difficile*-associated diarrhoea in adults. *Cochrane Database Syst Rev* 2017;3(03):CD004610
- 49 Di X, Bai N, Zhang X, et al. A meta-analysis of metronidazole and vancomycin for the treatment of *Clostridium difficile* infection, stratified by disease severity. *Braz J Infect Dis* 2015;19(04): 339–349
- 50 Stevens VW, Nelson RE, Schwab-Daugherty EM, et al. comparative effectiveness of vancomycin and metronidazole for the prevention of recurrence and death in patients with *Clostridium difficile* infection. *JAMA Intern Med* 2017;177(04):546–553
- 51 Zar FA, Bakkanagari SR, Moorthi KMLST, Davis MB. A comparison of vancomycin and metronidazole for the treatment of *Clostridium difficile*-associated diarrhea, stratified by disease severity. *Clin Infect Dis* 2007;45(03):302–307
- 52 Ahmed N, Kuo YH. Outcomes of total versus partial colectomy in fulminant *Clostridium difficile* colitis: a propensity matched analysis. *World J Emerg Surg* 2022;17(01):11
- 53 Bhangu A, Nepogodiev D, Gupta A, Torrance A, Singh PWest Midlands Research Collaborative. Systematic review and meta-analysis of outcomes following emergency surgery for *Clostridium difficile* colitis. *Br J Surg* 2012;99(11):1501–1513
- 54 Lee DY, Chung EL, Guend H, Whelan RL, Wedderburn RV, Rose KM. Predictors of mortality after emergency colectomy for *Clostridium difficile* colitis: an analysis of ACS-NSQIP. *Ann Surg* 2014;259(01): 148–156
- 55 Hall BR, Armijo PR, Leinicke JA, Langenfeld SJ, Oleynikov D. Prolonged non-operative management of *clostridium difficile* colitis is associated with increased mortality, complications, and cost. *Am J Surg* 2019;217(06):1042–1046
- 56 Lamontagne F, Labbé AC, Haecq O, et al. Impact of emergency colectomy on survival of patients with fulminant *Clostridium difficile* colitis during an epidemic caused by a hypervirulent strain. *Ann Surg* 2007;245(02):267–272
- 57 Ahmed N, Kuo YH. Early colectomy saves lives in toxic megacolon due to *Clostridium difficile* infection. *South Med J* 2020;113(07): 345–349
- 58 Sailhamer EA, Carson K, Chang Y, et al. Fulminant *Clostridium difficile* colitis: patterns of care and predictors of mortality. *Arch Surg* 2009;144(05):433–439, discussion 439–440
- 59 Abou Khalil M, Bhatnagar SR, Feldman L, et al. Development and validation of a clinical risk calculator for mortality after colectomy for fulminant *Clostridium difficile* colitis. *J Trauma Acute Care Surg* 2019;87(04):856–864
- 60 Ahmed N, Kuo YH, Guinto RK, Purewal J. Risk factors of surgical mortality in patients with *Clostridium difficile* colitis. A novel scoring system. *Eur J Trauma Emerg Surg* 2022;48(03): 2013–2022
- 61 Kulaylat AS, Kassam Z, Hollenbeak CS, Stewart DB Sr. A surgical clostridium-associated risk of death score predicts mortality after colectomy for *Clostridium difficile*. *Dis Colon Rectum* 2017;60 (12):1285–1290
- 62 Peprah D, Chiu AS, Jean RA, Pei KY. Comparison of outcomes between total abdominal and partial colectomy for the management of severe, complicated *Clostridium Difficile* infection. *J Am Coll Surg* 2019;228(06):925–930
- 63 Neal MD, Alverdy JC, Hall DE, Simmons RL, Zuckerbraun BS. Diverting loop ileostomy and colonic lavage: an alternative to total abdominal colectomy for the treatment of severe, complicated *Clostridium difficile* associated disease. *Ann Surg* 2011;254 (03):423–427, discussion 427–429
- 64 Hall BR, Leinicke JA, Armijo PR, Smith LM, Langenfeld SJ, Oleynikov D. No survival advantage exists for patients undergoing loop ileostomy for *Clostridium difficile* colitis. *Am J Surg* 2019;217 (01):34–39
- 65 Juo YY, Sanaiha Y, Jabaji Z, Benharash P. Trends in diverting loop ileostomy vs total abdominal colectomy as surgical management for *Clostridium difficile* colitis. *JAMA Surg* 2019;154(10):899–906
- 66 Felsenreich DM, Gachabayov M, Rojas A, Latifi R, Bergamaschi R. Meta-analysis of postoperative mortality and morbidity after total abdominal colectomy versus loop ileostomy with colonic lavage for fulminant *Clostridium difficile* colitis. *Dis Colon Rectum* 2020;63(09):1317–1326