




Processed Electroencephalogram in Intracranial Hypertension and Brain Hypoperfusion: A Case Report

César A. Martínez-de los Santos¹  Luis C. Becerra-Lio² Edwin O. Guillén-Ramírez²
Luis A. Pérez-Ruano³ Jose A. Figueroa-Sanchez³

¹Department of Anesthesiology, Hospital Zambrano Hellion TecSalud; School of Medicine and Health Sciences of the Tecnológico de Monterrey, Nuevo León, México.

²Department of Anesthesiology Resident Doctor Multicenter Medical Specialties Program TecSalud, Tecnológico de Monterrey, Nuevo León, México.

³Department of Neurosurgery, Hospital Zambrano Hellion TecSalud; School of Medicine and Health Sciences of the Tecnológico de Monterrey, Nuevo León, México.

Address for correspondence César A. Martínez-de los Santos, MD, MSc, Av. Batallon de San Patricio 112, Real San Agustín 66260 San Pedro Garza García, Nuevo León, México
(e-mail: cesarmartinez.md@tec.mx).

J Neuroanaesthesiol Crit Care

Abstract

Processed electroencephalogram (pEEG) is a record of electrical activity of the brain. In certain circumstances, it can reflect pathophysiological alterations and hemodynamic compromise. A 79-year-old woman diagnosed with subarachnoid hemorrhage and postcardiac arrest status was transferred for emergency ventriculostomy. The frontal monitoring with pEEG (SedLine, Masimo) from baseline showed low frontal activity, left and right spectral edge frequency (SEF) without numerical value, low activity in bilateral density spectral array (DSA), and zero in the patient state index (PSI). After ventricular puncture and placement of the ventriculostomy system, the pEEG showed an increase in the frequency and amplitude of the four-channel waveform of the pEEG, DSA, and numerical value of SEF and PSI. The use of pEEG can determine the depth of anesthesia and perhaps detect various cerebral and systemic pathophysiological and hemodynamic alterations; however, single monitoring may not be as predictive, so the use of multimodal monitoring is recommended.

Keywords

- ▶ neuromonitoring
- ▶ processed electroencephalography
- ▶ cerebral protection
- ▶ brain hypoperfusion
- ▶ safety

Introduction

Processed electroencephalogram (pEEG) is a noninvasive monitoring technique that registers electrical brain activity. The proximity of the sensor to the rostral structures of the brain through the scalp detects the neural function of the cerebral cortex, which is related to patient awareness, consciousness, brain function, and metabolism.^{1–4}

Changes in cerebral blood flow (CBF), intracranial hypertension (ICH), cerebral hypoxia, hypoperfusion, ischemia,

and nonconvulsive status epilepticus can result in alterations that may be observed in the pEEG independent of anesthetic drug effects.^{1,5} Therefore, in certain circumstances, these changes can help in the timely detection of pathophysiological alterations and hemodynamic compromise as part of multimodal monitoring.^{1,2}

This manuscript adheres to applicable CARE guidelines. Written consent was obtained from the patient's relatives for the publication of this clinical case without showing images or personal data of the patient.

DOI <https://doi.org/10.1055/s-0043-1777442>.
ISSN 2348-0548.

© 2024. The Author(s).

This is an open access article published by Thieme under the terms of the Creative Commons Attribution License, permitting unrestricted use, distribution, and reproduction so long as the original work is properly cited. (<https://creativecommons.org/licenses/by/4.0/>)
Thieme Medical and Scientific Publishers Pvt. Ltd., A-12, 2nd Floor, Sector 2, Noida-201301 UP, India

Case Report

A 79-year-old woman was brought to our hospital by their relatives with a suddenly altered level of consciousness and 11 points in Glasgow coma scale (eye response: 3; verbal response: 4; motor response: 4).

At the emergency room, the patient presents cardiorespiratory arrest, and advanced cardiopulmonary resuscitation maneuvers were started by the emergency room staff; 4 minutes later, she presented return of spontaneous circulation, data of severe brain injury with a scale score of FOUR = 6 (E0, M0, B4, R2). Endotracheal intubation was performed and intravenous (IV) infusion of propofol (30 $\mu\text{g}/\text{kg}/\text{min}$) and norepinephrine (0.08 $\mu\text{g}/\text{kg}/\text{min}$) was started.

Computed tomography (CT) scan revealed a Fisher IV subarachnoid hemorrhage and ICH. The American Society of Anesthesiologists (ASA) physical status V was assigned. After 40 minutes of return of spontaneous circulation, the patient was transferred to the operating room for placement of an external ventricular drain, with an invasive mechanical ventilation support, central venous access, arterial line for invasive pressure, an infusion of IV propofol and norepinephrine.

Initial monitoring upon admission to the operating room was heart rate (HR), respiratory rate (RR), noninvasive blood pressure (NIBP), invasive blood pressure (IBP), and Foley probe, and a frontal sensor was placed to monitor the depth of anesthesia with pEEG (SedLine, Masimo, 52 Discovery, Irvine, CA, United States). Their baseline vital signs were as follows: HR, 93 beats per minute (bpm); RR, 12 breaths per minute (bpm); end-tidal carbon dioxide (EtCO_2), 34 mm Hg; peripheral oxygen saturation (SpO_2) 98%; temperature of 36.9°C; blood pressure, 105/56 mm Hg; and mean arterial pressure (MAP), 72 mm Hg with vasopressor support.

Mechanical ventilation was started with pressure-controlled ventilation volume-guaranteed mode. The ventilatory parameters included 45% FiO_2 , 450 mL tidal volume, 12 bpm RR, 18 mm Hg peak inspiratory pressure, 4 mm Hg positive end-expiratory pressure, and 34 mm Hg EtCO_2 .

The pEEG showed from its placement low basal frontal waveform electroencephalographic activity, 98% suppression ratio, left spectral edge frequency (SEF-L) and right spectral edge frequency (SEF-R) without numeric values, low activity in the bilateral density spectral array (DSA), and zero on the patient state index (PSI; **► Fig. 1**).

With the aim of decreasing cerebral metabolism and thereby intracranial pressure (ICP), the propofol infusion was continued at the same dose and added IV lidocaine infusion at 30 $\mu\text{g}/\text{kg}/\text{min}$. An IV bolus of 2 $\mu\text{g}/\text{kg}$ fentanyl was administered continued by infusion of 0.039 $\mu\text{g}/\text{kg}/\text{min}$. Norepinephrine (0.08 $\mu\text{g}/\text{kg}/\text{min}$) was continued with the aim of maintaining adequate cerebral and systemic perfusion with a minimum target MAP of 85 mm Hg. Anesthetic and vasopressor infusions were maintained at the same dose until the end of the procedure. Therefore, there were no boluses or important variations in the dosage of these drugs.

The basal arterial blood gas test showed the following results: hydrogen potential (pH), 7.18; partial pressure of

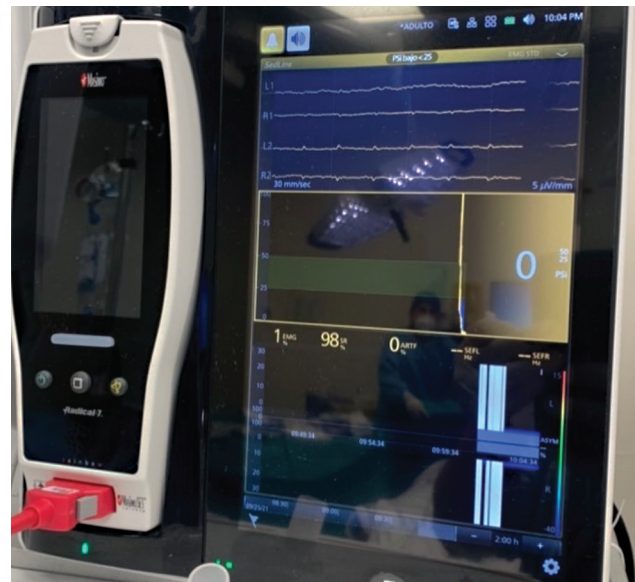


Fig. 1 Low basal frontal waveform electroencephalographic activity; 98% suppression ratio; spectral edge frequency (SEF) without numeric value; low activity in the bilateral density spectral array (DSA), and zero on the patient state index (PSI).

oxygen (PaO_2), 84 mm Hg; partial pressure of carbon dioxide (PCO_2), 41 mm Hg; arterial bicarbonate (HCO_3), 15.3 mm Hg; base excess (BE), -12; hemoglobin (Hb), 7.8 mg/dL; hematocrit (Hct), 25%; lactate, 3.7 mg/dL; and glucose, 338 mg/dL.

In the pEEG trend, we can see a summary of the low brain electrical activity during the first part of the procedure; after approximately 5 minutes after ventricular puncture and placement of the external ventricular drainage catheter system, an increase in brain electrical activity in the four-channel waveform frequency was identified in the pEEG. Between minutes 10 and 15, an increase in the trend, SEF, DSA, and PSI were observed (**► Fig. 2**).

Because the patient showed 7.8 mg/dL of hemoglobin and 25% of hematocrit in arterial blood gases, a globular package (255 mL) and a fresh frozen plasma (143 mL) were transfused. The final arterial blood gas test showed the following results: pH, 7.25; PaO_2 , 122 mm Hg; PCO_2 , 36 mm Hg; HCO_3 , 18.3 mm Hg; BE, -6; Hb, 9.6 mg/dL; Hct, 28%; lactate, 2.8 mg/dL; and glucose, 196 mg/dL.

After the increase and maintenance in pEEG activity, the propofol infusion was increased to 60 $\mu\text{g}/\text{kg}/\text{min}$. The patient was transferred to the intensive care unit under invasive mechanical ventilation, fentanyl 0.026 $\mu\text{g}/\text{kg}/\text{min}$, and norepinephrine 0.08 $\mu\text{g}/\text{kg}/\text{min}$. The vital signs were the following: HR, 84 bpm; blood pressure, 112/71 mm Hg; MAP, 84 mm Hg; RR, 12 bpm; EtCO_2 , 34 mm Hg; SpO_2 , 98%; temperature, 36.8°C and PSI 53. Unfortunately, the patient died 26 days after his hospital stay.

Discussion

Various authors agree that despite its diffusion and its simplicity in its use and interpretation,² pEEG has not

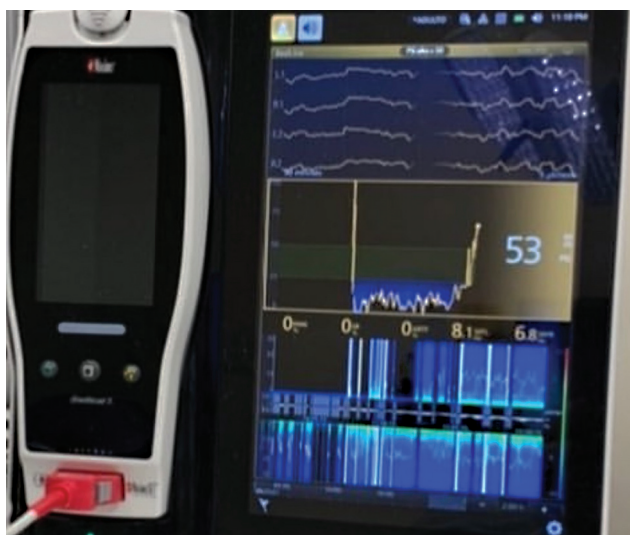


Fig. 2 Increase in four-channel waveform frequency, spectral edge frequency (SEF), density spectral array (DSA), and patient state index (PSI), with 0% suppression ratio.

been designated as standard monitoring by anesthesiology societies.^{3,4}

Brain cortical activity is modulated by anesthetic drugs, and various exogenous and endogenous stimuli and electroencephalogram readings are closely related to brain metabolism. Age, temperature, hydroelectrolytic and acid-base disorders, and hypoglycemia may be observed in the alteration of electroencephalogram and pEEG waveforms.¹

Diverse studies have shown that pEEG allows the identification of intracranial hemodynamic events, such as aneurysm rupture, vasospasm, neurovascular coupling, CBF autoregulation, changes in ICP, hypoperfusion, and ischemia,^{6–9} so neuromonitoring is recommended in neurocritical patients.¹⁰

In the event of a cardiac arrest, electroencephalogram and pEEG activity during cardiopulmonary resuscitation may be modified by alterations in circulation and brain perfusion. Isoelectric electroencephalogram and/or burst suppression may be indicative of adverse neurological outcomes.⁵ The use of pEEG in neurocritical and neurosurgical patients has great potential in the investigation of function, blood flow, and cerebral autoregulation, as well as for a better understanding of the physiology of consciousness and the mechanisms of action of anesthetic drugs, with the ultimate goal of improving postoperative outcomes and reducing complications.

In this case report, changes in the electroencephalogram may be possible due to possible changes secondary to the postcardiac arrest state, subarachnoid hemorrhage, and hypoperfusion secondary to ICH or systemic hypotension especially due to the age and diagnosis of the patient. The authors consider it a possibility that the increase in electroencephalographic activity after placement of a ventriculos-

tomy placement was due to a decrease in ICP and an improvement in CBF. A low blood pressure may not be sufficient to perfuse the brain and cerebrospinal fluid (CSF) drainage could have reduced ICP, restoring perfusion, which may be a speculation on the findings. However, the change was highly significant and almost immediately after placement of the CSF drain. A comparison between basal and final optic nerve sheath measurements may have increased the possibility of diagnosing ICH; however, this was not performed because of the urgency of the surgical procedure. Despite the poor prognosis of the patient on admission, changes in pEEG proved that the patient was treated promptly.

Conclusion

Common use of pEEG in neurocritical and neurosurgical patients can have important advantages, such as evaluation of the anesthetic depth, perhaps with the possibility of detecting various pathophysiological and hemodynamic cerebral and systemic alterations. Because the changes in this patient's pEEG could have been due to several different factors, it is not possible to conclude that the change was solely due to a decrease in ICP and an improvement in CBF following ventriculostomy placement. Single monitoring cannot be as predictive. Multimodality monitoring should be used in concordance with clinical examination and then patient-specific inferences should be made.

Conflict of Interest

None declared.

Acknowledgments

We would like to thank Editage (www.editage.com) for English-language editing.

References

- Montupil J, Defresne A, Bonhomme V. The raw and processed electroencephalogram as a monitoring and diagnostic tool. *J Cardiothorac Vasc Anesth* 2019;33(Suppl 1):S3–S10
- Purdon PL, Sampson A, Pavone KJ, Brown EN. Clinical electroencephalography for anesthesiologists: part I—background and basic signatures. *Anesthesiology* 2015;123(04):937–960
- Li Y, Bohringer C, Liu H. Double standard: why electrocardiogram is standard care while electroencephalogram is not? *Curr Opin Anaesthesiol* 2020;33(05):626–632
- Mashour GA, Woodrum DT, Avidan MS. Neurological complications of surgery and anaesthesia. *Br J Anaesth* 2015;114(02):194–203
- Caballero Á, Benet P, Bobi J, Fontanals J, Magaldi M, Mérida E. Bispectral index in an experimental model of cardiac arrest: monitoring during cardiopulmonary resuscitation. *Resuscitation* 2019;142:e8
- Foreman B, Claassen J. Quantitative EEG for the detection of brain ischemia. *Crit Care* 2012;16(02):216
- Ajčević M, Furlanis G, Miladinović A, et al. Early EEG alterations correlate with CTP hypoperfused volumes and neurological

- deficit: a wireless EEG study in hyper-acute ischemic stroke. *Ann Biomed Eng* 2021;49(09):2150–2158
- 8 Sanz-García A, Pérez-Romero M, Pastor J, et al. Identifying causal relationships between EEG activity and intracranial pressure changes in neurocritical care patients. *J Neural Eng* 2018;15(06):066029
 - 9 Canac N, Jalaeddini K, Thorpe SG, Thibeault CM, Hamilton RB. Review: pathophysiology of intracranial hypertension and non-invasive intracranial pressure monitoring. *Fluids Barriers CNS* 2020;17(01):40
 - 10 Sharma D. Perioperative management of aneurysmal subarachnoid hemorrhage. *Anesthesiology* 2020;133(06):1283–1305