



Endovascular Repair of Zone 0 Ascending Aortic Pseudoaneurysm: A Case Report

Sarah Halbert, MD^{1,2} Christian Nagy, MD^{1,3} Jared Antevil, MD^{1,4} Shawn Sarin, MD^{1,5}
Gregory Trachiotis, MD^{1,4}

¹Division of Cardiothoracic Surgery, Heart Center, Veterans Affairs Medical Center, Washington, District of Columbia

²Department of Surgery, MedStar Georgetown University Hospital, Washington, District of Columbia

³Department of Cardiology, George Washington University School of Medicine and Health Sciences and Veterans Affairs Medical Center, Washington, District of Columbia

⁴Department of Surgery, George Washington University School of Medicine and Health Sciences, Washington, District of Columbia

Address for correspondence Gregory Trachiotis, MD, Division of Cardiothoracic Surgery, Heart Center, Veterans Affairs Medical Center, 50 Irving St NW, Washington, DC 20422 (e-mail: Gregory.Trachiotis@va.gov).

⁵Department of Radiology, Interventional Radiology, George Washington University, School of Medicine and Health Sciences, Washington, District of Columbia

Aorta (Stamford) 2023;11:152–155.

Abstract

Keywords

- ▶ ascending aorta
- ▶ TEVAR
- ▶ stent grafting
- ▶ landing zone

Although open surgery is standard of care for ascending aortic pathology, endovascular approaches can be viable options. We report the case of a 77-year-old man with a 5.7-cm ascending aorta penetrating ulcer. Given his age and clinical profile, the patient underwent Zone 0 thoracic endovascular aortic repair.

Introduction

Open surgery is the gold standard for treatment of ascending aortic disease. However, it is sometimes chosen due to a lack of minimally invasive options. Thoracic endovascular aortic repair (TEVAR) for the treatment of ascending aortic pathology has been used selectively since it was first described in 2000.¹ Here, we report the successful treatment of a Zone 0 penetrating aortic ulcer (PAU) utilizing stent-graft deployment.

Case Presentation

A 77-year-old man established care with our service for follow-up of a known ascending aortic PAU after relocating from another state. Reportedly, the PAU had measured 4.2 cm in 2017 and had increased to 5 cm prior to relocation. At presentation to our department, the patient denied chest pain and had a history of hypertension controlled with medication.

Repeat imaging showed saccular aneurysmal dilation of the ascending aorta measuring up to 5.7 × 4.5 cm. The saccular component of the PAU itself was 3.4 cm in diameter (▶ **Fig. 1**). He had no history of coronary disease, no significant coronary calcification on computed tomography angiography (CTA), no aortic valve disease, and an ejection fraction of 55% on echocardiography. Based on the rapid increase in size and characteristics of his PAU, intervention was indicated. Proximal and distal areas in Zone 0 showed adequate landing zones for a standard TEVAR graft. Based on his imaging, age, and functional limitations, the patient qualified for either an open or endovascular procedure. Both options were discussed at length with the patient, who expressed a preference for TEVAR. The case was discussed in multidisciplinary forum, which included cardiothoracic surgery, structural interventional cardiology, and interventional radiology, with consensus for feasibility of TEVAR.

received
August 3, 2023
accepted after revision
November 8, 2023

DOI <https://doi.org/10.1055/s-0043-1777436>.
ISSN 2325-4637.

© 2024. The Author(s).

This is an open access article published by Thieme under the terms of the Creative Commons Attribution-NonDerivative-NonCommercial-License, permitting copying and reproduction so long as the original work is given appropriate credit. Contents may not be used for commercial purposes, or adapted, remixed, transformed or built upon. (<https://creativecommons.org/licenses/by-nc-nd/4.0/>)

Thieme Medical Publishers, Inc., 333 Seventh Avenue, 18th Floor, New York, NY 10001, USA

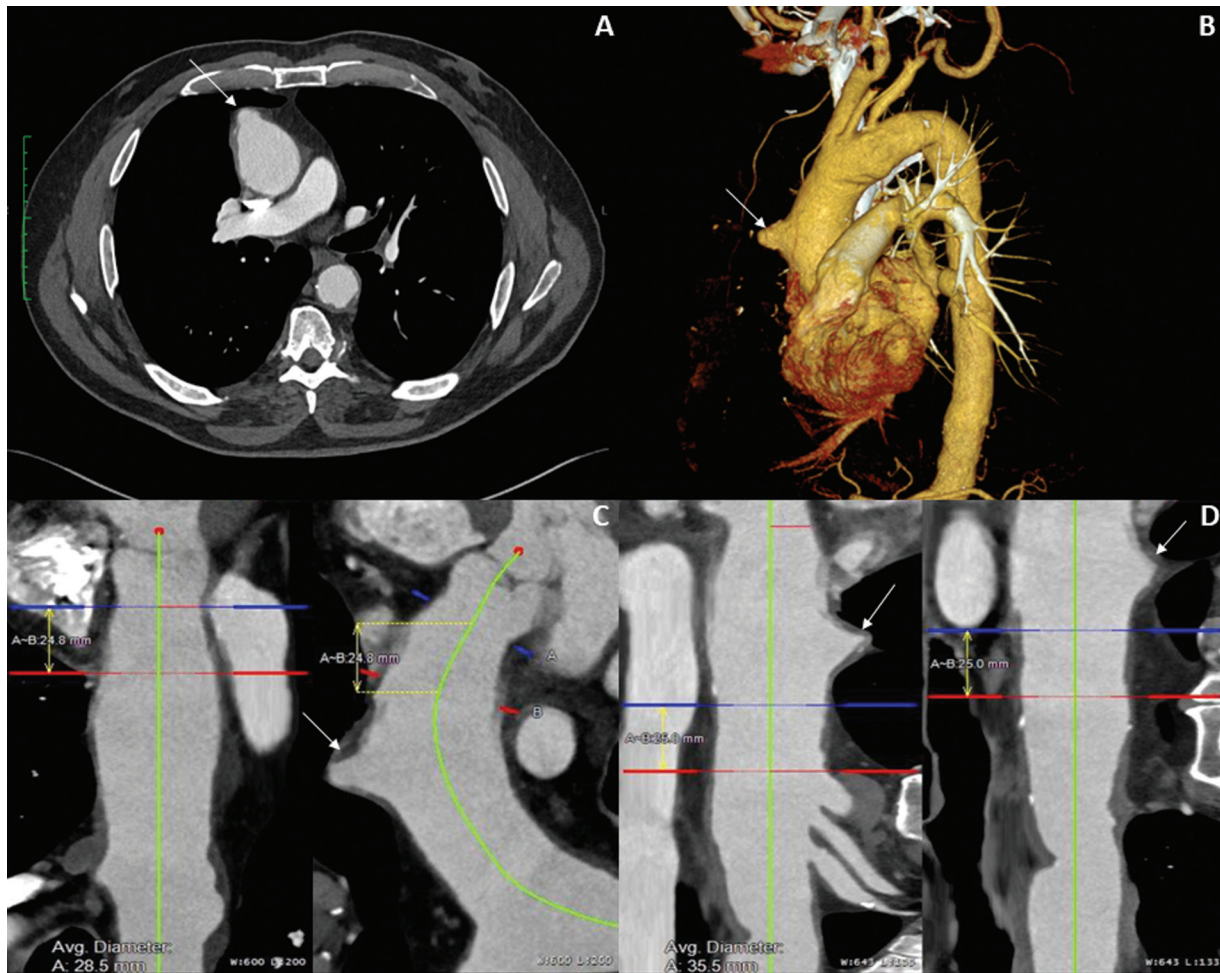


Fig. 1 Preoperative axial (A) and 3D-reconstruction (B) Computed tomography angiography images demonstrating ascending aortic penetrating ulcer (arrows). Curved planar reformats with corresponding measurements of average proximal (C) and distal (D) landing zone diameters are also shown.

The procedure was performed in a hybrid operative suite with all multidisciplinary teams present and a cardiac anesthesiologist. With the patient under general anesthesia, ultrasound guided access was obtained in the right radial, right common femoral, and left common femoral arteries (CFA). The so called “preclose” technique with Proglide vascular closure devices (Abbott Laboratories, North Plymouth, MN) was employed at the right femoral access. Coronary angiography was performed via right radial access to mark the level of the coronary arteries. The heights of the coronary arteries were low, embedded in the aortic valve, with ample room for proximal stent deployment. Coronary disease was seen, which had not been delineated on preoperative CTA. The patient had 100% occlusion of the left anterior descending artery (LAD), mitigated by brisk refill through collateralization. He also had a high-grade lesion of the midcircumflex artery (80% occlusion). Given the absence of angina and adequate collateral flow, no coronary intervention was felt to be indicated.

The right CFA access was serially dilated to accommodate a 24-Fr Gore DrySeal introducer sheath (W.L. Gore & Associates, Flagstaff, AZ). The ascending aorta was catheterized

with a pigtail flush catheter advanced from left CFA access. The image intensifier was placed in left-anterior-oblique angulation. Arch aortogram showed the penetrating ulcer in Zone 0. The origins of the great vessels were in standard configuration and widely patent. From right CFA access, a pigtail was advanced through the aortic valve, and a Lunderquist wire (Cook Medical, Bloomington, IN) was advanced into the left ventricle and used for cardiac pacing. A conformable-TAG (W.L. Gore & Associates, Flagstaff, AZ) 45 mm × 45 mm × 10 cm was passed from the right groin and positioned with seal on either side of the PAU. The device was deployed and seated during a brief period of rapid ventricular pacing, with no migration. Subsequent aortogram showed no evidence of endoleak and complete exclusion of the ulcer. The origins of the great vessels were preserved, and placement was above the aortic valve and coronaries (►Fig. 2). Hemostasis was achieved with the “preclose” technique. Pedal pulses were unchanged at the end of the case. The patient was extubated, neurologically intact, and transferred to the intensive care unit. CTA after 1 month demonstrated appropriate graft placement without evidence of leak (►Fig. 3).

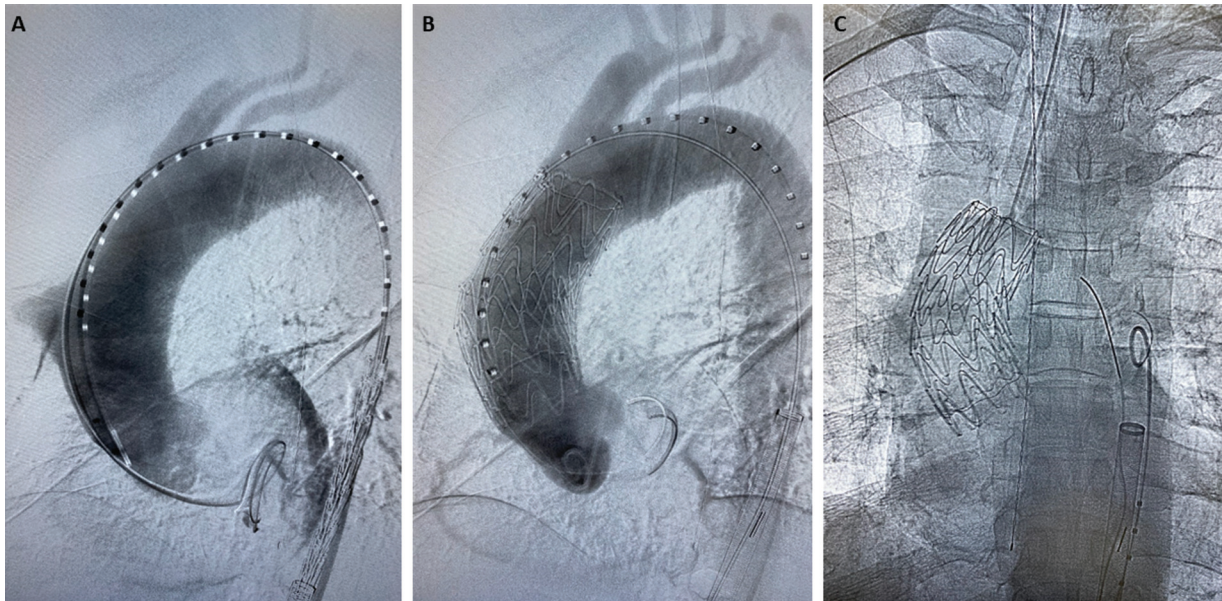


Fig. 2 Intraoperative angiogram prior to (A) and following (B) deployment of stent-graft in the ascending aorta. Final positioning is also shown (C).

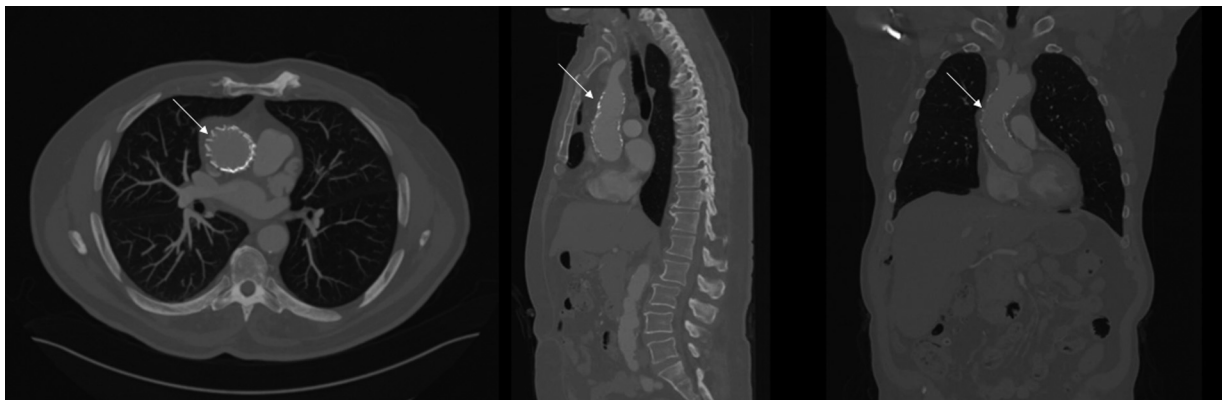


Fig. 3 Computed tomography angiography 1 month postoperatively: appropriate graft placement (arrows) without evidence of leak.

Discussion

TEVAR has been safely and effectively used in descending aortic disease for years.² In selected cases, standard TEVAR grafts have been employed in the management of ascending aortic disease; there is enthusiasm for an endovascular approach to Zone 0 disease with approved branched grafts and others on the horizon.³⁻⁷ The gold standard for treating Zone 0, which includes the sinotubular junction, ascending aorta, and base of arch vessels, remains open surgery. Endovascular approaches face multiple challenges. They require suitable landing zones, adequate aortic diameter, and careful stent-graft selection and deployment and are threatened by the increased shear stress within the ascending aorta, which can result in device migration.⁵ Because of the significance of regional anatomy, our program has elected to incorporate an Aortic “Zone 0 team” including cardiothoracic surgery, structural interventional cardiology, and interventional radiology to assess adequacy of TEVAR, appropriate diagnosis, and preparations for potential pitfalls during the procedure. In

our patient, the positioning of coronary orifices coupled with ample proximal and distal landing zones dictated that a standard graft could be used without occluding the coronary arteries or aortic arch vessels. To mitigate concerns over device migration, we opted to utilize rapid ventricular pacing during deployment. As seen on postoperative CTA, the device has remained in place with no signs of dissection or migration after 1 month.

Proper imaging of the aorta and careful determination of suitable landing zones are key for patient selection and operative planning. Graft selection is also critical, since problems can arise secondary to aortic curvature, the distance between the sinotubular junction and innominate artery, and the coronary artery orifices. Currently, there are no Food and Drug Administration-approved devices for use in the ascending aorta. However, multiple techniques, including physician modified grafts, chimney or periscope techniques, in situ fenestration, fenestrated grafts, and branched grafts have met with some success.³⁻⁵ There are

also several novel devices under development. One dedicated stent-graft for the ascending aorta (Zenith Ascend TAA Endovascular Graft, William Cook Europe, Bjaeverskov, Denmark) has shown promising early results in selected high-risk patients,⁶ and a second designed for the aortic arch (Terumo RelayBranch, Terumo Aortic, Sunrise, FL) is undergoing feasibility studies in the United States.⁷

One of the potentially life-threatening complications after TEVAR is Type A aortic dissection. While the precise mechanism remains a topic of debate, studies have identified an association with proximal landing zone, particularly Zone 0.⁸ Proximal stent-graft configuration and oversizing have also been identified as potential contributors.⁸ As the number of Zone 0 cases being performed endovascularly increases, additional research is critical to developing an in-depth understanding of the associated risks, allowing surgeons to better guide their patients in decision-making.

TEVAR for ascending aortic pathology can be safely and successfully performed. In anatomically amenable cases and with appropriate graft selection, TEVAR for selected Zone 0 aortic pathologies is an appropriate choice of therapy for patients utilizing a Zone 0 aortic team approach. However, further study is still needed, especially as specialized devices are developed and additional outcomes data become available.

Funding

None.

Conflict of Interest

The authors declare no conflict of interest related to this article.

Acknowledgments

The authors thank Matt Silva (Gore Medical) for assistance with 3D-reconstructions and case planning.

References

- 1 Dorros G, Dorros AM, Planton S, O'Hair D, Zayed M. Transseptal guidewire stabilization facilitates stent-graft deployment for persistent proximal ascending aortic dissection. *J Endovasc Ther* 2000;7(06):506-512
- 2 Verhoeven EL, Katsargyris A, Bekkema F, et al. Editor's choice - ten-year experience with endovascular repair of thoracoabdominal aortic aneurysms: results from 166 consecutive patients. *Eur J Vasc Endovasc Surg* 2015;49(05):524-531
- 3 Al-Hakim R, Schenning R. Advanced techniques in thoracic endovascular aortic repair: chimneys/periscopes, fenestrated endografts, and branched devices. *Tech Vasc Interv Radiol* 2018;21(03):146-155
- 4 Glorion M, Coscas R, McWilliams RG, Javerliat I, Goëau-Brissonniere O, Coggia M. A comprehensive review of in situ fenestration of aortic endografts. *Eur J Vasc Endovasc Surg* 2016;52(06):787-800
- 5 van Bakel TM, de Beaufort HW, Trimarchi S, et al. Status of branched endovascular aortic arch repair. *Ann Cardiothorac Surg* 2018;7(03):406-413
- 6 Tsilimparis N, Debus ES, Oderich GS. International experience with endovascular therapy of the ascending aorta with a dedicated endograft. *J Vasc Surg* 2016;63(06):1476-1482
- 7 A prospective, multicenter, non-blinded, non-randomized early feasibility study of the relay branch thoracic stent-graft system in subjects with thoracic aortic pathologies requiring treatment proximal to the origin of the innominate artery. *ClinicalTrials.gov* identifier: NCT03214601. Accessed March 15, 2022, at: clinicaltrials.gov.
- 8 Chen Y, Zhang S, Liu L, Lu Q, Zhang T, Jing Z. Retrograde Type A aortic dissection after thoracic endovascular aortic repair: a systematic review and meta-analysis. *J Am Heart Assoc* 2017;6(09):e004649