



# Radiographic Evolution of Scaphotrapezium Coalition Trough Carpal Ossification

## *Evolución radiológica de coalición entre escafoides y trapecio a lo largo de la ósificación del carpo*

Estefanía Olmedo Martín<sup>1</sup>  José Tomás López Salinas<sup>1</sup> Carlos Morales Sánchez-Migallón<sup>1</sup>

<sup>1</sup> Orthopedic Surgery and Traumatology, General University Hospital of Ciudad Real, Calle Obispo Rafael Torija, Spain

Address for correspondence Estefanía Olmedo Martín, MD, Calle Obispo Rafael Torija, Spain (e-mail: estefaniaolmed@gmail.com).

Rev Iberam Cir Mano 2023;51(2):e124–e128.

### Abstract

Carpal coalitions are anatomy variants, consisting of the union of two or more carpal bones. The incidence is low, usually being an incidental diagnosis. Describing the radiographic development through carpal ossification is our objective concerning a clinical case. Our patient is a 15-year-old male, who suffers repeated scaphoid fractures. He was diagnosed with bilateral non-osseous carpal coalitions in the follow-up. The patient had previous radiographs of his left wrist through infancy until skeletal maturation was observed. Thus, it was possible to compare them to reference images of normal skeletal maturation, showing the strongest differences after carpal ossification. Carpal coalitions are scarce, and the diagnosis is only possible after skeletal maturation, showing a higher risk of mechanical stress and present fractures than the general population.

### Keywords

- ▶ carpal coalition
- ▶ synchondrosis
- ▶ synostosis
- ▶ osteogenesis
- ▶ bone development

### Resumen

Las coaliciones carpianas son la unión de dos o más huesos del carpo. Presentan una baja incidencia, siendo el diagnóstico incidental. Nuestro objetivo es describir la evolución radiográfica de esta malformación durante la osificación a propósito de un caso. Varón de 15 años, con fracturas repetidas de escafoides derecho, al que se diagnostica de coalición entre escafoides y trapecio no ósea bilateral tras estudio complementario. El paciente contaba previamente con controles radiográficos de la muñeca izquierda desde la infancia hasta la maduración esquelética. Todos los huesos del carpo se osifican a partir de un núcleo primario de osificación, apareciendo secuencialmente. Comparando los controles radiográficos con las series óseas de referencia, se acentúan las diferencias a partir de los 9 años, al finalizar la osificación. Las coaliciones carpianas son poco frecuentes y pasan desapercibidas hasta la maduración esquelética del carpo. Presentan una mayor susceptibilidad al estrés mecánico, y mayor riesgo sufrir fracturas tras traumatismos.

### Palabras clave

- ▶ coalición carpiana
- ▶ sincondrosis
- ▶ sinostosis
- ▶ osificación
- ▶ maduración ósea

received  
October 20, 2022  
accepted  
October 9, 2023

DOI <https://doi.org/10.1055/s-0043-1777112>.  
ISSN 1698-8396.

© 2023. SECMA Foundation. All rights reserved.

This is an open access article published by Thieme under the terms of the Creative Commons Attribution-NonDerivative-NonCommercial-License, permitting copying and reproduction so long as the original work is given appropriate credit. Contents may not be used for commercial purposes, or adapted, remixed, transformed or built upon. (<https://creativecommons.org/licenses/by-nc-nd/4.0/>)

Thieme Revinter Publicações Ltda., Rua do Matoso 170, Rio de Janeiro, RJ, CEP 20270-135, Brazil

## Introduction

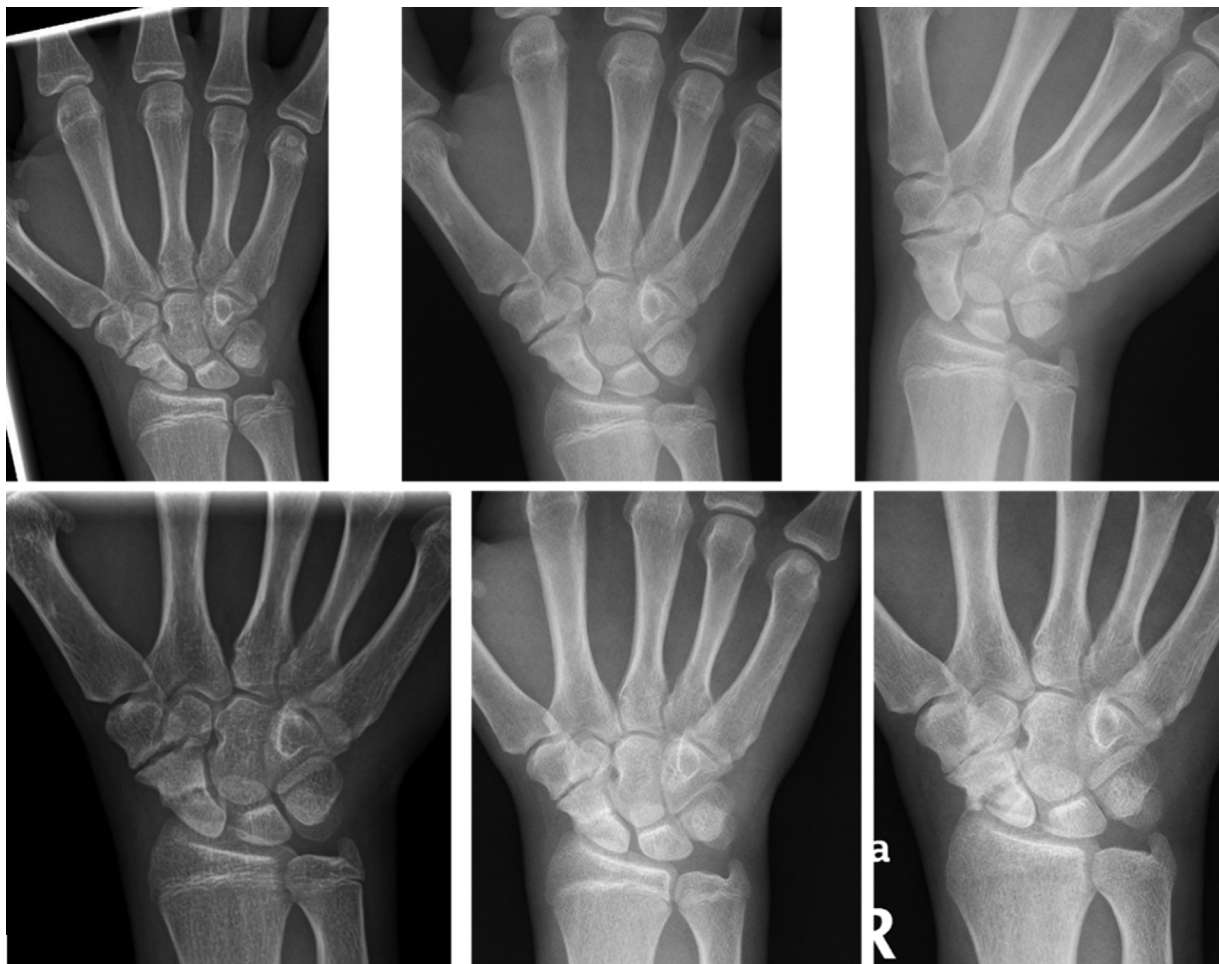
A carpal coalition is the union of two or more carpal bones.<sup>1</sup> They are considered anatomical variations present in a low percentage of the population, around 0.1%, reaching a prevalence of up to 9% in the west of the African continent.<sup>2</sup> It is more common in women, generally bilaterally and symmetrically affected, and is a genetically hereditary entity, following an autosomal dominant inheritance pattern.<sup>1</sup> Its appearance is related to failures in the joint cavitation process,<sup>3,4</sup> so more frequently it affects bones in the same carpal row and bilaterally. The most common are those that appear between semilunar - pyramidal,<sup>3,4</sup> and between large - hamate.<sup>1</sup> The least common is the scaphoid-trapezoidal, which usually appears in the context of malformation syndromes.<sup>3</sup>

The diagnosis of these entities is usually incidental, being a casual finding when performing a wrist x-ray after a trauma,<sup>5</sup> therefore their evolution throughout growth has not been previously described. We intend to present the radiographic evolution of this malformation regarding a case, considering the theories proposed for the appearance of this malformation in the available literature.

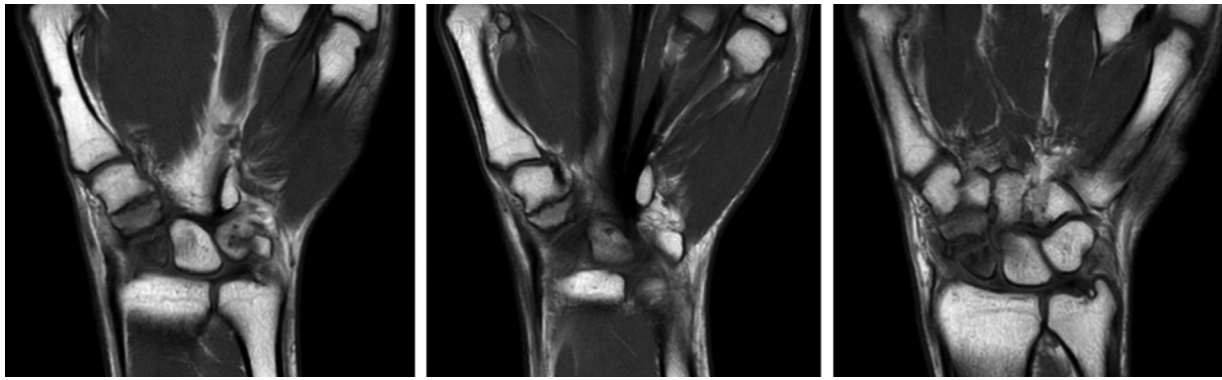
## Clinical Case

The patient is a 15-year-old white male, referred to the trauma clinic diagnosed in the emergency room with a fracture of the right scaphoid, after suffering a casual fall on that extremity. In less than 1 year he suffered another trauma to the same wrist, again presenting a fracture of the right scaphoid. Both episodes received conservative management by placing the corresponding closed casts. During follow-up, a non-bony carpal coalition was detected between the scaphoid and trapezium (►Figure 1). Furthermore, the appearance of a scaphoid pseudoarthrosis developed after the second traumatic event on the scaphoid is notable, requiring an MRI of the right wrist (►Figure 2).

When radiographs of the contralateral wrist were requested, a carpal coalition between the scaphoid and trapezium was also seen. Reviewing the history, the patient was treated with growth hormone (GH) for years from the age of 6 to 17 due to hypogrowth. During this time, he was subjected to periodic bone age controls using x-rays of the hand and wrist of the left upper limb, where the development of the carpus and the scapho-trapezoidal coalition can be seen upon reaching bone maturity (►Figure 3). To confirm



**Fig. 1** In these images we see the radiographic evolution of the right wrist after successive traumas; from top to bottom and left to right: 1–X-ray of the first scaphoid fracture (15 years), 2 and 3–consolidation begins at 8 months, 4–second trauma to the right wrist suffering a scaphoid fracture again, 5 and 6–control after conservative treatment of this second traumatic episode.



**Fig. 2** MRI images of the right wrist, diagnosis of carpal coalition type synchondrosis between trapezium and scaphoid, associated with a scaphoid pseudoarthrosis.

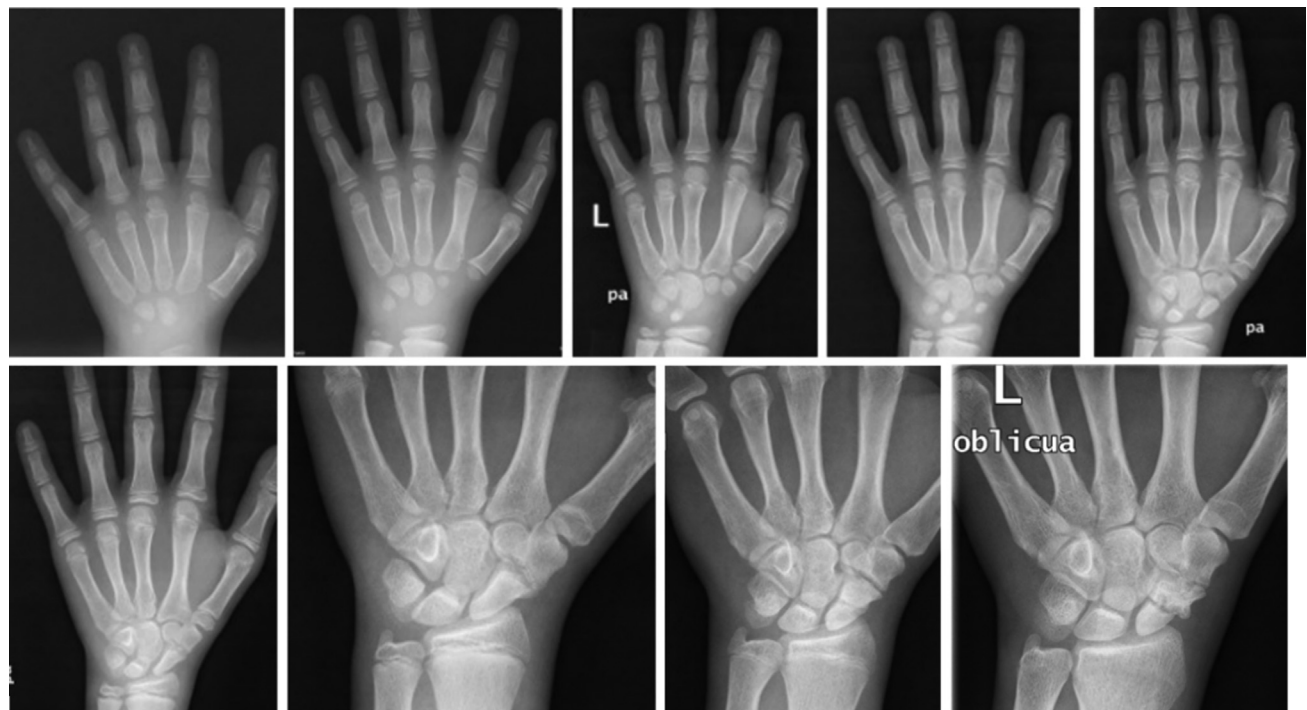the diagnosis of bilateral non-osseous scaphotrapezium carpal coalition, an MRI of the left wrist is requested, for a better assessment of the relationship between the two bones (→ **Figure 4**). Furthermore, scaphoid pseudoarthrosis is also observed in its proximal region, despite the lack of previous trauma reported by the patient in the left extremity. This pseudoarthrosis was a chance finding, without the patient showing related symptoms, so it was decided to opt for expectant management with follow-up consultations.

## Discussion

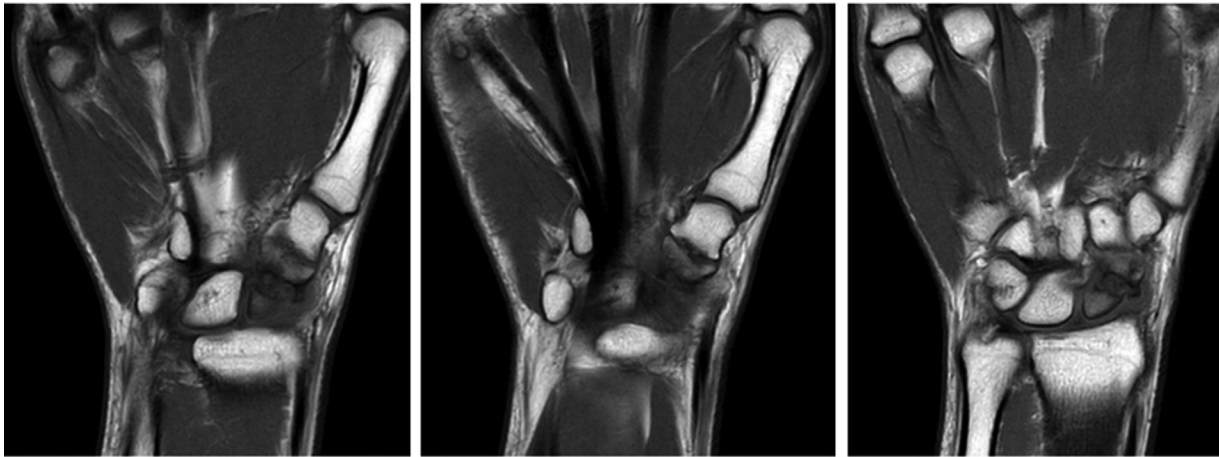
The appearance of coalitions is related to the failure in the separation process of the cartilaginous interzone between the adjacent carpal bones, which occurs between 4–8 weeks of gestation. This interface is made up of 3 layers: two denser

ones, which will become the articular cartilage, separated by one of lower density, from which the synovial and intra-capsular structures will be formed. This theory is applied to those coalitions that affect bones of the same carpal row and to those that share the same ossification rhythm. For the pisiform bone, which appears between 9–14 years in children, the previously described theory is not accepted; For those coalitions that affect this bone with the adjacent ones, it is related to a transformation of derivatives of the mesoderm.<sup>2</sup>

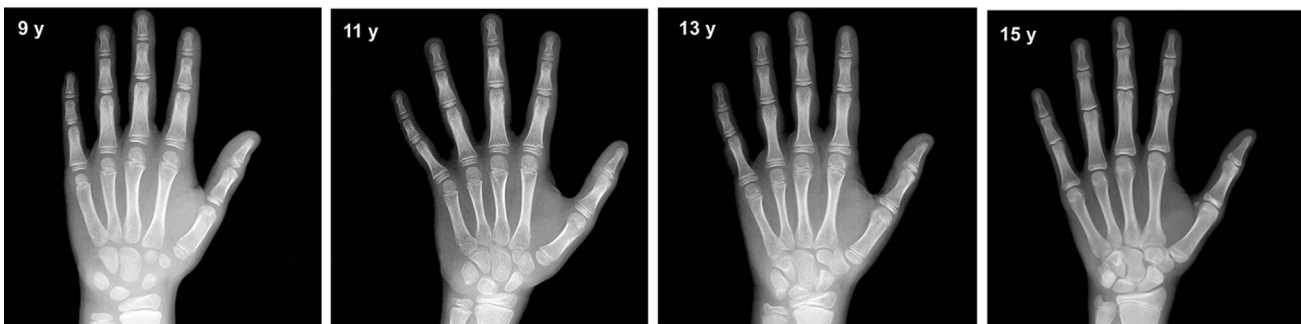
There are different types of coalitions between the carpal bones, the simplest classification being Brunnet's, which is divided into two groups depending on whether the coalition is bony or not<sup>4</sup>; In the latter case, the coalition can be made of cartilaginous tissue, also known as synchondrosis, or fibrous.<sup>1</sup> Concerning the rest of the classifications, as Defazio



**Fig. 3** X-ray of the left hand to monitor bone age from top to bottom and from left to right 1-6 years (top left); 28 years; 3- 10 years; 4 - 11 years; 5- 12 years; 6- 14 years; 7-15 years; 8-16 years.



**Fig. 4** MRI of the left wrist, where the same findings can be seen on the right: synchondrosis between trapezium and scaphoid and carpal scaphoid pseudoarthrosis.



**Fig. 5** Reference images of the Greulich and Pyle method of carpal development in males corresponding to the ages, from left to right: 9 years, 11 years, 13 years, and 15 years; From the age of 11, the differences in the morphology of the scaphoid and trapezium can be observed more clearly compared to those in the clinical case described. Taken from "Vicente Gilsanz OR. Hand Bone Age - A Digital Atlas of Skeletal Maturity. Springer.

explained, both the first classification described by Minaar and that of Singh are not useful for coalitions not bony as they are not included.<sup>1,4</sup>

All carpal bones ossify from a primary ossification center. In the full-term newborn, none of the carpal bones are ossified.<sup>5,6</sup> The large and pyramidal bones become visible at 3 months of age, with the large one appearing, which has a larger and more rounded ossification nucleus; these are the only ossification nucleus visible for the next 6 months in the wrist. Between 14 months and 3 years, 3 or 4 carpal bones are recognized; to the large and pyramidal, the semilunar and the trapezoidal are added.<sup>5</sup>

This sequential appearance of the carpal bones allows bone age to be determined by comparison with standardized radiographs of carpal bones by age and sex, following the method of Greulich and Pyle. This is the most used method for determining bone age.<sup>7</sup> In the case of the patient studied, differences can be observed in the skeletal maturation of the carpal bones concerning the standard shown in the Greulich and Pyle method (→ **Figure 5**), from the age of 12, where the lower edge of the trapezium extends to the scaphoid and, clearly at the age of 14, the alteration of the morphology of the scaphoid and the trapezium can be seen. In the case of our patient, we also

observed a complication that patients with carpal coalitions usually have, especially in non-bony ones,<sup>4</sup> which is a bone fracture. Although it has been theorized that the increase in fractures in this pathology may be related to the area where the fibrous tissue joins an area of weakness, in our case, we see that the bilateral fracture takes place in the middle third of the scaphoid.<sup>7</sup> This same pattern of fracture, has already been previously described by Nour-eldin, in this case, a percutaneous osteosynthesis with a compression screw was performed acutely, observing adequate consolidation after 8 months.<sup>8</sup>

A higher proportion of acute and chronic complications, such as chronic wrist pain, has been observed in patient series in patients with carpal coalitions than we found in the general population, which may be related to the alteration of the biomechanics of the wrist.<sup>1</sup>

## Conclusion

Carpal coalitions are a rare entity, which appears due to cavitation between the carpal bones between the 4th and 8th week of gestation, but which goes unnoticed until skeletal maturation of the carpus occurs; especially, considering the lack of symptoms that accompany this condition, whose

diagnosis is usually a coincidence. Despite this, it has been seen that they are related to a greater susceptibility to mechanical stress, and a greater risk of presenting fractures after suffering trauma.

### Bibliography

- 1 Defazio MV, Cousins BJ, Miversuski RA Jr, Cardoso R. Carpal coalition: A review of current knowledge and report of a single institution's experience with asymptomatic intercarpal fusion. *Hand (N Y)* 2013;8(02):157–163. Doi: 10.1007/s11552-013-9498-5
- 2 Gottschalk MB, Danilevich M, Gottschalk HP. Carpal Coalitions and Metacarpal Synostoses: A Review. *Hand (N Y)* 2016;11(03):271–277. Doi: 10.1177/1558944715614860
- 3 van Hoorn BT, Pong T, van Leeuwen WF, Ring D. Carpal Coalitions on Radiographs: Prevalence and Association With Ordering Indication. *J Hand Surg Am* 2017;42(05):329–334. Doi: 10.1016/j.jhsa.2017.02.002
- 4 Burnett SE. Hamate-pisiform coalition: morphology, clinical significance, and a simplified classification scheme for carpal coalition. *Clin Anat* 2011;24(02):188–196. Doi: 10.1002/ca.21086
- 5 Vicente Gilsanz OR. *Hand Bone Age - A Digital Atlas of Skeletal Maturity*. Springer; 2005
- 6 Navarro M.M., Tejedor B.M., López Siguero J.P. (2014, noviembre). El uso de la edad ósea en la práctica clínica. *Anales de pediatría continuada*12(06):275–283. [https://doi.org/10.1016/S1696-2818\(14\)70204-5](https://doi.org/10.1016/S1696-2818(14)70204-5)
- 7 Resnik CS, Grizzard JD, Simmons BP, Yaghamai I. Incomplete carpal coalition. *AJR Am J Roentgenol* 1986;147(02):301–304. Doi: 10.2214/ajr.147.2.301
- 8 Noureldin S, Ali M, Fallahi F, Dehler T. Scaphoid Fracture in a Patient with a Scaphotrapezial Synostosis: A Case Report and Literature Review. *Case Rep Orthop* 2017;2017:1941750. Doi: 10.1155/2017/1941750