



# Suspected Myocarditis after mRNA COVID-19 Vaccination among South Korean Adolescents

Mi Jin Kim<sup>1</sup> Jin Hee Kim<sup>2</sup> Hyun Ok Jun<sup>3</sup> Kyung Min Kim<sup>4</sup> Min Sub Jeung<sup>5</sup> Jun Sung Park<sup>6</sup>

<sup>1</sup> Division of Pediatric Cardiology, Department of Pediatrics, Asan Medical Center, University of Ulsan College of Medicine, Seoul, Republic of Korea

<sup>2</sup> Department of Emergency Medicine, Seoul National University Hospital, Seoul, Republic of Korea

<sup>3</sup> Department of Cardiovascular Surgery, Severance Cardiovascular Hospital, Yonsei University College of Medicine, Seoul, Republic of Korea

<sup>4</sup> Division of Cardiology, Incheon St. Mary's Hospital, College of Medicine, The Catholic University of Korea, Incheon, Republic of Korea

Address for correspondence Jun Sung Park, MD, PhD, Department of Pediatrics, Asan Medical Center, University of Ulsan College of Medicine, Seoul 05055, Republic of Korea (e-mail: mrpiglet@naver.com).

<sup>5</sup> Department of Pediatrics, Samsung Medical Center, Sungkyunkwan University School of Medicine, Seoul, Republic of Korea

<sup>6</sup> Department of Pediatrics, Asan Medical Center, University of Ulsan College of Medicine, Seoul, Republic of Korea

J Pediatr Infect Dis 2024;19:75–82.

## Abstract

**Objective** Since vaccination for coronavirus disease 2019 (COVID-19) has been initiated, rare cases of COVID-19 mRNA vaccination-associated myocarditis (VAM) have been reported worldwide. This study aimed to report the short-term outcomes and the clinical presentation of VAM in South Korean adolescents.

**Methods** In this prospective multicenter study across five tertiary hospitals in South Korea, patients aged 12 to 17 years with symptoms of VAM were included from October 18, 2021, to April 30, 2022. We performed laboratory tests, electrocardiography, chest radiography, echocardiography, and cardiac magnetic resonance imaging studies on these patients.

**Results** A total of 14 patients were diagnosed with VAM during the study period. The median age of the patients was 15.2 years (interquartile range [IQR], 14.6–15.9) and 11 patients (78.6%) were male. All patients had received a messenger RNA Pfizer-BioNTech COVID-19 vaccine. The median latent period from vaccination to symptom onset was 1 (range, 0–8; IQR, 0.8–3.5) day. Chest pain was the most common symptom (11/14, 78.6%), and the median duration of symptoms was 1 week. Except for one patient (7.1%) who was admitted to intensive care unit, most patients (13/14, 93.8%) had a minor and short clinical course without an intensive treatment including an immune modulator.

**Conclusion** VAM in South Korean adolescents had self-limiting clinical courses as reported by previous studies. Despite the small number of cases, our findings, consistent with previous studies, revealed that East Asian adolescents might have a similar or even milder clinical course than adolescents of other ethnicities.

## Keywords

- COVID-19 vaccines
- myocarditis
- adolescent
- mRNA vaccine
- COVID-19

received

July 2, 2023

accepted after revision

October 17, 2023

article published online

December 29, 2023

DOI <https://doi.org/10.1055/s-0043-1777091>.

ISSN 1305-7707.

© 2023. The Author(s).

This is an open access article published by Thieme under the terms of the Creative Commons Attribution-NonDerivative-NonCommercial-License, permitting copying and reproduction so long as the original work is given appropriate credit. Contents may not be used for commercial purposes, or adapted, remixed, transformed or built upon. (<https://creativecommons.org/licenses/by-nc-nd/4.0/>)

Georg Thieme Verlag KG, Rüdigerstraße 14, 70469 Stuttgart, Germany

## Introduction

Coronavirus disease 2019 (COVID-19), caused by severe acute respiratory syndrome coronavirus 2 (SARS-CoV-2), has resulted in 500 million confirmed cases and 6 million deaths worldwide and was declared as a pandemic on March 11, 2020, by the World Health Organization.<sup>1,2</sup> The vaccine efficacy on COVID-19, including the omicron variant, has been reported to be 70 to 85% in the early phase and more than 50% in the subsequent stage.<sup>3–5</sup> The vaccines using viral mRNA are the most widely administered, and among them, the Pfizer-BioNTech COVID-19 vaccine is reported to be a favorable vaccine for children and adolescents.<sup>6</sup> However, as reported in adults, there is also a concern about suspected vaccination-associated myocarditis (VAM) in adolescents.<sup>7,8</sup> Most studies on adolescents reported that VAM showed mild symptoms and a self-limiting course with a markedly lower severity than that of cardiac complications associated with COVID-19 or multisystem inflammatory syndrome in children (MIS-C).<sup>7–10</sup> When considering the risk–benefit, COVID-19 mRNA vaccination is still recommended worldwide for the adolescent population because the efficacy of the vaccination outweighs the complications.<sup>9,11</sup>

However, the number of Asians included in large-scale studies on VAM in adolescents has been limited, and studies on VAM in Asian adolescents are lacking. A recent study reported the incidence and characteristics of VAM in the population of Hong Kong and its benign clinical course.<sup>12</sup> South Korea has had one of the highest numbers of newly confirmed cases worldwide because of the rapid spread of the omicron variant.<sup>2</sup> Among the newly confirmed cases in South Korea, the number of children and adolescents with COVID-19 was 1.8 times more than that of other populations because of their low vaccination rate.<sup>13</sup> Therefore, vaccination of the adolescent population is important to reduce spread of, and mortality from, COVID-19 in South Korea. Although a recent retrospective study reported a mild clinical course of VAM in South Korean adolescents,<sup>14</sup> the study population was geographically limited to two provinces of South Korea, and there was no result of cardiac magnetic resonance imaging (MRI). We conducted a prospective multicenter study to analyze the clinical characteristics of patients with VAM among South Korean adolescents and evaluated the hazard of VAM.

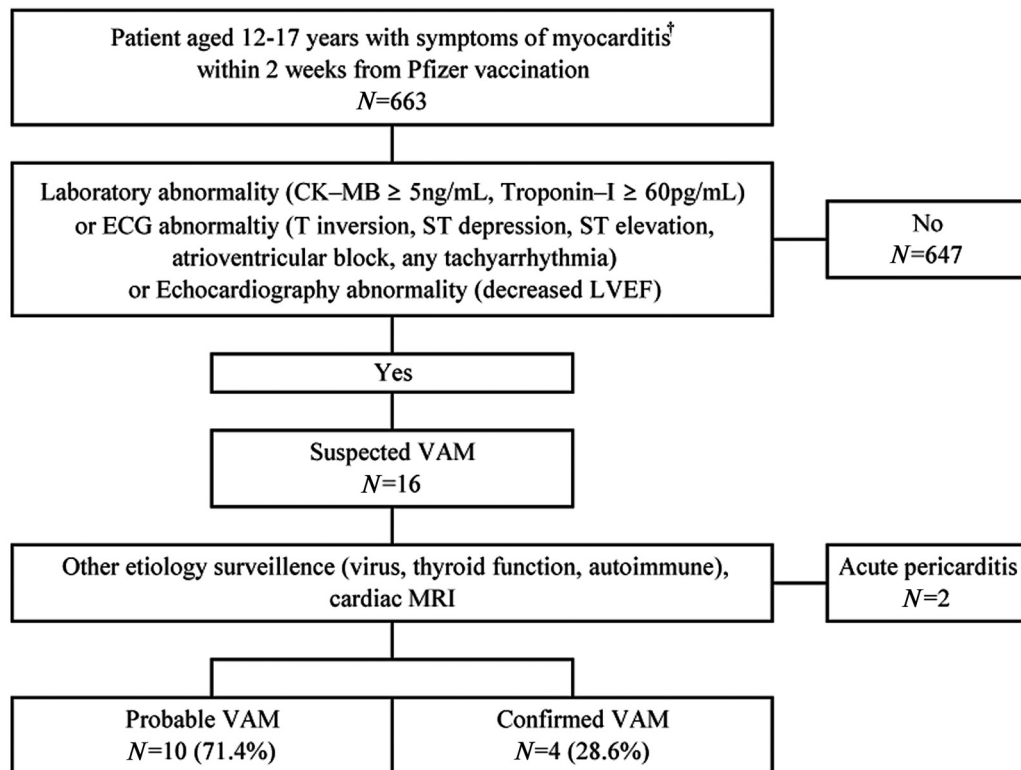
## Materials and Methods

We prospectively identified patients aged 12 to 17 years who visited Asan Medical Center, Seoul National University Hospital, Samsung Medical Center, Incheon St. Mary's Hospital, and Severance Hospital from October 18, 2021, to April 30, 2022, since South Korea started Pfizer-BioNTech COVID-19 vaccine for this population from October 18, 2021. The following tests were performed on all the adolescent patients aged 12 to 17 years with symptoms of suspected myocarditis (any fever, general weakness, nausea, vomiting, cough, dyspnea, headache, dizziness, chest pain, orthopnea, chest discomfort, or palpitations): complete blood cell test,

electrolyte, chemistry test, C-reactive protein, procalcitonin, erythrocyte sediment rate, B-type natriuretic peptide (BNP), troponin-I, creatine kinase (CK), leukocyte dehydrogenase, CK-MB, echocardiography, electrocardiography (ECG), chest radiography, blood gas analysis, and blood culture (►Fig. 1). The ECG was interpreted by a pediatric cardiologist. Echocardiography was performed and interpreted by a pediatric cardiologist. The patients with suspected myocarditis on the basis of ECG abnormalities, elevated cardiac enzymes, or left ventricular systolic dysfunction on echocardiography were enrolled for the study and underwent the following additional surveillance: viral surveillance (herpes simplex virus, cytomegalovirus, hepatitis B and C, SARS-CoV-2 immunoglobulin [Ig]G and polymerase chain reaction [PCR], respiratory virus nasopharyngeal PCR panel), bacterial blood culture, thyroid function test, autoimmune test (antinuclear antibody, IgG, IgA, and IgM), and cardiac MRI. An MRI analysis and interpretation were performed by cardiovascular magnetic resonance experts of the performing center. Although the cardiac MRI was to be conducted within 2 weeks from symptom onset, the test was omitted if the clinical symptoms and abnormality of the tests were normalized before the due date. Cases of suspected VAM were categorized as “probable” or “confirmed” using the Centers for Disease Control and Prevention (CDC) case definitions (►Supplementary Table S1 [available in the online version]).<sup>15</sup> The patients with isolated abnormality in ECG without elevation of the cardiac enzyme were classified as having pericarditis rather than myocarditis. On the other hand, patients with decreased ventricular function on echocardiography or atrioventricular block (AVB) on ECG were classified as myocarditis regardless of the value of cardiac enzymes.

In case of mild symptoms, outpatient follow-up was performed without hospitalization. All the patients were followed up during hospitalization or as outpatients until the clinical symptoms and abnormalities of tests, including laboratory tests, echocardiography, and ECG, were normalized. The demographics, including the date of birth, sex, ethnicity, date of receiving the first and second doses of the COVID-19 vaccine, symptoms, date of onset, medical history, family history, hospital course, sequela, and mortality were collected. Informed consent was obtained from the parents of the patients and was explained to the patients. The Institutional Review Board represented by Human Research at Asan Medical Center approved this study (IRB number: 2021-1549).

- Abnormality of laboratory test: CK  $\geq$  250 IU/L, CK-MB  $\geq$  5 ng/mL, troponin-I  $\geq$  60 pg/mL, and BNP  $\geq$  40 pg/mL.
- Abnormality of ECG: T wave inversions, nonspecific ST-segment changes, diffuse ST-segment elevation, AVB, supraventricular tachycardia, or ventricular tachycardia.<sup>15</sup>
- Abnormality of echocardiography: Left ventricular ejection fraction (LVEF)  $<$  50%, regional wall motion abnormalities, and fractional area change (FAC) correlated with tricuspid annular plane systolic excursion (TAPSE)  $<$  35%.
- Abnormality of cardiac MRI: Consistent with the original or revised Lake Louise criteria for myocarditis.<sup>16</sup>



**Fig. 1** Flow chart of the study population. BNP, B-type natriuretic peptide; CK, creatine kinase; ECG, electrocardiography; LVEF, left ventricular ejection fraction; MRI, magnetic resonance imaging; VAM, vaccination associated myocarditis. <sup>†</sup>Symptom of myocarditis: fever, general weakness, nausea, vomiting, cough, dyspnea, headache, dizziness, chest pain, orthopnea, chest discomfort, and/or palpitation.

Descriptive data are expressed using a graph and table created using Excel 365 (Microsoft Corp., Redmond, Washington, United States). Median values with range and inter-quartile ranges (IQRs) have been used to describe skewed data. These calculations were performed using IBM-SPSS for Windows software, version 21 (SPSS Inc., Chicago, Illinois, United States).

## Results

A total of 663 patients visited the study affiliates with symptoms of possible myocarditis (► **Fig. 1**). After excluding patients with normal laboratory and ECG findings, 16 patients were suspected of having VAM. After excluding two patients diagnosed with pericarditis with isolated ST elevation in ECG, 14 patients were diagnosed with VAM. The patients with decreased cardiac function on echocardiography or AVB on ECG (Patients Nos. 2, 13, and 14 in ► **Supplementary Table S2** [available in the online version]) were regarded as having myocarditis despite the normal value of cardiac enzyme. The median age of the patients was 15.2 (IQR, 14.6–15.9) years, and most were male (11/14, 78.6%). All patients received the Pfizer-BioNTech COVID-19 vaccine. Among them, seven (50%) patients developed clinical symptoms associated with the first dose of vaccination, and the other seven (50%) patients developed them after the second dose of vaccination. The median latent period from vaccination to symptom onset was 1 (range, 0–8; IQR, 0.8–3.5) day. The most common symptom was chest pain (11/14, 78.6%), followed by chest discomfort,

dyspnea, and fever. The median duration of symptoms was a week. Based on the CDC case definition, four (28.6%) patients were confirmed cases (Patient Nos. 1, 3, 5, and 10 in ► **Supplementary Table S2** [available in the online version]), and the others were probable cases (► **Table 1**). No patient showed positive findings in surveillance for other etiology of myocarditis, including bacterial, viral, and autoimmune studies. Only two patients had a combined medical condition (Patient Nos. 1 and 13 in ► **Supplementary Table S2** [available in the online version]). Patient No. 1 had concomitant acute kidney injury (AKI) derived from rapidly progressive glomerulonephritis (RPGN) associated with COVID-19 mRNA vaccination (pathologically confirmed), and Patient No. 13 had a remote history of cured acute myocarditis with unknown etiology 10 years previously.

As most patients had minor symptoms, three patients (Patient Nos. 2, 7, and 14) were not admitted but were followed up at the outpatient clinic. Despite a lack of statistical significance, patients who received a second dose had a higher admission rate than those who received only the first dose (71.4 vs. 85.7%). Eleven (78.6%) patients were admitted and followed up, and most of them (10/11, 90.9%) were discharged without sequela; however, one patient (Patient No. 1) had end-stage renal disease due to RPGN. One patient was admitted to the intensive care unit (ICU; Patient No. 5) to manage symptomatic AVB. The median duration of symptoms was 7 (IQR, 5–15) days. Twelve patients (85.7%) needed nonsteroidal anti-inflammatory drugs (NSAIDs), and three patients (21.4%) needed vasodilators for heart failure

**Table 1** COVID-19 vaccine and clinical data

Age, y, median (range, IQR)	15.2 (12.1–17, 14.6–15.9)
Male, n (%)	11 (78.6)
Brand of COVID-19 vaccine, n (%)	
Pfizer-BioNTech	14 (100)
Dose of vaccine with symptoms, n (%)	
First dose	7 (50)
Second dose	7 (50)
Days from vaccine administration to symptom onset, d, median (range, IQR)	1 (0–8, 0.8–3.5)
Symptoms, n (%)	
Chest pain	11 (78.6)
Chest discomfort	7 (50)
Dyspnea	6 (42.9)
Fever	4 (28.6)
Nausea	3 (21.4)
Vomiting	3 (21.4)
General weakness	3 (21.4)
Headache	2 (14.3)
Orthopnea	2 (14.3)
Dizziness	2 (14.3)
Duration of symptom, d, median (range, IQR)	7 (4–45, 5–15)
CDC case definition of myocarditis	
Confirmed	4 (28.6)
Probable	10 (71.4)
Other proven myocarditis etiology <sup>a</sup>	0 (0)
Disposition, n (%)	
Outpatient clinic	2 (14.3)
Ward admission	11 (78.6)
ICU admission	1 (7.1)
Treatment	
NSAID	12 (85.7)
Steroid	1 (7.1)
Vasodilator	3 (21.4)
Prolonged symptom over 1 mo	3 (21.4)
Mortality	0 (0)

Abbreviations: CDC, Centers for Disease Control and Prevention; COVID-19, coronavirus disease 2019; ICU, intensive care unit; IQR, interquartile range; NSAID, nonsteroidal anti-inflammatory drug.

<sup>a</sup>Surveillance for other etiology of myocarditis: viral surveillance (herpes virus, cytomegalovirus, hepatitis B and C, COVID-19 IgG and PCR, respiratory virus nasopharyngeal PCR panel), bacterial blood culture, thyroid function test, autoimmune test (antinuclear antibody, immunoglobulin G, A, and M).

management (Patients Nos. 5 and 10). Patient No. 1 underwent methylprednisolone pulse therapy and was administered immune suppressants for salvage therapy of AKI, not for myocarditis itself.

The most common abnormal value among laboratory tests was an elevation of troponin-I (12/14, 85.7%), and CK, CK-MB, and BNP were observed to follow (78.6, 50, and 50%, respectively) (– **Table 2**). The laboratory values reached peak levels in the order of CK, CK-MB, troponin-I, and BNP (0, 0, 1, and 1.5 days, respectively). The elevation of troponin-I and BNP were the most lasting laboratory abnormalities to normalize (median, 8 and 9 days, respectively). Seven patients (50%) had ECG abnormalities, and ST elevation was the most common abnormality (6, 42.9%) (– **Table 3**). In echocardiography, three patients showed abnormalities (3/13, 23.1%). Two of them showed systolic dysfunction in tissue Doppler imaging and decreased LVEF (Patients Nos. 2 and 13), and the other had pericardial effusion (Patient No. 10). The right ventricular function represented by TAPSE and FAC were preserved in all patients. Of the eight patients who underwent cardiac MRI, five (62.5%) showed abnormal findings consistent with the Lake Louise criteria. Late gadolinium enhancement was the most common finding (3, 37.5%), followed by decreased LVEF and pericardial effusion. The representative findings of the imaging study are summarized in – **Fig. 2**.

Patients were followed up by 432 days in median. Three patients took vasodilators: Patient No. 10 took medication for a week; Patient No. 5 took medication for a year because of exertional dyspnea; and Patient No. 13 is still taking the medication as of August 3, 2023, because LVEF has not recovered. Except for Patient No. 13, the other 13 patients recovered completely and did not show a symptom recurrence over the follow-up period.

#### *A Patient with Concomitant RPGN after the Second Dose of Vaccination*

A 16-year-old female patient without known previous history of COVID-19 had only a mild symptom of myocarditis but a severe deteriorating RPGN after the second dose of the Pfizer-BioNTech COVID-19 vaccine. She had mild febrile sense, general weakness, and myalgia within a week after the first dose of the Pfizer-BioNTech COVID-19 vaccine. Three weeks after the first dose, she received the second dose of the vaccine. She had 3 days of presumed myocarditis symptoms, which were mild and spontaneously resolved without visiting the hospital: fever, general weakness, nausea, vomiting, and orthopnea. After 3 weeks of no symptoms, headache and dyspnea occurred and worsened for 2 weeks. Five weeks after the second dose, she underwent laboratory tests. The test results were consistent with AKI: systolic blood pressure (BP) 170 mm Hg, diastolic BP 100 mm Hg, creatinine 9.6 mg/dL, blood urea nitrogen 66 mg/dL, potassium 5.4 mmol/L, pH 7.28, bicarbonate 16.4 mmEq/L, microscopic proteinuria, and microscopic hematuria. The patient had typical symptoms derived from volume overload due to renal insufficiency: hypertension, azotemia, metabolic acidosis, and electrolyte imbalance. She underwent intermittent hemodialysis (HD) to control volume overload, azotemia, and electrolyte imbalance for AKI. There was no evidence of myocarditis in initial tests: CK-MB 3.0 ng/mL, troponin-I 38 pg/mL, normal ECG, no cardiomegaly, and

**Table 2** Laboratory data

Blood test	Abnormal, <i>n</i> (%)	Peak level, median (Range, IQR)	Time to peak, d Median (Range, IQR)	Time to normalize, d Median (range, IQR)
CK (IU/L)	11 (78.6)	410 (60–7,070, 187–1,801)	0 (0–1, 0–0)	3 (0–6, 2–5)
CK-MB (ng/mL)	7 (50)	9.6 (0.2–766, 1–108)	0 (0–3, 0–1)	3.5 (0–6, 1.5–4.75)
Troponin-I (pg/mL)	12 (85.7)	1,706 (3–381,522, 70–22,494)	1 (0–4, 0–2)	8 (2–49, 2.75–15)
BNP (pg/mL)	7 (50)	41 (2–1,332, 10–221)	1.5 (0–3, 1–2.8)	9 (3–25, 4.5–18)

Abbreviations: BNP, B-type natriuretic peptide, CK, creatine kinase; IQR, interquartile range.

Note: Reference ranges: CK <250 IU/L, CK-MB <5 ng/mL, troponin-I <60 pg/mL, and BNP <40 pg/mL.

normal echocardiography. A cardiac MRI was conducted later to distinguish the pathogenesis of AKI between the primary involvement of immune reaction from COVID-19 vaccination and unrecognized hypoperfusion derived from VAM, and it showed a late gadolinium enhancement which is consistent with VAM. HD was conducted immediately after the gadoterate-based contrast-enhanced cardiac MRI to prevent nephrogenic systemic fibrosis. This finding on cardiac MRI was not interpreted as a current cardiac issue but as a remote VAM event that possibly occurred and might affect hypoperfusion of the kidney in the first week after the second dose of the Pfizer-BioNTech COVID-19 vaccine because there

was no deterioration of cardiac function in both echocardiography and cardiac MRI. Therefore, there was no treatment for VAM because the patient had no hemodynamic instability or abnormal test indicating myocardial injury. A renal biopsy showed crescent glomerulonephritis and acute tubulointerstitial necrosis. Methylprednisolone pulse therapy was administered to salvage the kidney. However, as the end-stage renal disease progressed, she underwent HD for 25 days, and living-donor kidney transplantation 6 months after vaccination.

## Discussion

Our study showed that VAM in adolescents in South Korea was a self-limiting condition; almost all our patients recovered after short-term NSAID administration. The symptom duration was a week, and the ICU admission rate was 6.4%. No patient needed immune modulators, including intravenous Ig or corticosteroids, except for one patient who underwent methylprednisolone pulse therapy for RPGN, not for VAM (Patient No. 1). Although the clinical characteristics such as the timing of onset after vaccination, higher rate of hospitalization among the patients who received a second dose, and male predominance are similar to those of other studies,<sup>7,8,14,17,18</sup> duration of symptoms was shorter than the 35 days reported by a previous large-scale study,<sup>8</sup> and the ICU admission rate was lower than that of previous studies (18–53%).<sup>7,8</sup> This milder clinical course of VAM in an East Asian population compared with other ethnicities is consistent with other studies on Asian populations.<sup>12,14,19</sup> These limited but consistent results imply that VAM in the East Asian adolescent population may have a similar or even milder clinical course than in other populations.

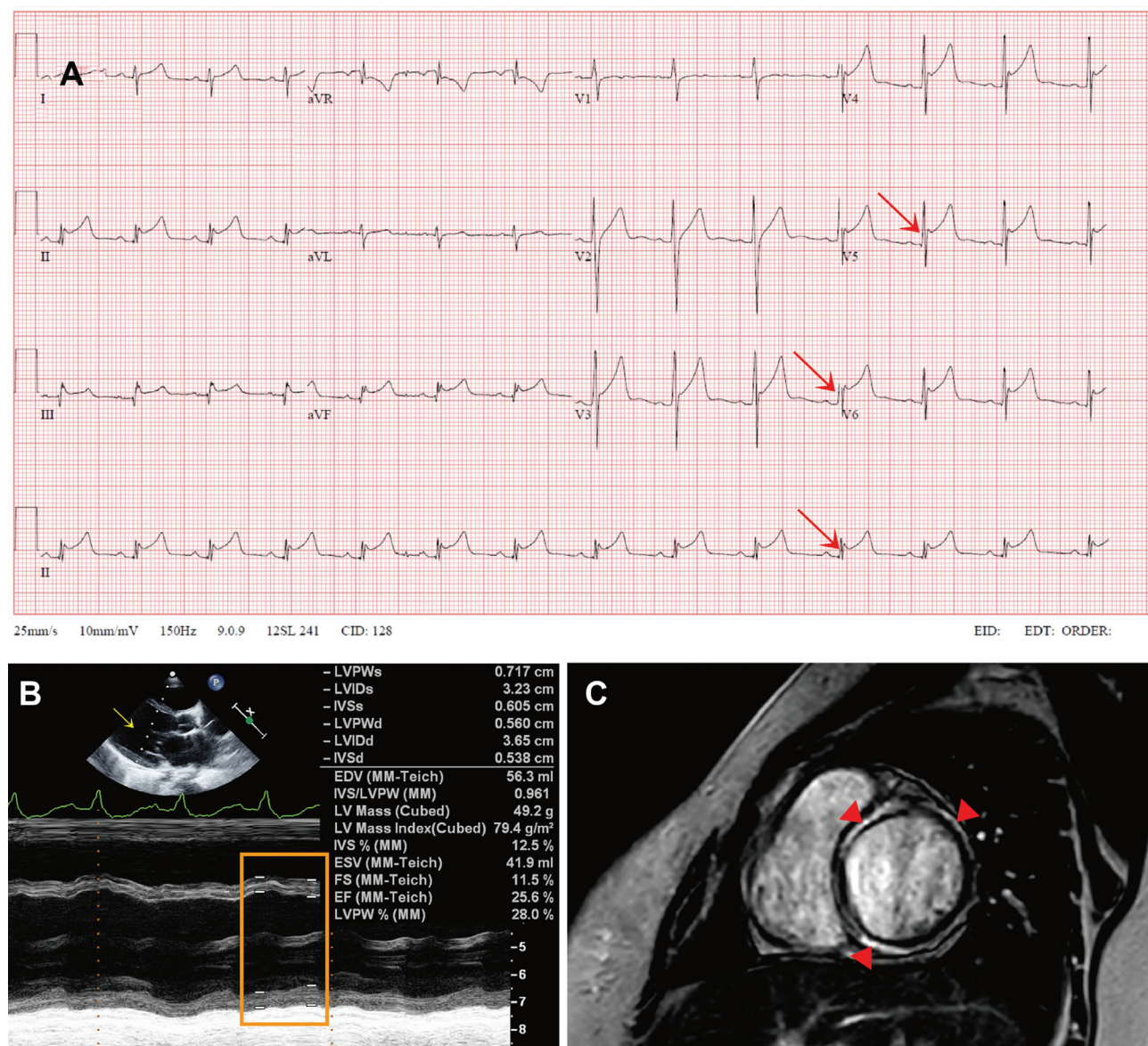
Although there is no study on the racial differences in VAM, there have been several studies on the racial characteristics of COVID-19, which have reported that COVID-19 has a more severe clinical course in the Asian population compared with populations of other ethnicities.<sup>20,21</sup> However, these studies included only South Asian populations (such as Indian, Pakistani, or Bangladeshi). Another study conducted in Los Angeles, of which more than half of Asian ethnic origin were East Asian (Korean, Japanese, and Chinese) showed that

**Table 3** ECG and imaging data

ECG ( <i>n</i> = 14)	Number (%)
Normal ( <i>n</i> = 7, 50%)	
Abnormal ( <i>n</i> = 7, 50%)	
ST segment elevation	6 (42.9)
AV block	2 (14.3)
T inversion	1 (7.1)
ST segment depression	0 (0)
Tachyarrhythmia	0 (0)
Echocardiography ( <i>n</i> = 13)	
Normal ( <i>n</i> = 10, 76.9%)	
Abnormal ( <i>n</i> = 3, 23.1%)	
Decreased LVEF	2 (15.4)
Pericardial effusion	1 (7.7)
MRI ( <i>n</i> = 8)	
Normal ( <i>n</i> = 3, 37.5%)	
Abnormal ( <i>n</i> = 5, 62.5%)	
Late gadolinium enhancement	3 (37.5)
Decreased LVEF	2 (25)
Pericardial effusion	1 (12.5)

Abbreviations: AV, atrioventricular; ECG, electrocardiography; LVEF, left ventricular ejection fraction; MRI, magnetic resonance imaging.





**Fig. 2** Findings of electrocardiography, echocardiography, and magnetic resonance image. (A) Electrocardiography of Patient No. 3 shows ST elevation in limb leads and precordial leads (red arrows); (B) echocardiography of Patient No. 13 shows dilated left ventricle (yellow arrow) and decreased contractility represented by ejection fraction (orange square); (C) cardiac magnetic resonance image of Patient No. 5 shows subepicardial delayed enhancement of myocardium on phase sensitive inversion recovery image.

the hospital and ICU admission rate in this population was lower than that of other populations.<sup>22,23</sup> Although there was no adjustment for covariates, the COVID-19 dashboard shows lower mortality in East Asian countries than in other countries in terms of raw data.<sup>2</sup> The explanation for this might extend beyond the social components such as socioeconomic status, quarantine policy, and social distancing. The seroconversion of IgG occurred earlier than that of IgM in some Chinese and Japanese studies, implying that there could be cross-reactivity of specific antibodies of seasonal coronavirus endemic in East Asia.<sup>24,25</sup> Furthermore, the human lymphocyte antigen (HLA) genotype impacts the severity of COVID-19.<sup>26</sup> The prevalence of HLA, which can have a protective effect against COVID-19, may be higher in the Asian population.<sup>27,28</sup> Finally, the bacillus Calmette–Guerin vaccination, which is included in the mandatory vaccination policy of South Korea, can affect the suscepti-

bility to other nonspecific infections, including COVID-19.<sup>29</sup> Such immunologic characteristics may affect the incidence of COVID-19 in Asian countries and the immunologic side effects of COVID-19 vaccination, considering that the pathophysiology of VAM might include host immune response of cytotoxic T lymphocytes, although not fully understood. Therefore, future studies are needed to validate the interracial difference in the severity of VAM and elucidate its possible mechanisms.

Although vaccination is the most effective option in preventing COVID-19,<sup>30</sup> there is COVID-19 vaccine hesitancy because of concern for serious side effects, especially cardiac complications.<sup>31</sup> However, the risk and severity of cardiac complications of COVID-19 vaccination are much milder than those of COVID-19 or MIS-C.<sup>10</sup> Furthermore, considering a similar or even milder clinical course of VAM in the East Asian population reported in our study and the other

consistent studies, COVID-19 vaccination in adolescents in East Asian countries can also be recommended. Simultaneously, vigilance for cardiac manifestations should be continued, considering that VAM can manifest as fulminant myocarditis and have a critical clinical course.<sup>32,33</sup>

Our study has some limitations. Although we conducted a multicenter study of tertiary hospitals, our results would not be generalized for VAM in other Asian countries beyond South Korea because we included only the Asian population from limited regions of South Korea with a too small number of cases. However, our findings are consistent with other studies, including one in other provinces of South Korea, reporting the similar or milder clinical course of VAM in the East Asian population.<sup>12,14,19</sup> As such, our study can serve as a meaningful preliminary study for further nationwide or multicountry studies of East Asian countries. We found lower incidence of VAM in South Korea compared with that of other ethnicities (3.9–16.3 cases per 100,000),<sup>19,34–38</sup> and we also found that VAM cases were less severe. The incidence of VAM in South Korea is only 3.9 cases per 100,000 (135/3,481,287, as announced by the central disease control headquarters of Korea on May 20, 2022), while more than 80% of the adolescents aged 12 to 17 years were vaccinated with the second dose. Since the study was not nationwide, patients who failed to be followed up or did not visit the emergency department (ED) with mild discomfort may have been missed. Furthermore, as we did not conduct mandatory cardiac MRI or myocardial biopsy if the diagnosis could already be made with laboratory tests, echocardiography, and ECG, and if the clinical symptoms resolved before the due date of the test, there were a few confirmed cases according to the CDC definition. However, such selective diagnostic processes do not delay the decision or deteriorate the clinical course of the patients.

## Conclusion

VAM in South Korean adolescents had self-limiting clinical courses, as reported by previous studies. Despite the small number of cases included in our study, our findings consistent with previous studies revealed that East Asian adolescents might have a similar or even milder clinical course than adolescents of other ethnicities.

### Authors' Contribution

J.S.P. conceptualized the study, contributed to formal analysis, software, writing—review and editing. All authors contributed to data curation. M.J.K. contributed to methodology and writing—original draft.

### Funding

None.

### Conflict of Interest

None declared.

### Acknowledgment

We would like to thank Editage ([www.editage.co.kr](http://www.editage.co.kr)) for English language editing.

## References

- Cucinotta D, Vanelli M. WHO declares COVID-19 a pandemic. *Acta Biomed* 2020;91(01):157–160
- World Health Organization. WHO coronavirus (COVID-19) dashboard. Accessed May 14, 2022 at: <https://covid19.who.int/>
- Tseng HF, Ackerson BK, Luo Y, et al. Effectiveness of mRNA-1273 against SARS-CoV-2 omicron and delta variants. *Nat Med* 2022;28(05):1063–1071
- Pajon R, Doria-Rose NA, Shen X, et al. SARS-CoV-2 omicron variant neutralization after mRNA-1273 booster vaccination. *N Engl J Med* 2022;386(11):1088–1091
- Fowlkes AL, Yoon SK, Lutrick K, et al. Effectiveness of 2-dose BNT162b2 (Pfizer BioNTech) mRNA vaccine in preventing SARS-CoV-2 infection among children aged 5–11 years and adolescents aged 12–15 years—PROTECT Cohort, July 2021–February 2022. *MMWR Morb Mortal Wkly Rep* 2022;71(11):422–428
- Frenck RWJ Jr, Klein NP, Kitchin N, et al; C4591001 Clinical Trial Group. Safety, immunogenicity, and efficacy of the BNT162b2 Covid-19 vaccine in adolescents. *N Engl J Med* 2021;385(03):239–250
- Truong DT, Dionne A, Muniz JC, et al. Clinically suspected myocarditis temporally related to COVID-19 vaccination in adolescents and young adults: suspected myocarditis after COVID-19 vaccination. *Circulation* 2022;145(05):345–356
- Jain SS, Steele JM, Fonseca B, et al. COVID-19 vaccination-associated myocarditis in adolescents. *Pediatrics* 2021;148(05):148
- Chin SE, Bhavsar SM, Corson A, Ghersin ZJ, Kim HS. Cardiac complications associated with COVID-19, MIS-C, and mRNA COVID-19 vaccination. *Pediatr Cardiol* 2022;43(03):483–488
- Patel T, Kelleman M, West Z, et al. Comparison of multisystem inflammatory syndrome in children-related myocarditis, classic viral myocarditis, and COVID-19 vaccine-related myocarditis in children. *J Am Heart Assoc* 2022;11(09):e024393
- Bozkurt B, Kamat I, Hotez PJ. Myocarditis with COVID-19 mRNA vaccines. *Circulation* 2021;144(06):471–484
- Chua GT, Kwan MYW, Chui CSL, et al. Epidemiology of acute myocarditis/pericarditis in Hong Kong adolescents following Comirnaty vaccination. *Clin Infect Dis* 2022;75(04):673–681
- Central Disease Control Headquarters RoK. Coronavirus (COVID-19). Republic of Korea. Accessed June 3, 2022 at: [http://ncov.mohw.go.kr/tcmBoardView.do?brdId=3&brdGubun=31&dataGubun=&ncvContSeq=6475&contSeq=6475&board\\_id=312&gubun=BDJ](http://ncov.mohw.go.kr/tcmBoardView.do?brdId=3&brdGubun=31&dataGubun=&ncvContSeq=6475&contSeq=6475&board_id=312&gubun=BDJ)
- Roh DE, Na H, Kwon JE, Choi I, Kim YH, Cho HJ. Chest pain and suspected myocarditis related to COVID-19 vaccination in adolescents—a case series. *Children (Basel)* 2022;9(05):9
- Gargano JW, Wallace M, Hadler SC, et al. Use of mRNA COVID-19 vaccine after reports of myocarditis among vaccine recipients: update from the Advisory Committee on Immunization Practices—United States, June 2021. *MMWR Morb Mortal Wkly Rep* 2021;70(27):977–982
- Ferreira VM, Schulz-Menger J, Holmvang G, et al. Cardiovascular magnetic resonance in nonischemic myocardial inflammation: expert recommendations. *J Am Coll Cardiol* 2018;72(24):3158–3176
- Oster ME, Shay DK, Su JR, et al. Myocarditis cases reported after mRNA-based COVID-19 vaccination in the US from December 2020 to August 2021. *JAMA* 2022;327(04):331–340
- Li X, Lai FTT, Chua GT, et al. Myocarditis following COVID-19 BNT162b2 vaccination among adolescents in Hong Kong. *JAMA Pediatr* 2022;176(06):612–614
- Kim S, Hwang I, Ko M, Kwon Y, Lee YK. Safety monitoring of COVID-19 vaccination among adolescents aged 12 to 17 years old in the Republic of Korea. *Osong Public Health Res Perspect* 2022;13(03):230–237
- Lassale C, Gaye B, Hamer M, Gale CR, Batty GD. Ethnic disparities in hospitalisation for COVID-19 in England: the role of socioeconomic factors, mental health, and inflammatory and



- pro-inflammatory factors in a community-based cohort study. *Brain Behav Immun* 2020;88:44–49
- 21 Williamson EJ, Walker AJ, Bhaskaran K, et al. Factors associated with COVID-19-related death using OpenSAFELY. *Nature* 2020; 584(7821):430–436
  - 22 United States government. United States Census. Accessed May 23, 2022 at: <https://www.census.gov/>
  - 23 Ebinger JE, Achamallah N, Ji H, et al. Pre-existing traits associated with COVID-19 illness severity. *PLoS One* 2020;15(07):e0236240
  - 24 Nakano Y, Kurano M, Morita Y, et al. Time course of the sensitivity and specificity of anti-SARS-CoV-2 IgM and IgG antibodies for symptomatic COVID-19 in Japan. *Sci Rep* 2021;11(01):2776
  - 25 Zhang G, Nie S, Zhang Z, Zhang Z. Longitudinal change of severe acute respiratory syndrome coronavirus 2 antibodies in patients with coronavirus disease 2019. *J Infect Dis* 2020;222(02):183–188
  - 26 Langton DJ, Bourke SC, Lie BA, et al. The influence of HLA genotype on the severity of COVID-19 infection. *HLA* 2021;98(01):14–22
  - 27 Dijkstra JM, Frenette AP, Dixon B. Most Japanese individuals are genetically predisposed to recognize an immunogenic protein fragment shared between COVID-19 and common cold coronaviruses. *F1000 Res* 2021;10:196
  - 28 Naemi FMA, Al-Adwani S, Al-Khatibi H, Al-Nazawi A. Association between the HLA genotype and the severity of COVID-19 infection among South Asians. *J Med Virol* 2021;93(07):4430–4437
  - 29 Yitbarek K, Abraham G, Girma T, Tilahun T, Woldie M. The effect of bacillus Calmette-Guérin (BCG) vaccination in preventing severe infectious respiratory diseases other than TB: implications for the COVID-19 pandemic. *Vaccine* 2020;38(41):6374–6380
  - 30 Thomas SJ, Moreira ED Jr, Kitchin N, et al; C4591001 Clinical Trial Group. Safety and efficacy of the BNT162b2 mRNA COVID-19 vaccine through 6 months. *N Engl J Med* 2021;385(19):1761–1773
  - 31 Yasmin F, Najeeb H, Moeed A, et al. COVID-19 vaccine hesitancy in the United States: a systematic review. *Front Public Health* 2021; 9:770985
  - 32 Cui G, Li R, Zhao C, Wang DW. Case report: COVID-19 vaccination associated fulminant myocarditis. *Front Cardiovasc Med* 2022; 8:769616
  - 33 He W, Zhou L, Xu K, et al. Immunopathogenesis and immunomodulatory therapy for myocarditis. *Sci China Life Sci* 2023;66 (09):2112–2137
  - 34 Central Disease Control Headquarters RoK. COVID-19 vaccination. Accessed May 18, 2022 at: <https://ncv.kdca.go.kr/>
  - 35 Our World in Data. C. oronavirus (COVID-19) vaccinations. Accessed May 18, 2022 at: <https://ourworldindata.org/covid-vaccinations?country=#vaccinations-by-age>
  - 36 Krug A, Stevenson J, Høeg TB. BNT162b2 vaccine-associated Myo/pericarditis in adolescents: a stratified risk-benefit analysis. *Eur J Clin Invest* 2022;52(05):e13759
  - 37 Guo BQ, Li HB, Yang LQ. Incidence of myopericarditis after mRNA COVID-19 vaccination: a meta-analysis with focus on adolescents aged 12–17 years. *Vaccine* 2023;41(28):4067–4080
  - 38 Katoto PDMC, Byamungu LN, Brand AS, et al. Systematic review and meta-analysis of myocarditis and pericarditis in adolescents following COVID-19 BNT162b2 vaccination. *NPJ Vaccines* 2023;8 (01):89