Article published online: 2024-01-19

A Rare Complication of Intraprosthetic Dissociation of Cemented Bipolar Hemiarthroplasty during Closed Hip Reduction: Case Report and Literature Review

Amanda Mitchell, BA[1] Nicole Belkin, MD[1] Nana Sarpong, MD[1] Carl L. Herndon, MD[1] Thomas R. Hickernell, MD[2]

[1] Department of Orthopedic Surgery, Columbia University Medical Center, New York, New York
[2] Department of Orthopedic Surgery, Yale Medicine, New Haven, Connecticut

Address for correspondence Thomas R. Hickernell, MD, Department of Orthopedic Surgery, Yale Medicine, 260 Long Ridge Rd, Stamford, CT 06902 (e-mail: Thomas.hickernell@yale.edu).

J Hip Surg

Abstract

Hip hemiarthroplasty (HA) remains a frequently performed surgery for femoral neck fractures especially in the oldest, lowest demand patients. Debate persists concerning the optimal choice between unipolar and bipolar HA implants. A rare but important to recognize complication unique to bipolar HA is intraprosthetic dissociation (IPD). We review the literature on this rare phenomenon and identify predominant etiologies and implant components most involved in IPD, notably the role of hip dislocation and closed reduction in precipitating this complication. We also describe an elderly male patient with Parkinson's who experienced IPD of his bipolar HA during a closed reduction attempt. IPD typically requires open reduction and possibly revision of components, adding increased risk of reoperation/revision to those already frail and vulnerable to surgical complications.

Keywords
- bipolar
- hemiarthroplasty
- intraprosthetic dissociation
- dislocation

Femoral neck fracture is the second most common hip fracture,[1] and its high prevalence in older adults is only increasing with increasing rates of osteoporosis in the older population.[2] Fractures of the femoral neck can be treated with internal fixation if the fracture is nondisplaced or the patient is very young, but hip arthroplasty remains the gold standard treatment for most displaced fractures in older patients.[3] Among the arthroplasty options, hemiarthroplasty (HA) yields a higher reoperation rate but lower postoperative dislocation rate compared with total hip arthroplasty (THA).[4–6] As treatment trends and guidelines continue to change and tend to favor THA over HA for more active patients, HA remains a viable and frequently used treatment option especially for the most elderly patients with lower functional demands. However, the choice between unipolar and bipolar HA implants remains controversial.[7]

While some studies have shown no differences in hip function, complications, and dislocation risk[3,8,9] between unipolar and bipolar HA, bipolar HA is associated with better health-related quality of life (HRQoL) and later onset of acetabular erosion compared with unipolar HA.[10] However, the rare complication of intraprosthetic dissociation (IPD) continues to occur in bipolar HA, frequently during dislocation or reduction of the dislocated prosthetic hip. This complication has previously manifested in a variety of ways, for example, as dislodgement of the femoral stem[11,12] or dissociation of the two articulating surfaces of the femoral ball head and polyethylene (PE) lined cup.[13–15] IPD requires conversion from closed to open reduction to

received
April 12, 2023
accepted after revision
September 12, 2023

© 2024. Thieme. All rights reserved.
Thieme Medical Publishers, Inc., 333 Seventh Avenue, 18th Floor, New York, NY 10001, USA

DOI https://doi.org/10.1055/s-0043-1777061.
ISSN 2472-8446.

This document was downloaded for personal use only. Unauthorized distribution is strictly prohibited.

repair or replace the prosthesis itself before reducing the hip dislocation, which may contribute to the increased risk of open reduction in bipolar HA.[16]

A recent study has shown an IPD rate of 13% during manual reduction of dislocated bipolar HA,[14] prompting the need for further study of this phenomenon. We herein describe a case of bipolar prosthetic dissociation during manual reduction of a dislocated HA. We also review the literature to discuss the consequences of this complication, including risks with revision surgery and potential loosening of the prosthetic's mobile components.

Methods

We reviewed the PubMed database for the following keywords: "bipolar," "hemiarthroplasty," "component," "disassembly," "dissociation," and "dislocation." Our inclusion criteria included the publication formats of case reports, case series, observational studies, and randomized trials. We also required publications to be available in English. Our search yielded 18 case reports/series[11–13,15,17–30] collectively presenting 45 cases of IPD among bipolar HA patients, as well as 4 observational studies[14,31–33] presenting 27 more IPD cases. From each publication included in this literature review, we categorized the described IPD cases both by the implant component involved in the dissociation and by etiology (►**Table 1**).

We encountered a case of IPD at our own institution in April 2021. A 76-year-old male patient with a history of Parkinson's presented to our institution with a displaced right femoral neck fracture after a fall. He was treated with cemented bipolar HA using a posterolateral approach (►**Figs. 1** and **2**) with proper restoration of leg length and offset. Two months postoperatively, this patient flexed the hip upon standing from a low seat, and his right hip dislocated posteriorly (►**Fig. 3**). A closed reduction with propofol sedation in the emergency department setting was attempted, which resulted in a reduction clunk and improvement in the leg's clinical length and alignment, but further imaging showed IPD of the bipolar prosthesis (►**Fig. 4**). The specific form of IPD in this patient's prosthesis was dissociation of the outer femoral head from the inner head caused by closed reduction maneuvers and levering of the outer shell against the pelvis during traction maneuvers. This required subsequent open reduction and revision of the femoral head component. At the time of open reduction, the femoral head was revised to a one-size-longer unipolar prosthesis (►**Fig. 5**) and the patient has experienced no further dislocation events at 6-month follow-up. The patient has provided their informed consent for their relevant medical information to be published in this journal article.

Results

IPD refers to the dissociation or misalignment of components within a bipolar HA prosthesis that can arise from prosthetic dysfunction or damage, and is typically associated with manual reduction after a dislocation event. From a review of the literature, we have found that this is a broad and diverse group of complications. IPD can arise spontaneously,[26] with trauma such as prosthesis dislocation,[11,13,15,23,24] and during reduction maneuvers for a dislocated prosthesis.[12] IPD has also been found to occur after erosion or fracture of the PE liner.[18,31] Dissociation can be further categorized according to the specific component that has dissociated from its proper position, including the outer head, PE liner, locking ring, and femoral stem. For instance, one research group has identified three different subtypes of locking mechanism failure alone: detached ring, dissociation of inner and outer heads, and the cooccurrence of both.[31]

We found that the majority (61.1%) of cases involved the inner head or outer head/cup of the implant, while the PE liner or locking ring was involved in 36.1% of cases. In contrast, the femoral stem or neck of the implant was rarely involved in IPD events. The predominating etiology for IPD was spontaneous (48.6%), in which there was no identifiable preceding trauma on the hip joint. Several IPD cases occurred due to trauma, of which the majority was specifically hip dislocation (18.1%) when the outer head/cup of the prosthesis was displaced from the acetabulum, while another quarter of cases occurred iatrogenically as a result of closed reduction maneuvers (26.4%).

Discussion

Despite general consensus on choosing HA over THA in older patients with lower ambulatory demand, the choice between unipolar and bipolar HA remains controversial. A 2005 international survey of operative management of femoral neck fractures showed that surgeons had varied preferences in their choice of arthroplasty for older patients with Garden type IV fractures, with 32% preferring unipolar HA and 41% preferring bipolar.[7] Managing a patient using HA involves weighing a variety of implant options, including cemented and uncemented femoral stems, fixed-neck and modular-neck, and unipolar and bipolar femoral head designs.[34] With each category of implant options, several factors about the case such as the patient's bone health, age, potential comorbidities, surgeon preferences and familiarity, patient priorities when weighing quality of life against risk of revision, and implant cost must all be reviewed in making a final decision on HA implant design. While surgeons performing THA, as opposed to HA, may consider the risk of IPD in choosing a dual-mobility implant due to the more robust body of work on this prosthetic's risk,[35] we reinforce that this phenomenon also has the potential to occur in HA when selecting a bipolar implant and must be similarly considered as a potential risk to the patient by treating physicians.

IPD of dual mobility implants in THA has been documented in the literature as early as 2007,[36] nearly three decades after the first implant was introduced in Europe in 1979.[37] Some aspects of IPD in dual mobility THA implants are similar to those in bipolar HA implants. Both implants have a femoral component that consists of a femoral stem or neck with a small-diameter head that articulates within a PE outer head or liner, and the outer head is then involved in a

 © 2024. Thieme. All rights reserved.

This document was downloaded for personal use only. Unauthorized distribution is strictly prohibited.

Table 1 Findings of the reviewed sources on cases of intraprosthetic dissociation

Author (publication year)	Study type	Patient sample (*N*)	Cases of IPD (*N*)	Cases per implant component involved (*N*)			Cases per etiology (*N*)				
				Inner head or outer head/cup	PE liner or locking ring	Femoral stem/ neck	Spontaneous	Trauma: Dislocation	Trauma: Other	Iatrogenic: Closed reduction	Unknown
Marcelino Gomes et al (2011)[11]	CS	1	1	1				1			
Yun et al (2010)[12]	CS	1	1	1						1	
Loubignac and Boissier (1997)[13]	CS	2	2	2						2	
Georgiou et al (2006)[15]	CS	5	5	4	1		2	1		2	
Barmada and Mess (1987)[17]	CS	2	3		3		3				
Calton et al (1998)[18]	CS	5	5		5		5				
Corteel and Putz (1996)[19]	CS	1	1	1							1
Guo et al (2008)[20]	CS	1	1	1				1			
Sevinç (2021)[21]	CS	2	2		2				1	1	
Kim (1986)[22]	CS	1	1		1		1				
Lee et al (2008)[23]	CS	1	1	1				1			
Tanaka et al (2002)[24]	CS	1	2	2			1		1		
Shiga et al (2010)[25]	CS	1	1			1	1				
Uruç et al (2017)[26]	CS	5	5	5			3			2	
Moores et al (2013)[27]	CS	1	1	1			1				
Star et al (1992)[28]	CS	3	3	1	1	1				3	
Tabutin and Damotte (2004)[29]	CS	4	4	4			4				
Herzenberg et al (1988)[30]	CS	3	6		6		5		1		
Lee et al (2018)[14]	RO	55	7	7						7	
Hasegawa et al (2004)[31]	RO	61	7		7		7				
Bhuller (1982)[32]	RO	33	2	2			2				
Figved et al (2006)[33]	RO	350	11	11				9	1	1	
Total cases, *N* (%)			72	44 (61.1)	26 (36.1)	2 (2.8)	35 (48.6)	13 (18.1)	4 (5.6)	19 (26.4)	1 (1.4)

Abbreviations: CS, case study or series; IPD, intraprosthetic dissociation; PE, polyethylene; RO, retrospective observational study.

 © 2024. Thieme. All rights reserved.

This document was downloaded for personal use only. Unauthorized distribution is strictly prohibited.

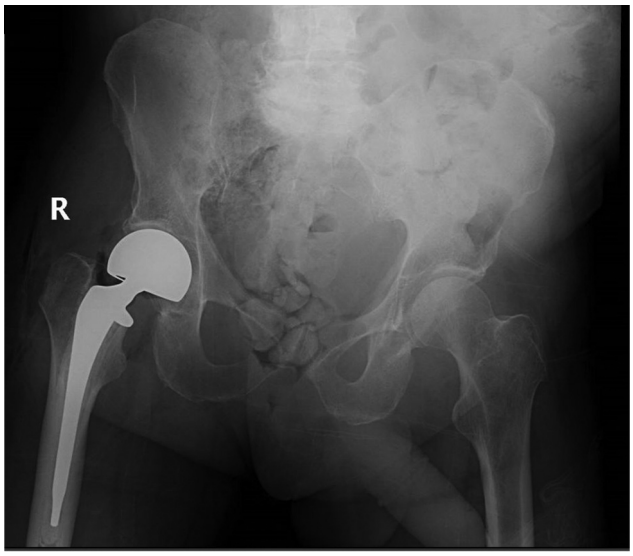

Fig. 1 Immediately postoperative anteroposterior radiograph showing right bipolar hemiarthroplasty implant with pelvic view.

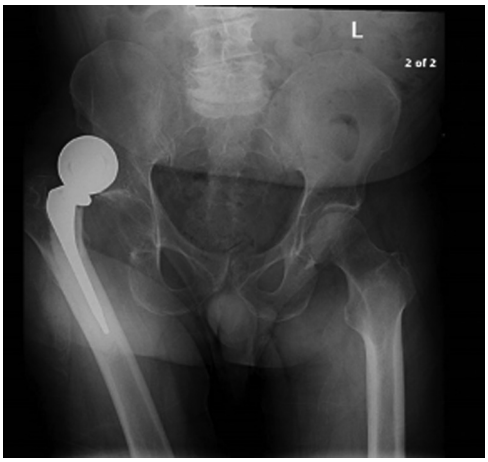

Fig. 3 Anteroposterior radiograph showing dislocation of the right bipolar hemiarthroplasty implant.

large-diameter articulation with the acetabulum.[35] With such similarities in the dual-articulation design, IPD of both implants frequently manifests as a separation of the smaller femoral head from the outer head,[38] at times with migration of the outer head from the acetabular space as in our case. However, IPD of bipolar implants has demonstrated its difference from dual mobility IPD by also involving intraprosthetic interfaces other than the two articulating heads, such as the femoral stem[25,28] and the locking ring within the PE liner.[31] IPD cases in dual mobility implants may occur due to mechanical loosening from wear of the PE liner,[38] typically in late IPD, or from traumatic causes such as closed reduction attempts in early IPD[35] which involve the "bottle-opener" mechanism.[13] While IPD in bipolar HA has occurred from these two causes (►**Table 1**), it has also occurred spontaneously with no erosion of the PE liner.[26] The unique etiologies and components involved in IPD of bipolar implants highlight the need for further study of IPD in HA as it has been widely studied in dual mobility THA.

Close to half of reported IPD in bipolar HA has occurred due to hip dislocation or during reduction maneuvers (44.5%, ►**Table 1**), which indicates that reducing the frequency of dislocation may be a critical step toward decreasing the risk of IPD. There has been extensive study of hip HA surgical approaches and their impact on postoperative dislocation rates. Surgeons commonly use three surgical approaches in hip HA[39]: anterior approach (AA), in which access to the anterior joint capsule is obtained using the plane between the sartorius, rectus femoris, and tensor fascia lata[40–42]; lateral approach (LA), in which the capsule is accessed by movement of the gluteus medius insertion[43,44]; and posterior approach (PA), in which the gluteus maximus muscle is divided along its fibers for posterior access to the joint.[45,46] The posterolateral approach (a type of PA) has been associated with a higher risk of dislocation than the anterolateral approach (considered either AA or LA), even when performing posterior repair to reattach the short external rotators and posterior joint capsule.[47] Other studies and meta-analyses have had similar

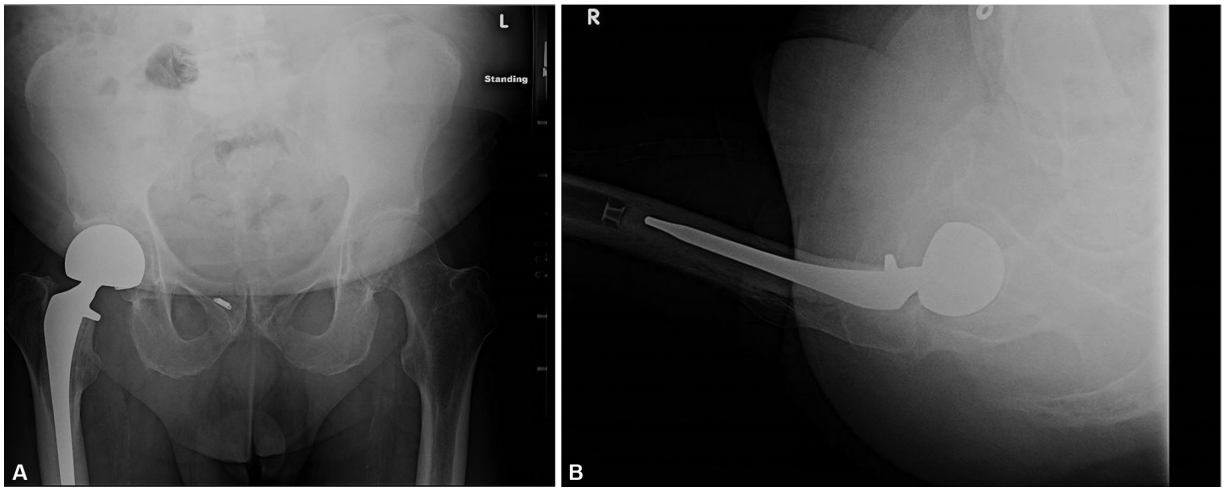

Fig. 2 Radiographs postoperative 1.5 months showing right bipolar hemiarthroplasty implant in correct position using anteroposterior views of the (**A**) pelvis and (**B**) lateral view of the right hip.

 © 2024. Thieme. All rights reserved.

This document was downloaded for personal use only. Unauthorized distribution is strictly prohibited.

Fig. 4 Anteroposterior radiograph showing intraprosthetic dissociation of the right bipolar hemiarthroplasty implant following attempted closed reduction maneuvers. Dissociation occurred between the outer and inner heads of the prosthesis.

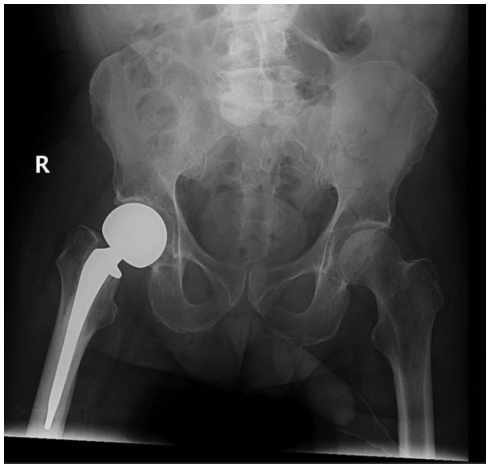

Fig. 5 Immediately postoperative anteroposterior radiograph of the pelvis, showing right femoral head revised with a unipolar hemiarthroplasty implant and the prior dislocation reduced.



Fig. 6 Manufacturer images of bipolar implant constructs, depicting (**A**) single locking mechanism (Bencox Bipolar Cup, Corentec[54]) and (**B**) dual locking mechanism with metal ring (Modular Bipolar System®, Zimmer[55]).

findings, with the PA found to be associated with higher risk of dislocation,[48–50] higher risk of reoperation due to dislocation,[51] and higher risk of both dislocation specifically and reoperation in general[39] compared with other surgical approaches, particularly the anterolateral and direct AAs. The PA may have advantages over other approaches such as decreased operative time[49]; however, other proposed advantages such as decreased wound infections, less pain, and better quality of life[52] have been less consistently reported.[39,50,53] With the PA introducing consistently higher rates of dislocation, we recommend surgeons consider performing hip HA using the AA or LA to reduce postoperative dislocations, and thus reduce the likelihood of IPD.

A significant proportion of IPD has occurred due to failure of the implant's locking mechanism, consisting of a PE ring and, in some manufacturer's models, a metal locking ring (36.1%, ►**Table 1**). Bipolar implant locking mechanisms may be divided into single and dual locking categories, both within the classic design of a metallic bipolar shell/outer cup containing a liner or insert of PE. In a single lock design, a PE ring is placed around the smaller-diameter neck of the femoral head after it has been inserted into the outer shell (►**Fig. 6A**); this PE ring replaced the locking leaflets of older prosthetics such as the Bateman UPF-I.[30] The PE ring then expands to fit into a matching groove near the peripheral rim of the PE liner which serves to lock the femoral head within the shell during hip articulation. In a dual locking mechanism, there is an additional metal locking ring anchored in the outer surface of the PE liner that enhances its close fit within the metal shell (►**Fig. 6B**). Prosthetics such as the Bencox Bipolar Cup (Corentec, Cheonan, South Korea), Bencox Bipolar Head (Aesculap, Tuttlingen, Germany), and Bencox Self-Centering Cup (DePuy, Warsaw, IN) are equipped with a single locking mechanism, while others like the Multipolar Cup and Modular Bipolar System (Zimmer, Warsaw, IN) and RINGLOC Cup (Biomet, Warsaw, IN) have a dual locking mechanism.[14] In many cases of IPD, failure of the locking mechanism has largely been attributed to macroscopic wear of the PE ring. The PE ring may degrade due to persistent impingement of the femoral neck on the ring from wider oscillations of the hip,[31] for example, with deep flexion and extension, or following natural wear of a thinner PE liner[18] that permits looser articulation of the femoral head within the outer cup construct. As the PE ring degrades from the peripheral rim, there is further opportunity for dislodgement of the metal locking ring in dual locking implants, with or without visible deformity in the metal ring.[31] With PE wear comes the dispersal of debris within the acetabular space, which has been observed alongside acetabular osteolysis[18] leading to implant failure.

Based on these proposed etiologies for PE ring degradation, surgeons may mitigate this process by cautioning their patients about wide hip oscillation movements and selecting thicker PE liners as a part of their implant construct. Preliminary research has also suggested that implants with a single locking mechanism are associated with increased risk of IPD during closed reduction compared with those with a dual locking mechanism (7 IPD cases out of 55 hips, 6 with single locking mechanism, $p = 0.04$).[14] While further studies are

 © 2024. Thieme. All rights reserved.

This document was downloaded for personal use only. Unauthorized distribution is strictly prohibited.

needed to control for potential confounding factors, evaluate the biomechanics of locking mechanism failure, and compare failure rates between implant manufacturers, the existing data suggest that surgeons may decrease the rate of locking mechanism failure and thus decrease IPD risk by selecting dual locking implants.

Nearly, if not all, IPD cases require open surgery to correct the complication. This potential intervention is risky for bipolar HA patients precisely because they are typically preselected for being the oldest, least active adults with femoral neck fractures, and thus are less tolerant of surgical procedures in general. The risk of surgical intervention for IPD partially negates the potential benefit of slower acetabular wear with bipolar HA prostheses (compared with unipolar), and surgeons must weigh both factors in selecting the best prosthetic for a patient. In cases of outer head dissociation, correction via intraoperative reassembly of the dissociated component with the rest of the prosthesis may introduce an increased risk of future IPD by using the same components for repair. For example, outer head dissociation may indicate a degree of wear on the PE liner that is not clearly apparent on radiographic imaging, but may predispose the same prosthetic components to dissociate again. Because of this, the authors recommend replacing the entire femoral head construct when possible.

Conclusion

In conclusion, the risk of IPD must be considered when deciding whether a unipolar or bipolar HA implant is the better treatment for a patient's femoral neck fracture. The potential advantages of bipolar compared with unipolar HA, such as slower acetabular erosion and better HRQoL, have been inconsistent across the literature. Other advantages of bipolar HA are manufacturer-specific, in that some device companies offer more customization options with bipolar versus unipolar in terms of head/neck length and head circumference. Factors like the potentially higher cost and the complication risk of IPD remain consistent disadvantages that are exclusive to bipolar HA. When performing hip HA, surgeons may want to consider choosing unipolar prosthetics over bipolar to reduce future operative risks to the patient related to IPD, and they should be aware of this potential complication when choosing implants and especially when performing closed reduction maneuvers on dislocated bipolar HA implants.

Funding
None.

Conflict of Interest
None declared.

References

1 Fowler GC. Pfenninger & Fowler's Procedures for Primary Care. 4th ed. Philadelphia: Elsevier; 2020
2 Manaster BJ, May DA, Disler DG. Chapter 11: Hip and Femur. In: Manaster BJ, May DA, Disler DG, eds. Musculoskeletal Imaging: The Requisites. 4th ed. Philadelphia: Saunders; 2013:167–181
3 Hedbeck CJ, Blomfeldt R, Lapidus G, Törnkvist H, Ponzer S, Tidermark J. Unipolar hemiarthroplasty versus bipolar hemiarthroplasty in the most elderly patients with displaced femoral neck fractures: a randomised, controlled trial. Int Orthop 2011;35(11):1703–1711
4 Zi-Sheng A, You-Shui G, Zhi-Zhen J, Ting Y, Chang-Qing Z. Hemiarthroplasty vs primary total hip arthroplasty for displaced fractures of the femoral neck in the elderly: a meta-analysis. J Arthroplasty 2012;27(04):583–590
5 Dorr LD, Glousman R, Hoy AL, Vanis R, Chandler R. Treatment of femoral neck fractures with total hip replacement versus cemented and noncemented hemiarthroplasty. J Arthroplasty 1986;1(01):21–28
6 Gebhard JS, Amstutz HC, Zinar DM, Dorey FJ. A comparison of total hip arthroplasty and hemiarthroplasty for treatment of acute fracture of the femoral neck. Clin Orthop Relat Res 1992;(282):123–131
7 Bhandari M, Devereaux PJ, Tornetta P III, et al. Operative management of displaced femoral neck fractures in elderly patients. An international survey. J Bone Joint Surg Am 2005;87(09):2122–2130
8 Parker MJ, Rajan D. Arthroplasties (with and without bone cement) for proximal femoral fractures in adults. Cochrane Database Syst Rev 2010;6:CD001706
9 Yang B, Lin X, Yin XM, Wen XZ. Bipolar versus unipolar hemiarthroplasty for displaced femoral neck fractures in the elder patient: a systematic review and meta-analysis of randomized trials. Eur J Orthop Surg Traumatol 2015;25(03):425–433
10 Inngul C, Hedbeck CJ, Blomfeldt R, Lapidus G, Ponzer S, Enocson A. Unipolar hemiarthroplasty versus bipolar hemiarthroplasty in patients with displaced femoral neck fractures: a four-year follow-up of a randomised controlled trial. Int Orthop 2013;37(12):2457–2464
11 Marcelino Gomes LS, do Carmo W, de Souza W. Femoral stem dislodgement during bipolar hemiarthroplasty dislocation. Orthopedics 2011;34(06):203
12 Yun HH, Park JH, Park JW, Lee JW. Femoral stem displacement during closed reduction of a dislocated bipolar hemiarthroplasty of the hip. Orthopedics 2010;33(02):118–121
13 Loubignac F, Boissier F. Dissociation de la cupule au cours de la réduction d'une luxation de prothèse de hanche intermédiaire. [Cup dissociation after reduction of a dislocated hip hemiarthroplasty] Rev Chir Orthop Repar Appar Mot 1997;83(05):469–472
14 Lee YK, Park CH, Ha YC, Koo KH. What is the frequency of early dissociation of bipolar cups and what factors are associated with dissociation? Clin Orthop Relat Res 2018;476(08):1585–1590
15 Georgiou G, Siapkara A, Dimitrakopoulou A, Provelengios S, Dounis E. Dissociation of bipolar hemiarthroplasty of the hip after dislocation. A report of five different cases and review of literature. Injury 2006;37(02):162–168
16 Varley J, Parker MJ. Stability of hip hemiarthroplasties. Int Orthop 2004;28(05):274–277
17 Barmada R, Mess D. Bateman hemiarthroplasty component disassembly. A report of three cases of high-density polyethylene failure. Clin Orthop Relat Res 1987;224:147–149
18 Calton TF, Fehring TK, Griffin WL, McCoy TH. Failure of the polyethylene after bipolar hemiarthroplasty of the hip. A report of five cases. J Bone Joint Surg Am 1998;80(03):420–423
19 Corteel J, Putz P. Luxation-dissociation d'une prothèse biarticuleé de hanche. [Dislocation-dissociation of a bipolar hip prosthesis] Acta Orthop Belg 1996;62(03):173–176
20 Guo JJ, Yang H, Yang T, Tang T. Disassembly of cemented bipolar prothesis of the hip. Orthopedics 2008;31(08):813
21 Sevinç HF. Dissociation of bipolar components following bipolar hemiarthroplasty: a report of two different cases and review of the literature. Ulus Travma Acil Cerrahi Derg 2021;27(05):600–603
22 Kim YH. Late separation of femoral head from bipolar acetabular assembly. Due to creep deformation of cup's inner bearing. Orthop Rev 1986;15(10):673–676

 © 2024. Thieme. All rights reserved.

This document was downloaded for personal use only. Unauthorized distribution is strictly prohibited.

23 Lee HH, Lo YC, Lin LC, Wu SS. Disassembly and dislocation of a bipolar hip prosthesis. J Formos Med Assoc 2008;107(01):84–88
24 Tanaka K, Nakayama Y, Murashige R, et al. A dislocation of the inner head in bipolar prosthesis with a self-centering system: a case report. J Nippon Med Sch 2002;69(02):192–195
25 Shiga T, Mori M, Hayashida T, Fujiwara Y, Ogura T. Disassembly of a modular femoral component after femoral head prosthetic replacement. J Arthroplasty 2010;25(04):659.e17–659.e19
26 Uruç V, Özden R, Duman İG, Kalacı A Five cases of early dissociation between the bipolar hip endoprosthesis cup components; either spontaneously or during reduction maneuvers. Acta Orthop Traumatol Turc 2017;51(02):172–176
27 Moores TS, Blackwell JR, Chatterton BD, Eisenstein N. Disassociation at the head-trunnion interface: an unseen complication of modular hip hemiarthroplasty. BMJ Case Rep 2013. Doi: bcr2013200387
28 Star MJ, Colwell CW Jr, Donaldson WF III, Walker RH. Dissociation of modular hip arthroplasty components after dislocation. A report of three cases at differing dissociation levels. Clin Orthop Relat Res 1992;278:111–115
29 Tabutin J, Damotte A. Dissociation progressive intra prothétique d'une prothèse intermédiaire de hanche. A propos de 4 cas. [Progressive intra-acetabular dislocation of bipolar hip prostheses: four cases] Rev Chir Orthop Repar Appar Mot 2004;90(01):79–82
30 Herzenberg JE, Harrelson JM, Campbell DC II, Lachiewicz PF. Fractures of the polyethylene bearing insert in Bateman bipolar hip prostheses. Clin Orthop Relat Res 1988;228:88–93
31 Hasegawa M, Sudo A, Uchida A. Disassembly of bipolar cup with self-centering system: a report of seven cases. Clin Orthop Relat Res 2004;425:163–167
32 Bhuller GS. Use of the Giliberty bipolar endoprosthesis in femoral neck fractures. Clin Orthop Relat Res 1982;162:165–169
33 Figved W, Norum OJ, Frihagen F, Madsen JE, Nordsletten L. Interprosthetic dislocations of the Charnley/Hastings hemiarthroplasty–report of 11 cases in 350 consecutive patients. Injury 2006;37(02):157–161
34 Florschutz AV, Langford JR, Haidukewych GJ, Koval KJ. Femoral neck fractures: current management. J Orthop Trauma 2015;29 (03):121–129
35 De Martino I, D'Apolito R, Waddell BS, McLawhorn AS, Sculco PK, Sculco TP. Early intraprosthetic dislocation in dual-mobility implants: a systematic review. Arthroplast Today 2017;3(03): 197–202
36 Asselineau A, Da SC, Beithoon Z, Molina V. Prevention of dislocation of total hip arthroplasty: the dual mobility cup. Interact Surg 2007;2(3–4):160–164
37 Noyer D, Caton JH. Once upon a time.... Dual mobility: history. Int Orthop 2017;41(03):611–618
38 Philippot R, Boyer B, Farizon F. Intraprosthetic dislocation: a specific complication of the dual-mobility system. Clin Orthop Relat Res 2013;471(03):965–970
39 van der Sijp MPL, van Delft D, Krijnen P, Niggebrugge AHP, Schipper IB. Surgical approaches and hemiarthroplasty outcomes for femoral neck fractures: a meta-analysis. [published correction appears in J Arthroplasty 2020 Feb;35(2):603–604] J Arthroplasty 2018;33(05):1617–1627.e9
40 Light TR, Keggi KJ. Anterior approach to hip arthroplasty. Clin Orthop Relat Res 1980;152:255–260
41 Weber M, Ganz R. The anterior approach to hip and pelvis. Orthop Traumatol 2002;10(04):245–257
42 Baba T, Shitoto K, Kaneko K. Bipolar hemiarthroplasty for femoral neck fracture using the direct anterior approach. World J Orthop 2013;4(02):85–89
43 Bauer R, Kerschbaumer F, Poisel S, Oberthaler W. The transgluteal approach to the hip joint. Arch Orthop Trauma Surg 1979; 95(1–2):47–49
44 Palan J, Beard DJ, Murray DW, Andrew JG, Nolan J. Which approach for total hip arthroplasty: anterolateral or posterior? Clin Orthop Relat Res 2009;467(02):473–477
45 Gibson A. Posterior exposure of the hip joint. J Bone Joint Surg Br 1950;32-B(02):183–186
46 Parker MJ. Lateral versus posterior approach for insertion of hemiarthroplasties for hip fractures: a randomised trial of 216 patients. Injury 2015;46(06):1023–1027
47 Enocson A, Tidermark J, Tornkvist H, Lapidus LJ. Dislocation of hemiarthroplasty after femoral neck fracture: better outcome after the anterolateral approach in a prospective cohort study on 739 consecutive hips. Acta Orthop 2008;79(02):211–217
48 Keene GS, Parker MJ. Hemiarthroplasty of the hip–the anterior or posterior approach? A comparison of surgical approaches. Injury 1993;24(09):611–613
49 Kunkel ST, Sabatino MJ, Kang R, Jevsevar DS, Moschetti WE. A systematic review and meta-analysis of the direct anterior approach for hemiarthroplasty for femoral neck fracture. Eur J Orthop Surg Traumatol 2018;28(02):217–232
50 Pajarinen J, Savolainen V, Tulikoura I, Lindahl J, Hirvensalo E. Factors predisposing to dislocation of the Thompson hemiarthroplasty: 22 dislocations in 338 patients. Acta Orthop Scand 2003; 74(01):45–48
51 Leonardsson O, Kärrholm J, Åkesson K, Garellick G, Rogmark C. Higher risk of reoperation for bipolar and uncemented hemiarthroplasty. Acta Orthop 2012;83(05):459–466
52 Kristensen TB, Vinje T, Havelin LI, Engesæter LB, Gjertsen JE. Posterior approach compared to direct lateral approach resulted in better patient-reported outcome after hemiarthroplasty for femoral neck fracture. Acta Orthop 2017;88(01):29–34
53 Leonardsson O, Rolfson O, Rogmark C. The surgical approach for hemiarthroplasty does not influence patient-reported outcome : a national survey of 2118 patients with one-year follow-up. Bone Joint J 2016;98-B(04):542–547
54 Simple Locking Ring Mechanism. Corentec. Updated Aug 20, 2023. Accessed August 21, 2023 at: http://www.corentec.com/product_view_eng.php?bid=6&c1=1
55 Modular Bipolar Head. Design Rationale. Surgitech Accessed August 21, 2023 at: http://surgitech.net/wp-content/uploads/2020/12/Modular-Bipolar-Head-Surgical-Technique.pdf

This document was downloaded for personal use only. Unauthorized distribution is strictly prohibited.

 © 2024. Thieme. All rights reserved.