



Advanced Pediatric-Type Follicular Lymphoma, Consequences of a Late Presentation in a Resource-Poor Setting: Case Report and Literature Review

Anthony Chibueze Nlemadim¹ Theophilus Ipeh Ugbem² Gabriel Unimke Udie³
Godwin Cletus Omini⁴ Eghomwanre Davis Izeke¹ Olufunke Folaranmi Adedokun¹
Ekaete Joseph Asuquo¹ Martin Madu Meremikwu¹ Friday Akwagiobe Odey¹

¹ Department of Paediatrics, University of Calabar Teaching Hospital, Calabar, Nigeria

² Department of Pathology, University of Calabar, Calabar, Nigeria

³ Department of Surgery, University of Calabar Teaching Hospital, Calabar, Nigeria

⁴ Department of Haematology, University of Calabar Teaching Hospital, Calabar, Nigeria

Address for correspondence Anthony Chibueze Nlemadim, MBBS, FWACP (Paed.), Paediatric Haematology-Oncology Unit, Department of Paediatrics, University of Calabar Teaching Hospital, Calabar, Cross River State, Nigeria (e-mail: tonymlemas@gmail.com).

Ind J Med Paediatr Oncol

Abstract

Pediatric-type follicular lymphoma (PFL) is a rare, nonaggressive, slow-growing (indolent), non-Hodgkin lymphoma that is typically seen in males as a localized disease with excellent outcomes. It is largely different from follicular lymphoma (FL). Few published studies on PFL are case series in developed nations. We report on a patient with advanced PFL, a 14-year-old female with 5-year history of neck swellings, abdominal distension for a month, and pericardial effusion, among others. The swellings waxed and waned; and involved all the peripheral lymph nodes. Tuberculosis (TB) GeneXpert and human immunodeficiency virus (HIV) screening were negative. She received anti-TB drugs prior to presentation in our hospital where nodal histopathology showed effaced architecture with diffuse follicles and abundant blastoid cells as well as negative CD5 and BCL2, and positive CD10 and CD20. Diagnosis of PFL (stage 3) was made. She completed six courses of cyclophosphamide, doxorubicin, vincristine, and prednisolone and is well 9 months after therapy. The PFL usually presents with stage 1 or 2 disease unlike in the index female case that was also complicated by effusion and ascites due to late presentation. It responded to chemotherapy and has not reoccurred; in contrast to classic FL and reactive follicular hyperplasia (RFH) which should be differentiated from PFL. Although RFH can be caused by TB or HIV, they are not causes of malignant lymphadenopathy. Physicians should be aware of PFL which may present in high clinical stages, but still retain its good prognosis, for the purposes of counseling.

Keywords

- ▶ pediatric
- ▶ follicular
- ▶ advanced
- ▶ lymphoma
- ▶ resource-poor

DOI <https://doi.org/10.1055/s-0043-1777042>.
ISSN 0971-5851.

© 2023. The Author(s).

This is an open access article published by Thieme under the terms of the Creative Commons Attribution License, permitting unrestricted use, distribution, and reproduction so long as the original work is properly cited. (<https://creativecommons.org/licenses/by/4.0/>)
Thieme Medical and Scientific Publishers Pvt. Ltd., A-12, 2nd Floor, Sector 2, Noida-201301 UP, India

Introduction

In 2008, the World Health Organization (WHO) acknowledged a subset of the classic follicular lymphoma (FL) called pediatric FL because of its distinctive clinical and genetic characteristics.¹ It was later recognized as a definite entity as pediatric-type FL (PFL) in the 5th edition (2016) of WHO classification of hematolymphoid tumors because its symptoms rarely occur in adults.² It is a rare indolent type of non-Hodgkin lymphoma (NHL) that is almost exclusively found in males less than 18 years of age and presents in low clinical stages with excellent prognosis.^{3–6} This is unlike the classic FL which is usually seen in adults as nodal disease in advanced clinical stages.^{7,8}

Despite the subtle differences in the histological grades and immunohistochemistry (IHC) of known indolent NHL (nodal pediatric marginal zone lymphoma, small lymphocytic lymphoma, classic FL), diagnosis of PFL may be challenging especially in low- and middle-income countries (LMICs) where there are paucity of resources and studies on the malignancy.^{6,9,10} Furthermore, majority of patients present in late disease stages mainly because of financial constraints since payment for hospital care is out-of-pocket.¹¹

While there is dearth of published studies on PFL in resource-poor settings like sub-Saharan Africa, most available literature on PFL are case reports and series performed in Western countries.^{3,5–8,12} From the foregoing, we report a patient diagnosed of PFL with some atypical clinical features.

Case Report

A 14-year-old female presented with 5-year history of neck swellings, 1 month history of irregular fever and abdominal swelling, and progressive difficulty in breathing for a week. Neck swellings were gradual in onset, painless, waxed and waned in size, and worse over the left part of the neck with associated snoring. She was noticed to be losing weight 2 years later but there was no history of chronic cough, or drenching night sweat or contact with an open case of pulmonary tuberculosis (TB). She had diffuse abdominal distension which progressively increased in size with easy satiety but no pain, vomiting, diarrhea, or constipation. Patient initially took over-the-counter medications for a year before visiting a secondary health facility where GeneXpert of gastric aspirate for *Mycobacterium tuberculosis* performed was negative. She received anti-TB drugs and was referred to our facility but delayed to come because of financial constraints. However, as breathlessness worsened, she presented to us. She received all childhood immunizations and had not attained thelarche or menarche. She is the only child of her parents who are of low socioeconomic status.

At first presentation to us, she was in respiratory distress with SPO₂ of 89% in room air. She was emaciated with a body mass index of 15.1 kg/m² (< 3rd percentile for age and sex) and was febrile. She was noticed to have multiple, mobile, firm, discrete, nontender, cervical, supraclavicular, axillary,

and inguinal masses largest measuring 6 cm by 5 cm in the left axilla. The palatine tonsils were moderately enlarged in addition to enlarged liver and spleen. Her cardiovascular examination was essentially normal except for muffled heart sounds and sinus tachycardia. Her respiratory and central nervous systems were also noncontributory.

Upon admission in the emergency room, sepsis was also suspected. Oxygen and intravenous antibiotics were commenced. She was nursed in cardiac position and plain chest X-ray done the following day showed enlarged cardiac silhouette, axillary and supraclavicular masses. Full blood count showed total white blood cell of $18.8 \times 10^3/\mu\text{L}$ ($4\text{--}12 \times 10^3$), neutrophil of 46.4%, lymphocyte of 42%, monocyte of 7.7%, hematocrit of 27.5%, and platelet of $220 \times 10^3/\mu\text{L}$ ($150\text{--}450 \times 10^3$). Electrolytes (urea, sodium, potassium, chloride, bicarbonate, and creatinine) were normal. Human immunodeficiency virus was negative and blood culture yielded no growth. Uric acid was 0.8 mmol/L (up to 0.36) and allopurinol was commenced by the third day of admission.

The cardiothoracic surgeons reviewed; chest x-ray and echocardiography (ECHO) done on the third day of admission revealed massive pericardial effusion of approximately 600 mL and no anterior mediastinal mass (→ Fig. 1). Pericardial catheterization done the same day drained approximately 1.8 L of serosanguineous fluid over 48 hours. The cytology of the fluid showed no malignant cell. Thereafter, the dyspnea markedly resolved and the oxygen saturation in room air was > 95%. Abdominal ultrasound scan done on the fifth day of admission showed hepatosplenomegaly, mild ascites, and enlarged para-aortic lymph nodes and she was transferred to the pediatric medical ward for continued care.

Axillary lymph node biopsy was performed the following day. The histopathology (microscopy) result received on the 12th day of admission revealed thick fibrous capsule, partly

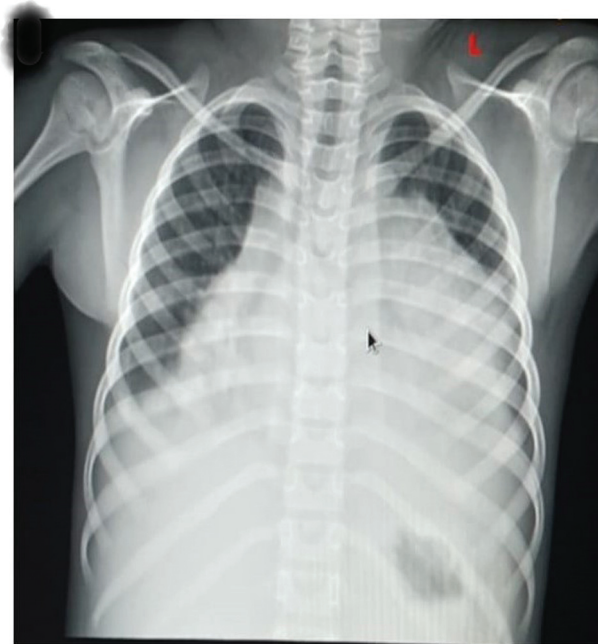


Fig. 1 Plain chest X-ray of the patient.

diffuse and partly nodular lesions with partial effacement composed of large neoplastic mononuclear cells having abundant clear cytoplasm (centroblasts) $> 15/\text{high-power field}$ (grade 3). They were surrounded by dense population of small cleaved cells (centrocytes), histiocytes, and few eosinophils suggestive of FL (► **Fig. 2**). The IHC result received on the 20th day of admission showed CD5 negative, CD10 positive, CD20 positive, and BCL2 negative; confirming diagnosis of PFL. BCL6 and Ki-67 panels as well as cytogenetic studies were not available. GeneXpert of the biopsied sample detected no TB. Repeat ECHO at this point showed minimal pericardial fluid and ejection fraction of 88%. Diagnosis of PFL (St. Jude stage 3) was made.

Meanwhile, on the seventh day of admission, bone marrow aspiration was done. It showed increased erythropoiesis, normoactive myeloid cells at different stages of maturation, normoactive lymphopoiesis, and $< 5\%$ plasma cells but no

malignant or foreign cell. The peripheral blood film was normal with small mononuclear cells that had thin clear rim of cytoplasm, regular nuclear outline, and condensed nuclear chromatin pattern.

After receiving the histopathology result, chemotherapy was prescribed but was commenced on day 21 of admission due to financial constraints. She received six courses of cyclophosphamide, doxorubicin, vincristine, and prednisolone (CHOP) according to the National Comprehensive Cancer Network (NCCN) guideline.¹³ Parents could not afford rituximab. All the symptoms resolved by the third chemotherapy course which was about 8 weeks after the initial presentation. She developed syndrome of inappropriate antidiuretic hormone secretion after the fourth course of chemotherapy and was appropriately managed. Child is regular on follow-up clinic visits with no symptom, sign, or palpable lymph node, 9 months after chemotherapy.

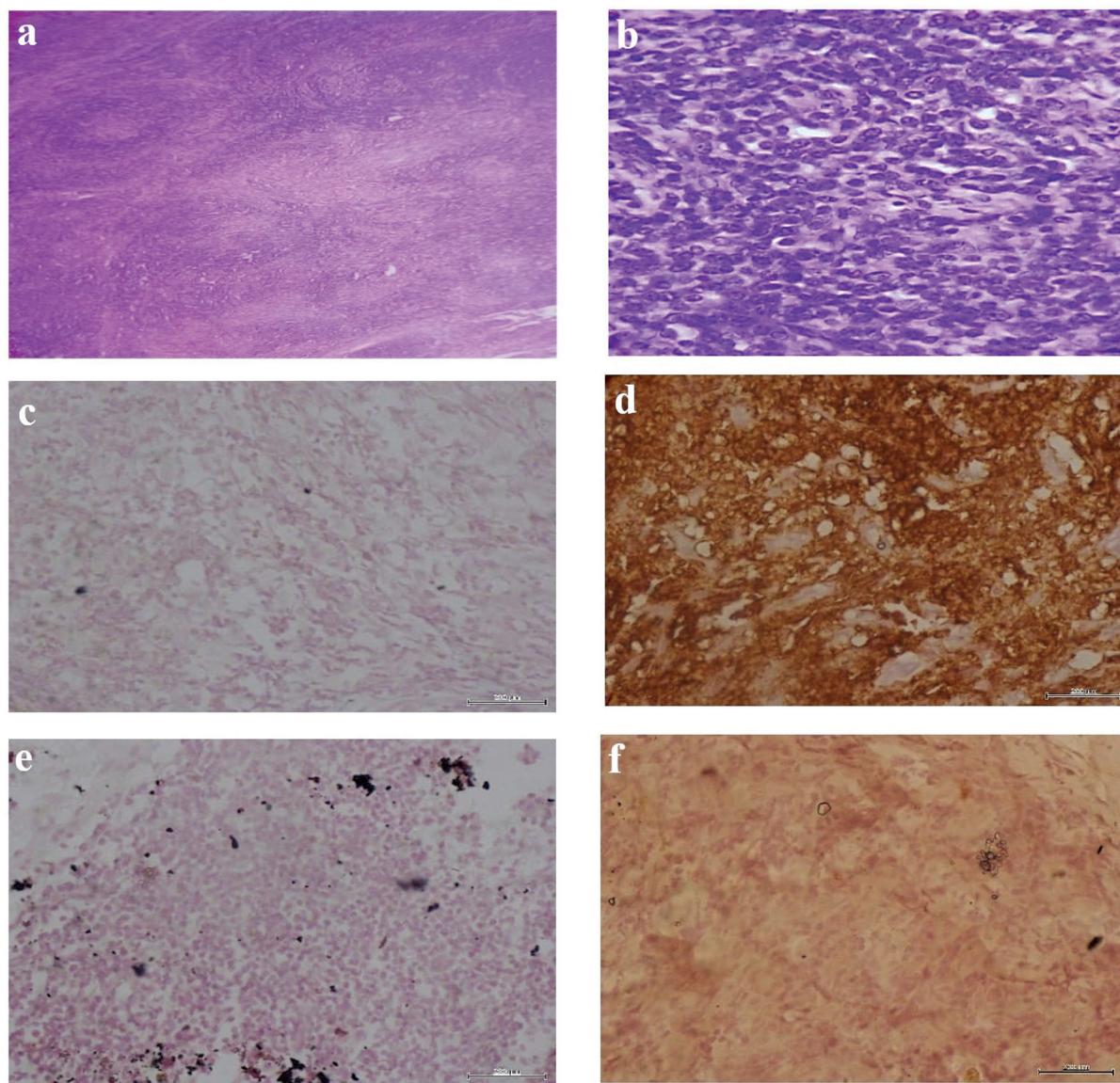


Fig. 2 Histopathology of the biopsied lymph node. (A) Partly effaced lymph node architecture by expansile follicle. Few follicles seen (hematoxylin and eosin [H&E] $\times 40$). (B) Numerous centroblasts and centrocytes (H&E $\times 400$). (C) CD5 stain negative. (D) CD10 stain strongly positive. (E) BCL2 negative in the follicles. (F) Positive CD20 staining.

Literature Review and Discussion

The PFL was searched in Google Scholar and PubMed using the following terms: “Pediatric,” “Follicular,” “Lymphoma,” “Nigeria,” and “Africa.” The PFL is very uncommon. It constitutes less than 3% of all childhood NHL with median age on presentation of 11 to 14 years (age range 3–25 years) and male-to-female ratio of 2.3:1 to 5.8:1 according to case series done in the United States, United Kingdom, and Italy.^{3,6,8,14} There is paucity of similar published data from sub-Saharan Africa. A study done by Adoke and Kabir between 2016 and 2017 in Northern Nigeria showed that 3 out of 9 pediatric cancers were FL with male-to-female ratio of 2:1 which is similar to 2.3:1 obtained by Lorscheid et al.^{3,10} This is despite the larger sample size of 23 in the study by Lorscheid et al who performed histopathology, IHC, and molecular analysis unlike that done in Nigeria where only histopathology and IHC were performed. These data are in consonance with the female case in this study whose symptoms started at the age of 9 years. On the contrary, indolent tumors like the classic FL and small lymphocytic lymphoma all have median age at onset of 60 to 65 years.^{9,15} The lack of studies may be due to the near absence of the malignancy in our region unlike in the industrialized countries of North America, Europe, and Asia where approximately 50% of healthy persons bear the *bcl-2* gene, the hallmark of FL.¹⁶ Other reasons for the rarity of PFL in LMICs may be lack of awareness and diagnostic resources with majority of diagnosis made from results obtained at the level of fine-needle aspiration cytology.¹⁰

Clinical Presentation

The PFL is usually a localized disease involving commonly the lymph nodes of the head and neck region particularly the Waldeyer's ring.^{3,7,8,12,17} It commonly involves the cervical lymph nodes while the tonsils are the most frequent deep nodal involvement with stages 1 and 2 (76–81%) or 3 and 4 (4–20%) disease.^{3,7,12} The classic FL occurs more in adult females (male:female 9:20) as advanced disease (stages 3 and 4) and has no predilection to the head and neck region.^{8,17} Our index female patient initially had localized disease that gradually became advanced with hepatosplenomegaly over a 5-year period due to delay in presentation to the hospital. However, there was no central nervous system, bone, or bone marrow involvement in our patient which is in tandem with the 20-year retrospective case series on PFL performed by Oschlies et al.⁷ St Jude's clinical staging was used by Oschlies et al and in our index case who presented in stage 3 with peripheral and deep nodal involvements above and below the diaphragm as well as organomegaly. Furthermore, the involvement of the abdomen with B symptoms (fever and weight loss) are features usually seen in classic FL which is rare in those less than 20 years of age.¹⁸ Extranodal involvement of the parotid gland, kidneys, skin, and digestive system have also been described in PFL though they were absent in our case.⁷ In addition, our patient presented with pericardial effusion which may be due to mediastinal lymph node engorgement since the cytology of the fluid was acellular.¹⁹

The PFL, just like classic FL and nodal pediatric marginal zone lymphoma (PMZL), is a painless and slow-growing (indolent) tumor with duration of adenopathy of few months to 3 years.^{3,18,20,21} Our patient first presented to a health facility about a year after the onset of the adenopathy which is similar to the finding on length of adenopathy on first presentation of PMZL by Taddesse-Heath et al.²¹ In addition, nodal PMZL has predilection to the head and neck with low clinical stages and is commonly seen in adolescent males (5.4:1) but our patient was a female.²¹

Another very close differential of PFL is reactive follicular hyperplasia (RFH) which is a common and frequent cause of indolent lymphadenopathy that waxes and wanes.²² The adenopathy in our patient waxed and waned but nodal masses of PMZL do not have such characteristic. The RFH usually involves any group of lymph node unlike PFL.²²

Therefore, the atypical clinical features of PFL in our patient were female sex, very slow-growing tumor characteristics, B symptoms and hepatosplenomegaly, and involvement of all peripheral lymph nodes. Others include advanced clinical stage on presentation, presence of pericardial effusion and ascites, and emergency room care, all of which also culminated in the consequences of late presentation.

Pathogenesis

There is proliferation of mature B-cells in the germinal center of the follicles in lymph nodes of patients with PFL, the etiology of which is unknown.²³ The RFH is due to increase in proliferation of lymph node follicular B-cells due commonly to stimulation of humoral immune response by viruses and bacteria.²² The recurrent or seasonal infection by these organisms and the resolution of the adenopathy may explain the waxing and waning nature of RFH.

The lymphomagenesis of PFL has been linked to mutations of *TNFRSF14* and/or *MAP2K1* which are tumor-suppressor and antiapoptotic genes, respectively, in contrast to classic FL where histone-modifying genes are frequently mutated in a complex manner.^{24,25} While *TNFRSF14* gene links with a pathway that regulates B cell receptor activation, the *MAP2K1* gene prevents activation of B cell proliferation. Patients have been shown to have different mutations of *TNFRSF14* and/or *MAP2K1* probably at different times implying that some of these mutations may either encourage B cell proliferation in the follicles or inhibit it.²⁴ These recurrent mutations may be the reason PFL waxes and wanes. Furthermore, the low genomic complexity of PFL probably explains its indolent and less aggressive nature unlike in classic FL.²⁵ In contrast, the recurrent increase and decrease of tumor size in classic FL may be due to varying levels of “death-inducing” and “death-inhibiting” forms of *bcl-2* protein in the follicular cells.¹⁶

Histopathology

The lymph node in our patient showed partly effaced architecture; expansile follicles with similar sizes, shapes, and thinned out mantle zones; maintained marginal zone; and the characteristic centrocytes and centroblasts with WHO histologic grade 3 similar to PFLs reported in studies.^{3,5,7,8,12} A histopathologist described the morphology of the patient's

lymph node biopsied by a pediatric surgeon. Grade 3 is uncommon in classic FL which usually presents in grades 1 to 2 and no “starry-sky” appearance.⁸ However, the “starry-sky” appearance which is due to tingible-body macrophages was absent in our patient and it has been noted to be a nonspecific occasional finding in RFH, PFL, and nodal PMZL.^{3,5} The PMZL has effaced nodal architecture with marked expansion of the marginal zone and attenuated mantle zone of the follicles unlike in PFL.²¹ The follicles in RFH have different shapes and sizes; preserved mantle and marginal zones; discernible germinal center light and dark zones (polarity) with reactive lymphoid cells; and are arranged in the cortical area of the nodes.^{5,22} This is in contrast to the usually dense evenly distributed follicles with no polarity in PFL.^{5,22,26} In addition, the lymph node architecture in RFH is not effaced, consists of polymorphous germinal center cells with tingible-body macrophages unlike the monomorphous cells in PFL.^{5,17}

Immunohistochemistry and Molecular Analyses

The CD10 and BCL6 in PFL are usually strongly positive showing that the malignant B cells are derived from the germinal centers.^{3,8,12} Being mature B cells, the CD19, CD20, and CD79a are also positive but markers of T cells (CD5 and CD3) are negative.^{8,23} The BCL2 protein is sparingly and weakly expressed in PFL which is in contrast to the classic FL where BCL2 expression is associated with stage 3/4 disease.^{7,8,12} This is in conformity with the finding in our patient whose BCL2 and CD5 were negative while CD10 and CD20 were strongly positive. A specialist pathologist performed the IHC on the index patient's lymph node sample. The BCL2 is normally not expressed in the germinal centers; plays a role in apoptosis of nonselected B cells but it is positive in malignant tumors, like classic FL.^{3,23} Therefore, BCL2 alone should not be used as a differentiating diagnostic marker between PFL and classic FL.^{3,5} Hence, from the aforementioned pathology, our patient had PFL and not advanced classic FL because of her attenuated follicular

mantle zones, high histological grading with predominant blastoid cytology, and negative BCL2.

The RFH also expresses BCL6, CD10, CD21 (follicular dendritic meshwork marker), CD3 (T cell marker), and Ki-67 (a marker of proliferation) but BCL2 is negative.^{17,22,27,28} Nevertheless, the Ki-67 distribution is uniform in PFL unlike in RFH where it varies and FOXP1 is positive in PFL but negative in RFH.^{5,17} Conversely, nodal PMZL expresses CD20, CD43, and BCL2 but not the germinal center markers (CD10 and BCL6).^{17,21} The CD3 and CD5 are also negative while Ki-67 staining is weak. This implies that PMZL, a mature B cell lymphoma, does not originate from the follicular germinal centers like PFL. Meanwhile, IRTA1 has been shown to be a specific marker for nodal PMZL.^{9,29}

The PFL usually shows monoclonal immunoglobulin heavy chain gene (*IGH*) rearrangements; absent t(14;18) and *IRF4* translocations; and negative *BCL2* and *BCL6* rearrangements on fluorescence in situ hybridization analysis.^{6,12,25} The RFH and nodal PMZL show no gene rearrangement or translocation while classic FL typically depicts BCL2 rearrangement and t(14;18)(q32;q21)/*IGH*-*BCL2* translocation which distorts the apoptotic activities of BCL2.^{17,23}

Unfortunately, some of these panels and the molecular analyses were not performed in the patient due to their unavailability and paucity of fund. Payment of pediatric cancer care in LMICs like ours is borne by the parents. To have further confirmed PFL in our patient, the following would have helped: BCL6 (not expressed by classic FL and nodal PMZL), FOXP1 (negative in RFH), IRTA1 (positive only in PMZL), *IGH* gene rearrangements (negative in RFH and PMZL), and t(14;18) (typically positive in classic FL). However, demonstration of the absence of T cell origin (negative CD5), matured B cell status (positive CD20), presence of follicular germinal center marker (positive CD10), and absence of BCL2 points to PFL in our patient as depicted by the NCCN.¹³ This diagnosis is enhanced by the slow-growing, waxing, and waning adenopathy; and typical histopathologic nature of PFL which can be distinguished from its close differential diagnoses as summarized in ►Table 1.

Table 1 Summary of the usual salient features of the major differential diagnoses of pediatric-type follicular lymphoma

Features	PFL	RFH	Classic FL	Nodal PMZL
Male:Female ratio	Up to 5.8:1	Equal	9:20	5.4:1
Median age (y)	11–14	Any age	60–65	16
Site	Head and neck lymph nodes	Cervical and axillary nodes	No nodal predilection	Head and neck lymph nodes
Duration of adenopathy	Up to 3 years	Short (in months)	Short (in months)	Up to 2 years
Extranodal	Absent	Absent	Present	Absent
Histology grade	3	Not applicable	1–2	1–2
Clinical stage	Low (1–2)	Not applicable	High (3–4)	Low (1–2)
B symptoms	Absent	Not applicable	Present	Absent
Hepatosplenomegaly	Absent	Variable	Present	Variable
Bone marrow involvement	Absent	Variable	Present	Absent

(Continued)

Table 1 (Continued)

Features	PFL	RFH	Classic FL	Nodal PMZL
Nodal architecture	Effaced	Largely preserved	Effaced	Effaced
Follicular pattern	Closely packed follicles Nonprominent marginal zone	Different sizes and shapes of follicles Preserved marginal zone	Closely packed follicles Nonprominent marginal zone	Few follicles with large diameter Expanded marginal zones
Follicle characteristics	Attenuated mantle zone “Starry sky” present No polarity	Polarity of germinal centers “Starry sky” present Maintained mantle zone	Attenuated mantle zone No “starry sky” appearance No polarity	Near-absent mantle zones “Starry-sky” present No polarity
Cell types	Predominantly centroblasts	Small and large cells. No atypia	Predominantly centrocytes. Monoclonal cells	Polymorphic cells. Few centroblasts
CD3	Absent	Present	Absent	Absent
CD10	Present	Present	Present	Absent
BCL2	Absent	Absent	Present	Present
BCL6	Present	Present	Absent	Absent
FOXP1	Present	Absent	Absent	Absent
IRTA1	Absent	Absent	Absent	Present
<i>IGH</i> gene rearrangements	Present	Absent	Absent	Absent
<i>BCL2</i> rearrangement	Absent	Absent	Present	Absent
t(14;18)	Absent	Absent	Present	Absent
Relapse	Absent	Variable	Frequent	Infrequent
Prognosis	Excellent	Variable	Variable	Favorable

Abbreviations: FL, follicular lymphoma; PMZL, pediatric marginal zone lymphoma; PFL, pediatric-type follicular lymphoma; RFH, reactive follicular hyperplasia.

Treatment and Prognosis

The treatment options for PFL are surgery, chemotherapy, and radiotherapy.⁸ Local lymph node excision of stage 1 disease followed by “watch and wait” have been reported because PFL have been thought not to recur after surgery with or without systemic chemotherapy.^{4,8,12} The PFL is chemosensitive and the commonly preferred chemotherapy combination is rituximab, cyclophosphamide, hydroxydaunorubicin, vincristine, and prednisone (R-CHOP).^{8,13} Successes have been recorded with only CHOP with 2- and 5-year post-PFL therapy overall survival of 100 and >95%, respectively.^{3,4,17} Hence, the prognosis is excellent. Our patient was treated with only CHOP; surgery was not feasible because her disease was advanced; and she is alive with no feature of PFL, 9 months post-chemotherapy.

Similarly, other indolent B cell lymphomas like nodal PMZL and classic FL are treated like PFL with surgery and same chemotherapy.^{8,13} However, classic FL is fraught with refractoriness to therapy, relapses, progressive disease course, and poor outcome with median overall survival of 6 to 10 years.^{5,12,23} The nodal PMZL has excellent outcome like PFL but any relapse within 2 years posttherapy is associated with median survival of 3 to 5 years.²⁹ Treatment for RFH is aimed at eliminating the offending microorgan-

ism or treating the underlying cause, for example, autoimmune diseases and the prognosis depends on the etiology.^{26,27}

Conclusion

The PFL, a rare indolent cancer that usually present as localized disease, may first be seen in advanced stage and can be distinguished from its closest differential diagnoses (classic FL, RFH, and nodal PMZL) using their clinical features, immunohistopathology, and response to therapy. Physicians in LMICs should be aware of PFL when they encounter indolent lymphadenopathy because it may aid in parental counseling since the tumor may have very good prognosis even in advanced stages. More studies should be done to ascertain the prognostic significance of advanced PFL in resource-poor settings where patients are likely to present late for management.

Statement

This manuscript has been read and approved by all the authors who met the requirements for authorship. Each author believes that the manuscript represents an honest work.

Ethical Approval

Permission to conduct this study was obtained from the University of Calabar Teaching Hospital Health Research and Ethics Committee (UCTH/HREC/33/Vol.III/052).

Consent for Publication

Informed written consent was obtained from the patient's parents for this case report publication.

Patient Consent

Consent is given.

Authors' Contributions

1. A.C.N.: conceptualized the study and designed it; defined the intellectual content; performed literature search; acquired data from the patient case file; investigations analysis and interpretation; drafted, edited, and revised the manuscript; and gave final approval for publication.
2. T.I.U.: designed the study; defined some intellectual content; performed literature search; investigations analysis and interpretation; edited and revised the manuscript; and gave final approval for publication.
3. G.U.U.: designed the study; defined some intellectual content; investigations analysis and interpretation; edited and revised the manuscript; and gave final approval for publication.
4. G.C.O.: conceptualized the study and designed it; defined some intellectual content; performed literature search; investigations analysis and interpretation; edited and revised the manuscript; and gave final approval for publication.
5. E.D.I.: conceptualized the study; performed literature search; acquired data from the patient case file; investigations analysis; edited and revised the manuscript; and gave final approval for publication.
6. O.F.A.: conceptualized the study; performed literature search; acquired data from the patient case file; investigations analysis; edited and revised the manuscript; and gave final approval for publication.
7. E.J.A.: conceptualized the study; performed literature search; acquired data from the patient case file; investigations analysis; edited and revised the manuscript; and gave final approval for publication.
8. M.M.M.: designed the study; defined the intellectual content; investigations interpretation; edited and revised the manuscript; and gave final approval for publication.
9. F.A.O.: designed the study; defined the intellectual content; investigations interpretation; edited and revised the manuscript; and gave final approval for publication.

Financial Support, Grant, and Sponsorship

None.

Conflict of Interest

None declared.

Acknowledgment

None.

References

- 1 Campo E, Swerdlow SH, Harris NL, Pileri S, Stein H, Jaffe ES. The 2008 WHO classification of lymphoid neoplasms and beyond: evolving concepts and practical applications. *Blood* 2011;117(19):5019–5032
- 2 Swerdlow SH, Campo E, Pileri SA, et al. The 2016 revision of the World Health Organization classification of lymphoid neoplasms. *Blood* 2016;127(20):2375–2390
- 3 Lorscheid RB, Shay-Seymore D, Moore J, et al. Clinicopathologic analysis of follicular lymphoma occurring in children. *Blood* 2002;99(06):1959–1964
- 4 Attarbaschi A, Beishuizen A, Mann G, et al; European Intergroup for Childhood Non-Hodgkin Lymphoma (EICNHL) and the international Berlin-Frankfurt-Münster (i-BFM) Study Group. Children and adolescents with follicular lymphoma have an excellent prognosis with either limited chemotherapy or with a “Watch and wait” strategy after complete resection. *Ann Hematol* 2013;92(11):1537–1541
- 5 Agrawal R, Wang J. Pediatric follicular lymphoma: a rare clinicopathologic entity. *Arch Pathol Lab Med* 2009;133(01):142–146
- 6 Agostinelli C, Akarca AU, Ramsay A, et al. Novel markers in pediatric-type follicular lymphoma. *Virchows Arch* 2019;475(06):771–779
- 7 Oschlies I, Salaverria I, Mahn F, et al. Pediatric follicular lymphoma—a clinico-pathological study of a population-based series of patients treated within the Non-Hodgkin's Lymphoma-Berlin-Frankfurt-Munster (NHL-BFM) multicenter trials. *Haematologica* 2010;95(02):253–259
- 8 Liu Q, Salaverria I, Pittaluga S, et al. Follicular lymphomas in children and young adults: a comparison of the pediatric variant with usual follicular lymphoma. *Am J Surg Pathol* 2013;37(03):333–343
- 9 Margolskee E, Martin P. Lymphoproliferative disorders. In: Weksler BB, Schechter GP, Ely SA, eds. *Wintrobe's Atlas of Clinical Hematology*. 2nd ed. Philadelphia: Wolters Kluwer; 2018:331–335
- 10 Adoke KU, Kabir B. Correlation of fine-needle aspiration cytology and surgical excision in the diagnosis of patients with cancer. *Ann Trop Pathol* 2018;9:69–74
- 11 Jabbar AA. Challenges in treating solid tumors in developing countries. *Hematol Transfus Cell Ther* 2020;42:S10–S11
- 12 Louissaint A Jr, Ackerman AM, Dias-Santagata D, et al. Pediatric-type nodal follicular lymphoma: an indolent clonal proliferation in children and adults with high proliferation index and no BCL2 rearrangement. *Blood* 2012;120(12):2395–2404
- 13 National Comprehensive Cancer Network. *NCCN Harmonized Guidelines™ for Sub-Saharan Africa. B-Cell Lymphomas*. Version 5. 2022 Pennsylvania; 2022. Accessed July 11, 2023 at: <https://www.nccn.org/global/what-we-do/harmonized-guidelines>
- 14 Gross TG, Kamdar KY, Bollard CM. Malignant non-Hodgkin lymphomas in children. In: Blaney SM, Adamson PC, Helman LJ, eds. *Pizzo and Poplack's Pediatric Oncology*. 8th ed. Philadelphia: Wolters Kluwer; 2021:1803–1835
- 15 Onwubuya IM, Adelusola KA, Durosinmi MA, Sabageh D, Ezike KN. Lymphomas in Ile-Ife, Nigeria: immunohistochemical characterization and detection of Epstein-Barr virus encoded RNA. *J Clin Diagn Res* 2015;9(06):EC14–EC19
- 16 Biagi JJ, Seymour JF. Insights into the molecular pathogenesis of follicular lymphoma arising from analysis of geographic variation. *Blood* 2002;99(12):4265–4275
- 17 Verma A, Pan Z. Pediatric-type follicular lymphoma. *Hum Pathol Rep* 2022;27:300590
- 18 Press OW. Follicular lymphoma. In: Kaushansky K, Lichtman MA, Prchal JT, Levi M, Press OW, Burns LJ, Caligiuri MA, eds. *Williams Hematology*. 9th ed. New York: McGraw-Hill Education; 2016: 1641–1650
- 19 Çelik S, Lestuzzi C, Cervesato E, et al. Systemic chemotherapy in combination with pericardial window has better outcomes in

- malignant pericardial effusions. *J Thorac Cardiovasc Surg* 2014; 148(05):2288–2293
- 20 Farmanfarma KK, Kiasara SH, Hassanipour S, Salehiniya H. Non-Hodgkin's lymphoma in the world: an epidemiological review. *World Cancer Research J* 2020;7:e1520
 - 21 Tadesse-Heath L, Pittaluga S, Sorbara L, Bussey M, Raffeld M, Jaffe ES. Marginal zone B-cell lymphoma in children and young adults. *Am J Surg Pathol* 2003;27(04):522–531
 - 22 Miranda RN, Khoury JD, Medeiros LJ. Reactive Follicular Hyperplasia. *Atlas of Lymph Node Pathology*. New York: Springer; 2013:11–13
 - 23 Takata K, Miyata-Takata T, Sato Y, Yoshino T. Pathology of follicular lymphoma. *J Clin Exp Hematop* 2014;54(01):3–9
 - 24 Schmidt J, Ramis-Zaldivar JE, Nadeu F, et al. Mutations of *MAP2K1* are frequent in pediatric-type follicular lymphoma and result in ERK pathway activation. *Blood* 2017;130(03):323–327
 - 25 Schmidt J, Gong S, Marafioti T, et al. Genome-wide analysis of pediatric-type follicular lymphoma reveals low genetic complexity and recurrent alterations of *TNFRSF14* gene. *Blood* 2016;128(08):1101–1111
 - 26 Weiss LM, O'Malley D. Benign lymphadenopathies. *Mod Pathol* 2013;26(Suppl 1):S88–S96
 - 27 Balakrishna J. Reactive lymphadenopathy. *PathologyOutlines.com Michigan*; 2023. Accessed July 19, 2023 at: <https://www.pathologyoutlines.com/topic/lymphnodesreactivegeneral.html>
 - 28 Khanlari M, Chapman J. Pediatric type Follicular lymphoma. *PathologyOutlines.com. Michigan*; 2021. Accessed July 17, 2023 at: <https://www.pathologyoutlines.com/topic/lymphomafollicularchildhood.html>
 - 29 Rossi D, Bertoni F, Zucca E. Marginal-zone lymphomas. *N Engl J Med* 2022;386(06):568–581