



# Awake Craniotomy in a Pregnant Patient—A Unique Challenge

Kirandeep Kaur<sup>1</sup> Apoorva Singh<sup>1</sup> Kiran Jangra<sup>1</sup> Sushant K. Sahoo<sup>2</sup>

<sup>1</sup>Division of Neuroanaesthesia, Department of Anaesthesia and Intensive Care, Postgraduate Institute of Medical Education and Research, Chandigarh, India

<sup>2</sup>Department of Neurosurgery, Postgraduate Institute of Medical Education and Research, Chandigarh, India

Address for correspondence Kiran Jangra, M.D., D.M., Division of Neuroanaesthesia, Department of Anaesthesia and Intensive Care, Postgraduate Institute of Medical Education and Research, Chandigarh 160012, India (e-mail: drkiransharma0117@gmail.com).

J Neuroanaesthesiol Crit Care 2023;10:217–218.

Neurosurgical interventions in pregnancy pose a dual challenge of optimizing cerebral physiology without compromising fetal well-being. Intracranial pressure lowering strategies, such as mannitol or furosemide administration, may have an adverse effect on the fetus. More importantly, gestational hypertension or eclampsia may mimic the features of intracranial pathology and compromise the management. Here, we describe the perioperative management of a pregnant female posted for awake craniotomy (AC) and excision for intracranial space occupying lesion at 22 weeks of gestation with a special emphasis on selection of perioperative medications.

A 26-year-old right-handed female was presented in emergency room with new onset of seizures. Magnetic resonance imaging brain described a space-occupying lesion in the left temporal region (3 × 2.5 × 4 cm near Wernicke area's area → **Fig. 1A**) for which AC with cortical mapping and tractography was planned in lateral position (→ **Fig. 1B**). Her preoperative workup was acceptable, and there were no neurological deficits. The psychological preparation of the patient was done using standard protocol for AC in addition to explaining the benefits of avoiding the exposure of fetus to the anesthetic agents. The potential risks related to AC and the possibility of adverse maternal and fetal outcomes were also explained. Standard American Society of Anesthesiologists (ASA) guidelines for fasting were followed. Premedication included antiepileptics, aspiration prophylaxis (tab. ranitidine 150 mg and metoclopramide 10 mg) the night prior and on the day of surgery, and inj. progesterone (Proluton Depot 250 mg intramuscular) for tocolysis. Intraoperative monitoring included standard ASA monitors, invasive arterial blood pressure, and continuous cardiocography. We planned the awake-awake-awake technique. Infusion dexmedetomidine was started at 0.5 µg/kg/h to target Ramsay sedation score 2, which was stopped before the dural opening. Scalp block was given with 2% lignocaine adrenaline (1:2,00,000) and 0.25%

bupivacaine, 15 mL each (total volume: 30 mL). After scalp block, head was fixed with Sugita four pin head holder. Absence of pin response indicated the adequacy of scalp block. The needle electrodes were placed to record the motor-evoked potentials on both right-sided upper and lower limbs. The voltage was kept minimum to elicit the response during motor mapping as higher voltages can incite hypercontraction of the gravid uterus.<sup>1</sup> Language testing was done by stimulation of the language area while continuously communicating with the patient for the components of fluency and comprehension. The patient was calm, conscious, and cooperative throughout the procedure and maintained stable hemodynamics. Intraoperative medications included cefuroxime 1.5 g, ondansetron 4 mg, levetiracetam 1 g, and paracetamol 1 gm. The intraoperative course was uneventful. Postoperatively, there was no deficit in the mother and a healthy baby was delivered vaginally at 40 weeks gestational age.

AC is preferred for lesions near eloquent areas and in high-risk patients. There is very limited data in the form of isolated case reports or case series related to AC in pregnant females. AC has a dual advantage of real-time neurological monitoring and avoiding exposure of anesthetic agents to the developing fetus.<sup>2</sup>

There are a few challenges during AC in pregnant patients, which needs to be considered during surgery. Antiedema drugs, such as mannitol, cross the placenta and may cause fetal dehydration.<sup>3,4</sup> However, it had been safely used during pregnancy but in a smaller dosage, up to 0.5 g/kg. Dexamethasone is routinely given in intracranial space-occupying lesions to reduce perilesional edema. In addition, it helps in fetal lung maturation and reduces nausea and vomiting. Thus, it can be given safely to these patients.<sup>5</sup> These patients are at risk of excessive sedation due to internal endorphins release and hormonal changes. We should give judicious sedation that too under strict monitoring. Hence,

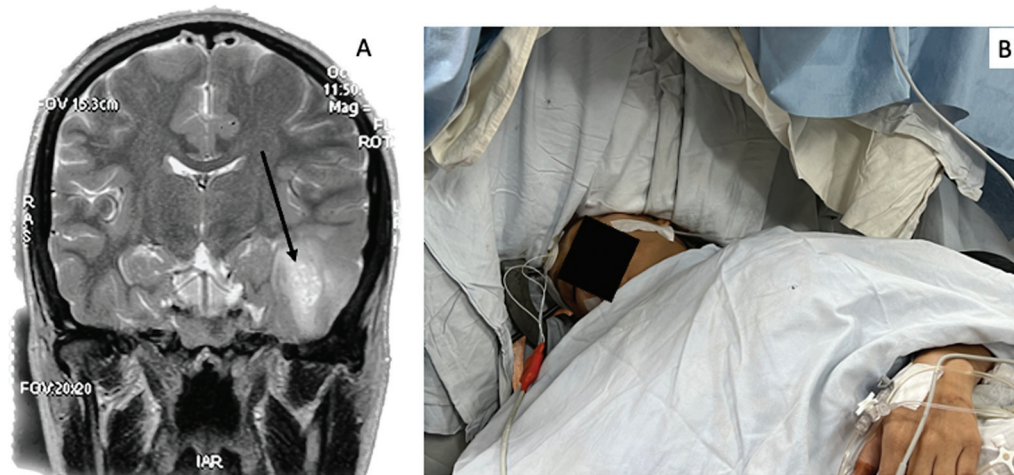
article published online  
February 23, 2024

DOI <https://doi.org/10.1055/s-0043-1776410>.  
ISSN 2348-0548.

© 2024. The Author(s).

This is an open access article published by Thieme under the terms of the Creative Commons Attribution License, permitting unrestricted use, distribution, and reproduction so long as the original work is properly cited. (<https://creativecommons.org/licenses/by/4.0/>)

Thieme Medical and Scientific Publishers Pvt. Ltd., A-12, 2nd Floor, Sector 2, Noida-201301 UP, India



**Fig. 1** (A) T2-weighted magnetic resonance imaging in coronal section showing hyperintense lesion (black arrow) along the left inferior temporal location with mild gyral expansion. (B) Intraoperative position of the patient in lateral decubitus.

we avoided loading dose of dexmedetomidine and other sedative analgesics.

We must be prepared for potential intraoperative complications too.<sup>6</sup> As antiepileptics have potential teratogenic effects, the drugs with minimal fetal effects should be chosen. For intraoperative seizures, the management line includes ice cold saline instillation in the surgical field followed by propofol boluses; if not controlled, midazolam and levetiracetam should be used.<sup>6</sup> If seizures are uncontrolled, we should follow the status epilepticus protocol for pregnant females.<sup>7</sup>

The hemodynamic target varies slightly from the non-pregnant patients, including maintaining normotension (20% baseline), euolemia, normoxia (partial pressure of oxygen > 80 mm Hg to avoid fetal hypoxia), normothermia, normocapnia in the early trimester, and normoglycemia (110–150 mg/dL) should be considered.<sup>8</sup> Mild hyperventilation (28–32 mm Hg) may be continued to maintain physiological hyperventilation in second and third trimester. It may not be possible to manipulate respiration in awake patients, but deep sedation should be avoided to prevent respiratory depression. Moderate-to-severe hyperventilation may reduce uterine blood flow. In advanced pregnancy, left uterine displacement should be done to avoid aortocaval compression. The current case was done in lateral position that displaced the uterus from aorta.

Pregnancy is a prothrombotic state that makes it deemed necessary to prescribe deep vein thrombosis prophylaxis in patients with neurological deficits.<sup>9</sup> Mechanical thromboprophylaxis should be initiated in immediate postoperative period in immobile patients. The pharmacological thromboprophylaxis may be started in high-risk patients after 48 to 72 hours. The current case did not develop any deficit. Hence, she was mobilized on the postoperative day 0.

Awake-awake-awake craniotomy with cortical mapping is safe for glioma resection in pregnant females. The lateral

position avoids aortocaval compression. Hemodynamic and respiratory parameters should be targeted to strike the balance of cerebral and fetal perfusion. Cerebral decongestants should be used with caution. A multidisciplinary approach is required for keeping the mother and baby healthy.

#### Conflict of Interest

None declared.

#### References

- 1 Manohar N, Palan A, Manchala RK, Manjunath ST. Monitoring intraoperative motor-evoked potentials in a pregnant patient. *Indian J Anaesth* 2019;63(02):142–143
- 2 Shiro R, Murakami K, Miyauchi M, Sanada Y, Matsumura N. Management strategies for brain tumors diagnosed during pregnancy: a case report and literature review. *Medicina (Kaunas)* 2021;57(06):613
- 3 Gurcay AG, Bozkurt I, Senturk S, et al. Diagnosis, treatment, and management strategy of meningioma during pregnancy. *Asian J Neurosurg* 2018;13(01):86–89
- 4 Basso A, Fernández A, Althabe O, Sabini G, Piriz H, Belitzky R. Passage of mannitol from mother to amniotic fluid and fetus. *Obstet Gynecol* 1977;49(05):628–631
- 5 Ng J, Kitchen N. Neurosurgery and pregnancy. *J Neurol Neurosurg Psychiatry* 2008;79(07):745–752
- 6 Jangra K, Rath GP. Anesthesia for awake craniotomy: what is new? *Curr Anesthesiol Rep* 2018;8(03):318–327
- 7 Roberti R, Rocca M, Iannone LF, et al. Status epilepticus in pregnancy: a literature review and a protocol proposal. *Expert Rev Neurother* 2022;22(04):301–312
- 8 Godoy DA, Robba C, Paiva WS, Rabinstein AA. Acute intracranial hypertension during pregnancy: special considerations and management adjustments. *Neurocrit Care* 2022;36(01):302–316
- 9 Devis P, Knuttinen MG. Deep venous thrombosis in pregnancy: incidence, pathogenesis and endovascular management. *Cardiovasc Diagn Ther* 2017;7(Suppl 3):S309–S319