Article published online: 2023-12-29

A Rare Case of Panton-Valentine Leukocidin-Related Cervical Empyema

Hung Le[1] Dung Le Thuy Nguyen[2] My Nu Tra Ton[3] Duy Phan[1] Anh Hoang Ngoc Tran[1] Van Tri Truong[1]

[1] Department of Neurosurgery, Vinmec Central Park International hospital, Vinmec Healthcare System, Ho Chi Minh city, Vietnam
[2] Department of Pharmacology, Vinmec Central Park International hospital, Vinmec Healthcare System, Ho Chi Minh city, Vietnam
[3] Department of Radiology, Vinmec Central Park International hospital, Vinmec Healthcare System, Ho Chi Minh city, Vietnam

Address for correspondence Van Tri Truong, MD, Msc, 208 Nguyen Huu Canh, Binh Thanh district, Ho Chi Minh city, 70000, Vietnam (e-mail: drtruongtri@gmail.com).

Asian J Neurosurg

Abstract

Staphylococcus aureus is found in the normal skin and mucosa of approximately 30% of healthy populations and is the most common pathogen in human disease associated with bacteria. They are divided into methicillin-sensitive *S*. aureus (MSSA) and methicillin-resistant S. aureus (MRSA). The *S. aureus* strains carrying the Panton-Valentine leukocidin genes (SA-PVL) were initially believed to belong to the MRSA group; however, recent reports showed they also belonged to the MSSA group (MSSA-PVL). SA-PVL is common in skin and soft-tissue infections but rare in musculoskeletal infections, especially in spondylodiscitis. We are reporting a case suffering from cervical spondylodiscitis and epidural abscess associated with MSSA carrying the Panton-Valentine leukocidin genes.

Keywords
- cervical empyema
- leukocidin
- MSSA
- spine surgery
- Panton-Valentine
- *Staphylococcus aureus*

Introduction

Staphylococcus aureus is found in the normal skin and mucosa of approximately 30% of healthy populations and is the most common pathogen in human disease associated with bacteria.[1,2] They are divided into methicillin-sensitive *S. aureus* (MSSA) and methicillin-resistant *S. aureus* (MRSA). The *S. aureus* strains carrying the Panton-Valentine Leukocidin genes (SA-PVL) were initially believed to belong to the MRSA group; however, recent reports showed they also belonged to the MSSA group (MSSA-PVL).[3] SA-PVL is common in skin and soft-tissue infections but rare in musculoskeletal infections, especially in spondylodiscitis.[3,4] There have been a few reports about the treatment and clinical outcome of spondylodiscitis associated with MSSA-PVL.[3,4] In developing countries, where polymerase chain reaction (PCR) is not routinely used in MSSA infection, misdiagnosis of PVL-MSSA infection may cause widespread of this strain and may lead to more severe cases of necrotizing pneumonia or deep tissue abscess. We report a case suffering from cervical spondylodiscitis and epidural abscess associated with MSSA-PVL at our medical center.

Case Report

A 62-year-old female with a history of type II diabetes was transferred to our hospital with a magnetic resonance imaging (MRI) suspected of epidural empyema. Her medical history was unremarkable except for type II diabetes; she denied any procedure performed on the back of her neck. The patient presented with pain in the left shoulder for a week. The pain increased with time, radiating to the left arm, and the patient had a slight fever. On clinical examination, the patient had slight weakness in the left arm with ⅘ muscle

DOI https://doi.org/10.1055/s-0043-1776307.
ISSN 2248-9614.

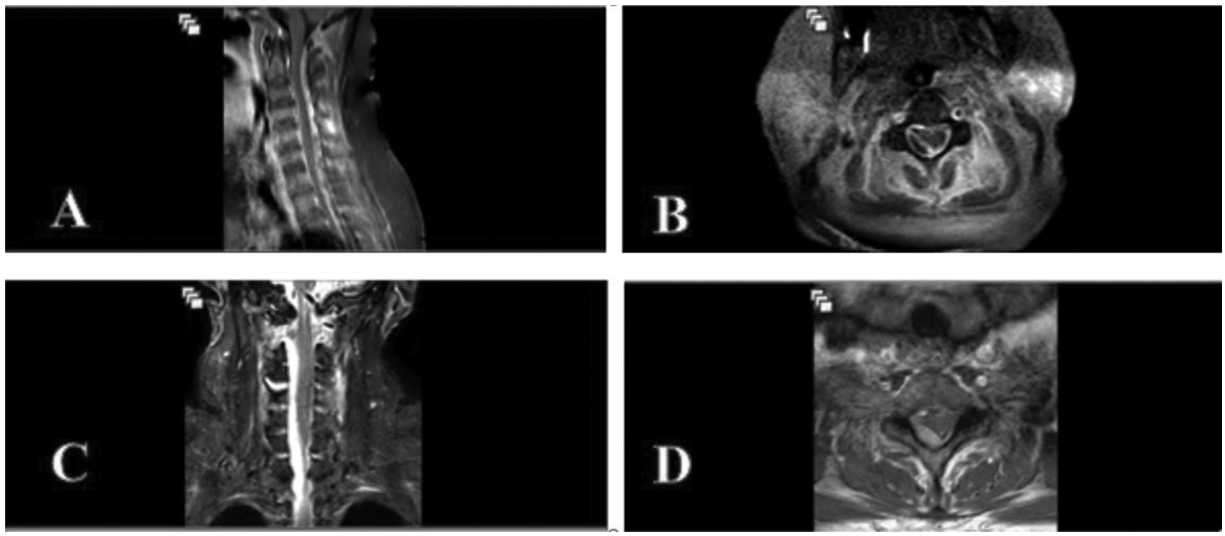

Fig. 1 (**A**) Sagittal T1-weighted (T1W) post-contrast, (**B**) axial T1W post-contrast, (**C**) coronal T2W, and (**D**) axial T2-weighted magnetic resonance images (MRIs) of the cervical spine showing an epidural empyema (hyperintensity on T2W, hypointensity on T1W with peripheral enhancement in post-gadolinium injection) at C1–T5 level. A coronal MRI revealed the lesion compressing the spinal cord laterally, more accentuated on the right, accompanied by extensive infiltration into the paraspinal muscles.

strength and urinary retention. Her cervical MRI showed an epidural abscess on the C1 to T5 level (►**Fig. 1**). Because of the poor general condition of the patient, we decided to perform a C3 to T4 hemilaminectomy without fusion and the abscess was drained out. Post operative cervical spine MRI showed adequate decompression of the spinal cord (►**Fig. 2**). After the surgery, the patient continued the antibiotic treatment with meropenem 1 g intravenous (IV) thrice a day (TID) and linezolid 600 mg IV twice a day (BID). After 7 days, the culture result was MSSA with erythromycin and clindamycin resistance; we decided to continue with the PCR test, and based on the antibiogram, meropenem was stopped. We continued IV linezolid 600 mg BID for 2 weeks until discharge. The patient recovered uneventfully from the surgery. Her neck pain dramatically decreased, and her muscle strength was 5/5 in the limbs. Urinary retention was resolved, and the bladder catheter was removed shortly. The patient continued with Zyvox 600 mg IV BID for 6 weeks then linezolid 600 mg per os BID for another 3 weeks. After 9 weeks, on re-examination, her neck pain was completely resolved, her neck MRI showed no sign of vertebral osteomyelitis (►**Fig. 3**), and her C-reactive protein level was 0.23mg/L. We decided to stop her antibiotic. In the last visit 8 months after the surgery, the patient was fine, and her blood tests were in the range of normal values.

Discussion

Spinal epidural abscess is a rare condition with an incidence of approximately 0.2 to 2.8 cases per 10,000.[5] Diabetes

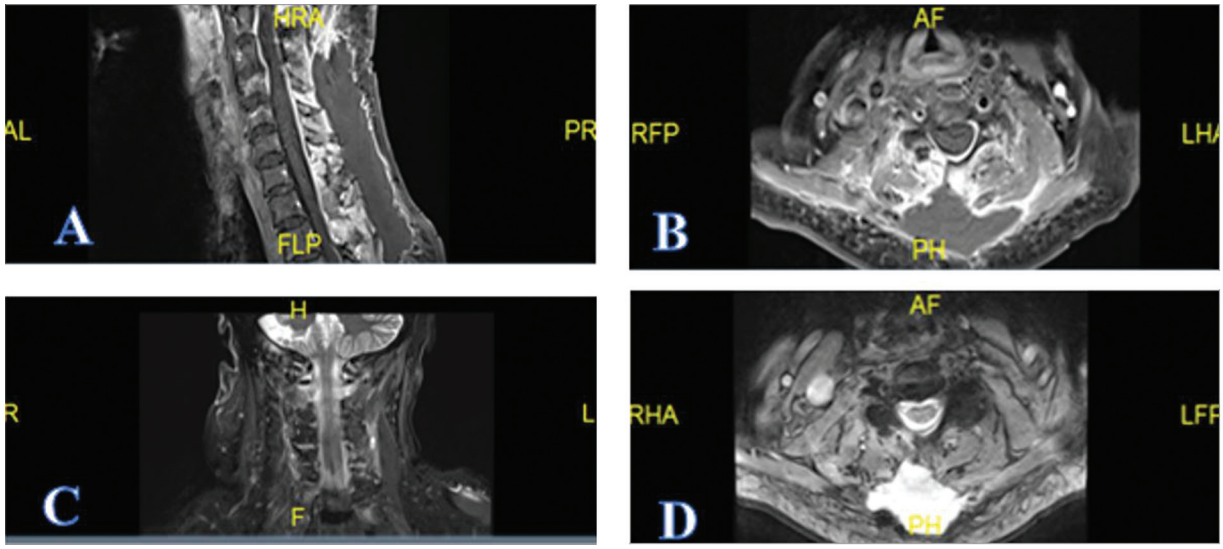

Fig. 2 (**A**) Sagittal T1-weighted (T1W) post-contrast, (**B**) axial T1W post-contrast, (**C**) coronal T2W, (**D**) axial T2W magnetic resonance images 2 days postoperatively showing decompression of the spinal cord and resolution of the epidural empyema.

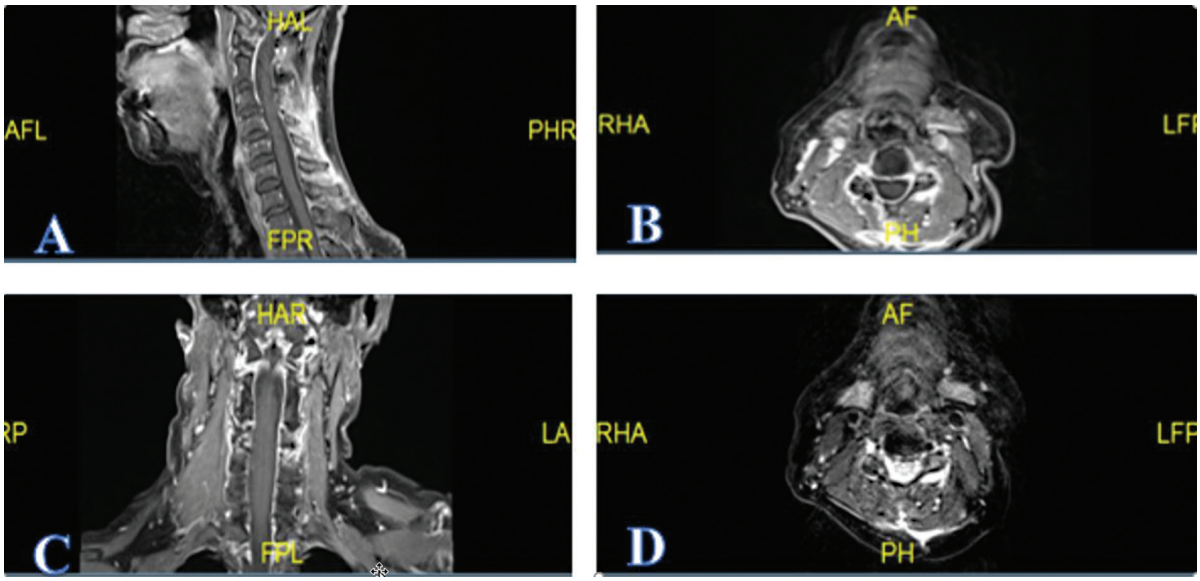

Fig. 3 (**A**) Sagittal T1-weighted (T1W) post-contrast, (**B**) axial T1W post-contrast, (**C**) coronal T1W post-contrast, (**D**) axial T2W follow-up magnetic resonance image post-specific treatment with *Staphylococcus aureus* showing a good response with no sign of recurrence.

mellitus, alcoholism, acquired immunodeficiency syndrome or other immunocompromised states, cancer, IV drug use, trauma, and spinal surgery have been listed as the risk factors of this condition.[6] The present case suffered from diabetes but denied the other factors. Moreover, her older age may be a predisposing factor of her cervical spinal epidural abscess.

PVL is a pore-forming toxin that lyses white cells and especially neutrophils. Approximately 2% of *S. aureus* strains carry both of the coding genes (LukSPV and LukF-PV) for the toxin. Those genes can be detected by PCR when PVL is clinically suspected. In Europe, PVL-SA is mainly represented by MSSA, whereas in the United States, MRSA is most frequently observed (clone phage called USA300), mainly acquired in hospitals.[7] In Asia, according to Yuan et al, the PVL-positive ST22-MSSA-t309 strain was among the most common clones in Urumqi, Northwestern China.[8] PVL toxin in *S. aureus* has been associated with both severe pneumonia and skin and soft tissue infections. PVL can promote the secretion of proinflammatory cytokines through the activation of nuclear factor kappa B (NF-κB) and causes necrotizing infections. However, there are only limited data on how this virulence factor may influence the clinical course or complications of bacteremic *S. aureus* infections.

Among antibiotics used to treat *S. aureus*, clindamycin, linezolid, and fusidic acid can prohibit PVL secretion in vitro. In contrast, oxacillin promotes the secretion of PVL, and vancomycin does not affect PVL secretion. According to the Health Protection Agency guidance on the diagnosis and management of PVL-associated *S. aureus* infections, treatment of deep-seated infections or severe skin infections may include one *S. aureus* treating antibiotic and one antibiotic that can inhibit the secretion of PVL such as linezolid and clindamycin.[9]

In our case, the antibiogram showed that the pathogen belonged to the MSSA strain and was susceptible to many common antibiotics (vancomycin, linezolid) (►**Table 1**). Because the present MSSA strain secreted PVL, we decided to

Table 1 Purulence culture result and antibiogram

Culture result	Positive		
Pathogen	*Staphylococcus aureus*	MRSA	Negative
Antibiogram			
Antibiotic	Sensitive	Intermediate	Resistant
Benzylpenicillin			MIC $\geq$ 0.5
Oxacillin	MIC = 0.5		
Vancomycin	MIC $\leq$ 0.5		
Teicoplanin	MIC $\leq$ 0.5		
Gentamicin	MIC $\leq$ 0.5		
Tetracycline	MIC $\leq$ 1		

(*Continued*)

Table 1 (*Continued*)

Tigecycline	MIC $\leq$ 0.12		
Linezolid	MIC = 1		
Erythromycin			MIC $\geq$ 8
Clindamycin			MIC $\geq$ 8
Ciprofloxacin	MIC $\leq$ 0.5		
Moxifloxacin	MIC $\leq$ 0.25		
Fusidic acid	MIC $\leq$ 0.5		
Trimethoprim/ Sulfamethoxazole	MIC $\leq$ 10		
Rifampicin	MIC $\leq$ 0.5		

Abbreviations: MRSA, methicillin-resistant *Staphylococcus aureus*; MIC, minimum inhibitory concentration.

Table 2 Antibiogram of *Staphylococcus aureus* strains at our center

Bacteria	Number of (+) specimens	Benzylpenicillin	Gentamicin	Rifampicin	Ciprofloxacin	Levofloxacin	Moxifloxacin	Erythromycin	Clindamycin	Linezolid	Vancomycin	Tetracycline	Co-trimoxazole
		Sensitive rate (%)											
S. aureus[1]	**255**	75	77	100	90	97	91	22	24	100	100	35	90
MRSA (72.0%)	**184**		70	100	87	96	88	8	9	100	100	22	88
MSSA (28.0%)	**71**	22	69	100	99	100	100	55	66	100	100	69	94

Abbreviations: MRSA, methicillin-resistant *Staphylococcus aureus*; MSSA, methicillin-sensitive *S.* aureus.

solely use linezolid to treat our patient. We did not combine linezolid with another antibiotic to minimize the adverse effects. However, the patient still suffered from known adverse effects such as changes in taste and anemia. The worst was anemia with hemoglobin concentration going down to 5.5 g/dL. The patient went well after linezolid was stopped in the 9th week.

Unlike the first cervical empyema associated with PVL-SA described by Gazeau et al,[4] our patient has no history of skin infection, and the patient had no previous procedure or injections to the infected location. The patient was transferred from a primary care clinic and we did not have the SA spectrum and antibiogram from all specialties of that clinic. As a result, we could not analyze the virulence and the threat of developing resistant strains in the original clinic. However, in ►**Table 2**, our antibiogram of all SA specimens shows that SA is becoming more resistant to macrolides, especially in MRSA strain. Fortunately, vancomycin and linezolid are our last resort for treating complicated SA infections.

In developing countries, PCR test is not routinely done to detect the genes coding for the toxin of the pathogen, and the antibiotics used according to the antibiogram may promote the secretion of the toxin of the pathogen. Although PCR test is expensive for patients in developing countries, the present case showed its important value in choosing the appropriate antibiotics for MSSA strain.

Conclusion

We described the first PVL-MSSA-related cervical empyema in Vietnam and the second case reported worldwide. However, the prevalence of this strain of MSSA may be higher. Clinicians in developing countries may have underestimated MSSA infection and did not indicate PCR sequencing to detect this dangerous MSSA strain in community-acquired infections.

Conflict of Interest
None declared.

References

1 Diekema DJ, Hsueh PR, Mendes RE, et al. The microbiology of bloodstream infection: 20-year trends from the SENTRY antimicrobial surveillance program. Antimicrob Agents Chemother 2019;63(07):e00355-19
2 Hanselman BA, Kruth SA, Rousseau J, Weese JS. Methicillin-resistant Staphylococcus aureus colonization in schoolteachers in Ontario. Can J Infect Dis Med Microbiol 2008;19(06):405–408
3 Shallcross LJ, Williams K, Hopkins S, Aldridge RW, Johnson AM, Hayward AC. Panton-Valentine leukocidin associated staphylococcal disease: a cross-sectional study at a London hospital, England. Clin Microbiol Infect 2010;16(11):1644–1648
4 Gazeau P, Jaffuel S, Garo B, Ansart S, Allano V. A cervical empyema due to Panton-Valentine leukocidin Staphylococcus aureus. Med Mal Infect 2016;46(06):326–327

5 Reihsaus E, Waldbaur H, Seeling W. Spinal epidural abscess: a meta-analysis of 915 patients. Neurosurg Rev 2000;23(04):175-–204, discussion 205
6 Chao D, Nanda A. Spinal epidural abscess: a diagnostic challenge. Am Fam Physician 2002;65(07):1341–1346
7 Varga M, Kuntová L, Pantůček R, Mašlaňová I, Růžičková V, Doškař J Efficient transfer of antibiotic resistance plasmids by transduction within methicillin-resistant Staphylococcus aureus USA300 clone. FEMS Microbiol Lett 2012;332(02): 146–152
8 Yuan W, Liu J, Zhan Y, et al. Molecular typing revealed the emergence of *pvl*-positive sequence type 22 methicillin-susceptible *Staphylococcus aureus* in Urumqi, Northwestern China. Infect Drug Resist 2019;12:1719–1728
9 Nathwani D, Morgan M, Masterton RG, et al; British Society for Antimicrobial Chemotherapy Working Party on Community-onset MRSA Infections. Guidelines for UK practice for the diagnosis and management of methicillin-resistant Staphylococcus aureus (MRSA) infections presenting in the community. J Antimicrob Chemother 2008;61(05):976–994

