



# Endovascular Treatment of Basilar Artery Stenosis

## *Tratamento endovascular de estenose de artéria basilar*

Leandro José Haas<sup>1,2</sup>  Bernardo Przysieszny<sup>1</sup> Wallace Mees<sup>1</sup>  Liz Caroline de Oliveira Camilo<sup>1</sup>  
Anna Lydia Schuster<sup>1</sup> João Pedro Latrônico Domingos<sup>1</sup>

<sup>1</sup> Department of Medicine, Universidade Regional de Blumenau, Blumenau, SC, Brazil

<sup>2</sup> Endovascular Neurosurgery, Hospital Santa Isabel, Blumenau, SC, Brazil

Address for correspondence Leandro José Haas, Neurosurgeon, Rua Floriano Peixoto, 222, Sala 1305 Centro, Blumenau, SC, CEP 89010-500, Brazil (e-mail: ljhaas@terra.com).

Arq Bras Neurocir 2024;43(2):e87–e92.

### Abstract

**Objective** To analyze epidemiological characteristics and therapeutic evolution of patients with basilar artery (BA) stenosis who underwent endovascular therapy in a reference service.

**Methods** Observational retrospective study of a case report of individuals with BA stenosis who underwent endovascular therapy in an endovascular neurosurgery reference service, between November 2005 and May 2018.

**Results** The prevalence was higher among male patients, with 60% of the cases. As for age, it ranged from 18 to 81 years old, with a mean of 60.2 years old. In terms of comorbidities, systemic arterial hypertension was found in 93% of the patients, and dyslipidemia in 86.7%. The initial symptoms were previous history of ischemic cerebrovascular accident (CVA) in 43.3% of the cases and dizziness in 46.7%. The degree of stenosis ranged from 90 to a 98% of obstruction, with a mean of 92.8%. Neurological deficit was observed in 23.3% of the cases postoperatively, and the postoperative death rate was 10% (3/30). There were no intraoperative adverse events.

**Conclusion** The applicability of endovascular stenting therapy in high-grade BA stenosis proved to be a safe and effective technique with lower morbimortality rates and faster recovery.

### Keywords

- ▶ basilar artery
- ▶ stenosis
- ▶ dizziness
- ▶ endovascular
- ▶ case report

### Resumo

**Objetivo** Analisar as características epidemiológicas e a evolução terapêutica de pacientes com estenose de artéria basilar (AB) submetidos a terapia endovascular em serviço de referência.

**Metodologia** Estudo retrospectivo observacional de trinta pacientes com estenose de AB submetidos à terapia endovascular em serviço de referência em neurocirurgia endovascular de Blumenau, SC, Brasil, no período de novembro de 2005 a maio de 2018.

**Resultados** O sexo masculino foi o mais prevalente, com 60% dos casos. A idade variou de 18 a 81 anos, sendo a média de 60,2 anos. Quanto à presença de comorbidades, observou-se que a hipertensão arterial sistêmica esteve presente em

### Palavras-chave

- ▶ artéria basilar
- ▶ estenose
- ▶ tontura
- ▶ endovascular
- ▶ angioplastia

received

March 20, 2023

accepted

June 21, 2023

article published online

October 31, 2023

DOI <https://doi.org/>

10.1055/s-0043-1776271.

ISSN 0103-5355.

© 2023. Sociedade Brasileira de Neurocirurgia. All rights reserved.

This is an open access article published by Thieme under the terms of the Creative Commons Attribution-NonDerivative-NonCommercial-License, permitting copying and reproduction so long as the original work is given appropriate credit. Contents may not be used for commercial purposes, or adapted, remixed, transformed or built upon. (<https://creativecommons.org/licenses/by-nc-nd/4.0/>)

Thieme Revinter Publicações Ltda., Rua do Matoso 170, Rio de Janeiro, RJ, CEP 20270-135, Brazil

93% dos casos e a dislipidemia em 86,7% dos casos. As sintomatologias iniciais observadas foram história prévia de AVE isquêmico em 43,3% dos casos e tontura em 46,7%. O grau de estenose variou de 90 a 98% de obstrução, com a média de 92,8%. Os stents de balão expansíveis foram os mais utilizados, sendo o da marca Pro-Kinect Energy o mais utilizado (60%). Por fim, em 23,3% dos casos, observou-se déficit neurológico no pós-operatório, e a taxa de óbito foi de 10% (3/30) no pós-operatório. Não ocorreu nenhum evento adverso intraoperatório.

**Conclusão** A aplicabilidade da terapia endovascular com utilização de stent em quadros de alto grau de estenose de AB mostrou-se técnica segura e eficaz com menores taxas de morbimortalidade e recuperação mais rápida.

## Introduction

Cerebrovascular diseases, especially ischemic cerebrovascular accident (CVA), are important causes of death worldwide. A total of 20% of ischemic cerebral events involve the posterior circulation.<sup>1,2</sup> The basilar artery (BA), originating at the junction point of the vertebral arteries, usually at the level of the bulbopontine sulcus, supplies arterial blood to most of the brainstem, the thalamus, and the occipital lobes, and to part of the cerebellum. Thus, it is the most important artery of the posterior cerebral circulation.<sup>2</sup>

The ischemic event caused by BA stenosis and acute occlusion has devastating effects. According to the degree of brain stem involvement, the symptoms may range from isolated cranial nerve palsy, hemiplegia, and locked-in syndrome, to coma.<sup>3</sup> The morbimortality rate of an acute basilar artery occlusion event is ~80%, with a worse prognosis when compared with ischemic events of the anterior circulation.<sup>3</sup>

Intracranial atherosclerotic disease and cardioembolic stroke are considered the main causes of BA stenosis. Approximately 60% of the posterior circulation ischemic events are due to atherosclerosis.<sup>4</sup> This condition is more frequently found in males, Asians, and African Americans, mainly between the 6<sup>th</sup> and 7<sup>th</sup> decades of life.<sup>5</sup>

The clinical presentation of BA stenosis may vary, with transient and intermittent symptoms, which may simulate otitis interna, with dizziness and headache.<sup>5</sup> Despite advances allowed by mechanical thrombectomy for ischemic events, mainly in the anterior circulation, and although studies such as ENDOSTROKE showed a high rate of revascularization after endovascular thrombectomy, its efficacy and safety remain uncertain when compared with drug treatment.<sup>6</sup> Endovascular treatment, based on the use of stents and balloons, has shown better outcomes than microsurgery, especially in patients whose stenosis is >70% and in whom conservative treatment has failed. Angioplasty is indicated for stenosis between 50% and 69%.<sup>7</sup> In stenosis <50%, medical treatment is the priority, aimed at managing risk factors and achieving secondary prevention of new events.<sup>7</sup>

The aim of the present study is to study the recanalization of BA stenosis through endovascular therapy with stents, as well as to analyze its clinical behavior in individuals who under-

went endovascular treatment in a reference endovascular neurosurgery service.

## Methods

Observational and retrospective study based on data collection and analysis of electronic medical records from a group of 30 participants seen in the endovascular neurosurgery reference service. All individuals who had failed clinical treatment events (acetylsalicylic acid 200mg/day, clopidogrel 75mg/day, and statin 80mg/day) presenting new cerebrovascular events and underwent endovascular therapy with angioplasty for stenosis ≥70% of the basilar artery between November 2005 and May 2018 were included in the study.

Insufficient medical data, such as loss to follow-up within 30 days, absence of radiological reports, platelets <100,000, previous neurosurgery or severe head trauma in the last 30 days and patients with RNI ≥1,7 using warfarin were considered exclusion factors. Endovascular treatment-related medical and epidemiological variables were studied, such as age, gender, pre-existing comorbidities, symptoms on admission, preoperative imaging tests, endovascular technique, stenosis characteristics, and 30-day postoperative follow-up.

The BA stenosis site was classified according to Archer et al. into proximal (from the vertebrobasilar junction to the origin of the anterior inferior cerebellar artery), middle (from the origin of the anterior inferior cerebellar artery to the origin of the superior cerebellar artery) and distal (distal to the origin of the superior cerebellar artery).<sup>8</sup> Stenosis degree was measured during digital cerebral arteriography using the Allura Xper FD10 hemodynamic machine (Philips Medical Systems, Veenpluis, Netherlands).

All procedures were performed by a neurosurgeon specialized in neurointervention with >15 years of experience and >2,000 intra- and extracranial angioplasties performed. All procedures were performed through femoral artery access, reaching the subclavian, the vertebral, and the BA (in order), using a 0.0014 size microguide compatible with the type of stent and balloon used. The technique and stent used were chosen by the surgeon. Due to the short time of procedure (average of 1 hour), most of cases were performed under sedoanalgesia and local anesthesia. Few patients were operated on under general anesthesia (20%). Follow-up

imaging tests were performed according to medical criteria. The magnetic resonance imaging (MRI) exam was not used after endovascular treatment.

All patients received dual antiaggregant therapy with clopidogrel 75 mg and acetylsalicylic acid 200 mg for at least 72 hours prior to the procedure. The time factor was very relative since each case was assessed individually according to clinical treatment failure. During the procedure, all patients received a bolus of heparin 5,000 IU. After the procedure, the protocol was clopidogrel 75 mg daily for 3 months and acetylsalicylic acid 300 mg daily continuously.

The project followed current ethical standards, approved by the local ethics committee, Comitê de Ética na Pesquisa em Seres Humanos da Universidade Regional de Blumenau, under CAAE: 80423017.7.0000.5370. The Informed Consent Form (ICF) was presented and made available to the study participants. Written informed consent was obtained from all subjects before the study.

### Statistical Analysis

The data were organized in descriptive tables showing, as appropriate, absolute and relative frequencies, means, standard deviations (SDs), and estimates. Analyses were tabulated using Microsoft Excel 2020 (Microsoft Corporation, Redmond, WA, USA) and analyzed using the SPSS Statistics for Windows, version 17.0 (SPSS Inc., Chicago, IL, USA).

### Results

The mean age among the study subjects was 60.2 years old (18 to 81 years old), with 60% of male patients. Dizziness and prior ischemic CVA were among the most prevalent symptoms (46.7 and 43.3%, respectively). There was rarely an association with gait alteration, but it was not possible to characterize it as ataxia. The least reported symptom was headache (13.3%). Regarding comorbidities, 93.3% of the patients had systemic arterial hypertension (SAH), which is the most prevalent comorbidity among the study subjects; 86.7% had dyslipidemia, and 26.7% had diabetes mellitus (DM). Five individuals had a history of active or previous smoking (16.7%). The mean preoperative modified Rankin scale<sup>8</sup> (mRS) was 2.1 (1 to 3) (► **Table 1**).

The mean degree of stenosis was 92.8%, as shown in ► **Fig. 1**. The middle segment of the BA was the most affected site (56.7%), followed by the proximal (30%) and distal segments (13.3%). Nine individuals had an ulcerated plaque (30%). Regarding the use of stents, as they have lower restenosis rates, balloon-expandable stents were most used, mainly the Pro Kinetic Energy (Biotronik, Bülach, Switzerland) (60%). The restenosis rate was low and not relevant to the study. All subjects underwent diagnostic digital cerebral arteriography during angioplasty, preceded by angioresonance or cerebral angio-computed tomography (CT) (33.3 and 26.7%, respectively) (► **Table 2**).

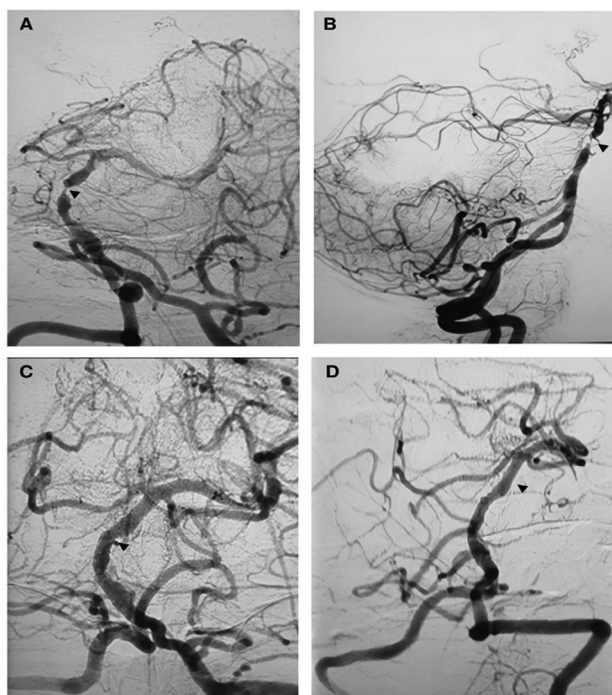
There were no intraoperative adverse events. Postoperative events included limb monoparesis (23.3%), dysphasia, and hemiplegia (13.3% each). Three individuals died within weeks of the procedure (10%). One of them had progressive

**Table 1** Clinical and epidemiological characteristics (n = 30)

Mean age (IQR) – years old	60.2 (18–81)
Gender, female – total nr. / Nr. (%)	9/30 (30)
Symptoms – total nr. / Nr. (%)	
iCVA	13/30 (43.3)
TIA	7/30 (23.3)
Dizziness	14/30 (46.7)
Headache	4/30 (13.3)
Pre-existing comorbidities – total nr. / nr. (%)	
Diabetes mellitus	8/30 (26.7)
Systemic arterial hypertension	28/30 (93.3)
Smoking	5/30 (16.7)
Dyslipidemia	26/30 (86.7)
Heart disease	6/30 (20)
Preoperative mRS	2.1 (1–3)

Abbreviations: iCVA, ischemic cerebrovascular accident; IQR, interquartile range; mRS, modified Rankin Scale; TIA, transient ischemic attack.

lowering of the level of consciousness due to the severity of his previous condition. One had bleeding in the fourth ventricle and the other had a rupture of a pseudoaneurysm in the right deep femoral artery. The mean mRS after 30 days was 1.25 (1 to 2) (► **Table 3**).



**Fig. 1** An 81-year-old male patient with acute stroke due to critical basilar artery stenosis. (A-B), left vertebral artery angiogram shows an occlusion (arrow) at the distal segment of the basilar artery. C-D, left vertebral artery angiogram obtained after intracranial angioplasty and stent placement (arrow) shows complete recanalization of the basilar artery with great distal perfusion.

**Table 2** Stenosis characteristics, stents, and preoperative tests (n = 30)

Mean stenosis degree % (IQR)	92.8 (90–98)
<i>Stenosis characteristics – nr. / total nr. (%)</i>	
Dissection	1/30 (3.3)
<i>Site</i>	
Proximal segment	9/30 (30)
Middle segment	17/30 (56.7)
Distal segment	4/30 (13.3)
Ulcerated plaque	9/30 (30)
<i>Stent type – nr. / total nr. (%)</i>	
<i>Balloon-expandable Stent</i>	
Coroflex Blue	3/30 (10)
Micro Drive	3/30 (10)
Pro Kinetic Energy	18/30 (60)
Liberte	2/30 (6.7)
Drive	2/30 (6.7)
<i>Self-expanding Balloon</i>	
Enterprise	1/30 (3.3)
Resolute Integrity	1/30 (3.3)
<i>Neuroimaging – nr. / total nr. (%)</i>	
Brain MRI	7/30 (23.3)
Brain CT	6/30 (20)
Digital cerebral arteriography	30/30 (100)
Cerebral Angio-CT	8/30 (26.7)
Carotid Doppler test	6/30 (20)
<b>Cerebral Angio-MRI</b>	<b>10/30 (33.3)</b>

Abbreviations: CT, computed tomography; IQR, interquartile range; MRI, magnetic resonance imaging.

**Table 3** Intraoperative events, outcome, and complications (n = 30)

Mean mRS after 30 days (IQR)*	1.25 (1–2)
Intraoperative adverse events nr. / total nr. (%)	0/30 (0)
Postoperative adverse events nr. / total nr. (%)	
Dysphagia	4/30 (13.3)
Hemiplegia	4/30 (13.3)
Monoparesis	7/30 (23.3)
Puncture site bleeding	2/30 (6.7)
<b>Death<math>\Delta</math></b>	<b>3/30 (10)</b>

Abbreviation: IQR, Interquartile range;  $\Delta$ Death, in weeks following the procedure.

## Discussion

In the present study, basilar stenosis affects patients between the 6<sup>th</sup> and 7<sup>th</sup> decades of life (**► Fig. 2**) who also have

DM as one of the most prevalent comorbidities, which is consistent with the literature.

In the present study, the prevalence of hypertensive (30% higher) and dyslipidemic patients (50% higher) was higher than in the study of the American and Chinese populations.<sup>9,10</sup> The study found dizziness and iCVA as the main initial symptoms, corroborating the basic literature; therefore, these are characterized as classic clinical presentations of basilar artery stenosis. On the other hand, the study found a lesser significance of headache, which was 29% less prevalent than in the literature. This difference is attributed to the fact that the population of the present study has headache as a secondary symptom, that is, it is present concomitantly with other symptoms.<sup>11</sup>

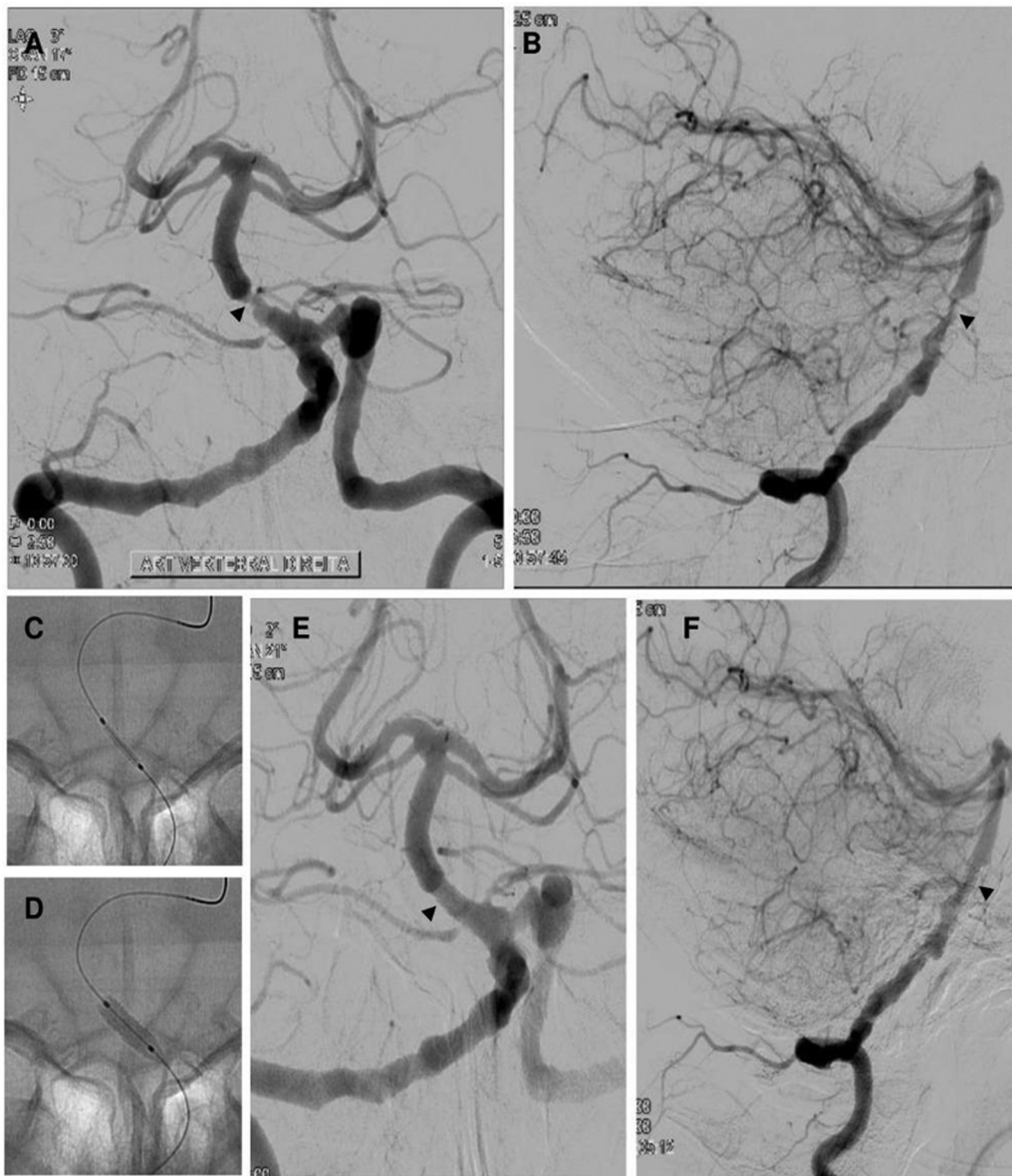
In an observational study with 40 patients, Ciríaco et al. observed that 28 patients (70%) had stenosis grades  $\geq 90\%$ ; these patients underwent endovascular therapy.<sup>5</sup> In the present study, all patients who underwent angioplasty had stenosis  $> 90\%$ .

Samaniego et al. point out that, in basilar stenosis, the middle segment was the most affected site, with 54.9% of cases.<sup>12</sup> The authors observed a greater association between smoking and middle segment stenosis, but they do not associate its site with worse on admission or follow-up mRS. The higher prevalence of one site was also reported in the study by Shu et al., with 41.2% of 51 patients presenting with middle segment stenosis.<sup>9</sup> Among the 187 patients evaluated in the study by Sun et al., the authors observed greater involvement of the proximal segment (55.6%), with 28.9% for the middle segment.<sup>13</sup> The present study showed greater middle segment involvement, in 56.7% of cases, with 4 of 5 smoking patients having middle segment stenosis, but not associated with worse outcomes.

In a long-term follow-up of 30 individuals with  $\geq 70\%$  stenosis of vertebral and BAs who underwent endovascular therapy, Djurdjevic et al. reported 7 deaths, 3 of which related to vascular events, 1 intraoperative death with basilar artery rupture, and the other 2 related to gangrene and intraparenchymal hemorrhage, 5 and 7 years after the procedure, respectively. In his long-term follow-up, Djurdjevic highlights stable treatment outcomes, indicating that endovascular treatment can be beneficial to appropriately selected patients with intracranial stenosis.<sup>14</sup>

In a study on revascularization techniques in BA occlusion, Siebert et al. noted that while the outcome remained unfavorable, the endovascular technique proved effective and relatively safe. The authors reported a mortality rate of 36.8%.<sup>7</sup> In a multicenter study, Kang et al. describe that endovascular therapy is safe and effective in recanalizing acute basilar artery occlusion.<sup>10</sup> In an analysis of 27 individuals who also underwent endovascular technique, Antunes Dias et al. found a mortality rate of 37% of the cases.<sup>15</sup> In the present study, a low mortality rate of 10% was observed, with 3 deaths per 30 treated patients. According to the mRS, there was an improvement in quality of life in all cases. The patients were monitored on an outpatient basis by the same neurosurgeon and underwent imaging exams after 1 year for control.





**Fig. 2** A 58-year-old male patient with acute due to basilar artery stenosis. (A-B), left vertebral artery angiogram shows a stenosis (arrow) at the distal segment of the basilar artery. (C-D), show balloon expandable stent angioplasty. (E-F), left vertebral artery angiogram obtained after intracranial angioplasty and stent placement (arrow) shows complete recanalization of the basilar artery with great distal perfusion.

According to the study by Kang et al., in the case of the 212 individuals they analyzed, younger patients, lower National Institutes of Health Stroke Scale (NIHSS) on admission, absence of DM as a comorbidity and absence of parenchymal hematoma were significant factors for a more favorable outcome after endovascular procedure.<sup>16</sup> In the study by Antunes Dias, the authors pointed out that being female, having a lower NIHSS on admission, mild to moderate symptoms, and a lower posterior collateral circulation score were considered predictors of a better outcome.<sup>15</sup> The present study found a higher prevalence of male subjects (70%) with a mean age of 60.1 years and a mean mRS on admission of 2.1, with no DM as an aggravating factor. One of the 3 patients who died was a 46-year-old female with subarachnoid hemorrhage (SAH); one was a 64-year-old male, smoker, with SAH; and the third was a 54-year-old male with SAH, smoker, dyslipidemic.

Despite dealing with a considerable database on endovascular therapy for basilar stenosis, the present study faced a few limitations, including its retrospective nature. Multi-center prospective studies and randomized clinical trial studies with control groups are needed to better determine clinical and radiological characteristics, as well as to confirm the safety and efficacy of intracranial angioplasty of BA stenosis compared with other treatments. Sample calculation was not done and should be considered as a limitation of the present study.

## Conclusion

The outcomes of the present study, such as the low postoperative morbimortality rate, support the use of the endovascular technique, especially for the BA.

**Ethics Approval**

Ethical approval for the present study was obtained from the Comitê de Ética na Pesquisa em Seres Humanos of FURB, under CAAE: 80423017.7.0000.5370.

**Disclosures**

No potential conflict of interests relevant to this article was reported.

**Sources of Funding**

Own financing, there wasn't financial supporter. The present study was free of costs.

**Conflict of Interests**

The authors have no conflict of interests to declare.

**Acknowledgments**

We thank Hospital Santa Isabel, Blumenau, Santa Catarina, Brazil, for providing structural support for the procedures.

**References**

- 1 Caplan LR. Posterior circulation disease: clinical findings, diagnosis, and management. Cambridge, England:: Blackwell Science Ltd.; 1996. p. 711
- 2 Hong JM, Chung CS, Bang OY, Yong SW, Joo IS, Huh K. Vertebral artery dominance contributes to basilar artery curvature and peri-vertebrobasilar junctional infarcts. *J Neurol Neurosurg Psychiatry* 2009;80(10):1087–1092
- 3 Dietrich WD, Bramlett HM. Ischemic cerebrovascular disease. In: Bradley WG, Daroff RB, Fenichel GM, et al. (editors). *Neurology in clinical practice: principles of diagnosis and management*. Philadelphia, PA: Butterworth Heinemann/ Elsevier Inc.; 2004. p. 1197–249
- 4 Caplan LR, Wityk RJ, Glass TA, et al. New England Medical Center posterior circulation registry. *Ann Neurol* 2004;56(03):389–398
- 5 Ciríaco JGM. Doença oclusiva da artéria basilar: aspectos clínicos e radiológicos [tese]. São Paulo: Faculdade de Medicina da Universidade de São Paulo. Departamento de Neurologia, 2008
- 6 Singer OC, Berkefeld J, Nolte CH, et al; ENDOSTROKE Study Group. Mechanical recanalization in basilar artery occlusion: the ENDOSTROKE study. *Ann Neurol* 2015;77(03):415–424
- 7 Siebert E, Bohner G, Zweynert S, et al. Revascularization Techniques for Acute Basilar Artery Occlusion : Technical Considerations and Outcome in the Setting of Severe Posterior Circulation Steno-Occlusive Disease. *Clin Neuroradiol* 2019;29(03):435–443
- 8 Archer CR, Horenstein S. Basilar artery occlusion: clinical and radiological correlation. *Stroke* 1977;8(03):383–390
- 9 Shu L, Riedel C, Meyne J, Jansen O, Jensen-Kondering U. Successful recanalization in acute basilar artery occlusion treated with endovascular therapy is independent of thrombus length. *J Neurointerv Surg* 2017;9(11):1047–1052
- 10 Kang DH, Jung C, Yoon W, et al. Endovascular thrombectomy for acute basilar artery occlusion: a multicenter retrospective observational study. *J Am Heart Assoc* 2018;7(14):e009419
- 11 Voetsch B, DeWitt LD, Pessin MS, Caplan LR. Basilar artery occlusive disease in the New England Medical Center Posterior Circulation Registry. *Arch Neurol* 2004;61(04):496–504
- 12 Samaniego EA, Shaban A, Ortega-Gutierrez S, et al. Stroke mechanisms and outcomes of isolated symptomatic basilar artery stenosis. *Stroke Vasc Neurol* 2019;4(04):189–197
- 13 Sun X, Tong X, Gao F, Lao H, Miao Z. Endovascular treatment for acute basilar artery occlusion: a single center retrospective observational study. *BMC Neurol* 2019;19(01):315
- 14 Djurdjevic T, Cunha A, Schulz U, Briley D, Rothwell P, Küker W. Endovascular treatment of patients with high-risk symptomatic intracranial vertebrobasilar stenoses: long - term outcomes. *Stroke Vasc Neurol* 2019;4(04):182–188
- 15 Antunes Dias F, Castro-Afonso LH, Zanon Zotin MC, et al. Collateral scores and outcomes after endovascular treatment for basilar artery occlusion. *Cerebrovasc Dis* 2019;47(5-6):285–290
- 16 Wilson JT, Hareendran A, Grant M, et al. Improving the assessment of outcomes in stroke: use of a structured interview to assign grades on the modified Rankin Scale. *Stroke* 2002;33(09):2243–2246