



# Single-Session Thrombectomy without Thrombolysis for Iliofemoral Deep Vein Thrombosis: A Single-Center Experience of ClotTrievers with Evaluation of Predictors for Reocclusion

Qian Yu<sup>1</sup> Daniel Kwak<sup>1</sup> Patrick Tran<sup>1</sup> Ethan Ungchusri<sup>1</sup> Bowen Wang<sup>2</sup> Syed Samaduddin Ahmed<sup>3</sup>  
Adam Said<sup>4</sup> Mikin Patel<sup>1</sup> Jonathan Lorenz<sup>1</sup> Osman Ahmed<sup>1</sup>

<sup>1</sup> Division of Interventional Radiology, Department of Radiology, University of Chicago, Chicago, Illinois, United States

<sup>2</sup> Department of Surgery, School of Medicine, University of Virginia, Charlottesville, Virginia, United States

<sup>3</sup> College of Osteopathic Medicine, Midwestern University Chicago, Chicago, Illinois, United States

<sup>4</sup> Department of Biological Sciences, University of Illinois at Urbana-Champaign, Champaign, Illinois, United States

Address for correspondence Qian Yu, MD, Division of Interventional Radiology, Department of Radiology, University of Chicago, Chicago, IL 60637, United States (e-mail: yuqian1006@gmail.com).

Arab J Intervent Radiol 2024;8:19–26.

## Abstract

**Objective** The aim of this study was to determine the effectiveness of a mechanical thrombectomy device in treating iliofemoral deep vein thrombosis (DVT) without thrombolysis and factors associated with post-thrombectomy occlusion.

**Methods** A single-institution retrospective study of consecutive patients who underwent mechanical thrombectomy for iliofemoral DVT using the Inari ClotTrievers device was performed from August 2019 to July 2022 without thrombolysis or aspiration. Pre- and post-thrombectomy modified Marder score, symptomatic relief, and other baseline characteristics were evaluated. Occlusion rate was evaluated by clinical symptoms and imaging studies during follow-up. Occlusion-free survival (OFS) was calculated. Factors associated with OFS were evaluated with log-rank tests and cox-proportional hazard ratio model. Procedure-related complications were reported.

**Results** Among 32 included patients and 45 limbs, the mean Marder score decreased from  $17.5 \pm 8.1$  to  $0.13 \pm 0.89$  after thrombectomy. Stenting was needed in 13 patients (40.6%). No procedure-related major complication was observed postprocedurally. At initial follow-up, symptomatic improvement and occlusion-free patency were achieved in 80.0 and 72.2%, respectively. Poor venous inflow on post-thrombectomy venogram ( $p < 0.05$ ) was associated with early occlusion. Suboptimal use of post-thrombectomy anticoagulation ( $n = 7$ ) was the only independent predictor of clinical and radiological OFS ( $p = 0.042$ ).

## Keywords

- deep vein thrombosis
- thrombectomy
- venous

**Conclusion** Mechanical thrombectomy with ClotTriever is safe and effective in the treatment of acute and/or subacute iliofemoral DVT and can mitigate the need for thrombolytic therapy. Poor venous inflow on post-thrombectomy venogram and suboptimal use of anticoagulation were associated with early reocclusion.

## Introduction

Iliofemoral deep vein thrombosis (DVT) often presents with worsening lower extremity edema, tenderness, skin discoloration, and skin ulcers. Despite systemic anticoagulation as the accepted standard of therapy, pharmacomechanical catheter-directed thrombolysis (PCDT) or thrombectomy can be considered to restore patency, achieve immediate symptomatic relief, and decrease the severity of future post-thrombotic syndrome (PTS).<sup>1,2</sup> The recent ATTRACT trial suggested higher hemorrhagic complication rates associated with PCDT without apparent long-term risk reduction in PTS,<sup>3,4</sup> resulting in the emergence of large bore thrombectomy devices such as Penumbra Lightning and INARI ClotTriever (Inari Medical, Irvine, California, United States) by avoiding the need to administer thrombolytics.<sup>5,6</sup> These newer generation devices have proven to be feasible for debulking DVT with decreased bleeding risk and reduced ICU stay. However, reocclusion and rethrombosis may be encountered post-thrombectomy, necessitating additional intervention and limiting clinical efficacy. Further, reocclusion rates of using pure mechanical thrombectomy (MT) devices without the use of tissue plasminogen activator (tPA) are lacking, and the risk factors for reocclusion are poorly defined. This study aims to determine the effectiveness of ClotTriever in treating iliofemoral DVT without thrombolysis and factors associated with post-thrombectomy occlusion.

## Methods

### Patient Population

A single institution, institutional review board approved, retrospective chart review was performed to identify consecutive patients who underwent MT for iliofemoral DVT using the Inari Medical ClotTriever device from Aug 2019 to July 2022 ( $n=37$ ). Inclusion criteria were patients more than 18 years old with documented evidence of acute or subacute iliofemoral DVT. DVT was diagnosed preoperatively with lower extremity ultrasound (US) and computed tomography venography (CTV). Patients who underwent adjunctive tPA thrombolysis and/or pharmacomechanical therapy were excluded ( $n=5$ ). A detailed inclusion diagram was depicted in ►Fig. 1. The following information was collected: age, sex, concurrent pulmonary embolism (PE), comorbidities, thrombus location, preoperative modified Marder score, whether the procedure was performed on an inpatient versus outpatient basis, and postprocedural anticoagulation.

### Technique

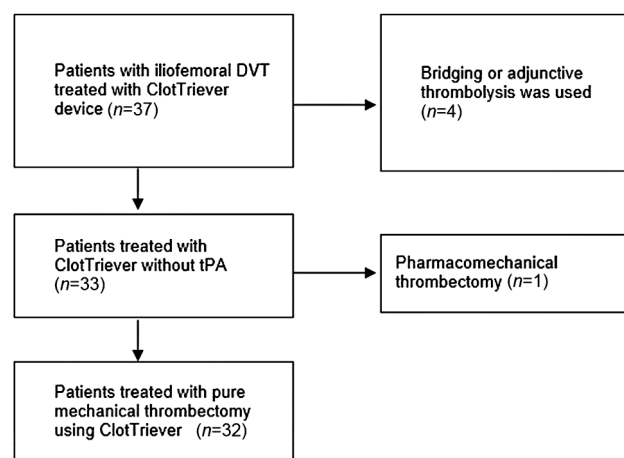
Thrombectomy was performed under moderate sedation or general anesthesia. Patients were positioned prone for pop-

liteal vein access or supine for femoral venous access based on the presence or absence of femoropopliteal DVT, respectively. Thrombectomy using the proprietary ClotTriever device was performed according to previously described techniques.<sup>7-9</sup> Venous stents were deployed if post-MT stenosis remained greater than 50%. Intraoperative anticoagulation was performed using unfractionated heparin with a target activated clotting time of 200 to 250 seconds. Postoperative anticoagulation therapy was initiated with a therapeutic intravenous heparin drip with transition to enoxaparin, coumadin, or direct-acting oral anticoagulant (DOAC) after discharge. Antiplatelet therapy was not routinely administered unless more than 2 stents were placed.

### Outcomes

Technical success (i.e., immediate effectiveness of MT) was evaluated by postprocedural modified Marder scores, which was calculated according to prior literature.<sup>10</sup> The quality of inflow of the vessels below the lesser trochanter was graded into “poor” and “acceptable” subjectively based on post-MT venogram at the end of the procedure.

Patients were instructed to return to the clinic for clinical follow-up and obtain US/CTV for radiology follow-up in 1 to 3 months and every 3 to 6 months afterward. Symptoms of DVT were determined by the evaluation of lower extremity edema, skin discoloration, and/or pain, and categorized as complete resolution (defined as return of baseline status), partial relief (defined as partial resolution of DVT symptoms), and unchanged or worsened clinical symptoms. Radiologic patency rate was classified as complete or near-complete patency ( $>95\%$  vessel patency), occlusion (patency  $<5\%$ ), and partial recanalization (which did not belong to the



**Fig. 1** Diagram of patient selection. DVT, deep vein thrombosis; tPA, tissue plasminogen activator.

**Table 1** Baseline characteristics and summary outcomes

Variables	All (n = 32)
Age	54.2 (16.81)
Sex (F:M)	21:11
Preoperative Modified Marder score (45 limbs)	17.5 (8.1)
Stent	13/32 (40.6%)
Postoperative anticoagulation compliance	24/32 (75.0%)
Warfarin	5 (15.6%)
Apixaban	12 (37.5%)
Rivaroxaban	9 (28.1%)
Enoxaparin	5 (15.6%)
Heparin drip	1 (3.1%)
Outpatient vs. inpatient	6:26
Contraindications to tPA	10/32 (31.3%)
Concurrent PE	16/32 (50.0%)
Comorbidities	
Cancer	10/32 (31.3%)
CHF	2/32 (6.3%)
Diabetes	6/32 (18.8%)
HTN	12/32 (37.5%)
MI	2/32 (6.3%)
Stroke	4/32 (12.5%)
Recent surgery	3/32 (9.4%)
Hypercoagulation	9/32 (28.1%)
Laterality	
Unilateral	19 (59.4%)
Bilateral	13 (40.6%)
Clot site	
IVC	17/32 (53.1%)
Iliac	32/32 (100.0%)
Femoral	25/32 (78.1%)
Popliteal	18/32 (56.3%)
Death	6/32 (18.8%)
Follow-up (months)	8.8 (7.8)

Abbreviations: CHF, congestive heart failure; HTN, hypertension; IVC, inferior vena cava; MI, myocardial infarction; PE, pulmonary embolism; tPA, tissue plasminogen activator.

former two categories). In addition to routine radiological post-MT evaluation, patients were subjected to US and/or CTV if symptoms of DVT recur.

Occlusion-free survival (OFS) was evaluated on a clinical and radiologic basis. The end-point of radiologic OFS was confirmed vessel occlusion on US/CTV. The end-point of clinical OFS was development of DVT symptoms that was subsequently confirmed by imaging (US/CTV). Patients were censored at the time of death or when endovascular revascularization was performed prematurely for stenotic but nonocclusive lesions.

Major procedure-related complications were evaluated based on adverse event classification per Society of Interventional Radiology (SIR) criteria.<sup>11</sup>

### Statistical Analysis

Data were summarized by mean/standard deviation for numerical variables and crude number/percentage for categorical variables. Factors associated with clinical and radiologic OFS were evaluated using a Cox proportional hazards regression model. A stepwise algorithm in forward direction using Bayesian information criteria was implemented to choose the final model. All the factors associated with OS at  $p = 0.05$  were introduced in the multivariable analysis. Statistically significant predictors were subjected to a log-rank test and the OFS was evaluated with Kaplan–Meier curves.  $p$ -Value less than 0.05 considered statistically significant. Median, 6-month, and 1-year OFS were calculated and presented with 95% confidence intervals (CI). All statistical analysis was performed with Stata 15.1 (STATA Corp., College Station, Texas, United States).

## Results

### Baseline Characteristics

A total of 32 patients (19 female, 59.4%) were included. The mean age was  $53.4 \pm 16.7$  years. Half of the patients presented with concurrent acute PE (15/30, 50.0%). Ten (31.3%) cases were presumably inferior vena cava (IVC) filter related. Ten (31.3%) patients had contraindications to tPA according to American Heart Association guidelines, which include history of intracranial hemorrhage ( $n = 3$ ), acute hemorrhage (gastrointestinal tract  $n = 2$ , vaginal bleed and hematuria from tumor invasion  $n = 2$ ), and recent surgery (renal transplant  $n = 1$ , cardiac surgery  $n = 1$ , spine surgery  $n = 1$ ). Additional baseline clinical characteristics of the study population including comorbidities are listed in ►Table 1.

### Procedural Metrix

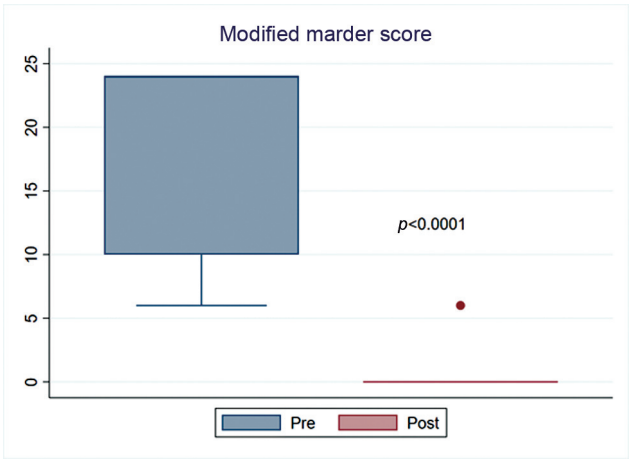A total of 6 (18.8%) and 26 (81.3%) patients underwent outpatient and inpatient thrombectomies, respectively. Unilateral thrombectomies were performed in 19 patients (59.4%), whereas 13 (40.6%) patients required bilateral thrombectomies. Among a total of 45 limbs, the mean modified Marder score before the procedure was  $17.5 \pm 8.1$  and after the procedure was  $0.13 \pm 0.89$  (►Fig. 2,  $p < 0.0001$ ). Stenting was performed in 13/32 patients (40.6%). By the end of the procedure, poor inflow was observed in 6/32 (18.8%) patients.

### Complications

One patient developed rigors intraprocedurally, resulting in abortion and incomplete thrombectomy of treated limb. This patient was brought back on a subsequent date for a successful thrombectomy. There was no procedure-related major complication in the immediate postoperative period.

### Anticoagulation

Among patients with clinical follow-up, the following long-term postprocedural anticoagulation was prescribed:



**Fig. 2** Modified Marder Score, before and after mechanical thrombectomy.

**Table 2** Clinical exam at initial follow-up

Initial symptom	n = 25
Resolved	10/25 (40.0%)
Improved	10/25 (40.0%)
Unchanged/Worsen	5/25 (20.0%)
Improvement	20/25 (80.0%)

warfarin (15.6%), apixaban (37.5%), rivaroxaban (28.1%), and enoxaparin (15.6%); one patient only received postoperative heparin drip (3.1%) and was not bridged to other anticoagulation regimen due to death during the index admission. Compliance with anticoagulation failed in seven patients. In four cases, anticoagulation was held due to hemorrhage (one patient each prescribed the following: rivaroxaban, apixaban, intravenous heparin infusion, and subcutaneous enoxaparin). One patient's international normalized ratio was suboptimal on warfarin. One patient with heparin-induced thrombocytopenia was treated with enoxaparin. One patient was noncompliant for subjective reasons.

**Follow-Up**

The average follow-up time was  $8.8 \pm 7.8$  months for the cohort. Death occurred in 6/30 patients (20%) during this

period due to sepsis ( $n = 1$ ), gastrointestinal hemorrhage from malignancy, bowel obstruction, bowel ischemia, respiratory failure, and hemorrhagic shock of unknown reason. None was procedure related.

Among patients who were clinically evaluated in 1 to 3 months after thrombectomy ( $n = 25$ ), complete symptomatic relief was achieved in 10 patients (40.0%); 10 patients reported symptomatic improvement. In five patients (40.0%), lower extremity swelling, and pain remained unchanged or progressed. Symptomatic improvement was achieved in 20/25 (80.0%) (►Table 2). The Median survival time (MST) for clinical occlusion was not reached (96% CI: 4 month – not reached, ►Fig. 3A). Clinical OFS was 66.1% (95% CI: 44.6–80.9%) at 6 months and 52.3% (95% CI: 27.9–72.0%) at 12 months, respectively.

Follow-up US and/or CT at 1 to 3 months postprocedural were available in 18 patients. Complete or near-complete restoration of patency was observed in 6/18 (33.3%) patients; partial recanalization was noted in 7/18 (38.9%) patients. Occlusion occurred in 5 (27.8%) patients. Total radiological nonocclusive rate was 14/18 (77.8%) at 1 to 3 month (►Table 3). The MST for clinical occlusion was 7 months (96% CI: 2 month – not reached, ►Fig. 4A). Radiologic OFS was 52.4% (95% CI: 27.6–72.3%) at 6 months and 35.9% (95% CI: 13.3–59.5%) at 12 months, respectively.

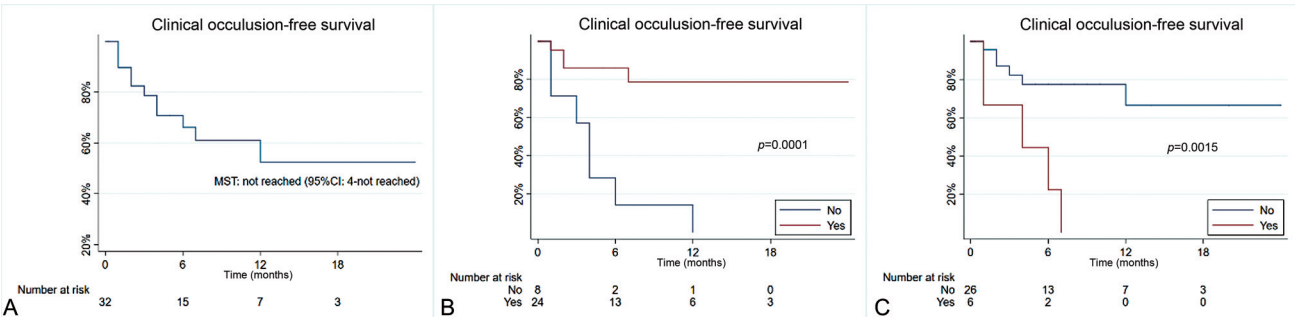
**Predictor Analysis**

On univariable analysis, both inappropriate use of anticoagulation and poor inflow are associated with clinical and radiological occlusion (►Table 4). On multivariable analysis, only inappropriate use of anticoagulation was an independent predictor for clinical and radiological occlusion (►Table 4).

Patients with appropriate anticoagulation use demonstrated both longer clinical and radiological OFS (log-rank  $p = 0.001$  and  $0.0043$ , respectively, ►Fig. 3B and 4B). Patients with poor inflow at the end of MT showed both early clinical and radiologic occlusion (log rank  $p = 0.0015$  and  $0.0087$ , ►Fig. 3C and 4C).

**Discussion**

Clinical utilization of MT has increased in recent years due to its ability to treat acute and subacute/chronic thrombus and/or fibrinous tissue in a single session without the use



**Fig. 3** Clinical occlusion-free survival (A) for all patients, (B) stratified by appropriate use of anti-coagulation, (C) stratified by whether poor inflow was present on post-thrombectomy venogram. CI, confidence interval.

**Table 3** Radiological patency at initial follow-up

Initial patency	n = 18
Complete/near complete	6/18 (33.3%)
Partial	7/18 (38.9%)
Occluded	5/18 (27.8%)
Nonoccluded	13/18 (72.2%)

of thrombolytic agents. In this cohort study, ClotTriever demonstrated significant clot burden reduction (modified Marder score 17.5 vs. 0.1 pre and post-MT, respectively), an unreached MST in clinical OFS and an MST of 7 months in radiologic OFS for thrombectomy of iliofemoral DVT without thrombolysis, and safe procedure profile. Moreover, patients that were inappropriately anticoagulated and poor inflow at the end of MT were associated with early occlusion.

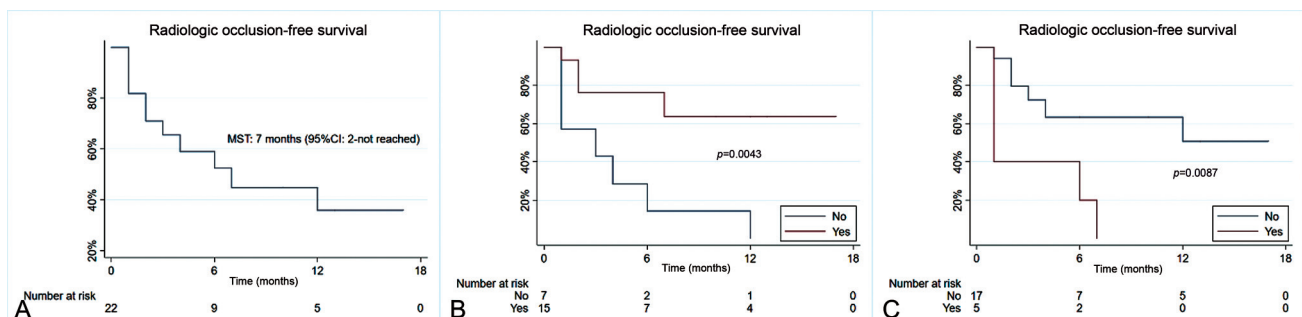
There is limited data for the patency rates of ClotTriever, as the device has only recently received approval by the U.S. Food and Drug Administration (FDA) in 2017. An interim study at 6 month follow-up, including the first 250 patients, of the multicenter, prospective single-arm ClotTriever Outcomes (CLOUT) registry reported a 24% rate for developing PTS with 90.1% maintaining vessel flow as assessed by duplex ultrasound.<sup>12</sup> While PTS was not evaluated by this study, the clinical symptomatic relief rate of 80.0% was achieved with a vessel patency of 72.2% on imaging studies at initial follow-up. The lower vessel patency rate (52.4% at 6 months) in this study may be multifactorial, including the relatively high prevalence of IVC thrombosis (53.1%) and risk factors for DVT recurrence (i.e., 31.3% of patients had a history of malignancy) in addition to the relatively short follow-up period.

The remainder of available published studies include small sample size investigations with short-term follow-up. For example, in a study of 96 patients undergoing thrombectomy for acute iliofemoral DVT, Jolly et al reported 97% to have demonstrated normal flow and 83% to have normal compressibility on duplex ultrasound at 30 days postprocedure.<sup>7</sup> Furthermore, in a study by Benarroch-Gampel et al involving 12 patients treated for acute or acute on chronic iliofemoral DVT with a median follow-up of 4 months, 91.7% of patients continued to have symptom resolution and 80% with persistent patency on duplex ultrasound examination.<sup>13</sup> This compares to the overall weighted

average nonocclusion rate on initial follow-up (1–3 months) evaluation of 80.0% demonstrated in this study. As mentioned previously, direct comparisons with these prior studies are further confounded by varying prevalence of risk factors as well as location of thrombosed vessel (53.1% of cases in this study involved the IVC and were of more chronic etiology). In particular, in the study by Jolly et al, 8.3% of patients had a history of cancer<sup>7</sup> versus 31.3% in the current investigation. Further, a large portion of patient presented with IVC filter-related thrombosis (31.3%), in which the chronically scarred veins are recalcitrant to traditional pharmacolysis and thus traditionally managed conservatively with systemic anticoagulation instead of attempting thrombectomy. Chronic venous remodeling may also result in a higher rethrombosis risk given poor venous inflow compared with reported literature. Parsing these factors in future studies will further define patients who can maximally benefit from large bore MT.

This study suggested an association between poor inflow at procedure end and early occlusion. The cause of poor inflow is multifactorial: chronically occluded deep femoral veins, poor drainage from popliteal and below knee vessels, acute thrombosis without development of collateralization, persistent lumen diameter, or residual thrombus. The use of tPA overnight infusion via an indwelling catheter and rheolytic thrombectomy device has been proven successful in acute clot thrombolysis of the popliteal vein to improve inflow.<sup>10,14</sup> In the setting when tPA is contraindicated, from a technical perspective, continued endovascular thrombectomy can be useful in improving the flow from upstream feeding vessels, with judicious use of venous stent extension, while preoperative and postoperative coagulations are necessary to achieve patency in below-knee vessels that are too small for MT. Further studies are warranted for further elaboration on this aspect.

Postoperative anticoagulation compliance was an additional significant independent predictor of recurrent thrombosis. While this is not an unexpected finding, it prompts the need to elucidate the reasons for noncompliance and actions to minimize those risks. In this study, hemorrhage and gastrointestinal bleeding (GIB) were the most common complications leading to anticoagulation discontinuation (each constituting 28.6%). As such, the use of anticoagulants with more favorable bleeding profiles is of particular importance to minimize the risk of recurrent thrombosis in this



**Fig. 4** Radiologic occlusion-free survival (A) for all patients, (B) stratified by appropriate use of anticoagulation, (C) stratified by whether poor inflow was present on post-thrombectomy venogram. CI, confidence interval.

**Table 4** Cox-proportional HR for predictor analysis

Variables	Clinical			Radiological		
	Univariable		p-Value	Univariable		p-Value
	HR			HR		
Age	0.997 (0.964–1.031)	0.871	–	0.995 (0.963–1.027)	0.741	–
Sex	1.784 (0.471–6.755)	0.393	–	1.069 (0.281–4.066)	0.922	–
Stent placement	1.715 (0.519–5.663)	0.376	–	1.229 (0.373–4.053)	0.735	–
Anticoagulation compliance	7.853 (2.245–27.468)	0.001	0.015	4.880 (1.406–16.932)	0.013	0.042
Charleson score	0.975 (0.806–1.179)	0.732	–	0.958 (0.796–1.154)	0.653	–
Concurrent acute PE	0.812 (0.2445–2.697)	0.734	–	0.847 (0.257–2.793)	0.785	–
Hypercoagulopathy	1.047 (0.305–3.592)	0.942	–	1.032 (0.300–3.549)	0.960	–
Unilateral vs. bilateral	2.350 (0.677–8.157)	0.178	–	1.495 (0.424–5.274)	0.532	–
IVC thrombus	3.803 (0.817–17.697)	0.089	–	3.686 (0.791–17.168)	0.097	–
Femoral vein involvement	3.362 (0.429–26.341)	0.248	–	1.837 (0.234–14.420)	0.563	–
Popliteal vein involvement	1.662 (0.485–5.698)	0.419	–	1.334 (0.385–4.619)	0.649	–
Poor inflow	5.856 (1.666–20.589)	0.006	0.141	4.378 (1.252–15.309)	0.021	0.093
				2.820 (0.709–11.216)		
				3.858 (1.049–14.188)		

Abbreviations: HR, hazard ratio; PE, pulmonary embolism.



post-MT population. DOACs have demonstrated up to 30% increased risk of GI bleeding when compared with warfarin.<sup>15–17</sup> Several studies have shown apixaban to have the most favorable GIB or major bleeding safety profile and rivaroxaban to have the least favorable.<sup>18–21</sup> Apixaban may, therefore, be considered when initially prescribing anticoagulation therapy or reinstating anticoagulation following resolution of the acute GIB episode. Furthermore, DVT in the setting of malignancy is relatively common (e.g., representing up to 30% of patients in the current study) and requires specific anticoagulation management following DVT treatment. Notably, several randomized controlled trials comparing DOACs to low-molecular-weight heparins suggested the former to be associated with higher risks of bleeding,<sup>22,23</sup> although this finding was not consistently reproducible.<sup>24,25</sup> This discrepancy was attributed to the heterogeneity of patient characteristics (including type of thromboembolism as well as type and stage of cancer) as well as definition of study outcomes and analyses thereof.

The ClotTrieve device for the treatment of acute and subacute iliofemoral DVT is a safe alternative to CDT, as demonstrated by the absence of immediate postoperative complications. There is additional clinical benefit over CDT due to its diminished risk of serious hemorrhage, including intracranial hemorrhage, and its use in patients with bleeding risks (malignancy, intracranial hemorrhage, recent surgery, etc.) due to the lack of thrombolytic administration. The results from the current study coincide with prior investigations of the ClotTrieve device for the treatment of iliofemoral DVT, where very few to no device-related complications were reported.<sup>7,12,13,26</sup> Furthermore, there is added healthcare economic benefit due to the lack of need for ICU-level monitoring, as is required following thrombolysis in CDT. Last but not least, approximately a third of the patients in this study had contraindications to tPA, which would not have offered the option for de clot otherwise in the era of purely CDT. This cohort showed that pure MT may achieve an acceptable patency durability.

There are several limitations of this study. Notably, this is a retrospective study performed at a single tertiary academic medical center, which limits the generalizability of these results. Second, the study included a heterogeneous patient population with diverse predisposing risk factors to recurrent DVT (malignancy, recent surgery, etc.). Due to the small sample size in this study, these risk factors could not be stratified and may confound the results. This is an expected limitation given the recency of FDA-approval and clinical use of the ClotTrieve system. It would be beneficial if future studies are performed to understand how these risk factors impact DVT recurrence for patients treated with this device, for example, with the conclusion of the CLOUT registry.

## Conclusion

In conclusion, the ClotTrieve thrombectomy system is highly effective and safe in the treatment of acute and subacute iliofemoral DVT without the need of thrombolysis. Appropriate use of anticoagulation is an independent predictor of

recurrent occlusion. While high technical success was achieved, methods to long-term patency and reduce rethrombosis are warranted in future studies.

## Note

All authors have read and approved the submitted manuscript. The manuscript has not been submitted elsewhere nor published elsewhere in whole or in part.

## Conflict of Interest

O.A. reported receiving personal fees from Argon Medical, Penumbra, Medtronic, Johnson & Johnson, and Boston Scientific and grants from Canon Medical, outside the submitted work. No other disclosures were reported.

## References

- 1 Lichtenberg MKW, Stahlhoff S, Młyńczak K, et al. Endovascular mechanical thrombectomy versus thrombolysis in patients with iliofemoral deep vein thrombosis - a systematic review and meta-analysis. *Vasa* 2021;50(01):59–67
- 2 Murphy KD. Mechanical thrombectomy for DVT. *Tech Vasc Interv Radiol* 2004;7(02):79–85
- 3 Comerota AJ. The ATTRACT trial: rationale for early intervention for iliofemoral DVT. *Perspect Vasc Surg* 2009;21(04):221–224, quiz 224–225
- 4 Winokur RS, Sista AK. DVT intervention in the post-ATTRACT era. *Curr Treat Options Cardiovasc Med* 2018;20(09):70
- 5 Robertson B, Neville E, Muck A, et al. Technical success and short-term results from mechanical thrombectomy for lower extremity iliofemoral deep vein thrombosis using a computer aided mechanical aspiration thrombectomy device. *J Vasc Surg Venous Lymphat Disord* 2022;10(03):594–601
- 6 Abramowitz S. Effective removal of chronic thrombus with the ClotTrieve System: results from the CLOUT Registry. *J Vasc Surg Venous Lymphat Disord* 2021;9(02):544–545
- 7 Jolly MA, Lockhart MM, Shah D, et al. Outcomes from a tertiary care center using a catheter thrombectomy system for managing acute iliofemoral deep vein thrombosis. *J Vasc Surg Venous Lymphat Disord* 2022;10(05):1044–1050
- 8 Wadhwa V, Malhotra A, Kesselman A. Single-session mechanical thrombectomy of lower extremity deep venous thrombosis using the ClotTrieve system: a single-institution experience. *Arab J Intervent Radiol* 2021;5(02):071–075
- 9 Dexter D. Thrombus chronicity subanalysis of mechanical thrombectomy for deep vein thrombosis in real-world patients: six-month outcomes from the CLOUT registry. *J Vasc Surg Venous Lymphat Disord* 2022;10(04):832–840
- 10 Vedantham S, Salter A, Lancia S, Lewis L, Thukral S, Kahn SR. Clinical outcomes of a pharmacomechanical catheter-directed venous thrombolysis strategy that included rheolytic thrombectomy in a multicenter randomized trial. *J Vascular Intervent Radiol* 2021;32(09):1296–1309. e7
- 11 Khalilzadeh O, Baerlocher MO, Shyn PB, et al. Proposal of a new adverse event classification by the Society of Interventional Radiology Standards of Practice Committee. *J Vascular Intervent Radiol* 2017;28(10):1432–1437. e3
- 12 Dexter DJ, Kado H, Schor J, et al; CLOUT Investigators. Interim outcomes of mechanical thrombectomy for deep vein thrombosis from the All-Comer CLOUT Registry. *J Vasc Surg Venous Lymphat Disord* 2022;10(04):832–840.e2
- 13 Benarroch-Gampel J, Pujari A, Aizpuru M, Rajani RR, Jordan WD, Crawford R. Technical success and short-term outcomes after treatment of lower extremity deep vein thrombosis with the ClotTrieve system: a preliminary experience. *J Vasc Surg Venous Lymphat Disord* 2020;8(02):174–181

- 14 Jeyabalan G, Marone L, Rhee R, et al. Inflow thrombosis does not adversely affect thrombolysis outcomes of symptomatic iliofemoral deep vein thrombosis. *J Vasc Surg* 2011;54(02):448–453
- 15 Abraham NS, Singh S, Alexander GC, et al. Comparative risk of gastrointestinal bleeding with dabigatran, rivaroxaban, and warfarin: population based cohort study. *BMJ* 2015;350;
- 16 Holster IL, Valkhoff VE, Kuipers EJ, Tjwa ET. New oral anticoagulants increase risk for gastrointestinal bleeding: a systematic review and meta-analysis. *Gastroenterology* 2013;145(01):105–112. e15
- 17 Ruff CT, Giugliano RP, Braunwald E, et al. Comparison of the efficacy and safety of new oral anticoagulants with warfarin in patients with atrial fibrillation: a meta-analysis of randomised trials. *Lancet* 2014;383(9921):955–962
- 18 Abraham NS, Noseworthy PA, Yao X, Sangaralingham LR, Shah ND. Gastrointestinal safety of direct oral anticoagulants: a large population-based study. *Gastroenterology* 2017;152(05):1014–1022. e1
- 19 Fralick M, Colacci M, Schneeweiss S, Huybrechts KF, Lin KJ, Gagne JJ. Effectiveness and safety of apixaban compared with rivaroxaban for patients with atrial fibrillation in routine practice: a cohort study. *Ann Intern Med* 2020;172(07):463–473
- 20 Lip GYH, Keshishian A, Li X, et al. Effectiveness and safety of oral anticoagulants among nonvalvular atrial fibrillation patients. *Stroke* 2018;49(12):2933–2944
- 21 Noseworthy PA, Yao X, Abraham NS, Sangaralingham LR, McBane RD, Shah ND. Direct comparison of dabigatran, rivaroxaban, and apixaban for effectiveness and safety in nonvalvular atrial fibrillation. *Chest* 2016;150(06):1302–1312
- 22 Raskob GE, van Es N, Verhamme P, et al; Hokusai VTE Cancer Investigators. Edoxaban for the treatment of cancer-associated venous thromboembolism. *N Engl J Med* 2018;378(07):615–624
- 23 Young AM, Marshall A, Thirlwall J, et al. Comparison of an oral factor Xa inhibitor with low molecular weight heparin in patients with cancer with venous thromboembolism: results of a randomized trial (SELECT-D). *J Clin Oncol* 2018;36(20):2017–2023
- 24 Agnelli G, Becattini C, Meyer G, et al; Caravaggio Investigators. Apixaban for the treatment of venous thromboembolism associated with cancer. *N Engl J Med* 2020;382(17):1599–1607
- 25 McBane RD II, Wysokinski WE, Le-Rademacher JG, et al. Apixaban and dalteparin in active malignancy-associated venous thromboembolism: the ADAM VTE trial. *J Thromb Haemost* 2020;18(02):411–421
- 26 Shah NG, Wible BC, Paulisin JA, et al. Management of inferior vena cava thrombosis with the FlowTrier and ClotTrier systems. *J Vasc Surg Venous Lymphat Disord* 2021;9(03):615–620