

Prevalence and Pattern of Nodal Metastases in Ovarian Malignancy: A Perioperative Audit


Ashok Padhy¹ Sony Nanda¹  Bhagyalaxmi Nayak¹

¹Department of Gynecologic Oncology, Acharya Harihar Post Graduate Institute of Cancer (AHPGIC), Cuttack, Odisha, India

Address for correspondence Sony Nanda, MBBS, MS, DNB, MNAMS, MCH, Department of Gynecologic Oncology, Acharya Harihar Post Graduate Institute of Cancer (AHPGIC), Cuttack, Odisha 753007, India (e-mail: sony.nanda@gmail.com).

South Asian J Cancer

Abstract



Sony Nanda

Keywords

- ▶ lymph node metastases
- ▶ ovarian cancers
- ▶ serous tumors
- ▶ nonserous tumors
- ▶ pelvic nodes
- ▶ para-aortic lymph node

It is still unclear whether or not full nodal dissection and detailed staging offer any benefits. Little is known regarding the degree of nodal involvement based on histotype. We aimed to assess the lymphatic dissemination patterns and prevalence in early-stage epithelial ovarian cancer and identify the underlying risk factors for nodal metastases. This is a prospective study conducted over a period of three years. Institutional ethics committee approval has been obtained. A total of 157 consecutive patients with apparently early-stage ovarian cancer, who were treated at the Department of Gynecologic Oncology, Acharya Harihar Post Graduate Institute of Cancer (AHPGIC) from January 2020 to January 2023, were included. The most frequent grade was 3 (66.8%), and the most common histotype was high-grade serous ovarian cancer (HGSO; 55.4%), followed by mucinous (16.5%) and endometrioid (14.01%) varieties. Seromucinous and clear cell ovarian cancers were found infrequently. The most common pattern was isolated pelvic nodal involvement in 48.9% of patients, followed by both para-aortic and pelvic nodal involvement in 25.5% of patients; 13 patients had isolated para-aortic nodal involvement. HGSO was most commonly associated with isolated metastasis to the pelvic lymph nodes alone, while the endometrioid variety was prone to both pelvic and para-aortic spread. Out of the 55 patients with nonserous tumors, 12.72% exhibited nodal involvement. Most nonserous tumors showed affinity for both pelvic and para-aortic (42.85%) nodal metastases. Only grade 3 and serous histology showed a positive association with nodal metastasis. Approximately 45.2% of cases showed upstaging after surgical staging procedures. Multicentric studies are essential to analyze the prognostic impact of systematic lymphadenectomy in ovarian carcinoma patients, depending on the histotype and distribution pattern of nodal metastases.

Introduction

Approximately 30% of the epithelial ovarian cancer (EOC) patients present with clinically early-stage (i.e., International Federation of Gynecology and Obstetrics [FIGO] stage I–II)

disease at initial evaluation. The management of clinically early-stage EOC is determined by surgical staging, which provides a guidance for adjuvant treatment. Although surgical staging of ovarian cancer is recommended,¹ the

DOI <https://doi.org/10.1055/s-0043-1775818> ISSN 2278-330X

How to cite this article: Padhy A, Nanda S, Nayak B. Prevalence and Pattern of Nodal Metastases in Ovarian Malignancy: A Perioperative Audit. *South Asian J Cancer* 2023;00(00):00–00

© 2023. MedIntel Services Pvt Ltd. All rights reserved.

This is an open access article published by Thieme under the terms of the Creative Commons Attribution-NonDerivative-NonCommercial-License, permitting copying and reproduction so long as the original work is given appropriate credit. Contents may not be used for commercial purposes, or adapted, remixed, transformed or built upon. (<https://creativecommons.org/licenses/by-nc-nd/4.0/>)

Thieme Medical and Scientific Publishers Pvt. Ltd., A-12, 2nd Floor, Sector 2, Noida-201301 UP, India

therapeutic benefit of lymph node dissection (LND) is still controversial. The incidence of nodal metastases reported in the literature is 10.6 to 24% for stage I, 23 to 50% for stage II, 53 to 74% for stage III, and 65 to 75% for stage IV ovarian cancer. The three main methods of EOC metastasis include implantation of exfoliated cells at distant intraperitoneal locations, direct dissemination to nearby organs, and spread through the retroperitoneal lymphatic channels.^{1,2} Age, clinical stage at the time of laparotomy, serous histology, high grade histology, CA125 levels, and cytologic evidence of neoplastic cells have all been identified as risk factors for lymph node metastasis in the past.^{3,4}

Advanced ovarian cancer (AOC) has a higher tendency to invade adjacent nodes.^{5,6} Panici et al discovered that systematic nodal dissection had a better progression-free survival (PFS), but not an overall survival (OS), when compared with debulking of enlarged nodes. In another trial LION's trial by Harter et al, systematic pelvic and para-aortic LND in patients with AOC with both intra-abdominal complete resection and clinically negative LN neither improved OS nor PFS despite detecting (and removing) subclinical nodal metastases in 56% of the patients.⁷ Hence, they concluded that systematic LND of clinical negative LN in patients with AOC and complete resection should be omitted to reduce postoperative morbidity and mortality. On the other hand, several investigations found that systematic lymphadenectomy improved OS in their study.²

Most of the studies have investigated the role of lymphadenectomy in AOC, but there is rarity of research in early-stage ovarian cancers. Therefore, it is still unclear whether or not full nodal dissection and detailed staging

offer any additional benefits in early-stage ovarian malignancies. Based on the histotype, little is known regarding the degree of nodal involvement. We aimed to assess the lymphatic dissemination patterns and prevalence in early-stage EOC (apparent stage I and II) and identify the underlying risk factors for nodal metastases.

Patients and Methods

This is a prospective study done over a period of 3 years (January 2020–January 2023). Institutional ethics committee approval has been done. Total of 157 consecutive patients with apparently early-stage ovarian cancer who were treated at the Department of Gynecologic Oncology, Acharya Harihar Post Graduate Institute of Cancer (AHPGIC), were included. Inclusion criteria in this study were apparent early-stage EOC who underwent primary surgical staging including systematic lymphadenectomy covering the pelvic and para-aortic regions. Apparently, early-stage patients were those who had disease confined only to pelvis, that is, stage I and II on imaging (contrast-enhanced computed tomography [CECT] abdomen and pelvis). Exclusion criteria were preoperative imaging suspicious for nodal metastases, any other histotype other than EOC, borderline tumors, patients incompletely staged at other medical centers, those who have had fertility sparing surgery, those with other concomitant cancers, and those who did not give consent.

Each patient in our study underwent surgical staging including exploration of entire peritoneal cavity, ascitic fluid cytology analysis, random peritoneal sampling or biopsy from suspicious areas, hysterectomy with bilateral

Table 1 Clinicopathologic features of surgically staged 157 patients

1	Age	Median (range)	52 years (18–70 years)
2	Grade	Low (Grade 1& 2)	52 (33.2)
		High (Grade 3)	105 (66.8)
3	Ascites	Nil	80 (50.9%)
		<1 L	47 (29.9%)
		>1 L	30 (19.1%)
4	CA125	≤ 35	28 (17.8%)
		35–250	56 (35.7%)
		>250	73 (46.5%)
5	CC	0	101 (64.3%)
		1	31 (19.7%)
		2	15 (9.5%)
		3	10 (6.3%)
6	Final assigned stage (pathological)	I	73 (46.5%)
		II	12 (7.6%)
		III	72 (45.9%)
7	Nodal metastases	Present	47 (29.94%)
		Absent	110 (70.06%)

salpingoophorectomy, infracolic omentectomy, and cytoreduction, as indicated. Systematic pelvic and para-aortic nodal dissection upto level of renal vessels was a part of the surgical staging. Pelvic nodes included all the node bearing fibrofatty tissue from distal circumflex iliac vein till the common iliac bifurcation. Para-aortic group included para-aortic, paracaval, and interaortocaval groups till renal vein. Final pathology results were obtained after the specimens were evaluated by an oncopathologist.

Results

One-hundred fifty-seven patients who fulfilled the inclusion criteria were enrolled. Identification of the clinicopathological variables related to nodal involvement, as well as the pattern of nodal metastases (pelvic or para-aortic), was done (→Table 1). Prior to being included in the evaluation, each patient gave their informed consent for the collection of data.

Statistical Analysis

SPSS Statistics Software version 21 was used to conduct the statistical analysis. Chi-squared analysis was used to estimate the differences between patients' lymph node status in terms of evaluated variables. The level for significance was chosen at $p < 0.05$.

Of the 157 enrolled patients, who characteristics are summarized in →Table 1, the median age was 52 years in our study sample. Based on the histopathology reports, final assigned stages were: Stage I = 73 (46.5%), Stage II = 12

Table 2 Pattern of nodal metastases

	Region involved	No. of patients
1	Pelvic-/Paln-	110
2	Nodal disease+	47
	Pelvic +/Paln-	23 (48.9%)
	Pelvic +/Paln+	11 (23.4%)
	Pelvic-/Paln+	13 (27%)

(7.6%), Stage III = 72 (45.9%). About 17.8% cases had CA125 levels in normal range, the most frequent histological grade was 3 (66.8%), and the most frequent histotype was high grade serous (55.4%), followed by the mucinous (16.5%) and endometrioid (14.01%) variety. The seromucinous and clear cell ovarian cancers were infrequently found. Metastases to the lymph nodes were found in 47 (29.93%) of the patients (→Table 1). The following was noted while looking at the afflicted lymph node regions: the most common pattern was isolated pelvic nodal involvement in 48.9% of patients, followed by both para-aortic and pelvic nodal involvement in 25.5% of patients; 13 patients had isolated para-aortic nodal involvement (→Table 2).

→Fig. 1 depicts nodal metastases in relation with histology. Most common was high-grade serous ovarian cancer (HGSOC; i.e., 38 of 87 cases) followed by endometrioid histology (5 of 22 cases) that was associated with nodal metastasis. Though LN metastases is uncommon in mucinous

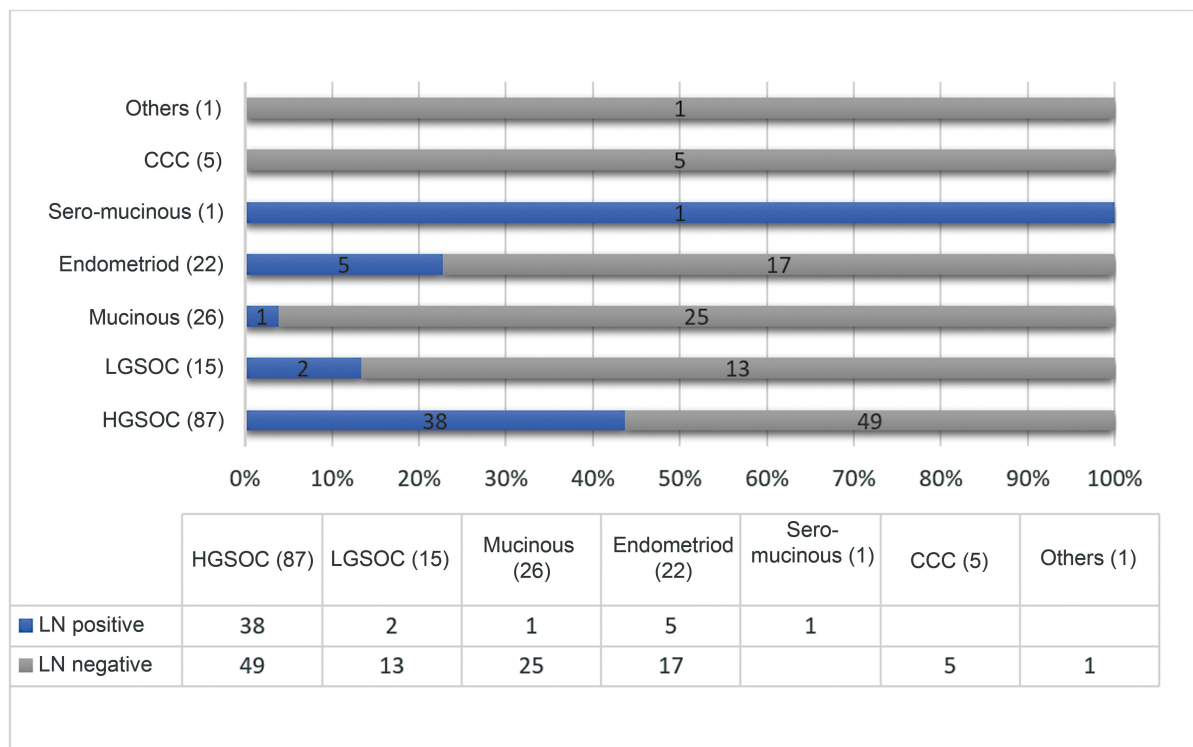


Fig. 1 Nodal metastases in relation with histotype. HGSOC, high-grade serous ovarian cancer; LGSOC, low-grade serous ovarian cancer; LN, lymph node.

ovarian cancers (MOCs), we found 1 case of nodal metastases among 26 mucinous ovarian tumors. One case of seromucinous tumor reported in this study showed nodal positivity. We did not find any clear cell ovarian carcinoma case with nodal metastases in our study.

→Fig. 2 shows pattern of nodal metastases in relation with histology. HGSOC was most commonly associated with isolated metastasis to the pelvic lymph nodes alone. Endometrioid varieties were prone to both pelvic and para-aortic spread. The rare mucinous variety showed a predilection for PALN, without pelvic nodal metastases.

→Fig. 3 shows the comparison between nodal involvement of serous and nonserous tumors. Out of the 55 patients with nonserous histotype of ovarian tumors, 12.72% ($n = 7$) exhibited involvement of the lymph nodes. Most of the nonserous tumors showed affinity toward both pelvic and para-aortic (42.85%) nodal metastases.

On analyzing for risk factors, only grade 3 and serous histology showed a positive association with nodal metastasis (→Table 3). Other risk factors like cytology, laterality, ascites, and CA125 were also analyzed in our study, but it did not show any significant association. Twenty patients of total 47 patients with positive lymph nodes had unilateral tumors. In patients with unilateral tumors, contralateral nodal spread was found in 10% of cases (2/20).

→Fig. 4 demonstrates upstaging of these tumors after complete surgical staging. Of total 157 cases, 71 cases (45.2%) showed upstaging after surgical staging procedures. Fourteen of 71 patients showed upstaging due to nodal involvement only. Of those 14 patients, 11 were HGSOC, rest were 1 each of LGSOC, endometrioid, and mucinous variety.

→Table 4 shows the intraoperative complications encountered while performing nodal dissection during surgical staging.

Discussion

A crucial initial step in managing patients with ovarian cancer is accurate surgical staging. The purpose of staging is to provide suitable, empirically supported adjuvant therapies. LND forms a “part and parcel” in surgical staging of early-stage EOC. Nodal dissection may be correlated with the prognosis in both early and advanced stages of illness, according to growing body of studies.⁸⁻¹²

Some preoperative radiological features are suggestive of nodal metastases like nodes with short-axis dimension more than 10 mm or with central necrosis and loss of fatty hilum. Other characteristic features like rounded (spherical) nodes, ill-defined, and irregular shaped nodes are suggestive of malignancy. Although preoperatively radiological features suggest the involvement of nodes, still complete surgical staging must be done even in apparently early-stage cancers. As in our study we had included 157 cases who did not show any nodal involvement on CECT imaging, but after surgical staging (including nodal dissection) 47 patients showed nodal metastases on final pathology report.¹³⁻¹⁷

Collective LN metastases were seen in 29.93% of the patients in this study (→Table 1). Results of a study by Takashima N et al and Panici B et al, regarding the involvement of the pelvic and/or para-aortic regions^{10,18,19} were likewise supported by the findings of our study. (→Table 1).

In addition, the relationship between nodal metastasis and clinicopathological factors has been analyzed. Previous data on known risk factors for lymph node metastases have been enriched by the risk variables identified in our work. These results are in line with other research that showed a higher risk for serous EOC and a lower risk for mucinous histotypes.^{3,13} According to earlier research, grade 3 EOCs also predicted nodal metastases.¹² In the current

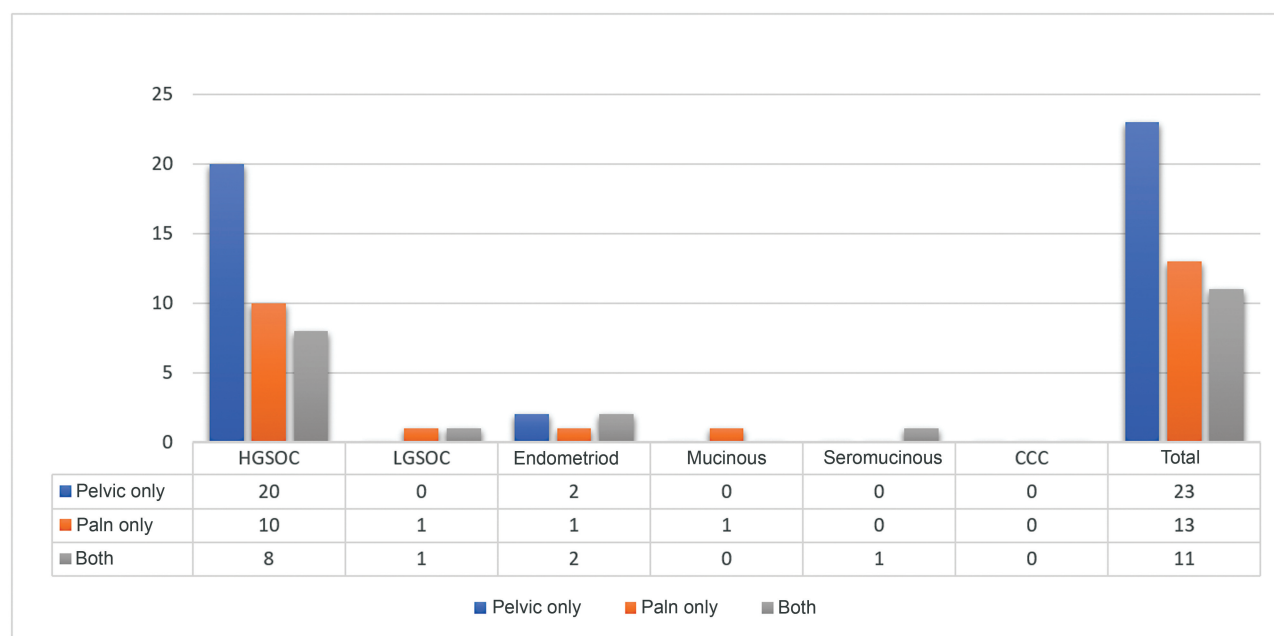


Fig. 2 Pattern of lymph node metastases in relation with histology.

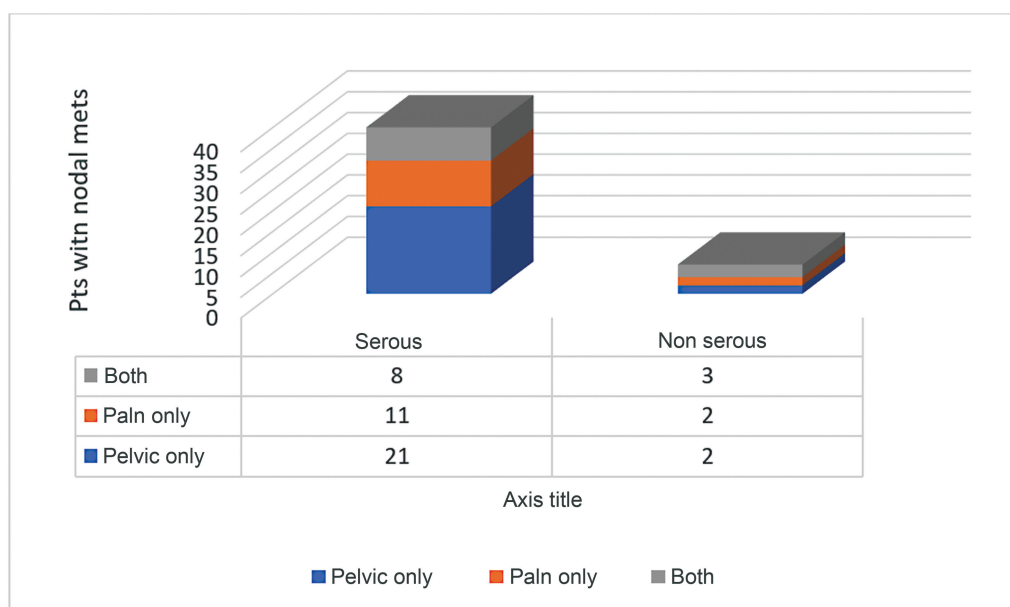


Fig. 3 Pattern of distribution—serous versus nonserous tumors.

Table 3 Risk factor analysis

Sl. no.	Risk factors		Total	Node negative (%)	Node positive (%)	p-Value
			<i>n</i> = 157	110	47	
1	Laterality	Unilateral	64	44 (68.7)	20 (31.25)	NS
		Bilateral	93	66 (70.9)	27 (29.1)	
2	Cytology	Negative	111	77 (69.3)	34 (30.6)	NS
		Positive	46	33 (71.3)	13 (28.2)	
3	Ascites	Absent	80	62 (77.5)	18 (22.5)	NS
		Present	77	48 (62.3)	29 (37.6)	
4	Histology	Serous	102	62 (60.7)	40 (39.3)	<i>p</i> < 0.05
		Nonserous	55	48 (87.3)	7 (12.7)	
5	Grade	Low	52	48 (92.3)	4 (7.6)	<i>p</i> < 0.05
		High	105	62 (59)	43 (40.9)	
6	CA125	≤ 35	28	21 (75)	7 (25)	NS
		>35	129	89(68.9)	40 (31.1)	

Abbreviation: NS, not specified.

investigation, other risk factors such laterality, cytology, and CA125 levels did not demonstrate any significant association. Suzuki et al¹⁵ described a cohort of patients with low-grade stage I malignancies and mucinous tumors. These patients were not likely to have nodal spread based on risk factors. Similar outcomes were observed in our investigation, where we observed just one case of infiltrative MOC with nodal metastases. No case of expansile MOC was found with positive nodes.

Benedetti-Panici et al¹⁶ discussed the significance of ipsilateral pelvic LND for unilateral ovarian malignancies; however, further research^{14,15,20} has shown that isolated contralateral nodal involvements are not uncommon. In this

study, of the 20/47 node positive patients who had unilateral tumors, 18 patients had ipsilateral nodal involvement, 1 patient had bilateral nodal involvement, and 1 patient of unilateral right ovarian tumor had isolated contralateral pelvic nodal (left) metastases in our study, hence, underscoring the fact that bilateral lymphadenectomy should be performed.

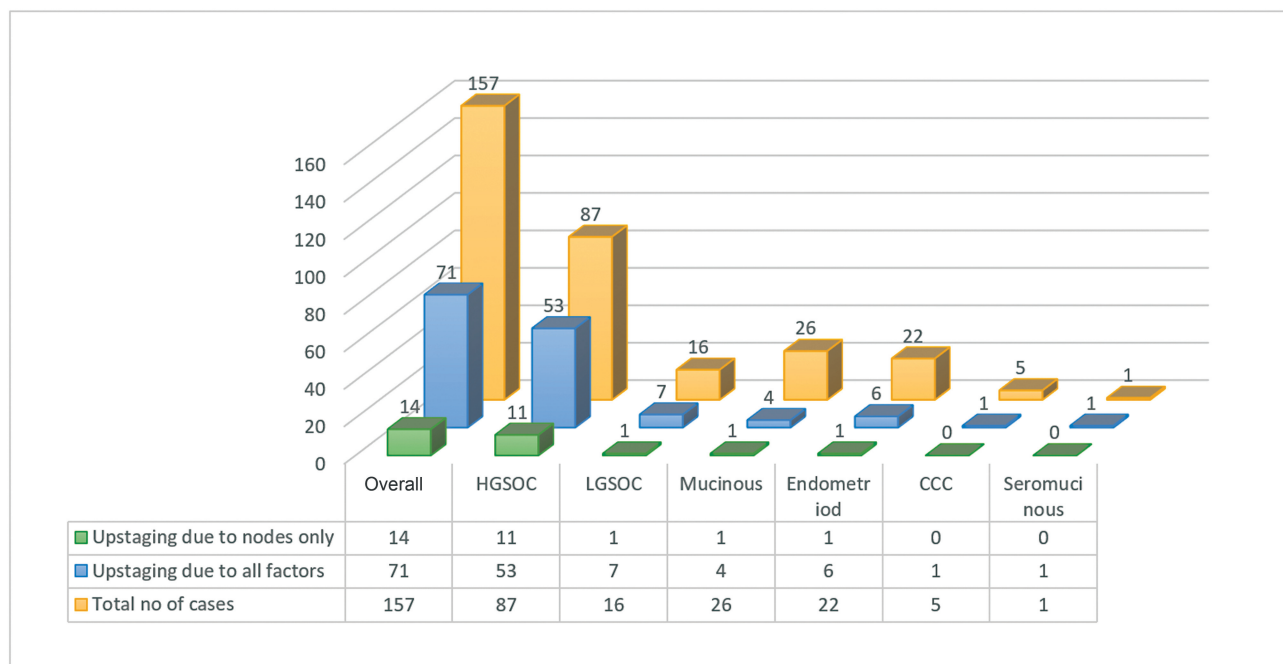
Lymph node locations have been studied in connection with ovarian cancer. In 48 ovarian cancer patients who were to be confirmed node-positive, Onda et al¹² looked at the vital locations for lymph node sampling. They came to the conclusion that if the biopsy was only performed at a single site, the area above the Inferior Mesentric Artery (IMA)

Table 4 Morbidity associated with lymphadenectomy

A	Intraoperative complications	No of patients
1	Vascular injury	
	External iliac vein	2
	External iliac artery	1
	Accessory obturator vein	1
	Obliterated umbilical artery	3
2	Nerve injury	
	Obturator nerve injury	3
3	Ureter injury	1
B	Postoperative complications	No of patients
	Postoperative ileus	5
	Lymphocele	11
	Lymphorrhoea	14
	Lymphedema	6
	Thromboembolic events	4

would be the most preferable location, and if it was performed at two sites, the combination of the obturator lymph nodes, internal and external iliac with the aortic lymph nodes above the IMA would produce the best results in terms of sensitivity and negative predictive value. Other studies^{8,18,21} have demonstrated that the incidence of nodal disease in the para-aortic region and the pelvic region is almost similar or even comparable. The findings of these studies are similar to the results derived in our study i.e., most common pattern of spread was isolated pelvic nodal metastases (23/47 node positive cases) followed by spread to isolated PALN region (13/47 cases), (→ Fig. 2). Additionally,

stage I tumor patients with isolated pelvic nodal metastases are frequent,^{6,8,17} supporting the idea that an ovarian lymphatic channel drains to the pelvic nodes. All of these results could be helpful in deciding whether patients be subjected to systematic lymphadenectomy or other nodal dissection procedures. However, it would be beneficial to be aware of the most common nodal involvement sites, particularly when lymph node sampling is being done. In our study, we observed that a significant prevalence of PALN dissemination (i.e., 51% cases showed PALN involvement), and hence, comprehensive surgical staging in apparent early-stage EOC should include both pelvic and para-aortic LND.

**Fig. 4** Upstaging of cases after surgical staging.

We observed a strong trend in upstaging among those with complete staging; overall 45.22% cases showed upstaging in our study. About 8.9% cases showed upstaging due to nodal metastases alone (►Fig. 4).

The categorization of patients according to the primary tumor's histologic type makes this study distinctive. The initial tumor's histologic type may influence the lymphatic routes. The most important conclusion of this study was that the histologic type of the tumor greatly influences the nodal involvement. Nodal metastases are more common in serous tumors than in nonserous tumors with a typical pattern of dissemination.^{22,23} Similar outcomes were discovered in this study. Nodal dissemination is seen five to six times more commonly in serous tumors than nonserous tumors and the former group has a specific metastatic pattern (50% cases showed isolated pelvic nodal metastases in our study) Therefore, LND may be a valid clinical option in the context of serous tumors. In contrast, there is no specific pattern in the distribution of nodal disease, and the risk of nodal disease is substantially lower with nonserous tumors. We have reported seven cases of nonserous type of tumors with nodal metastases with nonspecific pattern of spread. Additionally, nonserous tumors are typically resistant to chemotherapy, and it is unknown if postoperative chemotherapy works to treat nodal illness that persists after surgery. As a result, we currently believe that systematic LND is appropriate for nonserous tumors.

Although pelvic LND is generally considered a relatively safe procedure, few complications may occur and may vary considerably in their severity. ►Table 4 shows some of the morbidity associated with lymphadenectomy during our staging procedures. Both intraoperative and post-operative complications were seen but the incidence was not high (only 8% cases had Clavien Dindo grade 3 complications) and the complications have been managed conservatively. Similar findings have been reported in a study by He et al.²⁴

Our research suggests that a vital element in the surgical evaluation of early stage of EOC is bilateral pelvic and para-aortic LND up to renal vessels. A thorough evaluation, which includes meticulous LND, allows for accurate staging and the possibility of finding occult node metastases. Planning for restaging operations should take the tumor's grade and histotype into consideration. (Our study revealed a favorable correlation between tumor histotype and grade in cases of nodal metastases) When patients are recommended for completion staging procedures, these data may be useful. Nevertheless, multicentric analysis is necessary.

Some of the limitations of this study are that positron emission tomography-computed tomography (PET-CT) imaging has not been utilized and it is a single-center study. PET-CT facility was not available at our institute during this study period.

Conclusion

Multicentric studies are quintessential to analyze the prognostic impact of systematic lymphadenectomy in early-stage ovarian carcinoma patients, depending on the histotype and

distribution pattern of nodal metastases. Based on histology, this subset of node-positive EOC may be stratified, which may have prognostic significance and provide clarity for therapeutic decision making.

Conflict of Interest

None declared.

References

- Morice P, Joulie F, Camatte S, et al. Lymph node involvement in epithelial ovarian cancer: analysis of 276 pelvic and paraaortic lymphadenectomies and surgical implications. *J Am Coll Surg* 2003;197(02):198–205
- Le T, Adolph A, Krepart GV, Lotocki R, Heywood MS. The benefits of comprehensive surgical staging in the management of early-stage epithelial ovarian carcinoma. *Gynecol Oncol* 2002;85(02):351–355
- Ayhan A, Gultekin M, Taskiran C, et al. Lymphatic metastasis in epithelial ovarian carcinoma with respect to clinicopathological variables. *Gynecol Oncol* 2005;97(02):400–404
- Vergote I. Prognostic factors in stage I ovarian carcinoma. *Verh K Acad Geneesk Belg* 2001;63(03):257–271, discussion 272–276
- Young RC, Walton LA, Ellenberg SS, et al. Adjuvant therapy in stage I and stage II epithelial ovarian cancer. Results of two prospective randomized trials. *N Engl J Med* 1990;322(15):1021–1027
- Hoskins W, et al. In: Principles and practice of gynecologic oncology. 4th ed. Philadelphia: Lippincott Williams and Wilkins; 2005
- Harter P, Sehoul J, Lorusso D, Reuss A, Vergote I, Marth C, Kim JW, Raspagliesi F, Lampe B, Aletti G, Meier W. A randomized trial of lymphadenectomy in patients with advanced ovarian neoplasms. *New England Journal of Medicine* 2019 Feb 28380(09):822–32
- Chan JK, Munro EG, Cheung MK, et al. Association of lymphadenectomy and survival in stage I ovarian cancer patients. *Obstet Gynecol* 2007;109(01):12–19
- Chan JK, Kapp DS, Cheung MK, et al. The impact of the absolute number and ratio of positive lymph nodes on survival of endometrioid uterine cancer patients. *Br J Cancer* 2007;97(05):605–611
- Aletti GD, Dowdy S, Podratz KC, Cliby WA. Role of lymphadenectomy in the management of grossly apparent advanced stage epithelial ovarian cancer. *Am J Obstet Gynecol* 2006;195(06):1862–1868
- Onda T, Yoshikawa H, Yasugi T, et al. Patients with ovarian carcinoma upstaged to stage III after systematic lymphadenectomy have similar survival to Stage I/II patients and superior survival to other Stage III patients. *Cancer* 1998;83(08):1555–1560
- Maggioni A, Benedetti Panici P, Dell'Anna T, et al. Randomised study of systematic lymphadenectomy in patients with epithelial ovarian cancer macroscopically confined to the pelvis. *Br J Cancer* 2006;95(06):699–704
- Husband JE. CT/MRI of nodal metastases in pelvic cancer. *Cancer Imaging* 2002;2(02):123–129
- Ganeshalingam S, Koh DM. Nodal staging. *Cancer Imaging* 2009;9(01):104–111
- Suzuki M, Ohwada M, Yamada T, Kohno T, Sekiguchi I, Sato I. Lymph node metastasis in stage I epithelial ovarian cancer. *Gynecol Oncol* 2000;79(02):305–308
- Benedetti-Panici P, Greggi S, Maneschi F, et al. Anatomical and pathological study of retroperitoneal nodes in epithelial ovarian cancer. *Gynecol Oncol* 1993;51(02):150–154
- Burghardt E, Girardi F, Lahousen M, Tamussino K, Stettner H. Patterns of pelvic and paraaortic lymph node involvement in ovarian cancer. *Gynecol Oncol* 1991;40(02):103–106

- 18 Panici PB, Maggioni A, Hacker N, et al. Systematic aortic and pelvic lymphadenectomy versus resection of bulky nodes only in optimally debulked advanced ovarian cancer: a randomized clinical trial. *J Natl Cancer Inst* 2005;97(08):560–566
- 19 Takeshima N, Hirai Y, Umayahara K, Fujiwara K, Takizawa K, Hasumi K. Lymph node metastasis in ovarian cancer: difference between serous and non-serous primary tumors. *Gynecol Oncol* 2005;99(02):427–431
- 20 Cass I, Li AJ, Runowicz CD, et al. Pattern of lymph node metastases in clinically unilateral stage I invasive epithelial ovarian carcinomas. *Gynecol Oncol* 2001;80(01):56–61
- 21 Petru E, Lahousen M, Tamussino K, et al. Lymphadenectomy in stage I ovarian cancer. *Am J Obstet Gynecol* 1994;170(02):656–662
- 22 Trimbos JB, Vergote I, Bolis G, et al; EORTC-ACTION collaborators. European Organisation for Research and Treatment of Cancer-Adjuvant ChemoTherapy in Ovarian Neoplasm. Impact of adjuvant chemotherapy and surgical staging in early-stage ovarian carcinoma: European Organisation for Research and Treatment of Cancer-Adjuvant ChemoTherapy in Ovarian Neoplasm trial. *J Natl Cancer Inst* 2003;95(02):113–125
- 23 Morice P, Joulie F, Rey A, et al. Are nodal metastases in ovarian cancer chemoresistant lesions? Analysis of nodal involvement in 105 patients treated with preoperative chemotherapy. *Eur J Gynaecol Oncol* 2004;25(02):169–174
- 24 He M, Lai Y, Peng H, Tong C. Role of lymphadenectomy during interval debulking surgery performed after neoadjuvant chemotherapy in patients with advanced ovarian cancer. *Front Oncol* 2021;11:646135