




# Complete Long-Term Response to Radioembolization of Hepatic Metastases from Undifferentiated Uterine Sarcoma

Fuad Barakat<sup>1</sup> Andrea Regine Volker<sup>1</sup> Dirk Warth<sup>1</sup> Martin Binnenhei<sup>1</sup> Peter Reimer<sup>1</sup>  Klaus Tatsch<sup>1</sup>

<sup>1</sup> Interdisciplinary Tumor Board, Clinical Cancer Center, Städtisches Klinikum Karlsruhe, Karlsruhe, Germany

Arab J Intervent Radiol 2023;7:107–109.

**Address for correspondence** Fuad Barakat, MD, EBIR, Institute of Diagnostic and Interventional Radiology, municipal hospital Karlsruhe (städtisches Klinikum Karlsruhe), Moltkestrasse 90, Karlsruhe, 76133, Germany (e-mail: fuad.barakat@klinikum-karlsruhe.de).

## Abstract

### Keywords

- chemotherapy
- liver
- metastases
- sarcoma
- uterus

We report a case of long-term complete response to selective intra-arterial radiation therapy in a 48-year-old female patient with metastatic liver disease from undifferentiated uterine sarcoma.

## Introduction

A 48-year-old asymptomatic female patient presented for a routine cervical smear.

Histological examination revealed an epithelioid sarcoma of the endometrial stroma with melanocytic cells. Initial abdominal magnetic resonance imaging (MRI) revealed an intravaginal cervical tumor without extension beyond the uterus (International Federation of Gynecology and Obstetrics stage IB). MRI also revealed a suspicious left-sided iliac lymph node and multiple suspicious lesions in the right lobe of the liver suggestive of metastases.

Radical hysterectomy, bilateral adnexectomy, and para-aortic and iliac lymphadenectomy were performed via laparotomy. Histopathological examination of the surgical specimens revealed two separate tumor entities including well-differentiated endometrial carcinoma and poorly differentiated sarcoma of the uterine cervix with MSH 2 (mismatch repair gene) mutation, raising suspicion of underlying Lynch syndrome. Two metastatic iliac lymph nodes were positive for uterine sarcoma.

A computed tomography (CT)-guided liver biopsy was performed. Histology revealed metastases of the poorly differentiated uterine sarcoma (Grade G3). Hence, the uterine sarcoma was staged as follows: pT1 pN1 (2/49) M1 (hep)

ER 6 PR 6. Systemic chemotherapy (gemcitabine-docetaxel) was initiated 4 weeks after laparotomy.

Restaging CT examination after three cycles of systemic chemotherapy revealed interval growth of the hepatic metastases with no thoracic or skeletal metastases. Based on these findings, systemic therapy was changed to pazopanib as second-line therapy, along with selective intra-arterial radiation therapy (SIRT) as an additional local therapy for the hepatic metastases.

Pre-SIRT positron emission tomography/computed tomography (PET/CT) revealed new skeletal metastases, progression of hepatic metastases, and suspicious lymph nodes in the porta hepatis and left pelvis.

The patient received additional treatment for the skeletal metastases with radiation therapy and denosumab (Xgeva) and continued on the systemic pazopanib therapy.

Bilobar SIRT was successfully carried out 10 days after SIRT evaluation. At this stage, systemic therapy (pazopanib) was paused.

One month after SIRT, the patient presented with lower abdominal pain. CT examination revealed progress of the lymphatic metastases. Systemic therapy with pazopanib was reinitiated.

Restaging fluorodeoxyglucose positron emission tomography/computed tomography (FDG-PET/CT) (**–Fig. 1**)

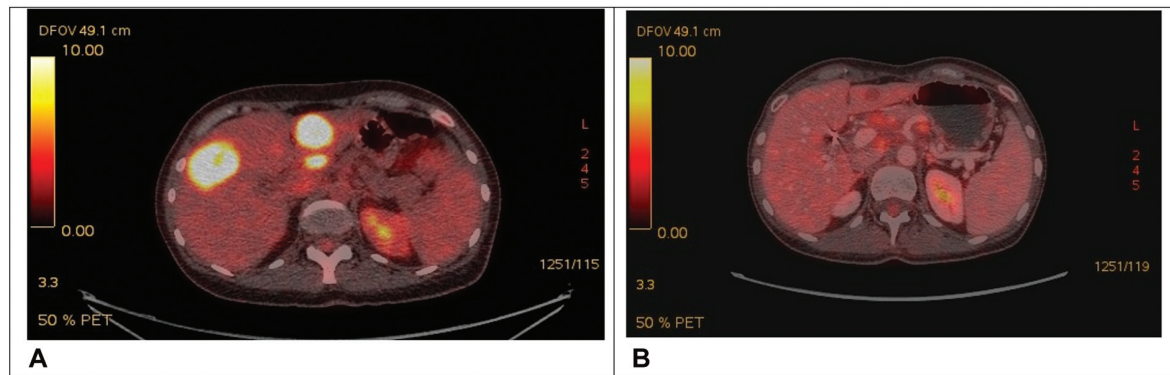
article published online  
November 13, 2023

DOI <https://doi.org/10.1055/s-0043-1775725>.  
ISSN 2542-7075.

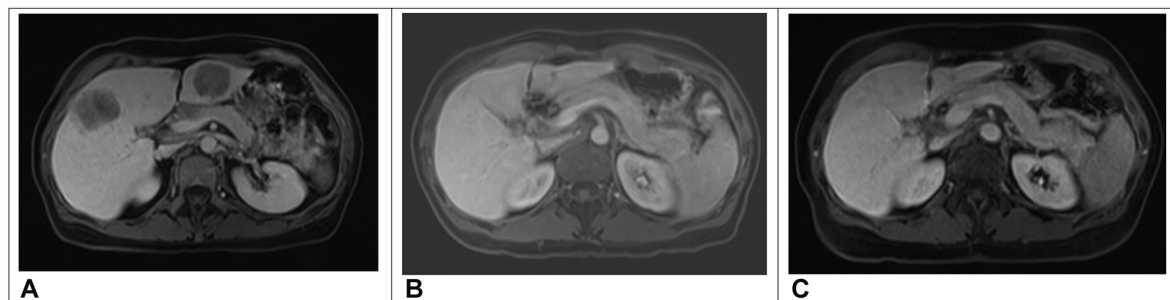
© 2023. The Author(s).

This is an open access article published by Thieme under the terms of the Creative Commons Attribution License, permitting unrestricted use, distribution, and reproduction so long as the original work is properly cited. (<https://creativecommons.org/licenses/by/4.0/>)

Thieme Medical and Scientific Publishers Pvt. Ltd., A-12, 2nd Floor, Sector 2, Noida-201301 UP, India



**Fig. 1** FDG- PET/CT pre (A) and post SIRT (B): complete remission (functional criteria) of the hepatic metastases 3 months post SIRT.



**Fig. 2** MRI pre and post SIRT: complete remission after SIRT of the hepatic metastases. (A) MRI of the liver pre SIRT. (B) MRI of the liver 1 year after SIRT. (C) MRI of the liver 4 years and 6 months after SIRT.

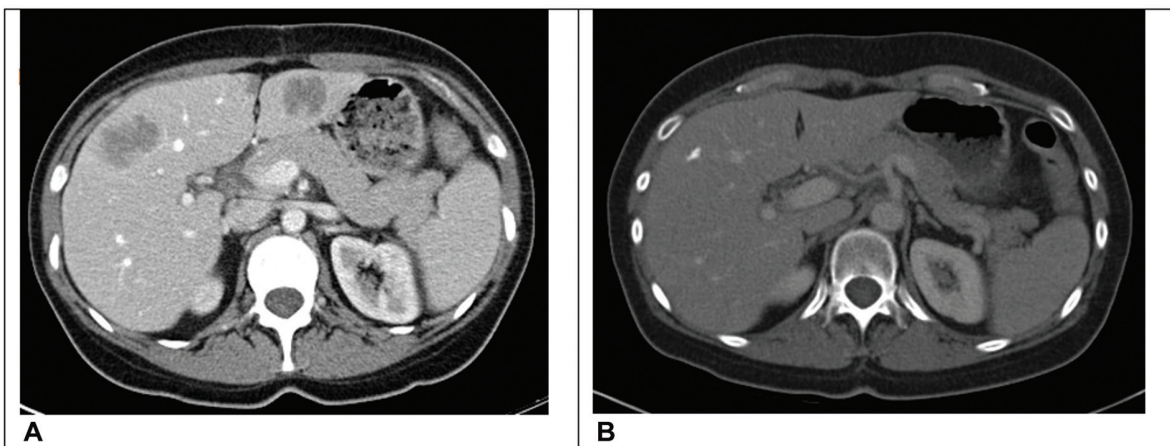
and liver MRI 3 months after SIRT revealed partial remission (morphologic criteria) and complete remission (functional criteria) of the hepatic metastases, with interval progression of skeletal metastasis and lymph nodes. Restaging FDG-PET/CT at 9 months after SIRT and liver MRI (► **Fig. 2**) revealed complete remission of the hepatic and lymphatic metastases and unchanged skeletal metastases. The patient requested to stop the pazopanib and added vitamin B17 therapy (Amygdalin) to the regimen herself.

Regular restaging examinations (► **Fig. 2** and **3**) over more than 6 years after SIRT continued to reveal complete re-

sponse of the lymphatic and hepatic metastases and stable skeletal metastases.

## Discussion

Uterine sarcomas are rare and account for 3 to 7% of uterine cancers. Endometrial stromal tumors account for 7 to 25% of uterine sarcomas and include low-grade endometrial stromal sarcoma (LG-ESS), high-grade (HG-ESS), and undifferentiated uterine sarcoma (UUS). In 60% of patients with USS, the disease is diagnosed at an advanced



**Fig. 3** CT-scan pre SIRT and 6 years and 9 months post SIRT: Complete remission after SIRT of the hepatic metastases. The latest CT scan examination more than 6 years after SIRT shows calcified residual changes of the liver metastases. (A) CT of the liver pre SIRT. (B) CT of the liver more than 6 years after SIRT.

stage, with a very poor prognosis (survival less than 2 years).<sup>1</sup>

The first-line treatment of metastatic HG-ESS and UUS is anthracycline-based chemotherapy. An alternative or second-line option is a tyrosine kinase inhibitor, like pazopanib and imatinib.

Embolization for sarcoma liver metastases can be performed to complement systemic therapy and is indicated in patients with unresectable sarcoma who have large-volume liver metastases with little or no extrahepatic disease.<sup>2</sup>

Our patient developed a progression of hepatic metastases under first-line systemic therapy. For this reason, SIRT therapy was carried out and we managed to achieve morphologic partial remission of progressive liver metastases of a uterine sarcoma within 1 month after SIRT, during a break in systemic therapy. We interpret this as a demonstration of the efficiency of SIRT in the context of hepatic metastases of uterine sarcoma, as a stand-alone therapy. In our case, however, the long-term complete response was achieved in combination with second-line systemic therapy, which was reinitiated some weeks after SIRT.

We found little to no data on the use of SIRT as a local therapy for hepatic metastases of uterine malignancies, whether alone or in combination with systemic therapy. Current literature reports SIRT as a palliative therapy option, mainly for the treatment of hepatic metastases of colorectal cancer, neuroendocrine tumors, breast cancer, and malignant melanoma, as well as primary hepatic malignancies.<sup>3</sup> However, there is some research suggestive of a beneficial role in nonpalliative cases.

The study of Gray et al<sup>4</sup> shows that the combination of chemotherapy with radioembolization is significantly more effective in increasing tumor responses and progression-free survival than the same treatment with chemotherapy alone. According to another study by Raval et al,<sup>5</sup> an early combination of chemotherapy and radioembolization for the treatment of liver metastases seems sensible, especially considering the additive toxicity of sequential chemotherapies and the risk of possible resistance development under polychemotherapy.

Gronchi et al<sup>2</sup> stated that no randomized studies review radioembolization in patients with sarcoma metastasis. However, a randomized study on colorectal liver metastases by Van Hazel et al<sup>6</sup> found that the addition of SIRT to chemotherapy improved the median survival compared to chemotherapy alone (29.4 months as opposed to 11.8 months).

SIRT is currently only indicated in cases with progressive hepatic metastases under systemic therapy; that is, late in the course of the disease.<sup>7</sup> However, our experience with this patient and supportive research suggests that one may consider SIRT in other scenarios, such as a first-line treatment in combination with systemic therapy.

#### Conflict of Interest

None declared.

#### References

- 1 Bose S, Schwartz GK, Ingham M. Novel therapeutics in the treatment of uterine sarcoma. *Am Soc Clin Oncol Educ Book* 2022;42:900–909
- 2 Gronchi A, Guadagnolo BA, Erinjeri JP. Local ablative therapies to metastatic soft tissue sarcoma. *Am Soc Clin Oncol Educ Book* 2016;35:e566–e575
- 3 Jakobs TF, Hoffmann RT, Poepperl G, et al. Mid-term results in otherwise treatment refractory primary or secondary liver confined tumours treated with selective internal radiation therapy (SIRT) using (90)Yttrium resin-microspheres. *Eur Radiol* 2007;17(05):1320–1330
- 4 Gray B, Van Hazel G, Hope M, et al. Randomised trial of SIRT-spheres plus chemotherapy vs. chemotherapy alone for treating patients with liver metastases from primary large bowel cancer. *Ann Oncol* 2001;12(12):1711–1720
- 5 Raval M, Bande D, Pillai AK, et al. Yttrium-90 radioembolization of hepatic metastases from colorectal cancer. *Front Oncol* 2014;4:120
- 6 Van Hazel G, Blackwell A, Anderson J, et al. Randomised phase 2 trial of SIRT-spheres plus fluorouracil/leucovorin chemotherapy versus fluorouracil/leucovorin chemotherapy alone in advanced colorectal cancer. *J Surg Oncol* 2004;88(02):78–85
- 7 Bester L, Meteling B, Boshell D, Chua TC, Morris DL. Transarterial chemoembolisation and radioembolisation for the treatment of primary liver cancer and secondary liver cancer: a review of the literature. *J Med Imaging Radiat Oncol* 2014;58(03):341–352