



“Natural” History of Operated Type A Aortic Dissection

Gian B. Danzi, MD¹ Alberto Carrozza, MD² Silvia Frattini, MD¹

¹Department of Medicine, Ospedale di Cremona, Cremona, Italy

²Department of Medical and Surgical Specialties, Radiological Sciences, and Public Health, University of Brescia, Brescia, Italy

Address for correspondence Gian B. Danzi, MD, Division of Cardiology, Ospedale di Cremona, Viale Concordia 1, 26012 Cremona, Italy (e-mail: gbdanzi@gmail.com).

Aorta (Stamford) 2023;11:162–163.

Abstract

Keywords

- ▶ aortic dissection
- ▶ surgical repair
- ▶ aneurysm

We describe the case of a 66-year-old gentleman with a previous replacement of the ascending aorta for an acute Type A aortic dissection who did not attend any scheduled follow-up visit. Seventeen years later, he presented to our institution with severe aortic regurgitation and with a giant aneurysmal dilation of the abdominal aorta.

A 66-year-old hypertensive gentleman presented to our Institution with acute pulmonary edema. In 2005, he underwent replacement of the ascending aorta with a Dacron graft for acute Type A aortic dissection. Subsequently, the patient remained asymptomatic but did not attend the scheduled follow-up visits and was reluctant to receive any medical advice.

Pulmonary edema was triggered by an episode of acute hypertension in the setting of severe aortic regurgitation due to aortic root dilatation (64 mm at sinuses of Valsalva). Computed tomography angiography of the aorta (–**Fig. 1**) showed a correct proximal insertion of the graft and persistence of a large false lumen extending from the distal graft anastomosis to the right iliac artery, with a giant aneurysmal dilation at the abdominal site (12 cm in diameter). The patient was treated with vasodilators, diuretics, and noninvasive ventilation with rapid improvement of

his clinical condition. After 6 days of hospitalization, he refused any proposed therapeutic approach and self-discharged.

Aortic dissection is the most common catastrophic event affecting the aorta. Surgery has completely changed the natural history of Type A aortic dissection, with a contemporary in-hospital mortality less than 25% and with a long-term survival around 75% at 10 years.^{1,2} Complications during follow-up can be related to failure proximal or distal to the resected zone. Proximal failure is generally due to an insufficient or unsatisfactory aortic repair. Complications in the distal aorta are often related to the persistence of false lumen flow that induces an inappropriate dilatation of the distal vessel. Blood pressure control and systematic assessment of the aorta by means of imaging techniques can discourage late events, as most patients have residual dissection flaps in the arch or in the distal aorta.

received

October 17, 2022

accepted after revision

July 19, 2023

article published online

November 10, 2023

DOI <https://doi.org/>

10.1055/s-0043-1774415.

ISSN 2325-4637.

© 2023. The Author(s).

This is an open access article published by Thieme under the terms of the Creative Commons Attribution-NonDerivative-NonCommercial-License, permitting copying and reproduction so long as the original work is given appropriate credit. Contents may not be used for commercial purposes, or adapted, remixed, transformed or built upon. (<https://creativecommons.org/licenses/by-nc-nd/4.0/>)

Thieme Medical Publishers, Inc., 333 Seventh Avenue, 18th Floor, New York, NY 10001, USA

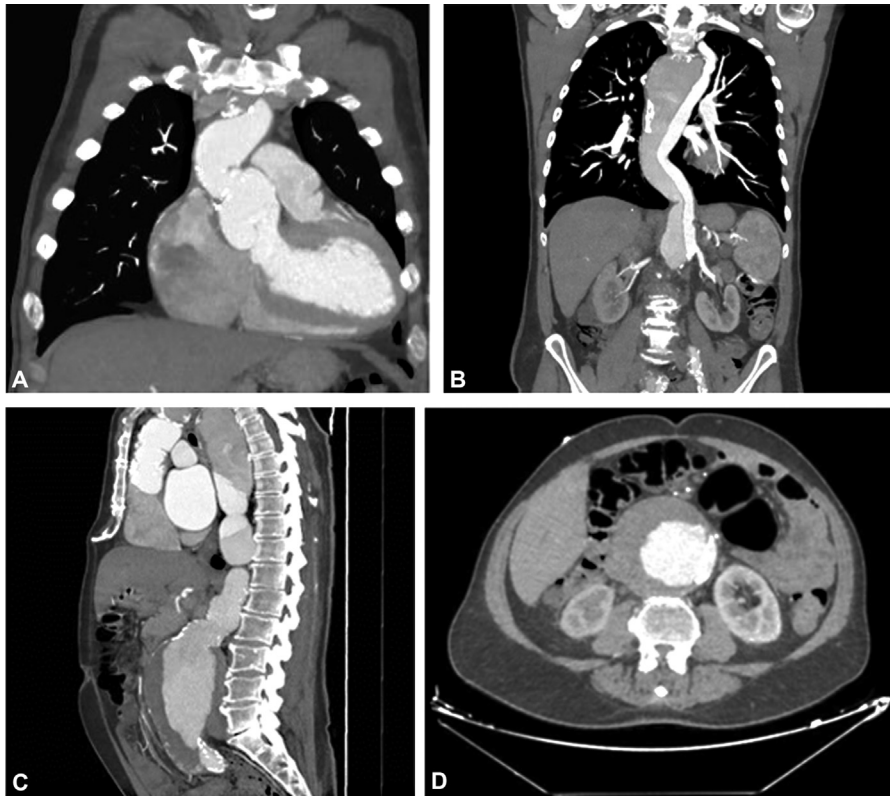


Fig. 1 Computed tomography angiography of the aorta. (A) Aortic root dilatation at sinuses of Valsalva (64 mm). (B, C) Correct proximal insertion of the graft and a persistence of a false lumen extending from the distal graft anastomosis to the right iliac artery with aneurysmal dilation at the abdominal site of 12 cm in diameter. (D) Concentric thrombotic apposition of the false lumen.

Funding

None.

Conflict of Interest

The authors declare no conflict of interest related to this article.

Acknowledgments

None.

References

- 1 David TE, Armstrong S, Ivanov J, Barnard S. Surgery for acute type A aortic dissection. *Ann Thorac Surg* 1999;67(06):1999–2001, discussion 2014–2019
- 2 Erbel R, Aboyans V, Boileau C, et al; ESC Committee for Practice Guidelines The Task Force for the Diagnosis and Treatment of Aortic Diseases of the European Society of Cardiology (ESC) 2014 ESC Guidelines on the diagnosis and treatment of aortic diseases: Document covering acute and chronic aortic diseases of the thoracic and abdominal aorta of the adult. *Eur Heart J* 2014;35(41):2873–2926