



Role of Ancillary Investigations in Medicolegal Autopsy to Establish the Cause of Death and Legal Implications

Arneet Arora¹ Sangita Moirangthem¹ Jayanthi Yadav¹ Suhail Alikkal¹ Aniket Gour²
Navinchandra M. Kaore³

¹ Department of Forensic Medicine and Toxicology, All India Institute of Medical Sciences, Bhopal, Madhya Pradesh, India

² Department of Community and Family Medicine, All India Institute of Medical Sciences, Rishikesh, Uttarakhand, India

³ Department of Microbiology, All India Institute of Medical Sciences, Bhopal, Madhya Pradesh, India

Address for correspondence Sangita Moirangthem, MD Forensic Medicine and Toxicology, Department of Forensic Medicine and Toxicology, All India Institute of Medical Sciences, Bhopal 462020, Madhya Pradesh, India (e-mail: sangitachanu480@gmail.com).

J Lab Physicians

Abstract

Sudden death in young females can have various causes and it is important to investigate the cause thoroughly. In cases with a vague history, postmortem ancillary investigation can also help to establish or rule out potential causes of death, such as underlying medical conditions or environmental factors. These investigations may include various laboratory tests, such as toxicology, histology, microbiology, and genetic analysis, as well as radiological imaging studies. This information not only helps in ascertaining the cause and manner of death but also helps in establishing the legal connotations in any medicolegal case.

This is a case of a young woman allegedly 18 years brought for a medicolegal autopsy. She had been feeling unwell for a few days before her death, experiencing vomiting, weakness, and fatigue. Although no underlying disease was diagnosed, she was advised to take a pregnancy test. Fifteen days later, she died at home continuing to feel unwell. Upon autopsy, the young woman was found to be emaciated, and revealed a male fetus, of 4 to 5 months of gestational age, in her uterus. A radiological examination of bones conducted postmortem revealed that the age of woman was approximately 15 years old. Postmortem microbiology analysis revealed the presence of the bacteria *Leuconostoc mesenteroides* in a blood sample collected from the subclavian vein. The pathogenicity of this bacteria in the cause of death along with the role of ancillary investigation in the light of Indian criminal law and its challenges are being discussed.

Keywords

- ▶ sudden death
- ▶ young female
- ▶ *Leuconostoc mesenteroides*
- ▶ postmortem ancillary investigations
- ▶ Indian POCSO Act
- ▶ mandatory reporting

Introduction

The death of an adolescent is a tragic event that can have a profound impact on family, friends, and the wider community. Females have lower mortality rates than males in these

age groups. Causes of death in this age group can vary and may include accidents, suicide, violence, self-harm, infectious diseases such as respiratory infections and maternal conditions (complications for pregnancy) as leading causes of death among adolescents and young adults. In sudden

received

July 7, 2023

accepted after revision

August 12, 2023

DOI <https://doi.org/10.1055/s-0043-1774411>.

ISSN 0974-2727.

© 2023. The Indian Association of Laboratory Physicians. All rights reserved.

This is an open access article published by Thieme under the terms of the Creative Commons Attribution-NonDerivative-NonCommercial-License, permitting copying and reproduction so long as the original work is given appropriate credit. Contents may not be used for commercial purposes, or adapted, remixed, transformed or built upon. (<https://creativecommons.org/licenses/by-nc-nd/4.0/>)

Thieme Medical and Scientific Publishers Pvt. Ltd., A-12, 2nd Floor, Sector 2, Noida-201301 UP, India

unexpected death, suspicious death, and death due to unknown cause, a medicolegal autopsy is done to certain the cause and manner of death. Medicolegal autopsies may be performed without any prior knowledge of the deceased or any ailments or suspected causes of death; the deceased may even be unidentified and just found dead. As a result, the forensic pathologist needs to be ready for everything because it is possible for what was once thought to be presumed natural death to be anything, including a homicide. Many a time medicolegal autopsy is supplemented by ancillary investigations to help determine or corroborate the cause of death, and manner of death and to positively identify unknown deceased individuals. Ancillary investigations include radiology, histopathology, microbiology, and chemical analysis.

Postmortem microbiologic cultures have been used successfully as a diagnostic ancillary investigation and epidemiologic tool in disease outbreak scenarios, as well as in forensic autopsies and medicolegal investigations.¹⁻⁴ Their uses are usually taken into account during an autopsy in situations when there has been a history of infection, when inexplicable inflammation is found, and when traumatic and noninfectious causes of death have been ruled out. With proper practice of sample collection and the right sample for microbiological analysis, postmortem microbiological testing is one of the fundamental techniques in forensic pathology for determining the etiology of infection.⁵ Postmortem blood and tissue cultures can be used to learn more in-depth about the severity of the infectious process that was already recognized or known antemortem but resulted in the patient's rapid deterioration and death.

Lack of adequate nutrition and immunologic alterations during pregnancy can lead to altered severity of and susceptibility to infectious diseases during pregnancy. Such infectious diseases when not diagnosed timely can lead to serious complications and even death. Also, pregnant women are at increased risk of aspiration due to several factors including delayed gastric emptying, the gravid uterus, progesterone-mediated lower esophageal sphincter relaxation, and decreased gastric pH.⁶ Indian law recognizes consent for sexual intercourse only after the age of 18 and warrants criminal investigation if it is before that age, including a consensual act. For medical persons and persons with fiduciary responsibility, reporting to law enforcement agencies is made mandatory once the case has come to their knowledge. This mandatory reporting many times acts as a deterrent to seeking much-needed medical treatment for the fear of legal implications.

Case Report

Alleged History

The deceased is alleged to 18-year-old female, who had eloped with her boyfriend and had settled with his family working as a laborer. Her own family had disowned her. For the past 1 month, she was having complaints of vomiting and weakness that kept worsening. Fifteen days back she was taken to hospital by her mother-in-law, where she was

advised treatment and investigations for pregnancy check-ups. But she did not get the investigation done and was found dead at home 2 weeks later due to the worsening of her illness. The family was not aware of the pregnancy status.

External Examination

The deceased was a young emaciated adolescent female (►Fig. 1A), 148 cm in height, weight 30 kg (body mass index: 13.7 kg/m²). Eyeballs were sunken with hollowing of temporal fossa and cheeks. The abdomen was scaphoid in shape and devoid of subcutaneous fat, and the ribs were prominent. No signs of decomposition were evident externally. No injuries were evident on the body.

Internal Examination

The weight of the right lung and left lung were 167 and 151 g, respectively. Interlobar adhesions between the right upper and middle lobes were seen. On dissection of the lungs, a yellowish mucoid substance with some granular material is evident in terminal bronchioles resembling gastric content (►Fig. 1B). The uterus was enlarged and gravid (►Fig. 1C), containing a male fetus of length (crown–heel) 19 cm aged approximately 4 to 5 months (►Fig. 1D). Other organs were congested in appearance.

Histopathological Examination

Tissues from different organs were microscopically examined using hematoxylin and eosin stain and congestion of all the organs was seen. Significant interstitial inflammation and mild septal thickening with inflammatory changes around the bronchial cartilage and congestion of the lungs (►Fig. 2) were observed that corroborated with findings of aspiration seen grossly in the airways.

Microbiological Examination

Blood samples were collected with an aseptic technique and injected into adult BacTAlert 3D medium bottles (BACT/ALERT FA Plus) that were then incubated under normal atmospheric conditions, at 37°C in an automatic BacTAlert 3D blood culture machine (BioMérieux, Okhala, New Delhi, India). The blood culture bottle flashed positive indicating a critical mass of organisms. Gram staining was done that showed Gram-positive ovoid cocci or coccobacilli in pairs and chains. It was then subcultured on the blood agar, MacConkey's agar, and chocolate agar incubated at 37°C for 24 hours. The colonies grown were again subjected to Gram staining and were subjected to VITEK 2 Compact System (BioMérieux, France), an automated identification system used for the identification of microorganisms grown. The strain was identified as *Leuconostoc mesenteroides* by the automated system. Postmortem microbiological analysis suggested pre-existing bacteremia by *Leuconostoc mesenteroides*.

Radiology

Radiological examination of shoulders, elbow, wrist, and jaw and pelvis was done on PRORAD digital X-ray machine and the age of the female was ascertained to be 15 to 16 years. The third molar had not erupted, and the shoulder joint,

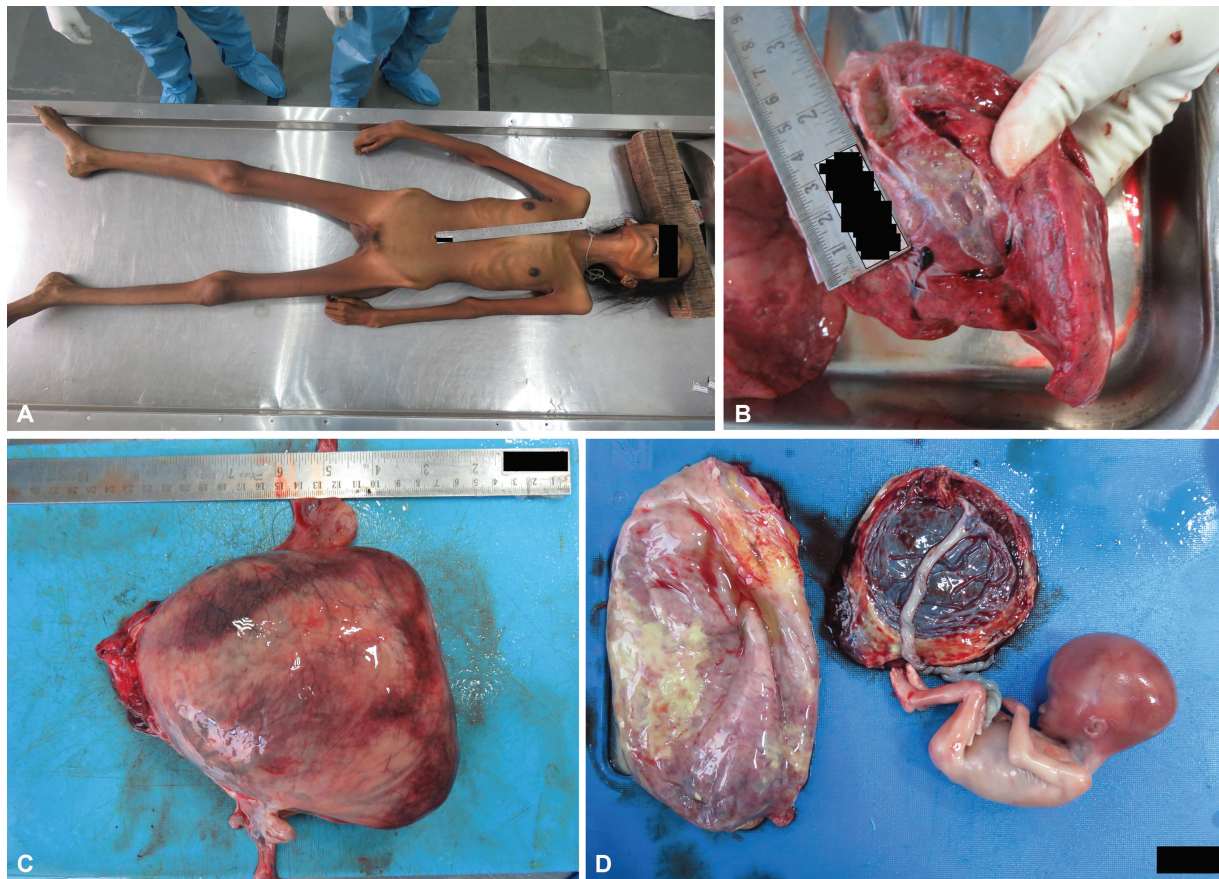


Fig. 1 (A) Thin emaciated body. (B) Yellowish granular material as aspirate along with mucoid material in the bronchus and bronchioles. (C) Uterus dimensions: 21 (length) × 17 cm (width) × 4 cm (anteroposterior). (D) Fetus of length 19 cm with placenta.

elbow joint wrist joint, and hip joint were not fused (► Fig. 3A–D).

Toxicological Examination

Viscera preserved for toxicological analysis did not reveal any metallic or nonmetallic poisoning.

After the postmortem, the cause of death was given as aspiration of gastric contents into the airway. Ancillary investigations played a crucial role in establishing the

comprehensive diagnosis of the presented case. Radiological examination confirmed the victim's age; microbiological analysis identified *Leuconostoc mesenteroides* bacteremia, shedding light on a pre-existing infection that contributed to the clinical deterioration; and histopathology corroborated aspiration of gastric contents, culminating in the determination of death's cause and the underlying infection.

Discussion

Adolescent pregnancy is linked to school abandonment, violence, unfavorable pregnancy terminations, obstetric problems, and other outcomes that could endanger the woman's quality of life and the lives of those around her. Although most early adolescent pregnancies happen in vulnerable circumstances, late-stage teens are voluntarily bearing children in many cultures, with or without a committed spouse. Pregnancy in adolescents carries risks for both the mother and the unborn child. Pregnancy in women less than 18 years of age is considered illegal and falls under POCSO Act (the Protection of Children from Sexual Offenses Act) as per Indian law. Valid (legal) consent for sexual intercourse cannot be given by a woman under 18 years of age. A case of rape (sexual assault) would be registered against the offender.⁷ Adolescent pregnancy faces higher risks of eclampsia, puerperal endometritis, and systemic

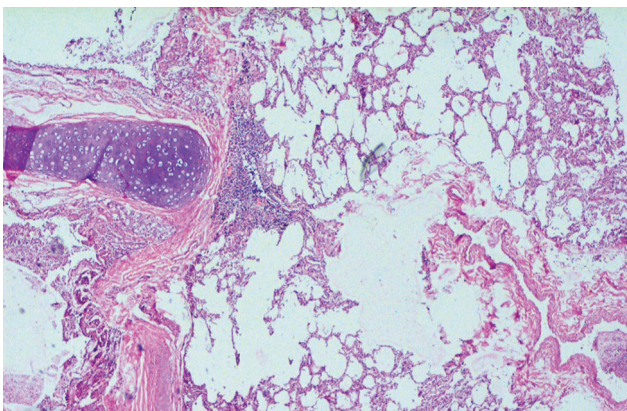


Fig. 2 Inflammatory changes around the bronchial cartilage and interstitial inflammation. 40x Hematoxylin and eosin stain.

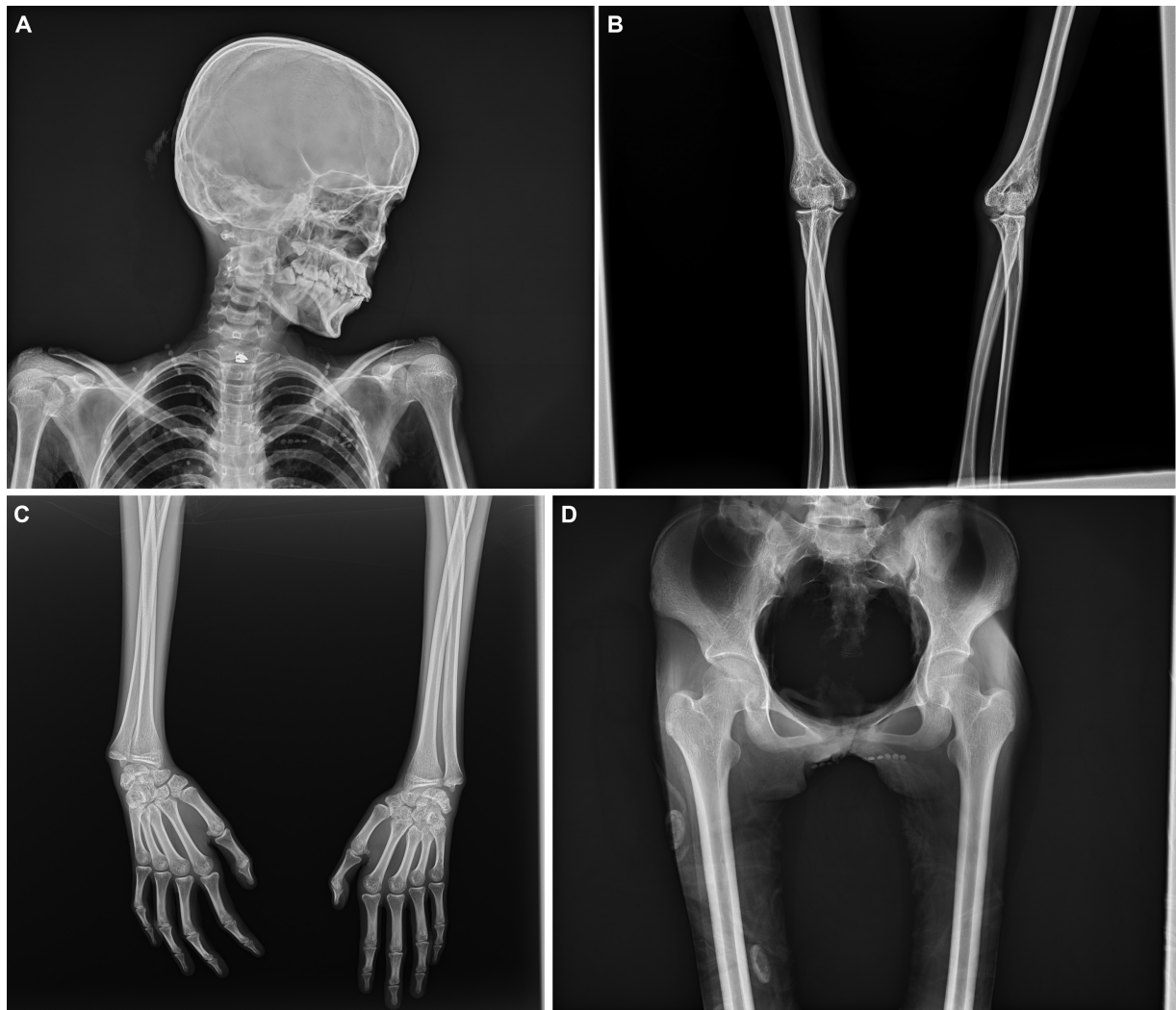

Fig. 3 (A) X-ray lateral view of skull showing: all teeth erupted except for third molar. Crown of third molar formed to the cemento-enamel junction and pulp chamber with a trapezoidal form, Acromion process appeared and not fused. Head of humerus not fused. (B) X-ray AP view of both elbow joints showing: Medial epicondyle of humerus not fused and head of radius partially fused with shaft. (C) X-ray AP view of both hands and wrist joints showing: Head of first metacarpal fused, distal end of radius and ulna partially fused. (D) X-ray AP view of pelvis and hip joints showing: Iliac crest, ischial tuberosity appeared but not fused. Head of femur not fused.

infections than women of older age.⁸ Because of the immune system's natural suppression during pregnancy, women may be more vulnerable to the consequences of infection.⁶ In this case the family was alleging the age of the girl to be 18 years that could be a reason to escape the legal implications. The postmortem examination revealed the age to be 15 to 16 years and this may be the best reason that the young female could not continue the advised treatment and investigations for fear of law.

The growth of a single microbial isolate is generally considered a true positive. The strain identified in this case was *Leuconostoc mesenteroides*, which belongs to the members of the Streptococcal family and has been regarded as nonpathogenic by some⁹ but some recognized as potential pathogens.¹⁰ It is known to be found in dairy products, pickles, skin of fruits, and other processed food. *Leuconostoc* is considered not part of the normal human microbiome and is potentially pathogenic causing endocarditis, urinary tract infections, intra-abdominal infections, and catheter-associated

bloodstream infections. Most of the *Leuconostoc mesenteroides* are nosocomial infections in immunocompromised patients.¹⁰ It is responsible for bacteremia, encephal meningitis, peritonitis, and pneumonia.^{10,11} Infective endophthalmitis,¹² infections, and outbreaks of *Leuconostoc* infections have also been reported.¹³ *Leuconostoc* infections are said to be directly associated with mortality as reported in a study of 88 cases of *Leuconostoc* infections.¹⁴ Many infections caused by these bacteria have also been reported especially in vancomycin-treated individuals and immunocompromised patients¹⁴ since the first instance of *Leuconostoc* infection in humans that was described in 1985.¹⁵ However, detection of these bacteria during pregnancy is not reported. In this case, the deceased was emaciated and pregnant. Pregnancy-related immunologic changes and inadequate nutrition might affect how infectious illnesses are transmitted and how susceptible pregnant women are to them. This alteration in the body's immunity might have played a role in facilitating the *Leuconostoc* infection in this

case. Gastric reflux and fatigue are very common during pregnancy that could have led to aspiration as the cause of death in the company of *Leuconostoc* infection.

Aspiration occurs when foreign material enters the airway. Mode of death in aspiration includes asphyxiation brought on by a blocked airway, inflammation or infection of the respiratory system brought on by inhaled debris, or aspiration pneumonia. In this case, the bronchioles were filled with yellowish mucoid with some granular substances and also there was microscopic evidence of acute lung injury in the form of congestion, interstitial thickening with inflammation, and inflammatory changes around the bronchial cartilage. This was confirmed by gross autopsy findings and was corroborated by histopathological examination as well. A meticulous autopsy along with appropriate postmortem ancillary investigations led to concocting the contributory elements leading to the cause of death of a young female with an incidental diagnosis of pregnancy on autopsy.

The right of minors to aware and responsible motherhood is guaranteed by laws in our country, but there are no measures that make it possible to readily implement these laws. Therefore, only a health professional can interpret the law's requirements and put them into practice. Health workers interpret and apply these laws, ensuring minors' rights while attending to pregnancies. Mandatory reporting of pregnant minors to the police, as mandated by obstetricians, contradicts the child's best interests and may deter seeking medical help, potentially endangering lives. Reporting such cases, even consensual ones, can be detrimental, particularly in rural settings where early marriages occur. Excessive reporting strains families and worsens burdens caused by teenage pregnancies. Re-evaluating reporting practices is essential to safeguard minors' rights and well-being.^{16,17}

Conclusion

While the autopsy itself provides valuable information, postmortem ancillary investigations can provide additional insight into the cause of death providing a more complete understanding of the circumstances surrounding the death. In this case, radiological examination helped in the estimation of the correct age and unraveling the discrepancies of the alleged age. Microbiological investigation helped in identifying an infection that contributed to the death and microscopic evidence of acute lung injury on histopathological examination that corroborates with aspiration as the cause of death and also established the manner of death as natural.

Conflict of Interest

None declared.

References

- Mazuchowski EL II, Meier PA. The modern autopsy: what to do if infection is suspected. *Arch Med Res* 2005;36(06):713–723
- Schneider V. [Value of bacteriologic studies within the scope of forensic autopsies]. *Z Rechtsmed* 1985;94(02):81–92 (In German.) [PubMed] [Google Scholar]
- Tsokos M, Püschel K. Postmortem bacteriology in forensic pathology: diagnostic value and interpretation. *Leg Med (Tokyo)* 2001;3(01):15–22
- Traeger MS, Wiersma ST, Rosenstein NE, et al; Florida Investigation Team. First case of bioterrorism-related inhalational anthrax in the United States, Palm Beach County, Florida, 2001. *Emerg Infect Dis* 2002;8(10):1029–1034
- Jermakow K, Rorat M. Post-mortem microbiology: retrospective analysis of infections caused by *Enterococcus* strains. *Pathogens* 2022;11(02):204
- Hunie M, Fenta E, Kibret S, Teshome D. The current practice of aspiration prophylaxis in obstetric anesthesia: a survey among non-physician anesthetic providers working in hospitals in Ethiopia. *BMC Anesthesiol* 2021;21(01):256
- Accessed August 24, 2023 at: https://www.indiacode.nic.in/handle/123456789/2079?sam_handle=123456789/1362
- Accessed August 24, 2023 at: <https://www.who.int/news-room/fact-sheets/detail/adolescent-pregnancy>
- Trujillo ME, Dedysh S, DeVos P, et al, Eds. *Bergey's Manual of Systematics of Archaea and Bacteria*. Hoboken, New Jersey: Wiley; 2015
- Meneguetti MG, Gaspar GG, Laus AM, Basile-Filho A, Bellissimo-Rodrigues F, Auxiliadora-Martins M. Bacteremia by *Leuconostoc mesenteroides* in an immunocompetent patient with chronic Chagas disease: a case report. *BMC Infect Dis* 2018;18(01):547
- Oh K, Jung D, Ko KS, Lee H, Park J, Lee H. Bacteremia caused by *Leuconostoc* species: 6-case series. *Kosin Med J* 2018;33:422
- Kumudhan D, Mars S. *Leuconostoc mesenteroides* as a cause of post-operative endophthalmitis—a case report. [8] *Eye (Lond)* 2004;18(10):1023–1024
- Franco-Cendejas R, Colín-Castro CA, Hernández-Durán M, et al. *Leuconostoc mesenteroides* periprosthetic knee infection, an unusual fastidious Gram-positive bacteria: a case report. *BMC Infect Dis* 2017;17(01):227
- Bou G, Luis Saleta J, Sáez Nieto JA, et al. Nosocomial outbreaks caused by *Leuconostoc mesenteroides* subsp. *mesenteroides*. *Emerg Infect Dis* 2008;14(06):968–971
- Buu-Hoi A, Branger C, Acar JF. Vancomycin-resistant streptococci or *Leuconostoc* sp. *Antimicrob Agents Chemother* 1985;28(03):458–460
- Ciulli P, Parlavecchio E, Onorati E, Russo P. Gli estrogeni nelle teen agers. Quali Risvolti medico-legali? [Contraception in teenagers. Medico legal implication] *Minerva Ginecol* 2002;54(02):189–192
- Vidanapathirana M, Rathnaweera R, Munasinghe K, Sanjeevane L. Study on pregnant teenagers referred by Obstetricians for medico-legal examination. *Medico-Legal J Sri Lanka* 2014;1:34–37