

Management of Lateral Wall Insufficiency

Sara W. Liu, MD¹  Sofia Lyford-Pike, MD²

¹Head and Neck Institute, Section of Facial Plastic and Microvascular Surgery, Cleveland Clinic, Cleveland, Ohio

²Department of Otolaryngology-Head and Neck Surgery, University of Minnesota, Minneapolis, Minnesota

Address for correspondence Sara W. Liu, MD, 9500 Euclid Avenue, A71, Cleveland, OH 44195 (e-mail: Lius11@ccf.org).

Facial Plast Surg 2023;39:616–620.

Abstract

Lateral wall insufficiency is a commonly encountered etiology of nasal obstruction, resulting from dynamic collapse at the level of the internal or external nasal valve. Various management strategies exist to strengthen the lateral wall or stent the nasal valves to relieve nasal obstruction, and range from noninvasive devices, minimally invasive implants, or surgical reconstructive techniques. Surgical options to address the nasal valves are selected based on each patient's anatomic findings, aesthetic and functional goals, and surgeon preference. This article describes the anatomy and physiology of the nasal sidewall and nasal valves and diagnosis of lateral wall insufficiency, and provides a framework for treatment options.

Keywords

- ▶ rhinoplasty
- ▶ nasal valve repair
- ▶ lateral wall insufficiency

Anatomy and Physiology

Lateral wall insufficiency (LWI) or collapse results in dynamic nasal valve compromise and is a primary cause of nasal obstruction. The lateral nasal wall is comprised of the skin-soft tissue envelope and the upper and lower lateral cartilages. This anatomic area is a key component of the nasal valve, which is described as the narrowest cross-sectional area of the nasal cavity with the greatest overall resistance to airflow. The nasal valve has two components, the external nasal valve (ENV) and the internal nasal valve (INV). The ENV is formed by the caudal septum and medial crura of the lower lateral cartilage (LLC) medially, nasal floor caudally, and alar cartilages and fibrofatty tissue laterally.¹ The INV is located approximately 1.3 cm from the nostril opening and is composed of the upper lateral cartilage (ULC) laterally, the dorsal septum medially, and inferiorly by the anterior aspect of the inferior turbinate.² The INV and ENV share a border at the caudal aspect of the ULC, also known as the scroll region.

The compressible cartilaginous structure of the external nose carries physiological properties with strong impacts on the nasal airway. The external nose is comparable to a Starling resistor, a rigid tube with a collapsible segment in which the internal pressure controls the degree of collapse of the tube. During inspiration, a negative pressure gradient is created between the atmosphere and the nasopharynx.

This is a result of Bernoulli's principle of fluid dynamics, which states that as velocity of a moving fluid increases, the pressure within the fluid decreases. As air flows past the narrowed segment of the nasal valve, the speed increases, thus decreasing pressure, resulting in collapse of the lateral wall toward the septum and narrowing of the valve. Poiseuille's law quantifies that flow is proportional to pressure difference multiplied by the radius to the fourth power, consequently small changes in the radius has a significant impact on flow.^{1,3-5}

Evaluation

LWI can be evaluated in the clinical setting with anterior rhinoscopy or nasal endoscopy to visualize the nasal valve. A grading system has been described which classifies LWI by the percentage of collapse of the nasal sidewall at the level of the INV toward the septum during inspiration as observed on nasal endoscopy. Grade 0 indicates no movement, Grade 1 corresponds to <33% collapse, Grade 2 to 33 to 66%, and Grade 3 to >66%.^{6,7} On physical exam, observation of the patient during passive and forced inspiration allows for evaluation of the structural integrity of the sidewall. In addition, the Cottle maneuver or modified Cottle maneuver is commonly employed to assess the nasal valve. The Cottle maneuver involves gentle lateral retraction of the cheek

article published online
September 14, 2023

Issue Theme Functional
Rhinoplasty; Guest Editors:
Krista L. Olson, MD, and Sunthosh
Kumar Sivam, MD

© 2023, Thieme. All rights reserved.
Thieme Medical Publishers, Inc.,
333 Seventh Avenue, 18th Floor,
New York, NY 10001, USA

DOI <https://doi.org/10.1055/s-0043-1773767>.
ISSN 0736-6825.

adjacent to the sidewall, whereas in the modified Cottle maneuver, a curette or back-end of a cotton-tipped applicator is inserted into the nostril to stent the sidewall. The patient then reports the degree of obstruction experienced before and after the maneuver, with a positive test indicating an improvement in airflow.⁸ Adjunctive testing has also been employed to evaluate nasal airflow through the nasal valve, including rhinomanometry and computed tomography; however, there is no gold standard test that accurately and objectively diagnoses LWI or nasal valve dysfunction. Additionally, these tests are often impractical or unavailable in office settings, so physical examination remains the go-to for evaluation and diagnosis of LWI. Patient-reported outcome measures can also be used to evaluate nasal obstruction. The impact of nasal obstruction on patient quality of life can be quantified using validated surveys such as the Nasal Obstruction Symptom Evaluation (NOSE)⁹ and Standardized Cosmesis and Health Nasal Outcomes Survey.¹⁰

Management

Nonsurgical Management

Although surgery is the mainstay of treatment for LWI, there are nonsurgical options available to patients who have mild symptoms or those who are not surgical candidates. Many over-the-counter products are available that attempt to increase nasal airflow by increasing the cross-sectional area of the nasal valve. They generally fall into three categories: external nasal dilators (ENDs), internal nasal stents (INs), and nasal clips.¹¹ These products are advertised for use for relief of temporary nasal obstruction (due to illness or allergies), improvement of sleep hygiene and snoring, and even for exercise performance enhancement.

ENDs are adhesive strips that are applied externally to the dorsum or cheek adjacent to the nose and exert a pulling force on the lateral nasal walls to increase the diameter of the nasal airway. The most commonly used and described in the literature are Breathe Right nasal strips, which stiffen the lateral walls to prevent inward collapse during inspiration, thus decreasing airflow resistance by about 10%.¹² One major disadvantage of ENDs is the external appearance during use, so they are primarily marketed for use during sleep.

More inconspicuous internal nasal devices can also be used to improve nasal obstruction due to LWI. INs are placed internally into each nostril and exert a circumferential outward force at the INV, while simultaneously compressing the columella medially to increase cross-sectional area of the ENV. Similarly, nasal clips are inserted over the septum with two endpieces that are inserted into each nostril to push the lateral wall out. In several studies, INs and nasal clips have been shown to increase nasal airflow and decrease resistance when compared to Breathe Right strips.^{13,14} These devices are also reusable since they do not involve an adhesive.

There are many varieties of each of these devices available to U.S. consumers to relieve nasal obstruction secondary to LWI; however, many of these are not reviewed in the scientific literature, making it difficult to compare individual products. However, nasal dilator products should be consid-

ered or recommended as a treatment modality for nasal obstruction, particularly in patients who are not surgical candidates.^{2,11} The devices can also be helpful in the evaluation of a surgical patient, as anecdotal benefit with use of a nasal dilator can confirm diagnosis of LWI and suggests that the patient would derive benefit from surgery addressing LWI.

Surgical Management

There is no gold-standard surgical treatment for LWI; rather, surgical repair should be tailored for each individual patient based on their physical exam findings, as well as functional and aesthetic goals, and surgeon preference. Correcting LWI should result in an improvement in the nasal airway by decreasing airflow resistance, while achieving a satisfactory cosmetic result. Structurally, the goals of surgical repair are to lateralize the sidewall away from the septum and reinforce the INV and ENV to prevent dynamic collapse. This can be achieved through various techniques well described in the literature, including suture techniques, alloplastic implants, cartilage grafting, and lateral suspension.

Suture Techniques

Suture techniques to achieve lateralization of the INV or ENV have been described as minimally invasive or adjunctive techniques to open rhinoplasty to improve LWI. Most commonly described is lateral suture suspension of the sidewall toward the inferior orbital rim or malar eminence. The point of maximal collapse is identified preoperatively with a modified Cottle maneuver. Under general anesthesia, skin overlying the inferior orbital rim or maxilla is incised, and the periosteum is exposed using a freer elevator. A Mitek self-retaining screw is inserted into the bone. An incision is made within the nasal vestibule at the previously marked location, and engaged with suture, that is then anchored to the Mitek screw.^{15,16} Alternatively, if foregoing use of the screw, the suture can be anchored to the periosteum in the same location.¹⁷ Tightening of this suture thus achieves lateral suspension of the nasal sidewall.

Other techniques that have been described in the literature include spanning sutures across the nasal dorsum to flare the ULCs, or LLC suspension and rotation toward the piriform aperture.¹⁶ There are limited data and existing studies have small patient populations; however, the major drawbacks reported for all suture techniques are loss of suspension that increased with duration of follow-up (as high as 35%) and infection rates up to 24%.¹⁷

Implants

The use of alloplastic implants has gained popularity in recent years. Titanium, silicone, and porous polyethylene have all been described as alternatives to cartilage grafting in rhinoplasty.¹⁸⁻²¹ Latera (Stryker, Kalamazoo, MI) is a Food and Drug Administration-approved bioabsorbable implant comprised of a 70:30 blend of poly(L-lactide) and poly(D-lactide) that is designed to support the ULC and LLC (see ► Fig. 1).²² The implant resorbs over a period of 18 to 24 months and is replaced with scar tissue to strength and




Fig. 1 Latera implant (Stryker, Kalamazoo, MI). Forked end is positioned subcutaneously superficial to the nasal bones, with the ribbed cylindrical portion extending caudally to lie over the upper and lower lateral cartilages.

reinforce a weak lateral wall. It is inserted into the sidewall through an endonasal minimally invasive technique using a delivery tool and is positioned over the nasal bone with a caudal extension toward the alar crease. Implantation can be done as a standalone procedure, or can be combined with septoplasty and inferior turbinate reduction, and can be performed in the operating room or in clinic under local anesthesia.²³ Adverse events associated with Latera implantation include infection, implant extrusion, failure to resorb, implant protrusion, and facial pain or discomfort.²⁴ The efficacy of Latera has been validated with patient-reported outcome measures, such as NOSE, and objectively with nasal endoscopy; however, studies are limited by short follow-up periods and lack of randomization.^{23,25–28}

Cartilage Grafting

LWI can be caused by inherent weakness of the cartilaginous framework, cephalic malposition of LLC, or concavity of LLC. Various cartilage grafting techniques can be employed during rhinoplasty to correct these deformities (see ►Fig. 2), and preoperative determination of the cause of LWI is prudent to select the appropriate surgical maneuvers. Grafts are fashioned from septal or conchal cartilage; costal cartilage is not ideal for grafting in the lateral wall, as it tends to be more rigid and bulky, and can result in external deformity even in thick-skinned patients.

Spreader grafts are frequently used to manage INV narrowing and correcting midvault deformity by restoring the dorsal aesthetic line. Although they do not directly address dynamic collapse, they are a useful tool in the armamentarium of nasal valve repair to widen the INV or correct concavity or deviation. They are fashioned ideally from straight pieces of cartilage (septal or conchal); if curved, the curve should face toward the septum. Spreader grafts are positioned between the septum and ULC unilaterally or bilaterally, and can be placed via an endonasal or open rhinoplasty approach.²⁹

Alar batten grafts are a workhorse for the treatment of LWI and can address both INV and ENV collapse. They can be placed via an endonasal approach or during traditional open rhinoplasty. Alar batten grafts are ideally curvilinear, with the convex surface placed against the lateral wall to support it, and should be thin with beveled edges to minimize external deformity.³⁰ Graft position should be at the point of maximal lateral collapse: the junction of caudal margin of ULC and cephalic margin of LLC to correct INV collapse, or caudal to cephalically positioned LLC for ENV. Grafts should span horizontally from the midpoint of the lateral crura and

extend onto the bony piriform aperture to prevent medial collapse.³¹ In the endonasal approach, the area of maximal nasal valve collapse is marked externally and infiltrated with local anesthetic. Using a 6- to 8-mm intranasal incision made at the point of supra-alar pinching, a precise pocket is dissected for graft placement. Using an open rhinoplasty approach, initial subcutaneous dissection to expose the LLC should not extend lateral to the junction of the middle and lateral third of the lateral crura. The graft is then placed superficial to the lateral cartilages in a subcutaneous pocket and secured with suture fixation.³¹ A through-and-through stitch can be placed by passing a needle from within the nasal cavity, creating a stab incision externally with an 11-blade scalpel, and passing the suture back through the nasal cavity to secure the graft and collapse the dead space in the

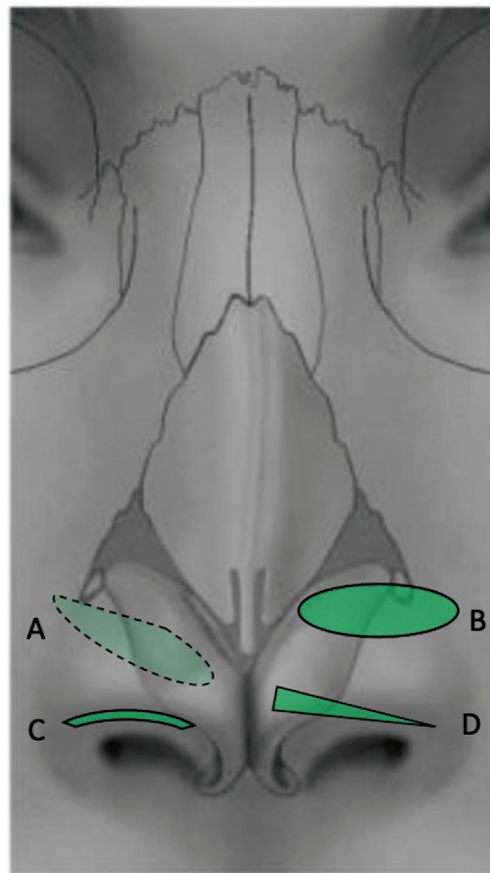


Fig. 2 Cartilage grafts commonly used for correction of lateral wall insufficiency. (A) Lateral crural strut graft, (B) alar batten graft, (C) alar rim graft, and (D) articulated alar rim graft.

dissection pocket. In both the endonasal and open approach, creation of the pocket is key to graft success. A pocket that is too wide risks graft migration, and not wide enough can result in graft distortion leading to deformity or nasal obstruction. Care must also be taken to orient the pocket horizontally, as oblique placement of the graft over the nasal bones will render the graft useless and cause persistent lateral wall fullness.

Lateral crural strut grafts (LCSGs) are indicated to correct ENV collapse resulting from cephalically malpositioned, weak, deficient, or concave LLCs. They can also contribute to nasal tip refinement and repositioning in patients with a boxy nasal tip.^{32,33} They are placed on the deep surface of the lateral crura, and are favored over batten grafts in patients with thin skin as they are more easily camouflaged. LCSGs are placed via an open rhinoplasty approach. Vestibular skin is undermined from the undersurface of the lateral crus from the cephalic border toward the caudal border. The integrity of the vestibular lining can be maintained during blunt dissection by first hydrodissecting with local anesthetic. The pocket can be extended laterally to the piriform aperture, alar base, or rim, depending on the patient's anatomic needs.³⁴ The LCSG is placed on the deep surface of the lateral crus, with the medial apex of the graft just lateral to the dome and cephalic margin not exceeding past the cephalic edge of the native lateral crus. The graft is secured with 2 to 3 sutures to the lateral crus with the knot placed away from the vestibular skin. In patients with cephalic malposition, the lateral crus can be released of its lateral attachments. The LCSG is then fixated to the undersurface of the lateral crura as described above, and the native cartilage and graft are then repositioned in a more caudal orientation within the alar lobule.³²

Cephalic turn-in of the lateral crura can be performed in patients with wide (greater than 12 mm) lateral crura and allows for reinforcement and reshaping without the need for a graft.³⁵ The vestibular skin is dissected from the undersurface of the LLC in a similar manner to LCSG placement. The caudal border of the vestibular skin is left attached. A partial thickness cut is made dividing the lateral crura along its horizontal axis, making sure to preserve at least 8 mm from the caudal border.³⁶ The cephalic portion is then folded under the caudal and fixated with suture.

Collapse of the alar margin due to inherent rim weakness or cephalic malposition of LLC can be managed using an alar rim graft (ARG). This technique can correct alar concavity, increase nostril aperture size, and improve alar support.³⁷ ARGs are fashioned to span the length of the alar margin that requires spanning, with beveled edges to reduce palpability. The medial end can also be softened by gentle crushing with a Brown-Adson forceps. The ARG is placed within a tunnel directly along the alar margin. By everting the rim with a wide double-pronged retractor, a precise tunnel can be dissected from the medial aspect of the marginal incision to the alar base with a narrow-tipped scissor and Cottle elevator.³⁸ To prevent migration of the graft, overdissection of the pocket is to be avoided.

The articulated ARG (AARG) is a modification of the ARG with integration to the tip framework, providing increased

stability and minimal risk of graft migration.²⁹ In addition, this technique can be a powerful tool to correct alar retraction. An open rhinoplasty approach is used, followed by dissection and release of the lateral crus. A caudal septal extension graft (CSEG) is used to immobilize and strength the tip complex. AARGs are fashioned from septal or chondral cartilage ideally, as conchal cartilage lacks the necessary stiffness, and are carved into a long triangular wedge, with the base of the triangle positioned over the domes and secured to the CSEG, creating a cantilever effect.³⁹ The apex of the graft is then tucked into a snug tunnel along the alar margin, similar to the ARG graft placement technique.

Conclusion

LWI is a frequently encountered etiology of nasal obstruction. Multiple treatment modalities exist, ranging from nonsurgical to minimally invasive to open rhinoplasty with extensive grafting techniques. In some cases, a combination of techniques may be necessary to address the root cause of LWI. Patients should be carefully evaluated, and treatment should be tailored to each individual patient based on their anatomic findings, symptoms, and prior nasal surgery history.

Conflict of Interest

None declared.

References

- 1 Hamilton GS III. The external nasal valve. *Facial Plast Surg Clin North Am* 2017;25(02):179–194
- 2 Rhee JS, Weaver EM, Park SS, et al. Clinical consensus statement: diagnosis and management of nasal valve compromise. *Otolaryngol Head Neck Surg* 2010;143(01):48–59
- 3 Bridger GP. Physiology of the nasal valve. *Arch Otolaryngol* 1970;92(06):543–553
- 4 Howard BK, Rohrich RJ. Understanding the nasal airway: principles and practice. *Plast Reconstr Surg* 2002;109(03):1128–1146, quiz 1145–1146
- 5 Kasperbauer JL, Kern EB. Nasal valve physiology. Implications in nasal surgery. *Otolaryngol Clin North Am* 1987;20(04):699–719
- 6 Tsao GJ, Fijalkowski N, Most SP. Validation of a grading system for lateral nasal wall insufficiency. *Allergy Rhinol (Providence)* 2013;4(02):e66–e68
- 7 Vaezaefshar R, Moubayed SP, Most SP. Repair of lateral wall insufficiency. *JAMA Facial Plast Surg* 2018;20(02):111–115
- 8 Das A, Spiegel JH. Evaluation of validity and specificity of the Cottle maneuver in diagnosis of nasal valve collapse. *Plast Reconstr Surg* 2020;146(02):277–280
- 9 Stewart MG, Witsell DL, Smith TL, Weaver EM, Yueh B, Hannley MT. Development and validation of the Nasal Obstruction Symptom Evaluation (NOSE) scale. *Otolaryngol Head Neck Surg* 2004;130(02):157–163
- 10 Moubayed SP, Ioannidis JPA, Saltychev M, Most SP. The 10-item Standardized Cosmesis and Health Nasal Outcomes Survey (SCHNOS) for functional and cosmetic rhinoplasty. *JAMA Facial Plast Surg* 2018;20(01):37–42
- 11 Kiyohara N, Badger C, Tjoa T, Wong B. A comparison of over-the-counter mechanical nasal dilators: a systematic review. *JAMA Facial Plast Surg* 2016;18(05):385–389
- 12 Wong LS, Johnson AT. Decrease of resistance to air flow with nasal strips as measured with the airflow perturbation device. *Biomed Eng Online* 2004;3(01):38

- 13 Raudenbush B. Stenting the nasal airway for maximizing inspiratory airflow: internal Max-Air Nose Cones versus external Breathe Right strip. *Am J Rhinol Allergy* 2011;25(04):249–251
- 14 Peltonen LI, Vento SI, Simola M, Malmberg H. Effects of the nasal strip and dilator on nasal breathing—a study with healthy subjects. *Rhinology* 2004;42(03):122–125
- 15 White JR Jr, Hamilton GS III. Mitek suspension of the lateral nasal wall. *Facial Plast Surg* 2016;32(01):70–75
- 16 Page MS, Menger DJ. Suspension suture techniques in nasal valve surgery. *Facial Plast Surg* 2011;27(05):437–441
- 17 Nuara MJ, Mobley SR. Nasal valve suspension revisited. *Laryngoscope* 2007;117(12):2100–2106
- 18 Wengen DF. Titanium implants in the nose: state of the art. *Facial Plast Surg* 2022;38(05):461–467
- 19 Goldman ND, Alexander R, Sandoval LF, Feldman SR. Nasal valve reconstruction using a titanium implant: an outcomes study. *Craniofacial Trauma Reconstr* 2017;10(03):175–182
- 20 Hurbis CG. An adjustable implant for nasal valve dysfunction: a 3-year experience. *Ear Nose Throat J* 2012;91(08):E5–E12
- 21 Gürlek A, Celik M, Fariz A, Ersöz-Oztürk A, Eren AT, Tenekci G. The use of high-density porous polyethylene as a custom-made nasal spreader graft. *Aesthetic Plast Surg* 2006;30(01):34–41
- 22 Sanan A, Most SP. A bioabsorbable lateral nasal wall stent for dynamic nasal valve collapse: a review. *Facial Plast Surg Clin North Am* 2019;27(03):367–371
- 23 Sidle DM, Stolovitzky P, Ow RA, et al. Twelve-month outcomes of a bioabsorbable implant for in-office treatment of dynamic nasal valve collapse. *Laryngoscope* 2020;130(05):1132–1137
- 24 Wilkins SG, Sheth AH, Kayastha D, et al. Adverse events associated with bioabsorbable nasal implants: a MAUDE database analysis. *Otolaryngol Head Neck Surg* 2023;168(05):1253–1257
- 25 Stolovitzky P, Senior B, Ow RA, Mehendale N, Bikhazi N, Sidle DM. Assessment of bioabsorbable implant treatment for nasal valve collapse compared to a sham group: a randomized control trial. *Int Forum Allergy Rhinol* 2019;9(08):850–856
- 26 Olson MD, Barrera JE. A comparison of an absorbable nasal implant versus functional rhinoplasty for nasal obstruction. *Am J Otolaryngol* 2021;42(06):1031–18
- 27 Kim DH, Lee HH, Kim SH, Hwang SH. Effectiveness of using a bioabsorbable implant (Latera) to treat nasal valve collapse in patients with nasal obstruction: systemic review and meta-analysis. *Int Forum Allergy Rhinol* 2020;10(06):719–725
- 28 Clark CM, Hakimi AA, Parsa KM, et al. Comparison of nasal obstruction symptom evaluation score outcomes after autologous cartilage grafts and Latera nasal implants. *Ann Otol Rhinol Laryngol* 2023;132(08):912–916
- 29 Ji KSY, Krane NA. Surgical treatment of dynamic nasal collapse. *Facial Plast Surg* 2022;38(04):339–346
- 30 Chua DY, Park SS. Alar batten grafts. *JAMA Facial Plast Surg* 2014;16(05):377–378
- 31 Toriumi DM, Josen J, Weinberger M, Tardy ME Jr. Use of alar batten grafts for correction of nasal valve collapse. *Arch Otolaryngol Head Neck Surg* 1997;123(08):802–808
- 32 Toriumi DM, Asher SA. Lateral crural repositioning for treatment of cephalic malposition. *Facial Plast Surg Clin North Am* 2015;23(01):55–71
- 33 Gunter JP, Friedman RM. Lateral crural strut graft: technique and clinical applications in rhinoplasty. *Plast Reconstr Surg* 1997;99(04):943–952, discussion 953–955
- 34 Silva Filho RdeO, Pochat VD. Anatomical study of the lateral crural strut graft in rhinoplasty and its clinical application. *Aesthet Surg J* 2016;36(08):877–883
- 35 Apaydin F. Lateral crural turn-in flap in functional rhinoplasty. *Arch Facial Plast Surg* 2012;14(02):93–96
- 36 Abdelwahab M, Patel P, Kandathil CK, Wadhwa H, Most SP. Effect of lateral crural procedures on nasal wall stability and tip aesthetics in rhinoplasty. *Laryngoscope* 2021;131(06):E1830–E1837
- 37 Guyuron B, Bigdeli Y, Sajjadian A. Dynamics of the alar rim graft. *Plast Reconstr Surg* 2015;135(04):981–986
- 38 Boahene KDO, Hilger PA. Alar rim grafting in rhinoplasty: indications, technique, and outcomes. *Arch Facial Plast Surg* 2009;11(05):285–289
- 39 Ballin AC, Kim H, Chance E, Davis RE. The articulated alar rim graft: reengineering the conventional alar rim graft for improved contour and support. *Facial Plast Surg* 2016;32(04):384–397