



Indirect Anterior Restorations with *no-prep* technique: Aesthetic and Biological Effectiveness

Alfio Pappalardo¹ Luca Fiorillo^{2,3,4} Francesco Catalano³ Gabriele Cervino³

¹Private Practice, Catania, Italy

²Department of Public Health Dentistry, Dr. D.Y. Patil Dental College and Hospital, Dr. D.Y. Patil Vidyapeeth, Pune, Maharashtra, India

³Department of Biomedical and Dental Sciences, Morphological and Functional Images, University of Messina, Messina, Italy

⁴Multidisciplinary Department of Medical-Surgical and Odontostomatological Specialties, University of Campania "Luigi Vanvitelli", Naples, Italy

Address for correspondence Luca Fiorillo, DDS, MSc, PhD, BIOMORF, University of Messina, Via Consolare Valeria 1, Messina, 98100, Italy (e-mail: lfiorillo@unime.it).

Eur J Gen Dent 2023;12:127–134.

Abstract

Keywords

- ▶ prosthodontics
- ▶ dental tissue
- ▶ no-prep
- ▶ oral health
- ▶ oral rehabilitation
- ▶ porcelain veneers
- ▶ aesthetic

The aesthetic result in the ceramic restoration of anterior teeth has always been a challenge in clinical practice and, in these cases, success depends on the skills of both the clinician and the dental technician. In current dentistry, the main objective is to pursue aesthetic results while preserving biological structures. Among the various conservative techniques available for anterior restorations, veneers are the most advantageous, compared to traditional crown preparation, both for the amount of tooth structure preserved in the preparation phase and for the direct adhesion on the enamel in the cementation. This article presents a clinical case of no-prep porcelain veneers (*no-prep technique*) for smile frame restoration.

Introduction

Prosthodontics is a specialized branch of dentistry that focuses on designing, fabricating, and fitting artificial replacements for missing teeth and other structures in the oral cavity. Prosthodontics aims to restore the patient's oral function, esthetics, and overall quality of life. *No-prep techniques* in dentistry are a relatively recent development that has revolutionized the field of prosthodontics.¹ These techniques use innovative materials and procedures to create dental restorations requiring little or no natural tooth structure preparation. This approach is attractive to patients because it often eliminates the need for injections and drilling, resulting in a more comfortable and less invasive treatment experience.

Some examples of *no-prep techniques* include using porcelain veneers, which can be bonded directly to the tooth's surface, and dental crowns that are milled using computer-

aided design and manufacturing (CAD/CAM) technology. No-prep techniques can offer a range of benefits, such as preserving more of the natural tooth structure, reducing the risk of post-treatment sensitivity, and producing more predictable and aesthetically pleasing results.² Dental anterior restoration refers to repairing or replacing damaged or missing teeth in the front of the mouth. One of the newer techniques used for anterior restoration is the no-prep approach. The no-prep technique involves placing a dental veneer directly onto the existing tooth without removing any natural tooth structure. This approach is often used for minor cosmetic improvements or repairing small chips and cracks in the front teeth. One advantage of the no-prep technique is that it is minimally invasive, meaning less disruption to the natural tooth structure. This can help preserve the tooth's health and reduce the risk of postoperative sensitivity. Another advantage is that the no-prep technique often requires only one visit to the dentist, as opposed to

article published online
September 18, 2023

DOI <https://doi.org/10.1055/s-0043-1772571>.
ISSN 2320-4753.

© 2023. The Author(s).

This is an open access article published by Thieme under the terms of the Creative Commons Attribution License, permitting unrestricted use, distribution, and reproduction so long as the original work is properly cited. (<https://creativecommons.org/licenses/by/4.0/>)

Thieme Medical and Scientific Publishers Pvt. Ltd., A-12, 2nd Floor, Sector 2, Noida-201301 UP, India

traditional dental veneers, which may require multiple visits. This can save time and reduce the overall cost of the procedure. However, the no-prep technique may only be suitable for some.

In some cases, the existing tooth may need more surface area to support a veneer without removing some natural tooth structure. In these cases, a traditional veneer may be necessary.³ The no-prep technique may not provide as long-lasting results as conventional veneers. This is because the veneers may only bond as strongly to the tooth, removing some of the natural tooth structure. The new mode of operation for many practitioners is to exploit healthy tooth tissue through partial adhesive restorations rather than preparing teeth for full coverage restorations. In particular, porcelain veneers are a minimally invasive aesthetic restoration option with a high success rate for color stability, biocompatibility, mechanical properties, and good aesthetic results.⁴⁻⁶ In selected cases, it is possible to obtain all the advantages of ceramics, especially its high bond strength to the enamel, without preparing the tooth,^{7,8} achieving various clinical benefits: no form of postoperative sensitivity, maximum bond strength to the enamel, function and aesthetics at the long term and possibility of reversibility. The main indications for this type of aesthetic restoration are as follows:

- Teeth with a previous minor additive composite restoration whose removal gives the technician the necessary space for the realization of the ceramic restoration;
- Teeth with anatomical alterations that allow insertion for ceramic veneers.

The latter indication fits perfectly with the clinical case in the following article.

Case Report

The no-prep technique in dentistry typically involves the following phases:

- Consultation: The first step is to consult with your dentist to assess your dental needs and determine if the no-prep technique is appropriate.
- Preparation: Once it is determined that the no-prep technique is the best option, the dentist will take impressions of your teeth to create a custom-fit veneer.
- Bonding: On your next visit, the dentist will clean and prepare the surface of the tooth to be restored. The veneer is then bonded to the tooth's surface using a unique dental adhesive.
- Polishing: After the veneer has been bonded, the dentist will polish and shape it to match the surrounding teeth.
- Follow-up: The dentist will schedule a follow-up appointment to ensure the veneer functions correctly and make any necessary adjustments.

The no-prep technique is a minimally invasive and efficient way to restore damaged or discolored teeth. Choosing a skilled and experienced dentist is essential to ensure the best outcome.

Case Presentation

After orthodontic therapy with a straight-wire technique, the female patient wanted to restore the harmony of her smile with minimally invasive treatment. The disharmony was related to the genesis of element 1.2 and the anomaly of the shape and volume of element 2.2. To evaluate the case, intra- and extraoral photos were taken to discuss the case with the patient and the technician and choose the most appropriate treatment plan for the clinical case (►Figs. 1-2). Subsequently, impressions were taken in polyvinylsiloxane on nonperforated commercial impression trays to create the diagnostic wax-up in the laboratory.

Diagnostic Wax-Up

In the laboratory, the impressions were developed with extra-hard plaster for the diagnostic wax-up involving elements 1.4-1.3-2.2-2.3; on the 1.4, a shape similar to a canine was given on the buccal side, on the 1.3, a shape more similar to a lateral incisor, on the 2.2 an increase in volume to close the distal diastema. Finally, in 2.3, a shape and volume in harmony with the contralateral 14 (►Fig. 3). Based on the wax-up, a transparent silicone key was made for the mockup.

Mockups

The composite mockup makes it possible to evaluate the diagnostic wax-up volumes and modify its shapes, dimensions and lengths if they are not congruous with the patient's smile and face (►Fig. 4).

A softer, oval shape of the teeth harmonizes well with the patient's face. The smile line follows the lower and upper lip trend, and the occlusal plane is symmetrical with the median lines and the bipupillary line (►Fig. 5).⁹

After removing the mockup, a definitive polyvinylsiloxane impression was taken with the single-phase bi-paste technique with commercially available nonperforated impression trays.

Technical and Laboratory Phases

The veneers were made of feldspar ceramic and sintered on the platinum sheet with the alveolar model technique (►Fig. 6). The translucency of the material characterizes these ceramic restorations to obtain highly aesthetic restorations with very thin ceramic layers, up to 0.5 mm, with or without preparation (►Fig. 7).

The only weak point remains the resistance to fracture with an elastic modulus ranging between 50 and 120 Mpa, which classifies it as a brittle ceramic. However, the brittleness of these ceramic materials can be considered before the adhesive cementation stage of the restorations. The distribution and interaction of crystals within the glass matrix change the mechanical properties, and the finer the crystals, the higher the fracture resistance^{10,11} (►Fig. 8).

Results

After isolation with a rubber dam (►Fig. 9), the teeth were cleaned with brushes and pumice. The final restorations were tried in for fit, shape, and color. Subsequently, the intaglio surfaces of the repairs were etched with 9%

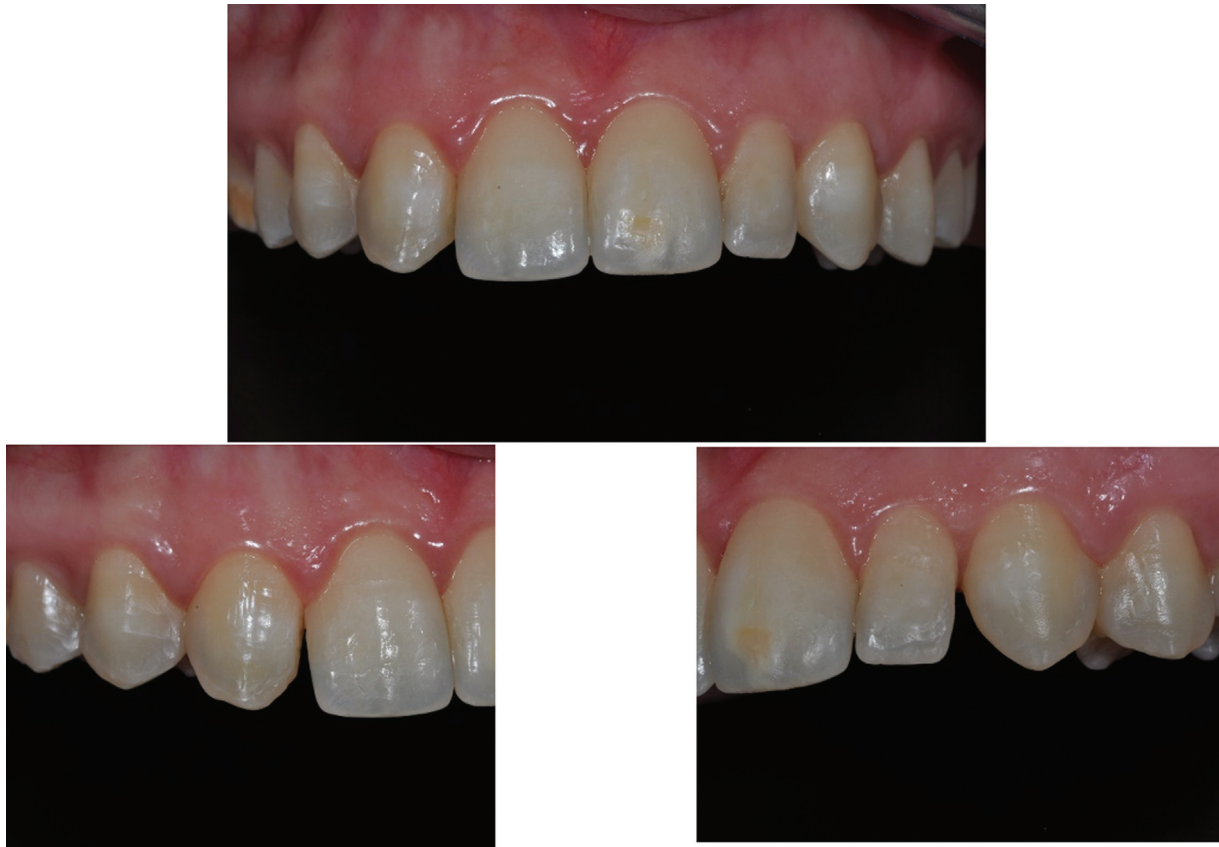

Fig. 1 Intraoral preoperative photo.

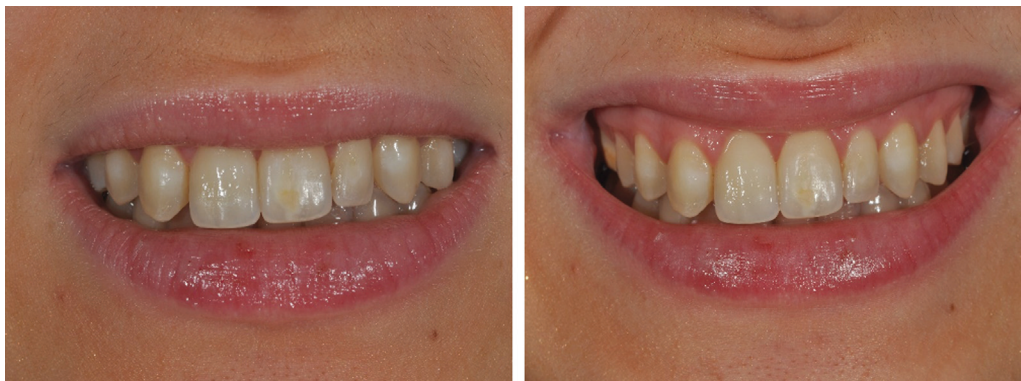

Fig. 2 Extraoral preoperative photo with relaxed and smiling lips.

hydrofluoric acid for 20 seconds to enhance the micromechanical retention of the ceramic artefacts. Crystalline precipitates are produced during acid etching, which could decrease the adhesive strength of the restorations,¹² which is removed by immersing the frameworks in an ultrasonic bath for 5 minutes. After rinsing and drying, a silane agent was applied for 1 minute. The dental substrate was etched with phosphoric acid for 60 seconds (**Fig. 10**), rinsed and air-dried.¹³ Without curing, an unfilled, hydrophobic universal bonding agent was applied to the framework and dental substrate. For the cementation of the veneers, a dual aesthetic resinous definitive cement was used, chosen based on

its mechanical properties and the restorative material used, and, after careful removal of the excess, the product was polymerized with a LED lamp for 40 seconds with low power mode. Afterward, glycerin gel was applied to block the air and light-cured again for 40 seconds with a high-power method on all surfaces.

The further excesses of resinous cement were removed with scalpel n.12, which does not damage the ceramic restorations (**Fig. 11**). The veneers were cemented one at a time. The finishing was carried out with interproximal abrasive strips, and finally, the rubber dam was removed to carry out the occlusal registration (**Figs. 12 and 13**).

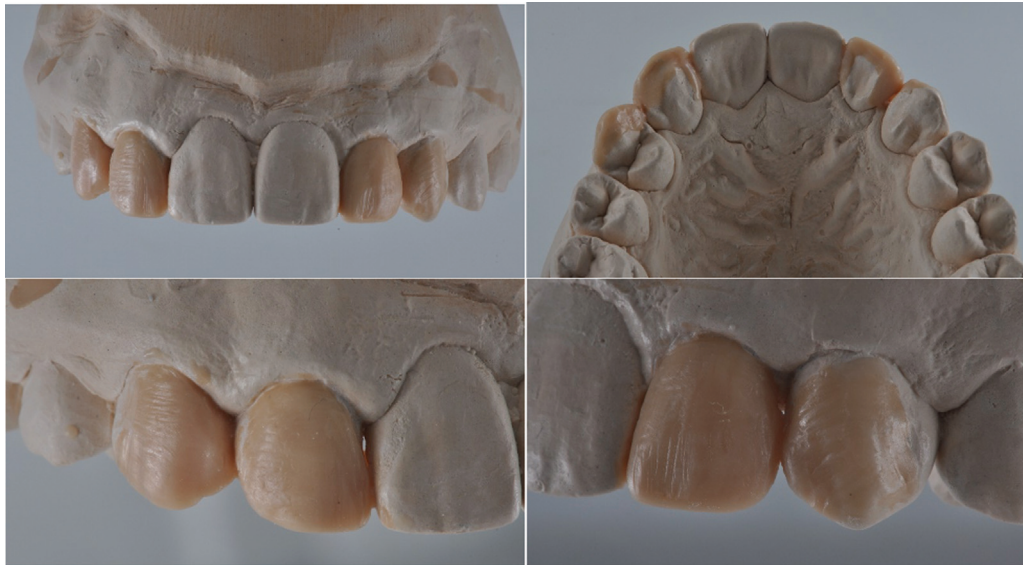

Fig. 3 Additive diagnostic wax-up.

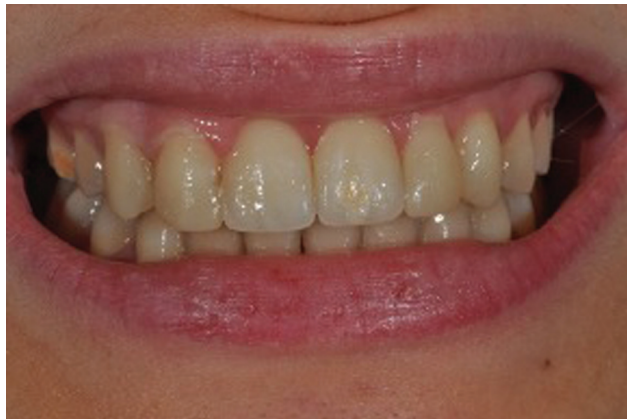

Fig. 4 Intraoral previsualization of final rehabilitation.

Fi-index Tool

This manuscript has been checked with the Fi-index tool and obtained a score of 0 on the date 19/12/22 according to Scopus for the first author only.^{14,15}

Discussion and Conclusions

Veneers are thin ceramic plates cemented onto the teeth's outer surface to improve aesthetics (dark, chipped teeth, closed spaces between teeth or restore function; teeth worn out due to wear, abrasion, and erosion). The no-prep technique is often combined with the creation of partial restorations called "additional": if it is not necessary to cover the entire surface of one or more teeth, it is possible to manufacture small ceramic fragments that can be cemented. This is necessary to fill a space or restore, for example, a fractured cusp. Similarly, today it is also possible to make very thin lithium disilicate crowns ("full veneers") in cases where it is necessary to completely cover the tooth surface (teeth heavily destroyed by caries, teeth consumed by wear or abraded by



Fig. 5 The extraoral figure of the mockup.

chemical substances, such as food acids, etc.). The small thickness of these crowns (up to 0.3 mm) allows you to make minimally invasive preparations or not touch the teeth with the burs. This will enable you to save the amount of enamel and dentin and not devitalize the teeth for prosthetic crowns.¹⁶⁻¹⁸

The ceramic veneers allow correcting anomalies of shape and volume (closing of black interdental triangles and diastemas, conoid teeth), pigmentations, and dyschromia such as nicotine and/or caffeine stains, yellowed, composite restorations, malpositions, and congenital enamel defects (e.g., fluorosis, imperfect amelogenesis), giving harmony to the smile even with a nonoptimal position of the teeth. Modern material technologies today allow various types of ceramics

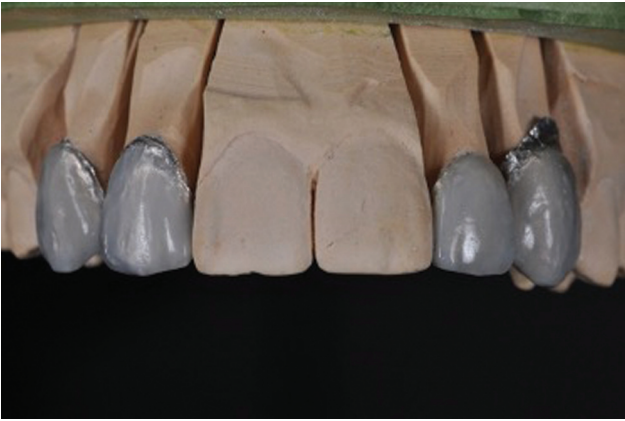

Fig. 6 Feldspathic ceramic platin-synthesized.



Fig. 7 Feldspathic ceramic restorations.

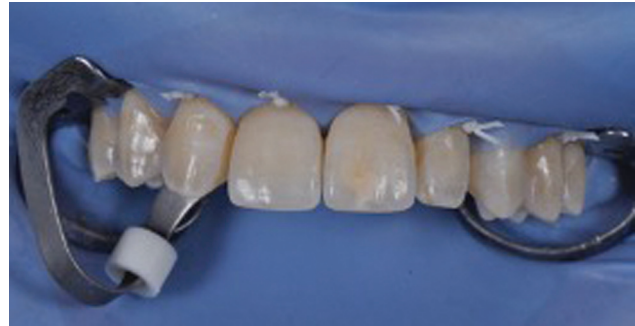

Fig. 9 Dental dam isolated field.

to create veneers, from traditional highly translucent feldspathic ceramics to the more recent highly resistant lithium disilicate-based ceramics. It is evident that a microscope or magnifying system is almost indispensable for rehabilitations carried out with these materials. The optimal mechanical properties and the high fracture resistance of the disilicate allow for the creation of definitive veneers in biomechanically nonideal situations, such as in patients with bites or the case of severe wear of the incisal edges. Since veneer preparation is a noninvasive technique that does not involve the gingival space, it is now possible to use intraoral scanners to take a digital impression of veneers. Compared to traditional ones, digital impressions do not require pastes, impression materials, or impression trays, which are often bulky and uncomfortable for patients. Intraoral scanners are high-resolution cameras that allow you to detect the shape of the teeth and gums and the color of the tissues, creating the veneers in a wholly digital way. This technique is very comfortable and quick and allows you to check the precision of the preparations in real time.^{2,19,20}

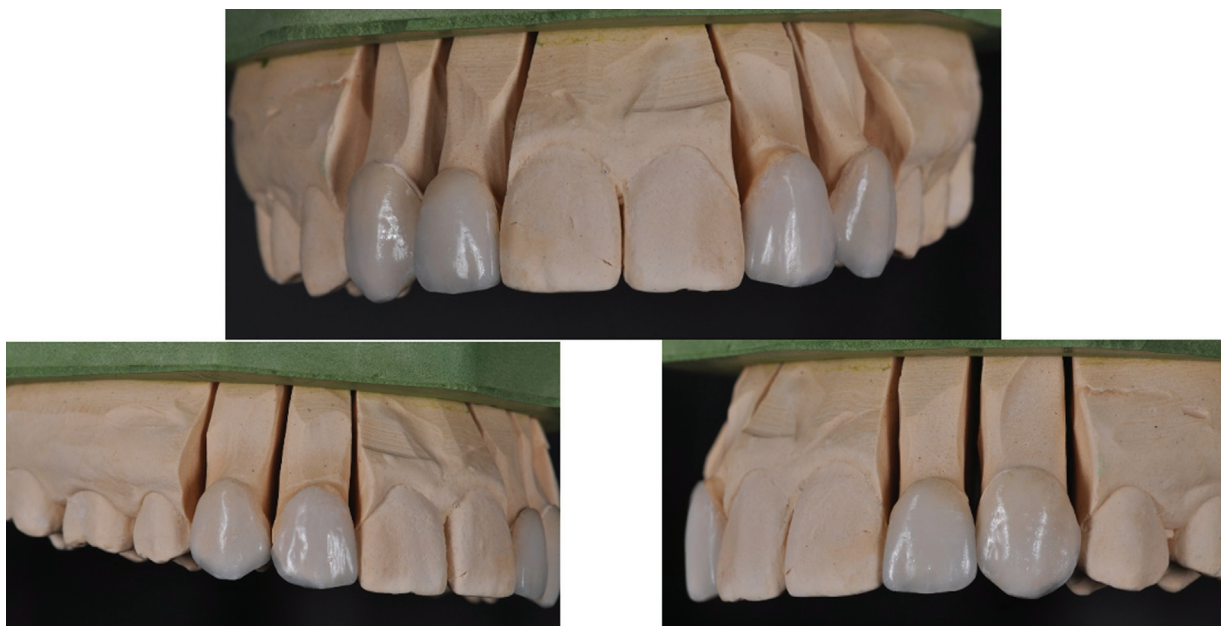


Fig. 8 Final restoration on the plaster model.

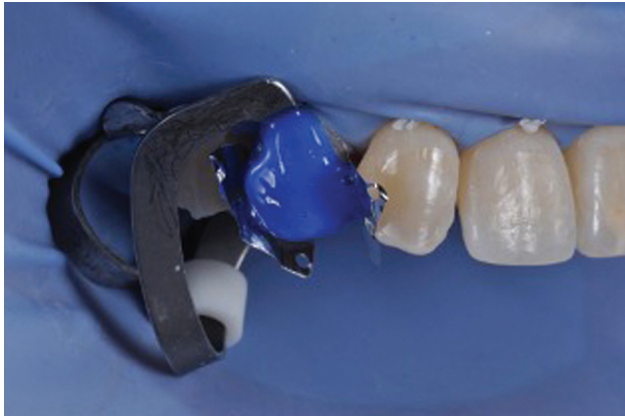

Fig. 10 Acid etching with a dental dam.

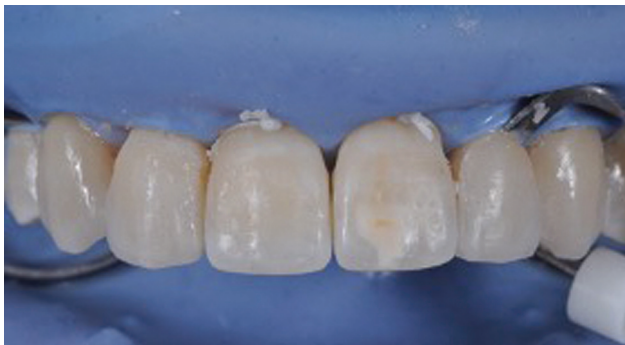

Fig. 11 Cemented veneers.

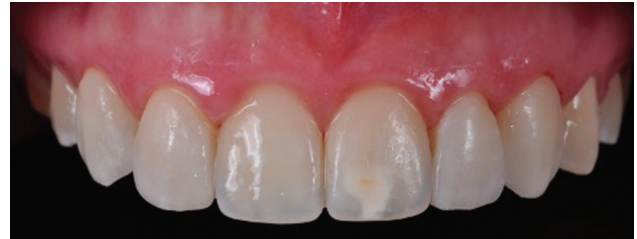

Fig. 12 Intraoral final result.

The treatment has no absolute contraindications and can be performed at any age. In the case of young patients who have not yet completed their growth (about 16 years for females and 18 for males), it is preferable to use dental veneers in composite resin. This material can be modified and/or removed more easily over time.²¹

Ceramic dental veneers can be made in the presence of composite reconstructions (frequent in patients who have chipped or worn teeth), provided the filling material does not show infiltrations (dark coloring of the margins) or secondary caries. The indirect restoration in the anterior sectors still today remains the gold standard for restoring a smile respecting the canons of aesthetics, function and durability over time compared to direct composite restorations in the anterior sectors, which have the advantage of requiring a single session, lower costs, and no tooth preparation.^{3,16,19,22} In fact, among the disadvantages of indirect restorations, the need to prepare the tooth to give the correct thickness to the product would not meet today's concepts of minimally inva-

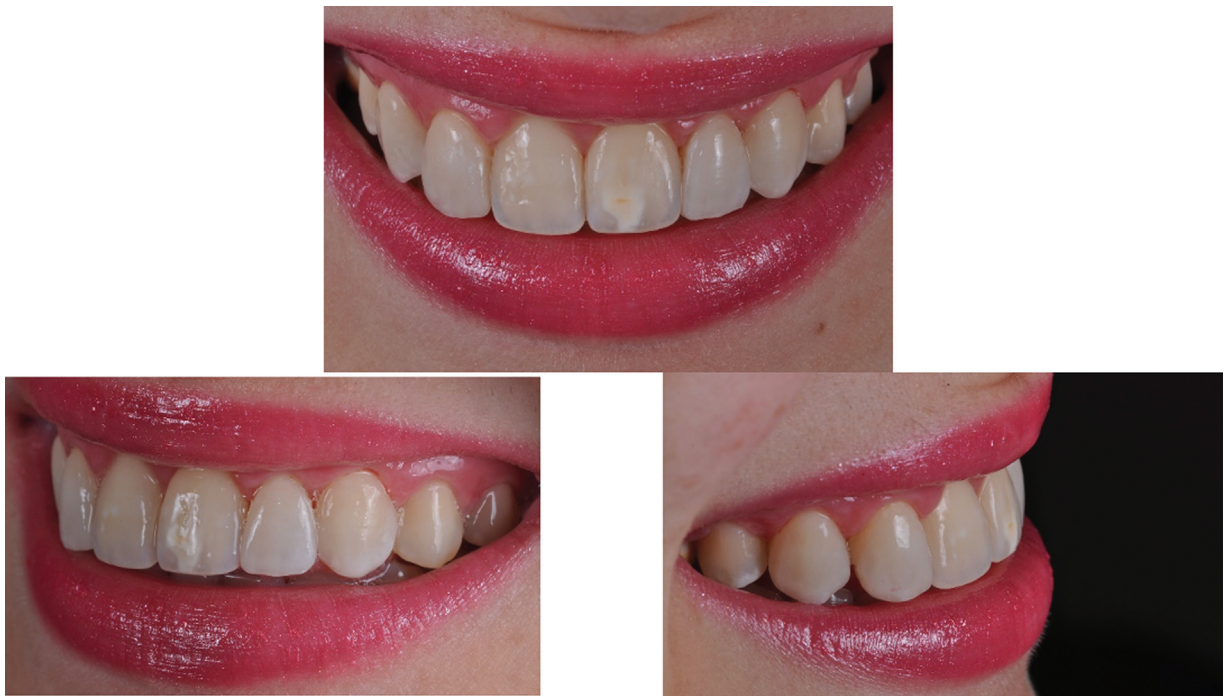

Fig. 13 Extraoral final result.

Table 1 Pros and cons of no-prep techniques

Pros	Cons
Minimally invasive: The no-prep technique preserves more natural tooth structure than traditional restorations, resulting in a minimally invasive approach. This can help maintain tooth health and reduce the risk of postoperative sensitivity	Limited indications: The no-prep technique may not be suitable for all cases. In situations where more extensive tooth surface area is required to support a restoration or when significant tooth structure needs correction, a traditional preparation approach may be necessary
Aesthetic results: No-prep restorations can provide highly aesthetic and natural-looking results, enhancing the patient's smile and overall appearance. The use of advanced materials and bonding techniques contributes to improved aesthetics	Long-term durability: While no-prep restorations can provide aesthetically pleasing results, they may not offer the same long-term durability as traditional restorations. The bonding strength of veneers without tooth preparation may be lower, potentially affecting the restoration's longevity
Time-efficient: No-prep techniques often require fewer dental visits, as the restorations can be fabricated and placed in a single appointment. This saves time for both the patient and the dentist	Case selection complexity: Choosing the appropriate cases for the no-prep technique requires careful evaluation and case selection. Dentists need to consider factors such as the patient's oral health, occlusion, and aesthetic goals to determine if the no-prep approach is suitable
Patient comfort: The absence of injections and drilling associated with the no-prep technique makes it a more comfortable and less invasive treatment option. Patients may experience less anxiety and discomfort during the procedure	Expertise and training: Performing successful no-prep restorations requires expertise and training in adhesive techniques and materials

sive dentistry. No-prep techniques in dentistry have several advantages that make them an attractive option for patients who require dental restorations.²³ Here are some of the critical benefits of no-prep techniques:

- **Minimally invasive:** No-prep techniques typically require little or no removal of natural tooth structure, meaning patients can undergo treatment with less pain and discomfort.
- **Preservation of tooth structure:** By preserving more of the natural tooth structure, no-prep techniques help maintain the tooth's structural integrity and reduce the risk of complications in the future.
- **Aesthetic appeal:** No-prep techniques can produce highly aesthetic, natural-looking, and long-lasting results.
- **Speed:** These techniques are often quicker than traditional dental procedures, meaning patients can complete treatment in fewer visits and spend less time in the dentist's chair.
- **Reduced sensitivity:** Because no-prep techniques do not require injections or drilling, patients may experience less post-treatment sensitivity and discomfort (► **Table 1**).

In the future, no-prep techniques will become even more sophisticated and effective. Advances in materials science and digital technology allow dentists to create more durable, functional, and aesthetic restorations than ever before. Additionally, as more dentists adopt these techniques, they will likely become more widely available and affordable, making them accessible to a more significant number of patients. Overall, no-prep techniques represent an exciting development in the field of dentistry that has the potential to significantly improve the patient experience and the quality of care provided by dental professionals. But today, the technological evolutions of materials, both the artefacts and the resinous types of cement, make it possible to save

healthy dental tissue by exploiting the no-prep technique when the correct diagnosis is made and when we have the clinical indication, as in the case presented in this article. The field of prosthodontics is continually evolving, and the future holds promising developments for no-prep techniques in dentistry. Advancements in material science can lead to the development of advanced dental restoration materials, offering improved aesthetics, durability, and bond strength for no-prep restorations. Integrating digital dentistry and CAD/CAM technology will play a significant role, with advancements in intraoral scanners and CAD/CAM systems streamlining the fabrication process for more precise and efficient restoration production. Researchers are exploring biocompatible and biomimetic materials that mimic natural tooth properties, enhancing aesthetics and functionality while promoting long-term oral health. Advancements in digital technology may enable highly customized and personalized restorations based on patient-specific data, leading to improved treatment outcomes and patient satisfaction. Future developments may further reduce tooth preparation, with minimally invasive techniques such as regenerative approaches and bioactive materials promoting natural tooth regeneration and reducing the need for restorative interventions. In conclusion, the no-prep technique for anterior dental restoration is a relatively new and minimally invasive approach that can provide quick and straightforward solutions for minor cosmetic improvements. However, it is essential to assess each case individually to determine the best course of treatment.

Authors' Contributions

A.P. wrote the original draft. L.F. reviewed and edited the manuscript. F.C. was involved in visualization. G.C. helped in project administration. All authors have read and agreed to the published version of the manuscript.

Informed Consent Statement

Informed consent was obtained from all subjects involved in the study.

Data Availability Statement

Data is available on request.

Funding

None.

Conflict of Interest

None declared.

References

- 1 Wells D. Low-risk dentistry using additive-only (“no-prep”) porcelain veneers. *Compend Contin Educ Dent* 2011;32(05):50–55
- 2 D’Arcangelo C, Vadini M, D’Amario M, Chiavaroli Z, De Angelis F. Protocol for a new concept of no-prep ultrathin ceramic veneers. *J Esthet Restor Dent* 2018;30(03):173–179
- 3 De Angelis F, D’Arcangelo C, Angelozzi R, Vadini M. Retrospective clinical evaluation of a no-prep porcelain veneer protocol. *J Prosthet Dent* 2023;129(01):40–48
- 4 Calamia JR, Calamia CS. Porcelain laminate veneers: reasons for 25 years of success. *Dent Clin North Am* 2007;51(02):399–417, ix
- 5 Friedman MJ. A 15-year review of porcelain veneer failure—a clinician’s observations. *Compend Contin Educ Dent* 1998;19(06):625–628, 630, 632 passim, quiz 638
- 6 Imburgia M, Cortellini D, Valenti M. Minimally invasive vertical preparation design for ceramic veneers: a multicenter retrospective follow-up clinical study of 265 lithium disilicate veneers. *Int J Esthet Dent* 2019;14(03):286–298
- 7 S. K. A. B. *Invisible: Esthetic Ceramic Restorations.*: Artes Medicas; 2008
- 8 Ortensi L, Vitali T, Bonfiglioli R, Grande F. New tricks in the preparation design for prosthetic ceramic laminate veneers. *Prosthesis*. 2019;1(01):29–40
- 9 Fradeani M. *Esthetic Analysis: A Systematic Approach to Prosthetic Treatment.* USA: Quintessence Publishing Company; 2004
- 10 Peumans M, De Munck J, Fieuws S, Lambrechts P, Vanherle G, Van Meerbeek B. A prospective ten-year clinical trial of porcelain veneers. *J Adhes Dent* 2004;6(01):65–76
- 11 Fiorillo L, D’Amico C, Turkina AY, Nicita F, Amoroso G, Risitano G. Endo and exoskeleton: new technologies on composite materials. *Prosthesis* 2020;2(01):1–9. Doi: 10.3390/prosthesis2010001
- 12 Magne P, Cascione D. Influence of post-etching cleaning and connecting porcelain on the microtensile bond strength of composite resin to feldspathic porcelain. *J Prosthet Dent* 2006;96(05):354–361
- 13 Buonocore MG. A simple method of increasing the adhesion of acrylic filling materials to enamel surfaces. *J Dent Res* 1955;34(06):849–853
- 14 Fiorillo L. Fi-Index: a new method to evaluate authors Hirsch-Index reliability. *Publ Res Q* 2022;38:465–474
- 15 Fiorillo L, Cicciù M. The use of Fi-Index tool to assess per-manuscript self-citations. *Publ Res Q* 2022;38:684–692
- 16 Agustín-Panadero R, Ausina-Escrihueta D, Fernández-Estevan L, Román-Rodríguez JL, Faus-López J, Solá-Ruiz MF. Dental-gingival remodeling with BOPT no-prep veneers. *J Clin Exp Dent* 2017;9(12):e1496–e1500
- 17 Freyberg BK. No-prep veneers: the myths. *Dent Today* 2011;30(06):70–71
- 18 Portelli M, Militi A, Logiudice A, Nucera R. An integrated approach, orthodontic and prosthetic, in a case of maxillary lateral incisors agenesis. *Prosthesis*. 2019;1(01):3–10
- 19 Oudkerk J, Eldafrawy M, Bekaert S, Grenade C, Vanheusden A, Mainjot A. The one-step no-prep approach for full-mouth rehabilitation of worn dentition using PICN CAD-CAM restorations: 2-yr results of a prospective clinical study. *J Dent* 2020;92:103245
- 20 Giudice GL, A A, F L, et al. The coronal tooth fractures: preliminary evaluation of a three-year follow-up of the anterior teeth direct fragment reattachment technique without additional preparation. *Open Dent J* 2017;11(01):266–275
- 21 Sykes D. Medico-legal aspect of dental implants. *Ann R Australas Coll Dent Surg* 2000;15:309–314
- 22 Magne P. Noninvasive bilaminar CAD/CAM composite resin veneers: a semi-(in)direct approach. *Int J Esthet Dent* 2017;12(02):134–154
- 23 Tallarico M, Caneva M, Baldini N, et al. Patient-centered rehabilitation of single, partial, and complete edentulism with cemented- or screw-retained fixed dental prosthesis: The First Osstem Advanced Dental Implant Research and Education Center Consensus Conference 2017. *Eur J Dent* 2018;12(04):617–626