

CONGENITAL MID-LINE DERMOID SINUS IN UPPER LIP

R. M. SABOO

SUMMARY

Two rare cases of congenital mid-line dermoid sinus of the upper lip in a family affecting the mother and her daughter are being presented.

Introduction

Dermoid cysts or sinuses of head and neck are known but are of infrequent occurrence. Involvement of upper lip is extremely rare. On reviewing the literature I could find just two cases reported by New & Erich in 1937.

Embryology

Epithelium of each maxillary process fuses with the corresponding lateral nasal process. Mesodermal continuity between the two processes is soon established and further medial extension of the maxillary mesoderm results in intermingling with the mesoderm of the frontonasal process. The medial extension of the maxillary mesoderm is considered by some embryologists (Frazer, 1931) to reach the mid-line in the lower part of the frontonasal process where it fuses with the corresponding mesoderm from the opposite side. Hence the upper lip is considered to originate chiefly from the two maxillary processes. Warbrick (1960) however, believes that the mesoderm of the central part of the upper lip is of frontonasal origin. Congenital dermoid sinus develops from inclusions of dermal cells along the line of embryonic fusion of the two medial nasal extensions of maxillary processes.

Case Report

Mrs. K., 25 yrs., was seen in the department of Plastic Surgery in July, 1984 for the complaint of a whitish cheesy discharge from the upper lip since childhood (Fig. 1). Recently she had applied indigenous medicines

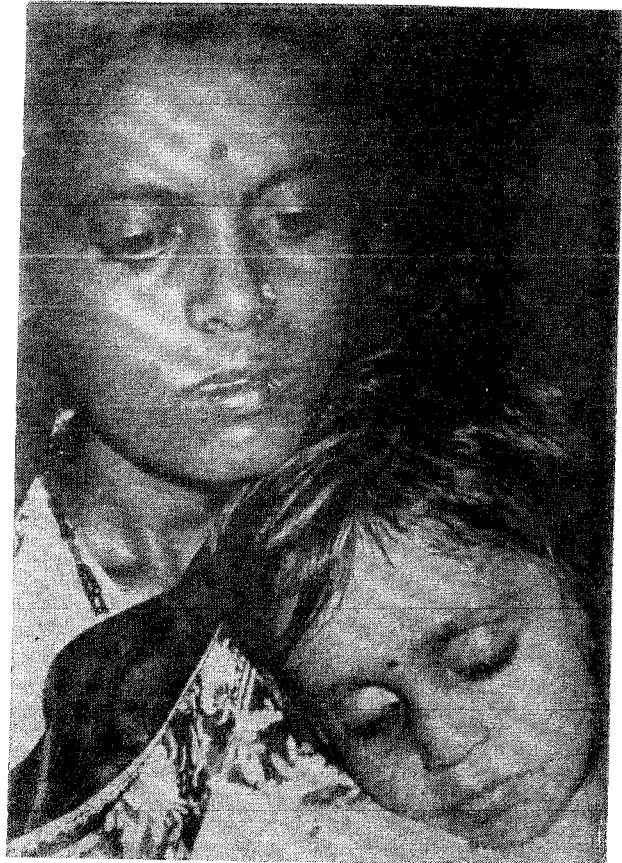


Fig. 1. Mother and her child showing dermoid sinus in the upper lip.

which caused pigmentation but with no relief in discharge. She denied history of trauma, swelling or its aggravation while eating. Her second 3-year old daughter was having similar complaints since birth. Two other siblings were normal.

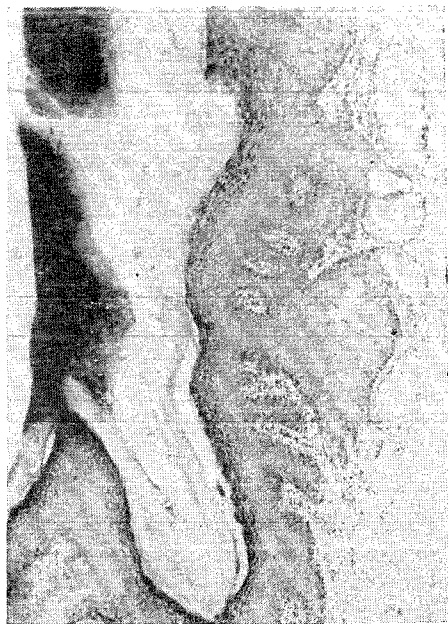

Fig. 2. Showing sinus tract lined with stratified squamous cells, sebaceous glands and sinus cavity filled with keratinized cells.

On examination there was a punctum in the mid-line of the philtrum of the upper lip overlying a small swelling. On pressing there was discharge of a thread like cheesy material from the punctum. There were no hairs coming out of it. A clinical diagnosis of dermoid sinus was made. She was operated under local anaesthesia.

On histopathological examination the diagnosis of dermoid sinus was confirmed (Fig. 2).

Subsequently, her daughter was also operated and was found to have the same lesion histopathologically.

Acknowledgement

I am thankful to the Director, St. John's Medical College Hospital, Bangalore for permitting me to use hospital records and to Prof. John A. Thomas, Professor and Head, Department of Pathology, St. J. M. C., Bangalore for histopathological studies.

REFERENCES

1. FRAZER, J. W. : A Manual of Embryology. Second Ed. London, Bailliere Tindall & Cox., 1940.
2. GORDEN, B. NEW AND JOHN B. ERICH : Dermoid cyst of the Head and Neck. Surg. Gynaecology and Obstetrics. 1937; 48 : 65.
3. WARBRICK, J. S. : The early development of the nasal cavity and upper lip in human embryo. J. Anat. 1980; 94: 351.

The Author

DR. R. M. SABOO, M.S., M.Ch., *Consulting Plastic Surgeon*, Saboo Nursing Home, Gandhibag, Nagpur.

Request for Reprints

To be addressed to the author.