

MANAGEMENT OF POST BURN CONTRACTURE USING TENSOR FASCIA LATA MYOCUTANEOUS FLAP

PRAMOD KUMAR VERMA

SUMMARY

Role of Tensor Fascia Lata myocutaneous flap in the management of a groin contracture has been evaluated. Its advantages and merits have been discussed alongwith a review of the literature.

Introduction

Post Burn contracture of the groin is not a very common condition. Symmetrical abduction to about 20° or more at the hip and maintenance of extension will prevent the adduction and flexion contracture. The patient with a groin contracture feels rather difficult to sit in the squatting position. Secondly in married woman (as in the present case) sexual life and child birth, i.e. normal delivery becomes an impossibility due to restricted abduction of the thigh.

Case Report

A lady 23 years was admitted on 8-2-1983 with complaints of inability to sit in the squatting position and to abduct her thighs fully. She had sustained burns one year back and had received a split skin graft. Initially after treatment she was alright but gradually she developed the above complaints, which was causing her great trouble due to a contracture on both sides of the pubic symphysis (Fig. 1 and 2). The surrounding thigh (both sides) was also scarred and had depigmented patches. She was operated on 18-2-84 and the contracture was released. The raw areas thus created were covered by Tensor Fascia Lata myocutaneous flaps (8×25 cms in size) on both sides (Fig. 3). The donor areas were skin grafted. Post-operative recovery was uneventful (Fig. 4).

Discussion

The raw area created after the release of a contracture is commonly covered by split skin

graft as was initially popularised by Cronin (1961). It is still a popular method because it is simple and easy to perform. Any region which has been covered by this method has to be properly splinted in the post-operative period, or else the graft will contract and scars may show hypertrophy. This can be prevented by firm pressure over the region (Fujimori et al., 1968). Skeletal suspension is an important aid in positioning (Burke Evan et al., 1970) but is cumbersome. Although Wagensteen (1934) used a Tensor Fascia Lata myofascial flap but his contribution was forgotten. Nahai et al. (1978) have recently popularised the use of Tensor Fascia Lata myocutaneous flaps.

Tensor Fascia Lata is a reliable flap which can be made as large as 15 cm×40 cm (Nahai et al., 1978). The extent to which this muscle will support the overlying skin has been reviewed by Dowden and McCraw (1981). Bostwick et al. (1979) are of the opinion that Tensor Fascia Lata flaps are extremely reliable. There has been no loss in the 15 TFL flaps used by them in the lower abdomen, groin or perineum. In their overall experience of 42 TFL flaps, they concluded that it is quite easy and safe for use. They further observed that for the region of groin instead of Gracilis myocutaneous flap, TFL flaps should be preferred. McGregor and Buchan (1980), have reported 16 TFL flaps in 13 patients. Majority of them were paraplegics. The results were good in all except in one case who had terminal necrosis. Hill et al. (1978) in their experience of 50 cases are also




Fig. 1. Pre-operative view showing the scarring of the thighs.

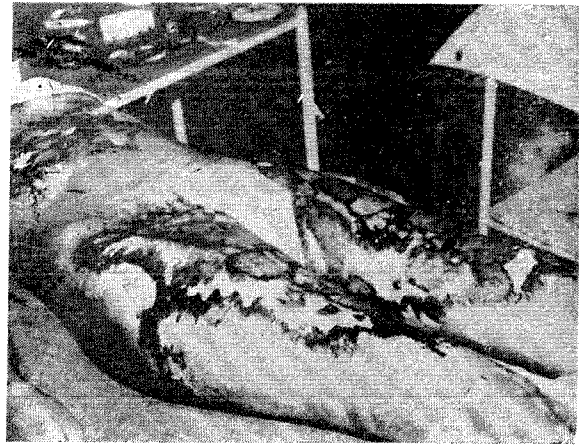


Fig. 2. Pre-operative view showing the contracture in the region of groin with limitation of abduction.

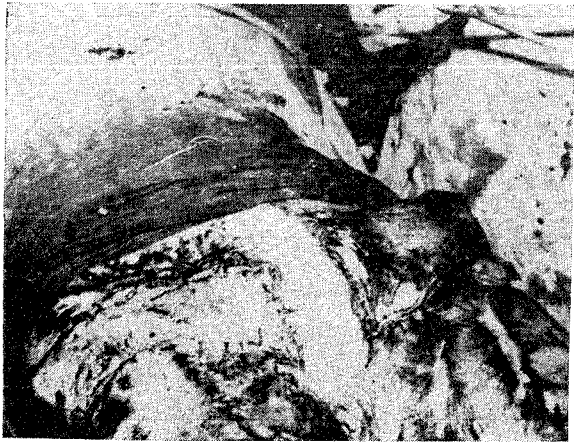

Fig. 3. Immediate post-operative view showing the flaps in position.

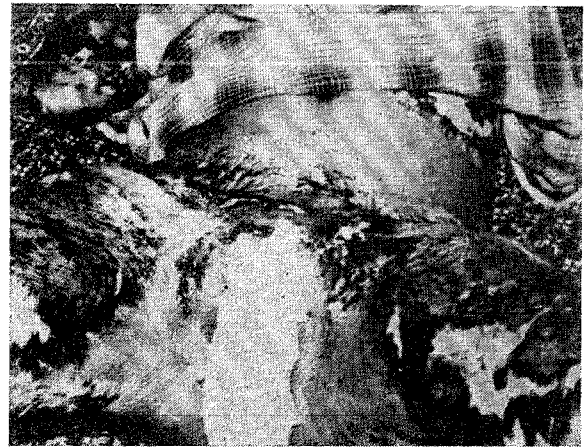

Fig. 4. Post-operative view after 3 months, showing full abduction of thighs.

of the opinion that TFL flaps with its overlying skin can be reliably raised and transposed to the nearby defects.

Conclusions

The Tensor Fascia Lata myocutaneous flap

is a reliable and dependable flap which can be used efficiently for releasing groin contractures. The result obtained in our case was very gratifying.

REFERENCES

1. BURKE EVAN, E. : Prevention and correction of deformity after severe Burns. *Surg. Cl. North America*. 1970; 50 : 1361.
2. CRONIN, T. D. : The use of molded splint to prevent contracture after split skin grafting on the neck. *Plast. Reconstr. Surg.* 1961; 27 : 7.

3. DOWDEN, R. V. AND McCRAW, J. B. : Myocutaneous flaps. Recent advances in Plastic Surgery, 1981.
4. FUJIMORI, R. : Sponge fixation method for treatment of early scars. *Plast. Reconstr. Surg.* 1968; 42 : 322.
5. HILL, H. L., NAHAI, F. AND VASCONEN, L. O. : The Tensor Fascia Lata myocutaneous free flap. *Plast. Reconstr. Surg.* 1978; 61: 517.
6. MCGREGOR, J. C. AND BUCHAN, A. C. : Our clinical experience with Tensor Fascia Lata myocutaneous flap. *Br. Jr. Plast. Surg.* 1980; 33 : 270.
7. NAHAI, F. : The Tensor Fascia Lata musculocutaneous flap. *Ann. of Plast. Surg.* 1978; 1: 372.
8. WAGENSTEEN, O. H. : Repair of recurrent and difficult hernia and other large defects of abdominal wall employing the Ilio Tibial Tract or Fascia Lata as a pedicled flap. *Surg. Gyn. Obst.* 1934; 59 : 766.

The Author

DR. PRAMOD KUMAR VERMA, *Associate Professor of Plastic Surgery*, 5, Medical Officers' Flat, Patna Medical College Hospital, Patna.

Request for Reprints

To be addressed to the author.