



# Ultrasonic Bone Scalpel versus Conventional Technique for Thoracolumbar Spinal Decompression: A Prospective Randomized Controlled Trial

## *Bisturi ósseo ultrassônico versus técnica convencional para descompressão espinhal torácica: Um teste controlado randomizado prospectivo*

Chok-anan Rittipoldech<sup>1</sup> Pawat Limsomwong<sup>1</sup> Napatpong Thamrongsuksiri<sup>2</sup>

<sup>1</sup>Department of Orthopedics, Hatyai Hospital, Songkhla, Thailand

<sup>2</sup>Department of Anatomy, Faculty of Medicine, Chulalongkorn University, Bangkok, Thailand

Address for correspondence Napatpong Thamrongsuksiri, MD, Department of Anatomy, Faculty of Medicine, Chulalongkorn University, Rama IV Rd, Khwaeng Pathum Wan, Khet Pathum Bangkok 10330, Thailand (e-mail: napatpong.tha@gmail.com).

Rev Bras Ortop 2023;58(5):e706–e711.

### Abstract

**Objective** The purpose of the present study is to compare intraoperative blood loss, operating time, laminectomy time, hospital length of stay, and complications in thoracolumbar spinal decompression using ultrasonic bone scalpels (UBSs) with conventional procedures.

**Methods** Forty-two patients who underwent decompressive laminectomy and pedicular screw fusion with a surgical level of 1–5 levels between February 1, 2020, and June 30, 2022, in a single institution were evaluated for eligibility, and 11 were excluded due to a history of spinal surgery ( $n = 3$ ), spinal tumor ( $n = 3$ ), and spinal infection ( $n = 5$ ). A total of 31 patients were randomly divided into the UBS group ( $n = 15$ ) and the conventional group ( $n = 16$ ). Intraoperative blood loss, operating time, laminectomy time, hospital length of stay, and complications were recorded.

**Results** Intraoperative blood loss and laminectomy time were significantly lower in the UBS group ( $656.0 \pm 167.6$  ml,  $54.5 \pm 27.4$  minutes, respectively) than in the conventional group ( $936.9 \pm 413.2$  ml,  $73.4 \pm 28.1$  minutes, respectively). Overall operation time, hospital length of stay, and complications were all similar between the groups.

**Conclusion** The UBS is a useful instrument for procedures performed near the dura mater or other neural tissue without excessive heat or mechanical injury. This device is

### Keywords

- ▶ decompression, surgical
- ▶ laminectomy
- ▶ randomized controlled trial
- ▶ thoracic vertebrae
- ▶ ultrasonics

*Work developed in the Department of Orthopedics, Hatyai Hospital, Songkhla, Thailand.*

received  
July 20, 2022  
accepted  
September 27, 2022

DOI <https://doi.org/10.1055/s-0043-1768627>  
ISSN 0102-3616.

© 2023. Sociedade Brasileira de Ortopedia e Traumatologia. All rights reserved.

This is an open access article published by Thieme under the terms of the Creative Commons Attribution-NonDerivative-NonCommercial-License, permitting copying and reproduction so long as the original work is given appropriate credit. Contents may not be used for commercial purposes, or adapted, remixed, transformed or built upon. (<https://creativecommons.org/licenses/by-nc-nd/4.0/>)

Thieme Revinter Publicações Ltda., Rua do Matoso 170, Rio de Janeiro, RJ, CEP 20270-135, Brazil

recommended for various spinal surgeries in addition to high-speed burrs and Kerrison rongeurs.

## Resumo

**Objetivo** O objetivo do presente estudo é comparar perda de sangue intraoperatória, tempo de operação, tempo de laminectomia, tempo de internação hospitalar e complicações na descompressão espinal torácica utilizando bisturis ósseos ultrassônicos (BOUs) em relação aos procedimentos convencionais.

**Métodos** Quarenta e dois pacientes submetidos a laminectomia descompressiva e fusão pedicular do parafuso com um nível cirúrgico de 1 a 5, entre 1° de fevereiro de 2020 e 30 de junho de 2022 em uma única instituição, foram avaliados para elegibilidade e 11 foram excluídos devido ao histórico de cirurgia espinal ( $n=3$ ), tumor espinal ( $n=3$ ) e infecção espinal ( $n=5$ ). Perda de sangue intraoperatória, tempo de operação, tempo de laminectomia, tempo de internação e complicações foram registradas.

**Resultados** A perda de sangue intraoperatória e o tempo de laminectomia foram significativamente menores no grupo BOU ( $656,0 \pm 167,6$  ml,  $54,5 \pm 27,4$  min, respectivamente) do que no grupo convencional ( $936,9 \pm 413,2$  ml,  $73,4 \pm 28,1$  min, respectivamente). O tempo de funcionamento total, o tempo de internação e as complicações foram todos semelhantes entre os grupos.

**Conclusão** O bisturi ósseo ultrassônico é um instrumento útil para procedimentos realizados próximos à dura-máter ou outro tecido neural sem calor excessivo ou lesão mecânica. Este dispositivo é recomendado para várias cirurgias de coluna vertebral, juntamente com rebarbas de alta velocidade e pinça Kerrison.

## Palavras-chave

- ▶ descompressão cirúrgica
- ▶ laminectomia
- ▶ ensaio clínico controlado aleatório
- ▶ vértebras torácicas
- ▶ ultrassom

## Introduction

Thoracolumbar spine degenerative disease is a major cause of disability worldwide. Spondylolisthesis, disc degeneration, and spinal stenosis are examples of such disorders. Thoracolumbar degenerative spine disease can lead to a reduction in the quality of life with a variety of clinical symptoms, including radiculopathy, weakness, and low back pain of varying levels of severity.<sup>1</sup> Improving surgical safety and preventing complications in spinal surgery is important given the increasing frequency of spinal surgery and the aging of patients having these operations in recent decades. Decompressive laminectomy, which has greater risks of nerve or dura injury or uncontrollable bleeding and takes a lot of time to accomplish, is one of the most important procedures in degenerative spinal surgery.<sup>2-5</sup> Therefore, a major concern in spinal decompression is how to minimize intraoperative bleeding, reduce the operating time, and improve safety.

The Kerrison rongeurs and high-speed burrs are traditional instruments that have been used for a long time in spinal decompression. It has the advantages of being available in a variety of sizes, having great cutting characteristics, and being inexpensive. However, when using high-speed burrs, the proximity of spinning parts to structures such as nerves, vessels, and dura maters along with the associated heat damage to the surrounding tissues can limit their use or result in iatrogenic injury.<sup>6,7</sup>

Ultrasonic devices, which were initially designed for dentistry, first emerged in 1952.<sup>8</sup> By the 1970s, technology had advanced to the point that meningioma and vestibular schwannoma could be effectively debulked and removed.<sup>9,10</sup> Only bone is cut while using the ultrasonic bone scalpel (UBS) since its blade is generated at a frequency of 22.5 kHz. It provides the advantages of accurate bone cutting, minimizing damage to surrounding tissue, and reducing blood loss.<sup>11</sup>

Several studies have found the ultrasonic bone scalpel to be a safe method of cutting bone,<sup>6,12,13</sup> but none of these studies has investigated the outcomes of its utilization in thoracolumbar spinal surgery. The purpose of the present study is to compare intraoperative blood loss, operating time, laminectomy time, hospital length of stay, and complications in thoracolumbar spinal decompression using UBSs with conventional procedures.

## Methods

### Study Design

This is a single-center, prospective randomized controlled, non-inferiority trial. The study was approved by the Hatyai Hospital's Institutional Review Board (IRB No.61/2564) and registered by the Thai Clinical Trials Registry (TCTR20200106003) – the approved randomized controlled trial was conducted at the Department of Orthopedics, Hatyai Hospital, Thailand. It included 31 patients that underwent thoracolumbar spinal

decompressive laminectomy and posterior instrumented fusion performed by the first author (Rittipoldech C.). He has experience of performing 20 thoracolumbar laminectomy procedures with a UBS. The inclusion criteria were a degenerative thoracolumbar spinal disease with a plan for decompressive laminectomy and pedicular screw fusion with a surgical level of 1 to 5 levels and an age range of 40 to 90 years old. The exclusion criteria were a history of spinal surgery, coagulopathy problems, end-stage renal disease, spinal tumor, spinal infection, congenital spinal stenosis, inflammatory pathology disease, or allergy to tranexamic acid.

Forty-two patients who underwent decompressive laminectomy and pedicular screw fusion with a surgical level of 1 to 5 levels between February 1, 2020, and June 30, 2022 in a single institution were evaluated for eligibility, and 11 were excluded due to a history of spinal surgery ( $n=3$ ), spinal tumor ( $n=3$ ), or spinal infection ( $n=5$ ). Blinded block randomization at the inclusion of the 31 patients allocated them to 1 of 2 groups: the UBS group ( $n=15$ ), in which a thoracolumbar spinal decompression was performed with the UBSs, and the conventional group ( $n=16$ ), in which the decompression was performed with the Kerrison rongeurs and high-speed burrs (► Fig. 1).

### Patients Evaluation and Imaging Feature

Patients in both the UBS and conventional groups experienced typical thoracolumbar spinal stenosis symptoms, including numbness and weakness in the lower limbs. Plain X-rays and magnetic resonance imaging (MRI) of the thoracolumbar and lumbosacral spine were performed on all patients. Magnetic resonance imaging revealed that both groups had a degenerative spinal disease, ligamentum fla-

vum hypertrophy, or neural compression associated with symptoms.

### Surgical Technique

In all patients, the patient was placed in the prone position after general anesthesia and antibiotic was administered. Fluoroscopy was used to assess the confirm levels. A posterior midline incision was made to expose the lamina and the transverse processes of the affected segment. Rongeurs were used to remove the dorsal spinous process, the supraspinous ligament, and the interspinous ligament.

For the UBS group, the lamina was cut longitudinally along the midline of the bilateral facet joints using an UBS (Bone-Scalpel, Misonix, NY, USA) until the full thickness of the bone structure, including the lamina and ossified ligament, was uncovered. It is critical to keep the tip of the UBS moving and not to hold it in one place for too long. It is also essential to push it farther. When the bone cut is completed, a give-way sensation is felt, and this is the finishing point. Afterwards, the cephalad and caudal lamina were separated. The lamina was grasped at one end and gently lifted with towel clamp forceps as the ossified ligaments and lamina began to loosen. Simultaneously, the adhesions were released with a nerve stripper or blade (► Fig. 2).

For the conventional group, to remove the lamina, a high-speed burr was used in conjunction with a Kerrison rongeur to create troughs on either side of laminae and then laminectomy was completed. In all cases, the pedicle screws were placed via a free-hand technique with the aid of fluoroscopy, and homeostasis was obtained using gelfoam and bipolar cautery. All patients who underwent spinal decompression in the present study were administered

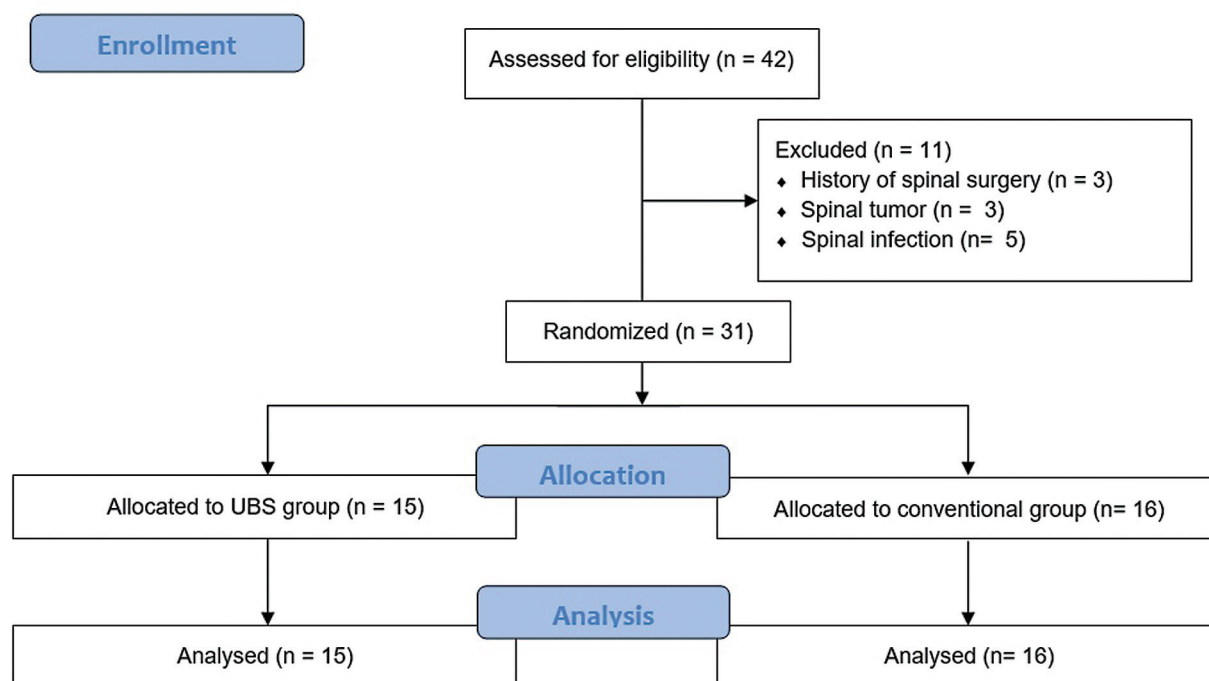
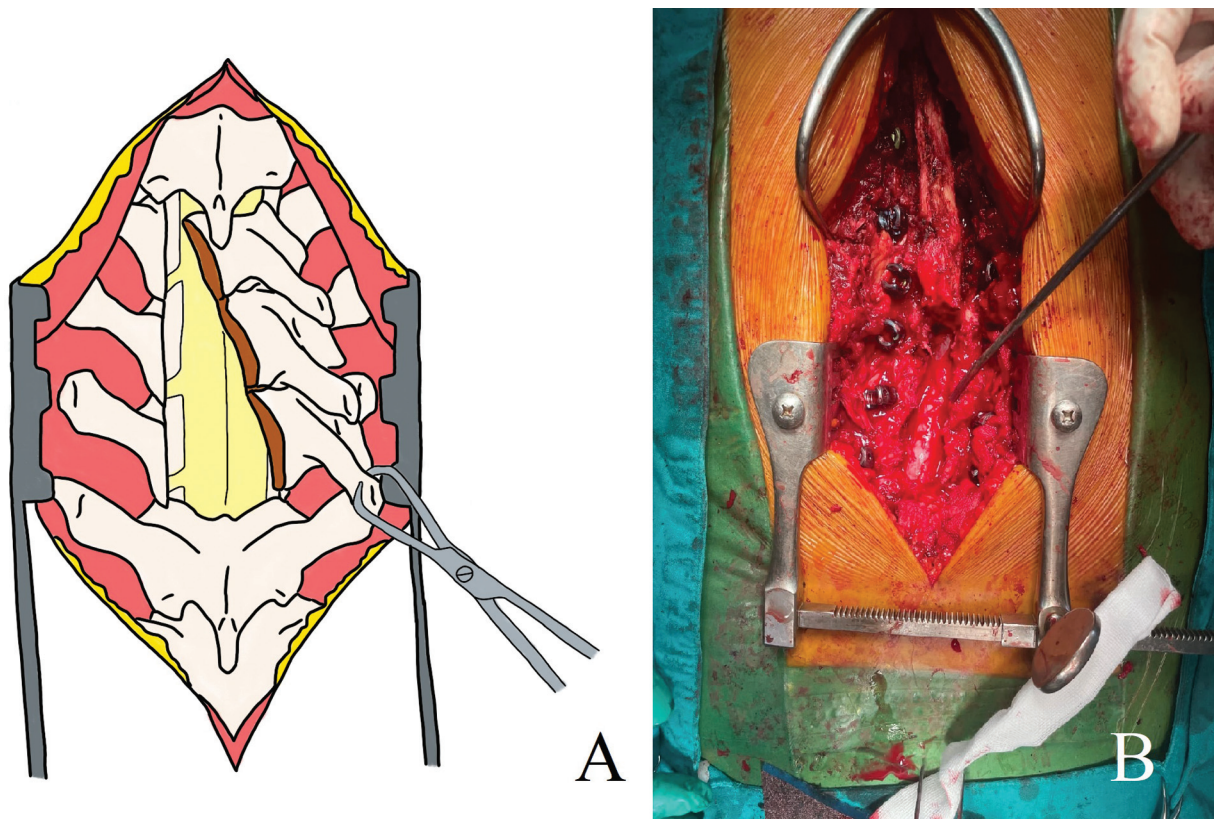


Fig. 1 Flowchart of enrollment.



**Fig. 2** (A) Illustration showing that the lamina was grasped at the spinous process and gently lifted with towel clamp forceps, and the lamina was separated. (B) Intraoperative image showing a complete decompressive laminectomy.

tranexamic acid during the operation, and records on intraoperative blood loss and time from the start of decompression surgery were recorded. Standard closure was done in layer by layer over a Radivac drain.

Intraoperative blood loss, operating time, laminectomy time, hospital length of stay, and complications were recorded in both groups.

### Statistical Analysis

Statistical analysis was performed with Jamovi 2.3.5 (Sydney, Australia) for Windows. Chi-squared tests were used to compare categorical data. Continuous data were tested for normality and compared with either Student t tests or Mann-Whitney U tests depending on normality. P-values < 0.05 were considered statistically significant. A power analysis was performed with Epitools (Ausvet, Australia) for the primary outcome measure (mean bleeding volume).<sup>14</sup> To achieve a minimum power of 0.80 with a confidence level of 0.95, a minimum sample size of 20 patients was required to detect the minimum important difference in bleeding volume. To avoid missing or incomplete data, a 30% increase in sample size was added to the total sample size of 26.

## Results

### Demographic Data

In the present study, we recruited a total of 31 patients who met the criteria with a mean age of  $57.1 \pm 8.0$  years old.

At the time of surgery, patients in the UBS (15 patients) and conventional (16 patients) groups were similar regarding age, gender, body mass index, and decompression level (► **Table 1**).

### Intraoperative Blood Loss

Intraoperative blood loss in the UBS group was found to be lower than in the conventional group. Intraoperative blood loss in the UBS and conventional group was  $656.0 \pm 167.6$  ml and  $936.9 \pm 413.2$  ml, respectively (► **Table 2**).

### Operating Time and Laminectomy Time

The UBS group had significantly less laminectomy time than the conventional group. The time required for laminectomy in the UBS and conventional groups was  $54.5 \pm 27.4$  minutes and  $73.4 \pm 28.1$  minutes, respectively. However, the overall operative time was found to be similar in both groups. The UBS and conventional groups had operative time of  $215.5 \pm 60.7$  mins and  $218.4 \pm 50.2$  minutes, respectively (► **Table 2**).

### Hospital Length of Stay and Complications

There were no significant differences in hospital length of stay and complications between the UBS and conventional groups. In the UBS group, 2 of 15 patients (13.3%) had a superficial wound infection, while there was no superficial wound infection in the conventional group. There was no evidence of a dura tear or a neurological deficit in either group. The hospital length of stay of the UBS and



**Table 1** Demographic data (age, gender, body mass index, and decompressive level)

	Total (n = 31)	UBS (n = 15)	Conventional (n = 16)	p-value
Age, years; mean ± SD	57.1 ± 8.0	51.1 ± 7.8	55.5 ± 14.3	0.711
Gender				0.376
Female; n (%)	14 (45.2)	8 (53.3)	6 (37.5)	
Male; n (%)	17 (54.8)	7 (46.7)	10 (62.5)	
BMI, kg/m <sup>2</sup> ; mean ± SD	25.5 ± 4.1	26.1 ± 3.7	24.9 ± 4.4	0.401
Decompression level; mean ± SD				0.945
Short-segment (≤ 3); n (%)	27 (87.1)	13 (86.7)	14 (87.5)	
Long-segment (> 3); n (%)	4 (12.9)	2 (13.3)	2 (12.5)	

Abbreviations: BMI, body mass index; SD, standard deviation; UBS, ultrasonic bone scalpel.

**Table 2** Results concerning intraoperative blood loss, operative time, laminectomy time, hospital length of stay, and complications between the UBS and conventional groups

	UBS (n = 15)	Conventional (n = 16)	p-value
Intra-operative blood loss, ml; mean ± SD	656.0 ± 167.6	936.9 ± 413.2	0.031
Operative time, mins; mean ± SD	215.5 ± 60.7	218.4 ± 50.2	0.883
Laminectomy time, mins; mean ± SD	54.5 ± 27.4	73.4 ± 28.1	0.019
Hospital length of stay, days; mean ± SD	8.7 ± 3.2	7.7 ± 2.7	0.367
Complications			
Superficial wound infection; n (%)	2 (13.3)	0 (0)	0.131
Neurological deficit; n (%)	0 (0)	0 (0)	
Dura tears; n (%)	0 (0)	0 (0)	

Abbreviations: SD, standard deviation; UBS, ultrasonic bone scalpel.

conventional groups was 8.7 ± 3.2 days and 7.7 ± 2.7 days, respectively (► **Table 2**).

## Discussion

The most important finding of the present randomized controlled trial is that intraoperative blood loss and laminectomy time are significantly lower in the UBS group (656.0 ± 167.6 ml, 54.5 ± 27.4 minutes) than in the conventional group (936.9 ± 413.2 ml, 73.4 ± 28.1 minutes). The study demonstrates that overall operation time, hospital length of stay, and complications are all similar.

Intraoperative blood loss is a common problem, particularly during multilevel spinal fusion surgeries. Significant blood loss requires frequent blood transfusions throughout the intraoperative and postoperative periods of multilevel and even single-level spine surgery.<sup>15</sup> The rates of mortality and morbidity are prominently increased in patients who have a blood loss > 500 mL during spinal surgery.<sup>16</sup> Several studies also suggest that longer surgical time is a substantial risk factor for perioperative and postoperative complications, such as deep vein thrombosis, pulmonary embolism, and surgical site infection.<sup>17</sup> Therefore, reducing intraoperative blood loss and shortening operative time are of

highest concern in spinal surgery. In the present study, the operative time for UBS and conventional techniques differ significantly, with UBS taking less time. Most postoperative problems associated with dura tears, such as pseudomeningocoele, headache, postoperative meningitis, and cerebral bleeding, have been reported in previous studies. According to previous studies, the UBS can selectively cut hard tissues like bone while sparing soft-tissue structures like the dura mater and nerves, making it at least as safe and effective in spinal decompression.<sup>18</sup> Both techniques used in our study had no problems related to dura tears. The rate of intraoperative unintentional durotomy was not different between these 2 techniques, according to the present study. In addition, as compared to the conventional technique for thoracolumbar spinal decompression, the UBS did not increase the risk of postoperative complications while decreasing intraoperative blood loss and minimizing laminectomy time.

## Limitations

The present study has several limitations. First, our study had a sample size of only 31 patients, which means increasing the number of patients could make a difference in complications. Second, our study did not include clinical outcomes such as

neurologic status and long-term follow-up. Therefore, further studies may increase the JOA score or Frankel grade. Third, the procedure for inserting pedicular screws and rods under fluoroscopy using the free-hand technique in each case took a varying amount of time, which may affect results in intraoperative blood loss, overall operating time, hospital length of stay, and complications. Finally, the present study has no mid- to long-term follow-up. Further studies may add the duration of follow-up period to assess possible complications and long-term clinical outcomes.

## Conclusion

Intraoperative blood loss and laminectomy time are significantly lower in the UBS group than in the conventional group. In conclusion, the UBS is a useful instrument for procedures performed near the dura mater or other neural tissue without excessive heat or mechanical injury. This device is recommended for various spinal surgeries in addition to high-speed burrs and Kerrison rongeurs.

### Financial Support

The authors declare that no funds, grants, or other support were received during the preparation of the present manuscript.

### Conflict of Interests

The authors have no conflict of interests to declare.

## References

- Ravindra VM, Senglaub SS, Rattani A, et al. Degenerative Lumbar Spine Disease: Estimating Global Incidence and Worldwide Volume. *Global Spine J* 2018;8(08):784–794
- Huang YH, Ou CY. Significant Blood Loss in Lumbar Fusion Surgery for Degenerative Spine. *World Neurosurg* 2015;84(03):780–785
- Kalff R, Ewald C, Waschke A, Gobisch L, Hopf C. Degenerative lumbar spinal stenosis in older people: current treatment options. *Dtsch Arztebl Int* 2013;110(37):613–623, quiz 624
- Pereira BJ, de Holanda CV, Ribeiro CA, et al. Spinal surgery for degenerative lumbar spine disease: Predictors of outcome. *Clin Neurol Neurosurg* 2016;140:1–5
- Takai K, Matsumoto T, Yabusaki H, Yokosuka J, Hatanaka R, Taniguchi M. Surgical complications associated with spinal decompression surgery in a Japanese cohort. *J Clin Neurosci* 2016; 26:110–115
- Al-Mahfoudh R, Qattan E, Ellenbogen JR, Wilby M, Barrett C, Pigott T. Applications of the ultrasonic bone cutter in spinal surgery—our preliminary experience. *Br J Neurosurg* 2014;28(01):56–60
- Dave BR, Krishnan A, Rai RR, Degulmadi D, Mayi S, Gudhe M. The Effectiveness and Safety of Ultrasonic Bone Scalpel Versus Conventional Method in Cervical Laminectomy: A Retrospective Study of 311 Patients. *Global Spine J* 2020;10(06): 760–766
- Velho V, Kharosekar H, Jasmit S, Valsangkar S, Palande DA. Ultrasonic osteotome: A cutting edge technology, our experience in 96 patients. *Indian Journal of Neurosurgery* 2014;03(03): 150–153
- Nakagawa H, Kim S-D, Mizuno J, Ohara Y, Ito K. Technical advantages of an ultrasonic bone curette in spinal surgery. *J Neurosurg Spine* 2005;2(04):431–435
- Nakase H, Matsuda R, Shin Y, Park YS, Sakaki T. The use of ultrasonic bone curettes in spinal surgery. *Acta Neurochir (Wien)* 2006;148(02):207–212, discussion 212–213
- Vercellotti T. Technological characteristics and clinical indications of piezoelectric bone surgery. *Minerva Stomatol* 2004;53 (05):207–214
- Bydon M, Xu R, Papademetriou K, et al. Safety of spinal decompression using an ultrasonic bone curette compared with a high-speed drill: outcomes in 337 patients. *J Neurosurg Spine* 2013;18 (06):627–633
- Wahlquist S, Nelson S, Glivar P. Effect of the Ultrasonic Bone Scalpel on Blood Loss During Pediatric Spinal Deformity Correction Surgery. *Spine Deform* 2019;7(04):582–587
- Lu XD, Zhao YB, Zhao XF, et al. Efficacy and Safety Analysis of Ultrasonic Bone Curette in the Treatment of Thoracic Spinal Stenosis. *Orthop Surg* 2019;11(06):1180–1186
- Willner D, Spennati V, Stohl S, Tosti G, Aloisio S, Bilotta F. Spine Surgery and Blood Loss: Systematic Review of Clinical Evidence. *Anesth Analg* 2016;123(05):1307–1315
- Carson JL, Poses RM, Spence RK, Bonavita G. Severity of anaemia and operative mortality and morbidity. *Lancet* 1988;1(8588):727–729
- Proietti L, Scaramuzzo L, Schiro' GR, Sessa S, Logroscino CA. Complications in lumbar spine surgery: A retrospective analysis. *Indian J Orthop* 2013;47(04):340–345
- Cappabianca P, Cavallo LM, Esposito I, Barakat M, Esposito F. Bone removal with a new ultrasonic bone curette during endoscopic endonasal approach to the sellar-suprasellar area: technical note. *Neurosurgery* 2010;66(suppl\_1)E118