Article published online: 2023-06-12

Cystic Cerebral Cavernous Malformations: Report of Five Cases and a Review of Literature

Krishna Shroff[1] Chandrashekhar Deopujari[2] Vikram Karmarkar[2] Chandan Mohanty[2]

[1] Department of Neurosurgical Oncology, Tata Memorial Centre, Parel, Mumbai, Maharashtra, India
[2] Department of Neurosurgery, Bombay Hospital Institute of Medical Sciences, Mumbai, Maharashtra, India

Address for correspondence Chandrashekhar Deopujari, MCh, Room no. 114, Bombay Hospital, Vitthaldas Thackersey Marg, New Marine Lines, Mumbai, 400020, Maharashtra, India (e-mail: d.chandrashekhar11@gmail.com).

AJNS 2023;18:272–292.

Abstract

Introduction Cerebral cavernous malformations (CCMs) account for about 5 to 13% of intracranial vascular malformations. Cystic cerebral cavernous malformations (cCCMs) are a rare morphological variant and can cause diagnostic and therapeutic dilemmas. We describe our five such cases and review the existing literature on this entity.

Methods A search of the PubMed database for cCCMs was done, and all articles in English emphasizing the reporting of cCCMs were selected. A total of 42 publications describing 52 cases of cCCMs were selected for analysis. Epidemiological data, clinical presentation, imaging features, the extent of resection, and outcome were analyzed. Radiation-induced cCCMs were excluded. We have also described five of our cases of cCCMs and reported our experience.

Results The median age at presentation was 29.5 years. Twenty-nine patients had supratentorial lesions, 21 had infratentorial lesions, and 2 had lesions in both compartments. Among our four patients, three had infratentorial lesions, whereas one had a supratentorial lesion. Multiple lesions were seen in four patients. A majority (39) had symptoms of mass effect (75%), and 34 (65.38%) had raised intracranial pressure (ICP), whereas only 11 (21.15%) had seizures. Among our four operated patients, all of them had symptoms of mass effect, and two of them also had features of raised ICP. The extent of resection was gross total in 36 (69.23%), subtotal in 2 (3.85%), and not reported in 14 (26.93%). All four of our operated patients underwent gross total resection, but two of them underwent a second surgery. Of the 48 patients in whom the surgical outcome was reported, 38 improved (73.08%). One showed a transient worsening followed by improvement, one developed a worsening of the pre-existing focal neurological deficit (FND), two developed a new FND, and 5 had no improvement in their FNDs. Death occurred in one patient. All four of our operated patients improved

Keywords
- cystic cavernomas
- cystic cerebral cavernous malformations
- cystic vascular malformations

article published online
June 12, 2023

DOI https://doi.org/10.1055/s-0043-1768577.
ISSN 2248-9614.

Thieme Medical and Scientific Publishers Pvt. Ltd., A-12, 2nd Floor, Sector 2, Noida-201301 UP, India

after surgery, although three of them showed a transient worsening of FNDs. One patient is under observation.

Conclusion cCCMs are rare morphological variants and can cause considerable diagnostic and therapeutic dilemmas. They should be considered in the differential diagnosis of any atypical cystic intracranial mass lesion. Complete excision is curative, and the outcome is generally favorable; although transient deficits may be seen.

Introduction

Cerebral cavernous malformations (CCMs) have been variously called cryptic angioma, cavernous angioma, cavernous hemangioma, cavernoma, and "angiographically occult vascular malformations."[1–3] They account for about 5 to 13% of intracranial vascular malformations and their population prevalence is 0.5%.[4–8] CCMs are the only vascular malformations known to form cysts.[9,10] The traditional classification systems (like Zabramski's) do not describe a cystic variety separately.[5] Cystic CCMs (cCCMs) are rare[4,9,11–13] and their prevalence has not been reported in literature. They can cause considerable diagnostic and management dilemmas. We describe our experience with five such cases and review the relevant literature.

Methods

Literature Review

A search of the PubMed database was done for cCCMs. Keywords used for the search were "cystic cavernomas," "cystic cavernous malformations," and "cystic cavernous angiomas." All articles in English literature where the emphasis was placed on the reporting of intracranial cCCMs (the imaging appearance showed a significant cystic component to the lesion) and their typical features were selected for analysis; and a total of 42 publications reporting 52 cases of cCCMs were identified and analyzed (►**Table 1**).[2–9,11–44] Epidemiological data, namely age, sex, and family history; clinical symptoms at presentation; imaging features; extent of surgical resection; and outcome were analyzed descriptively. Radiation-induced cCCMs were excluded.

Case Studies

Case 1: A 9-year-old boy presented to us with an intermittent, moderate-severity occipital headache. He also had an imbalance when walking for 2 months. Examination showed a conscious, cooperative patient with horizontal gaze-evoked nystagmus, a wide-based ataxic gait, and a subtle left-side lower motor neuron type of facial nerve weakness. Magnetic resonance imaging (MRI) revealed a multilobulated predominantly cystic lesion in the cerebellar vermis with evidence of intralesional hemorrhage (►**Fig. 1A**). He underwent surgery via a midline suboccipital craniotomy, and a near-total excision was achieved. Six months after his surgery, he had presented in an unconscious state that was attributed to hydrocephalus due to a bleed in the residual lesion (►**Fig. 1B**) obstructing the flow of cerebrospinal fluid (CSF) at the level of the fourth ventricle. A ventriculoperitoneal shunt procedure was done at the time at another center, following which he recovered and was sent back to us for further treatment.

He later underwent a redo midline suboccipital craniotomy in a prone position for excision of the residual lesion in the middle cerebellar peduncle through the fourth ventricle. This was excised completely along with the daughter cysts. The postoperative computed tomography (CT) scan was satisfactory in terms of lesion excision (►**Fig. 1C**). Postoperatively, truncal ataxia persisted for a few weeks after which he gradually improved. He also developed cerebellar mutism which improved over 2 months with speech therapy. At a follow-up of 6 years, he was doing well in the penultimate year of secondary school.

Case 2: A 14-year-old girl presented to us with a headache and blurring of vision in both eyes for about a week. She also gave a history of an increase in appetite and some weight gain over the previous month. Her examination was normal apart from the finding of severe optic disc edema in both eyes. MRI showed a solid-cystic lesion (►**Fig. 2A**), in the frontal horn and anterior body of the right lateral ventricle with its dilatation and transependymal seepage of CSF due to obstruction of the foramen of Monro, with a midline shift of 1.3 cm to the opposite side. The solid component (which showed only mild postcontrast enhancement) was abutting the right optic nerve and chiasm. This lesion was reported to be an ependymoma or a craniopharyngioma, for which we evaluated her hormonal status, which was normal.

A transcortical route through the right middle frontal gyrus was taken. A cyst containing xanthochromic fluid (►**Fig. 2B**) was seen at a depth of about 1.5 cm from the cortical surface. At the depth of the cystic cavity, the solid component was visualized (as a reddish-brown, mulberry-like lobulated lesion). After having drained the cyst fluid, the lesion was completely excised (including the peripheral gliotic hemosiderin-stained region). A postoperative CT scan was done the next day; it confirmed complete excision of the solid component as well as a reduction in hydrocephalus and midline shift. Histopathology confirmed the diagnosis of a CCM (►**Fig. 2C**). At 4 months of follow-up, an MRI (►**Fig. 2D**) was done that showed complete excision and some residual gliosis and products of hemoglobin degradation in the right basifrontal region, with complete resolution of hydrocephalus and midline shift.

Table 1 Operated cases of cCCMs reported in literature

Sl. no.	Author and year	Age/sex	Presentation	Location and Imaging features	Extent of resection	Surgical findings	Outcome
1	Manz, Klein et al 1979[18]	30/M	Right eye diminution of vision, intermittent and pulsatile frontal headaches which were more pronounced at recumbency and at times accompanied by nausea and vomiting	Suprasellar mass lesion	NR (blood clot and debris evacuated following which chiasm became flat)	Right frontal craniotomy—right optic nerve distorted by an intrinsic blue lobulated multicystic mass extending across the chiasm to involve the left optic nerve and right optic tract	Central vision improved in right eye, but a permanent left homonymous hemianopia developed
2	Ramina et al 1980[19]	45/F	Seizure, previously headaches, nausea and vomiting, impaired memory, visual difficulty, left arm weakness, altered behavior	Right temporo-parieto-occipital region, cystic part in parietal region with calcified walls	STR	Cyst with yellow-brown fluid and calcified solid mass. Complete cyst evacuation with subtotal removal of solid mass which was adherent to surrounding tissue	All focal deficits improved
3	Vaquero et al 1983[2]	29/F	Diffuse headache, progressive left hemiparesis	Right parietal region, with slight enhancement of walls after IV contrast	GTR	Big cyst filled with xanthochromic fluid with a 0.5 cm solid nodule	Improved
		51/M	Headache, progressive left hemiparesis	Right parietal region, partly cystic and partly solid lesion, solid portion was enhancing with contrast	GTR	Two cysts containing turbid greyish fluid	Improved
4	Khosla et al 1984[20]	3/F	Difficulty walking, repeated falls, unsteadiness of gait, bilateral papilloedema, right hemiparesis, truncal and gait ataxia, bilateral cerebellar signs, increased head circumference, positive Macewen's sign, wide open anterior fontanelle	Large irregular cystic lesion in left cerebral hemisphere (frontoparietal), no enhancement, no calcification	GTR	$\sim$ 250 mL of decomposing liquid blood drained, a network of blood vessels seen on the medial surface of the frontal lobe	Improved
5	Bellotti et al 1985[21]	54/M	Intracranial hypertension (underwent VP shunt), papilloedema, vague right-sided cerebellar syndrome,	Cystic lesion in cerebellar vermis, slightly to the right of the midline, with enhancement of the cavity wall, no intramural nodule	GTR	Cystic component containing lemon-yellow fluid and a grayish-red intramural nodule	Improved
		53/F	Generalized asthenia, raised ICP, progressive ataxia, papilloedema, severe right sided cerebellar signs,	Cystic lesion of right cerebellar hemisphere with a small intramural nodule and marked triventricular hydrocephalus	GTR	Small reddish $\sim 2 \times 3$ mm intramural nodule which lay immediately under the cortex with a clear cleavage plane	Improved

Table 1 (*Continued*)

Sl. no.	Author and year	Age/sex	Presentation	Location and Imaging features	Extent of resection	Surgical findings	Outcome
		44/F	Raised ICP, papilloedema, vague left sided cerebellar signs,	Cystic lesion of the left cerebellar hemisphere with an intramural nodule and triventricular hydrocephalus	GTR	~ 10 mL of lemon-yellow fluid containing cyst with small brownish-red intramural nodule	Raised ICP settled but vague left-sided cerebellar deficit persisted at 5 months
6	Iplikçioğlu et al 1986[22]	30/F	Headache, tendency to fall to the left, left peripheral facial palsy, total sensorineural hearing loss in left ear, hypoanesthesia in left ophthalmic and maxillary nerve distributions	Hydrocephalus, large round cystic mass with small solid component in left CPA with two small calcifications. No perifocal edema. Effaced fourth ventricle. Slight enhancement of cyst wall with contrast.	GTR	Large bluish extramedullary cystic mass, with a solid part on its anterolateral wall adherent to the brain stem & 7th and 8th cranial nerves	Improved, left peripheral facial palsy and hearing loss in left ear persisted
7	Steiger et al 1987[15]	21/M	Focal epilepsy	Left parietal hypodense area with hyperdense border, no enhancement	NR	Cyst filled with degraded blood	NR
		75/F	Progressive left hemiparesis	Right frontal heterogenous enhancing area	NR	Discolored cystic nodule	NR
		45/M	Hemiparesis, papilloedema	5.5 cm frontal cyst with peripheral enhancement, perifocal cerebral edema	NR	Thick-walled cyst and discolored nodule	NR
8	Gangemi et al 1989[23]	9 M/F	Generalized seizures, tense fontanelle, left hemiparesis	Right frontal inhomogeneous hyperdense mass with calcifications, and two large cysts in the right parietal region and left lateral ventricle, respectively. No contrast enhancement	GTR	Dark red intracerebral mass, composed of partially thrombosed vessels with cysts containing brownish fluid	Improved
		6 M/F	Progressive head enlargement and slight right arm paresis	Left frontoparietal large inhomogeneous hyperdense area, with no enhancement; containing a large deep cystic component and a small, calcified portion on its cortical surface	GTR	Cyst containing brownish fluid with solid partially calcified mass consisting of thrombosed vessels	Improved

(*Continued*)

Table 1 (*Continued*)

Sl. no.	Author and year	Age/sex	Presentation	Location and Imaging features	Extent of resection	Surgical findings	Outcome
9	Okada et al 1989[24]	4 M/F	Convulsion, low grade fever, vomiting, expanded anterior fontanelle, decreased left lower limb movements	Heterogenous high density lesion in with a large, well-demarcated, low-density area in the right frontal lobe	GTR	Dark brown fluid in the cyst with a dark red nodular tumor in the fronto-medial portion	Improved
10	Hatashita et al 1991[9]	20/F	Headache and vomiting, papilloedema	Large round isodense lesion in left frontal lobe	GTR	Cyst cavity containing ~ 50 mL degraded blood with solid nodule	Improved
11	Nakasu et al 1991[25]	8 M/ F	Tense anterior fontanelle, frequent vomiting	Large cystic lesion with small, slightly dense nodule in left parietal region which showed only minimal enhancement	GTR	Subcortical cyst containing watery-clear fluid with grayish nodule	Improved
12	Ferreira and Ferreira 1992[26]	8/M	Headache, vomiting, left visual disturbance, photophobia	CT—hyperdense suprasellar mass with greater projection to the left which did not enhance with contrast	GTR	Wine-colored encapsulated mass seen below the left optic nerve and optic chiasm, which was adherent to the lower aspect of the optic nerve	Vision remained the same postoperatively
13	Kadota et al 1994[7]	28/F	Moderate truncal ataxia and scanning speech	Large cystic tumor with irregular round mural nodule in cerebellar vermis, heterogenous enhancement with contrast	GTR	Cyst containing transparent yellow fluid	Improved
14	Sato and Kubota 1995[14]	52/F	Intermittent occipital headache,	5cm mass in right thalamic region containing a large cyst with irregular shaped dense calcification. Slight enhancement of cyst wall with contrast. MRI—T2W—high intensity lesion with surrounding brain edema and a reticulated mixed intensity core	GTR	Cyst containing xanthochromic fluid	Improved
15	Brunori and Chiappetta 1996[3]	60/M	Right facial numbness, tinnitus, hearing loss, vertigo, imbalance, right cerebellar signs	3 cm lobulated mass in the right CPA containing multiple cysts with T1W and T2W hyperintense contents. Solid component	NR	Reddish-blue mulberry like lesion adherent to the brain stem, 7th and 8th cranial nerves, with cysts containing xanthochromic fluid	Death due to massive hemorrhage

Table 1 (*Continued*)

Sl. no.	Author and year	Age/sex	Presentation	Location and Imaging features	Extent of resection	Surgical findings	Outcome
				showed marked enhancement with contrast			
16	Lai et al 1998[27]	18/F	Seizure	Slightly enhanced solid calcified portion and large cystic portion in frontal region	GTR	Cyst filled with transparent yellowish fluid, reddish brown solid mass	Improved
17	Vajramani et al 1998[28]	46/M	Tinnitus, headache, clumsiness of right upper and lower limbs, difficulty walking, slurred speech, right sensorineural hearing loss (right CPA syndrome)	CT—isodense contrast enhancing lesion in the right CPA with a cyst capping the tumor, fourth ventricle compressed and ipsilateral prepontine cistern widened	GTR	Beefy red tumor lateral to the brain stem in the CPA over the cranial nerves which could be easily dissected off. Lesion was extremely vascular—partial decompression done. Imaging showed the residual tumor and re-exploration with total removal was then done	Improved
18	Cibula et al 1998[6]	67/F	Seizures, gait apraxia, left sided neglect, "frontal lobe" personality, gaze paresis	Multiple cysts with calcification and an expanded pontine cyst	NR	Excision of right frontal lobe mass—cyst and reddish nodule with a small vascular attachment removed	NR
19	Siddiqui and Jooma 2001[29]	27/M	Headaches, episodic blurring of vision, seizures, drowsiness, papilloedema, bilateral 6th nerve palsies, exaggerated lower limb deep tendon jerks and extensor plantar responses	Large heterogenous lesion in the left temporal lobe with a solid calcified intramural part and a large cystic component ($7.5 \times 6 \times 5$cm) with perifocal edema and midline shift	NR	Pale yellow-green fluid within the cyst with no significant evidence of recent hemorrhage. Cyst wall was vascularized. Hemosiderin staining seen in the left parahippocampal gyrus after the solid vascular component was excised	Improved
20	Chicani et al 2003[30]	15/M	Headaches, nausea and vomiting, incomplete right homonymous hemianopia, later presented with seizure and loss of consciousness	Well circumscribed, round, 4×5 cm left parieto-occipital mass containing blood/blood products, which progressed in size to 7×5 cm	GTR	Multilobulated encapsulated lesion containing multiple lobules filled with blood and blood products of different ages	Visual field deficit worsened—dense right superior homonymous quadrantanopia, no new

(*Continued*)

Table 1 (*Continued*)

Sl. no.	Author and year	Age/sex	Presentation	Location and Imaging features	Extent of resection	Surgical findings	Outcome
							neurological deficit
21	Stevenson et al 2005[31]	57/M	Progressive right sided sensorineural hearing loss, tinnitus, facial numbness in region of mandibular division, gait imbalance	Large cystic lesion in the right CPA with marked brain stem compression, with slight enhancement along the walls of the cyst and patchy areas of heterogenous signal inside the cyst, moderate hydrocephalus	GTR	Multilobulated cystic mass containing xanthochromic fluid with areas of hypervascularity along the wall and intimate association with vertebral and posterior inferior cerebellar arteries	Improved, hearing was restored
22	Yagi et al 2005[32]	29/M	Impaired mental concentration	Multiple large cystic lesions, some with areas of calcification	GTR of right parietal lesion	Right parietal cyst seen filled with xanthochromic fluid with its interior wall thin, smooth and elastic. Red mural nodule seen	Improved
23	Lim et al 2006[33]	48/M	Dizziness	4.7 × 4 cm lesion T2W-round, well-defined mass with homogenous high signal intensity, in left cerebellar hemisphere, 4th ventricle effaced and displaced to the right side. No calcification/hemorrhage/perilesional edema	NR	Cystic lesion containing clear serous fluid, with a thin wall merging into surrounding gliotic brain. Cyst wall peeled off easily from the surrounding brain except at the site of the mural nodule (located in the lower part of the cyst wall)	Improved
24	Zakaria et al 2006[34]	8/M	Headache, alteration of consciousness, vomiting, left lateral rectus palsy, papilloedema, bilateral upgoing plantars	MRI—multilobulated heterogenous midline mass with both solid and cystic components, in the region of the third ventricle, with minimal enhancement. No calcification	GTR	Yellowish, mulberry tumor in the third ventricle at the junction of the foramen of Monro. Lesion showed a solid vesicular mass as well as a cystic portion containing altered blood	Improved
25	van Lindert et al 2007[35]	3/F	Vomiting, progressive deterioration in sensorium	Multicystic lesion of 6.5 × 4 × 6cm with mixed densities in the left frontotemporoparietal—paraventricular region with a surrounding hypointense rim	NR	Multiple cysts containing various liquids were partially removed, but evidence of recent hemorrhage was not seen	Improved initially, later declined in motor, speech and language development with a right spastic hemiparesis. Imaging revealed a slight growth of the lesion and patient underwent

Table 1 (*Continued*)

Sl. no.	Author and year	Age/sex	Presentation	Location and Imaging features	Extent of resection	Surgical findings	Outcome
							surgery again (two stage procedure)
26	Son et al 2008[36]	20/F	Generalized seizures	CT—7 × 5 × 5cm mixed density lesion in the left frontal and basal ganglia region showing heterogenous enhancement. MRI—multicystic mass surrounded by a low intensity hemosiderin rim on T2W images with a venous angioma abutting the medial portion of the mass on contrast MRIs	GTR	Brownish mass containing many cysts/caverns with each containing brownish liquified blood products	Improved
27	Ohba et al 2010[4]	76/F	Right facial palsy and right hemiparesis	Multiple cystic masses with high intensities and mural nodules with mixed intensities on T1W and T2W images, multiple low intensity areas and low intensity margins on T2 star-weighted images	GTR	Largest cystic lesion removed—cyst drained and reddish mural nodule completely excised	Improved
28	Srivastava et al 2010[37]	30/F	Recurrent seizure, headache, left hemiparesis	CT—Well-defined target-like lesion ("target sign") in right frontal lobe with central enhancing core and well-demarcated surrounding hypodense halo with perilesional edema. MRI—mixed intensity central core on T1W and T2W images, halo was isointense on T1W and hyperintense on T2W images with blooming on gradient echo images. Irregular enhancement of the central core and brilliant spherical enhancement of the peripheral halo	GTR	Xanthochromic fluid aspirated from the cystic lesion, the wall of which was easily separable from the surrounding gliotic brain	Improved
29	Huang et al 2011[12]	50/M	Right ear progressive hearing loss, vertigo, right sided facial numbness in	Lesion in the CPA with solid and cystic components compressing the	GTR	Red, firm, vascular, anteriorly solid lesion with cystic changes, adherent	Improved

(*Continued*)

Table 1 (*Continued*)

Sl. no.	Author and year	Age/sex	Presentation	Location and Imaging features	Extent of resection	Surgical findings	Outcome
			the region of the third (mandibular) division of trigeminal nerve, unsteady gait (ataxia)	brain stem and cerebellum. Anterior portion of the lesion was solid with cystic changes and posterior portion was cystic. Solid part (2.2 × 2.2 × 2.3 cm) enhanced with contrast		to the brain stem and cerebellar hemisphere, facial, trigeminal and acoustic nerves. Xanthochromic fluid drained from cystic part	
30	Moon et al 2011[38]	54/F	Diplopia, headache	Cystic lesion in the right CPA, and another hemorrhagic lesion in the right temporal region which may have been an asymptomatic CCM (morphology not mentioned, whether solid or cystic)	NR	Cyst wall fenestrated and yellowish cyst fluid drained, following which a yellow-colored mass was seen originating from the Dorello canal and encircling the abducent nerve	Abducent palsy did not improve (permanent palsy)
31	Otani et al 2012[39]	74/F	Left sided hearing loss, tinnitus, vertigo, cerebellar disturbances, horizontal nystagmus	CT—isohyperdense CPA lesion without visible calcifications, MRI—heterogenous muti-lobulated hemorrhagic lesion compressing the brain stem and cerebellum	NR	NR	Permanent hearing loss, preserved facial function
32	Kim et al 2013[40]	19/M	Right sided motor weakness	Cystic lesion of 7.2 × 4.6 × 6 cm with a 2cm intracystic enhancing nodule in the left frontoparietal lobe with surrounding edema and mass effect	GTR	Yellow fluid aspirated from the cyst. Nodule was freely mobile, relatively hard, with a yellow surface and low vascularity which was resected en-bloc	Improved
33	Kim et al 2015[5]	48/M	Headache, right hemiparesis	Cystic mass lesion in the left basal ganglia with perilesional edema. No calcification. No nodule or enhancement seen	GTR	Yellowish cystic fluid with no encapsulation and surrounding gliotic plane. No active bleeding or abnormal vessels in the field.	Improved
34	Knerlich-Lukoschus et al 2015[16]	11/M	Sudden onset occipital headaches, nausea and vomiting, double vision (6th nerve palsy), ataxia, left sided dysmetria	Hemorrhagic, fluid level exhibiting cystic mass centered in left cerebellar hemisphere 4 × 4.1 × 4.7 cm, with an anteromedial nodule 2.4 × 2.4 × 3.2 cm; early hydrocephalus	GTR	Potential venous structure not identifiable during resection	Improved
		5/M			GTR	Berry-like appearance	Improved

Table 1 (*Continued*)

Sl. no.	Author and year	Age/sex	Presentation	Location and Imaging features	Extent of resection	Surgical findings	Outcome
			Progressive headaches, 1 episode of syncope	Mixed density lesion with hyperintense T1W nodule and superior cystic component. T2W MRI showed reticulated lesion with mixed, predominantly low T2 intensity, surrounded by hyperintense edematous rim and associated anteromedial high T2 signal nodule			
		14/F	Progressive occipital headaches	T2W MRI showed heterogenous signal intensities of cystic and reticulated lesion components with surrounding edematous changes	STR	Berry-like appearance	Improved
		3/M	Progressive headaches and ataxia (familial CCM—history of multiple CCMs in father)	Spherical hemorrhagic lesion in the left cerebellar hemisphere showing different cystic lesion components with mixed signal intensity suggestive of hemorrhages of different ages, with mass effect and fourth ventricle effacement	GTR	Firm and calcified lesion	Improved
		2.5/M	Acute onset of severe headaches	Cystic left sided hemorrhagic cerebellar lesion with mass effect on the fourth ventricle and brain stem	GTR	Berry-like appearance	Improved
35	Abou-Al-Shaar et al 2016[8]	33/F	Headache, progressive visual loss in both eyes, visual acuity—right eye 20/25 and left eye 20/30, visual fields—left homonymous incomplete hemianopia	Large, heterogenous, hyperintense, hemorrhagic right suprasellar extra-axial complex cystic lesion with mass effect on the hypothalamus, third ventricle and optic pathway	GTR	Suprasellar intrachiasmatic large hemorrhagic cavernous malformation	Improved
36	Villaseñor-Ledezma et al 2017[17]	1.5/F		MRI—5.7 × 4.6 × 4.2 cm multicystic left cerebellar	GTR	Multilobulated lesion consisting of mulberry-like	Improved

(*Continued*)

Table 1 (*Continued*)

Sl. no.	Author and year	Age/sex	Presentation	Location and Imaging features	Extent of resection	Surgical findings	Outcome
			Progressive cervical torticollis with upper extremity clumsiness	hemisphere mass showing areas of hemorrhage and cysts with various stages of thrombus. Mass showed T2W peripheral hypointense rim on T2W imaging with perilesional edema and mass effect		structures surrounded by a xanthochromic area	
37	Yeo et al 2018[13]	13/M	Progressive gait unsteadiness, diplopia	3.0 × 2.7 × 3.3 cm hyperintense mass cyst in the floor of the fourth ventricle on T1W and T2W sequences, with mass effect. No enhancement seen	NR	Initially underwent aspiration of the cystic lesion. 2 weeks after discharge returned with headache vomiting and left sided weakness with CT showing acute hemorrhage, then underwent posterior fossa craniotomy and excision	Improved
38	Giacobbo Scavo et al 2018[41]	62/F	Severe left trigeminal neuralgia (ophthalmic and maxillary divisions), slight gait ataxia	Large cystic intracranial mass on the left side of the brain stem at the level of the entry zone of the trigeminal nerve with a small solid portion, causing brain stem compression	GTR	Posterior-medial portion of the lesion was solid (reddish, firm and vascular, continuing with a thin capsule adherent to brain stem, cerebellar hemisphere, and trigeminal nerve) and showed signs of cystic changes; the main cystic portion of the lesion contained xanthochromic fluid	Improved
39	Lu and Daniels 2019[42]	1/M	Generalized tonic–clonic seizure	Multiple vascular lesions with one large multiloculated lesion in the right frontal lobe with T2 hypointense hemosiderin rim with mass effect, sulcal effacement and midline shift	NR	NR Novel, heterozygous splice variant in KRITI1 gene (c.1730 + 5delG) found on peripheral blood testing	Improved
40	Tarabay et al 2019[43]	44/F	Mild bilateral tinnitus for 3 months, followed by vertigo, nausea and vomiting, gait instability, nystagmus to the right side	CT—Hyperdense lesion of right CPA, with associated mass effect on fourth ventricle, MRI—multilobulated lesion in the right CPA, with various signal intensities suggestive of	NR	Gray and soft lesion localized to the CPA with old hemorrhagic components and adherent to the brain stem surface, trigeminal nerve displaced superiorly	Improved

Table 1 (*Continued*)

Sl. no.	Author and year	Age/sex	Presentation	Location and Imaging features	Extent of resection	Surgical findings	Outcome
				hemorrhages of different ages. Minimal heterogenous contrast enhancement		and lower cranial nerves displaced anteroinferiorly	
41	Efe et al 2020[11]	35/M	Aphasia, vomiting, recurrent seizures, nystagmus, ataxia, left dysdiadochokinesia	Multiple cystic lesions across the brain (supra- and infratentorial, largest 5 × 3 cm in left occipital lobe, and another 2.5 × 2 cm in the cerebellum) with effacement of the fourth ventricle	GTR	Transparent yellow cyst fluid (cerebellar) evacuated, cyst wall excised and an engorged purple nodule was seen and removed, underwent 3 more surgeries later	Improved
42	Jang et al 2021[44]	42/M	Sudden onset headache, progressive right hemiparesis and hemihypoanesthesia	CT - Cystic mass with a fluid-fluid level and calcified nodule at the left thalamus with obstructive hydrocephalus with signs of raised ICP. MRI—5 × 5 × 3 cm sized lobulated cyst (compressing the third ventricle and left basal ganglia) with a fluid-fluid level, a focal peripheral calcified nodule, and subtle enhancement in the left thalamus	GTR	Cyst containing xanthochromic fluid, solid mass was calcified	Temporary aggravation of hemiparesis and hemiparesthesia noted, which recovered over 2 months following surgery
43	Present study, 2022	9/M	Occipital headache, imbalance walking, ataxic gait, subtle lower motor neuron type of facial weakness	Multilobulated predominantly cystic lesion in the cerebellar vermis	GTR	Mulberry bluish-black lesion extending upto the upper vermis, with daughter cysts	Developed a bleeding in the residual lesion and underwent surgery again. Truncal ataxia persisted for a few months after surgery, and later gradually improved. Developed cerebellar

(*Continued*)

Table 1 (*Continued*)

Sl. no.	Author and year	Age/sex	Presentation	Location and Imaging features	Extent of resection	Surgical findings	Outcome
							mutism after surgery, which gradually improved.
		14/F	Headache, blurring of vision in both eyes, papilloedema, increase in appetite and weight gain	Solid-cystic right basifrontal lesion extending into the right frontal horn with hydrocephalus	GTR	Cyst containing xanthochromic fluid, at the depth of which was a mulberry-like solid component	Improved
		61/M	Progressive right-sided weakness, slurring of speech	Cystic ventral pontine lesion	GTR	Cyst containing xanthochromic fluid drained and cyst wall excised	Transient swallowing dysfunction. Preoperative limb weakness improved. Developed re-bleeding after surgery, underwent re-exploration with evacuation of the hematoma and excision of the cyst wall remnant
		31/M	Progressive left sided numbness over the face and body, weakness of left-hand grip	Cystic lesion with a fluid level in the medulla oblongata, slightly more to the right side	GTR	Cyst fluid was xanthochromic and brownish in color	Developed ataxia, difficulty with swallowing and urinary retention, later improved

Abbreviations: CCM, cerebral cavernous malformation; CPA, cerebellopontine angle; CT, computed tomography; GTR, gross total resection; MRI, magnetic resonance imaging; NR, not reported; STR, subtotal resection; T2W, T2-weighted.

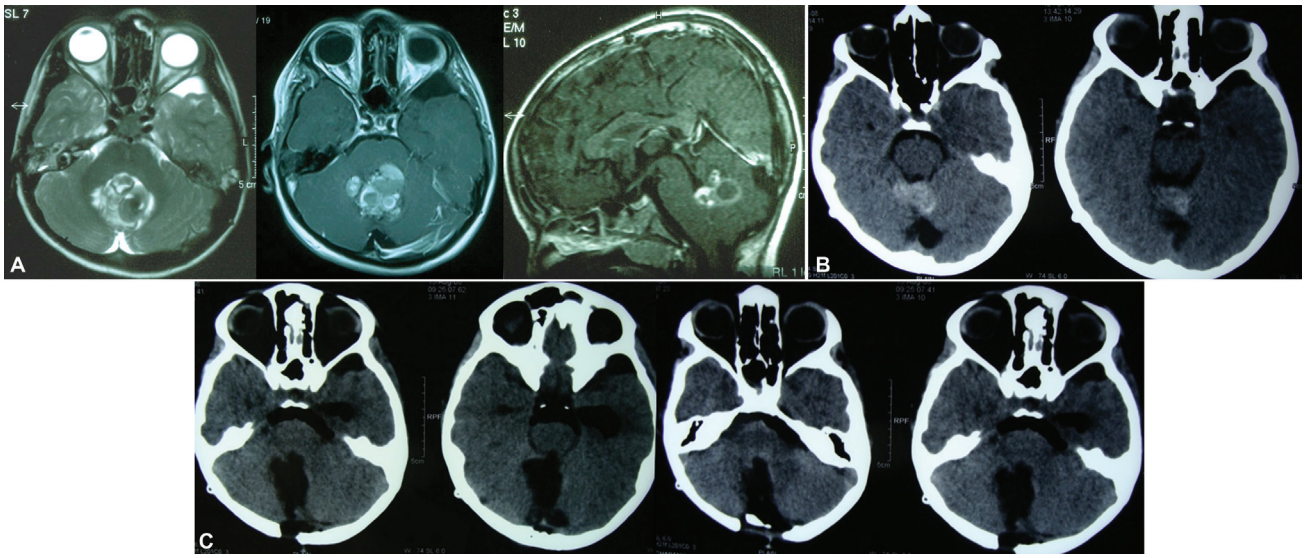

Fig. 1 (**A**) T2-weighted (*left*) and postcontrast axial (*middle*) and sagittal (*right*) images of a 9-year-old boy with a cerebellar vermian multicystic cavernoma with peduncular extension. (**B**) Six months after surgery, the boy presented in-extremis with a bleed from a small peduncular remnant at the site of the lesion. (**C**) Postoperative computed tomography scan after second surgery, showing complete excision.

Case 3: A 61-year-old gentleman with diabetes and hypertension, presented with insidious onset of right-sided (upper and lower limb) weakness for 2 months, which was more in the distal muscles and gradually progressive. He also complained of slurred speech that he noticed from the time of the onset of weakness. There were no symptoms of raised intracranial pressure such as headache/vomiting/blurred or double vision. Neurological examination of the cranial nerves was normal, and power was grade 4/5 in the right upper and lower limbs.

►**Fig. 3A** showed a T1-weighted (T1W) isointense lesion in the pons, which was hyperintense on T2W images and not suppressed on fluid-attenuated inversion recovery. Gradient echo (GRE) images showed a hypointense component to the fluid level within the cystic lesion, besides a peripheral hypointense rim. A tractography (►**Fig. 3B**) was done for surgical planning, which showed the corticospinal tracts to be displaced posterior to the lesion and on the right side.

A suboccipital craniotomy was done on the left side and using intraoperative navigation guidance (to map out the shortest trajectory to the lesion, which was not surfacing), the site for the incision on the pons was marked in the peritrigeminal safe entry zone (►**Fig. 3C**). Cyst fluid was drained, and the wall was excised and sent for histopathology examination. Layered closure was performed after having achieved hemostasis.

A CT scan was done the next day that showed no hematoma at the operative site (►**Fig. 3D**). The patient was recovering well and did not have any new postoperative neurological deficits. However, on the fifth postoperative day in the morning, he woke up with worsening right-sided hemiparesis and slurred speech. A CT scan was done, and it showed a hematoma at the site of the cyst. He was shifted to the intensive care unit for close observation of his neurological status, and after a period of observation for another 5 days, his sensorium worsened, and his Glasgow coma scale score dropped to E1V1M5. He was then intubated and started on mechanical ventilation. A CT scan was done again (►**Fig. 3E**), and it showed a slight increase in the size of the hematoma; however, there was no hydrocephalus. He was taken up for a re-exploration. A partly liquified hematoma and an organized blood clot were visualized on the left anterolateral pontine surface, and these were completely evacuated in a piecemeal fashion through the same previous entry zone. A small remnant of the cyst wall was visualized and excised. The wall of the cyst was friable. Hemostasis was achieved, the cyst cavity was irrigated with saline solution, and closure was done. A CT scan the next day (►**Fig. 3F**) showed evacuation of the hematoma. The patient was weaned off ventilatory support over the next 2 days and extubated. He developed swallowing dysfunction that gradually improved over the next 2 months with swallowing therapy, and his right-sided limb weakness improved over the next 6 months gradually with physiotherapy.

Case 4: A 31-year-old gentleman presented with complaints of subtle weakness of left-hand grip and progressive numbness on the left side of his body and face for about 1 month. About a year and a half back, he had complaints of dizziness associated with vomiting for which he was admitted to a hospital and managed conservatively. Neurological examination showed decreased sensations on the left side of his face and body (to crude touch and pinprick) and normal posterior column sensations. The remainder of the examination was normal, including the cranial nerves. MRI (►**Fig. 4A**) showed a cystic lesion with a fluid level in the medulla oblongata (slightly more to the right side) with a peripheral hypointense rim that was appreciable on T2w images.

A midline suboccipital craniotomy was done and intraoperative ultrasound was used to localize the exact location of the cavernoma. The vertical extent of the lesion was from the level of the lower cranial nerve rootlets to the level of the obex. A longitudinal incision in the right posterolateral sulcus (►**Fig. 4B**) was taken over the medulla and the cavity containing xanthochromic and brownish fluid was

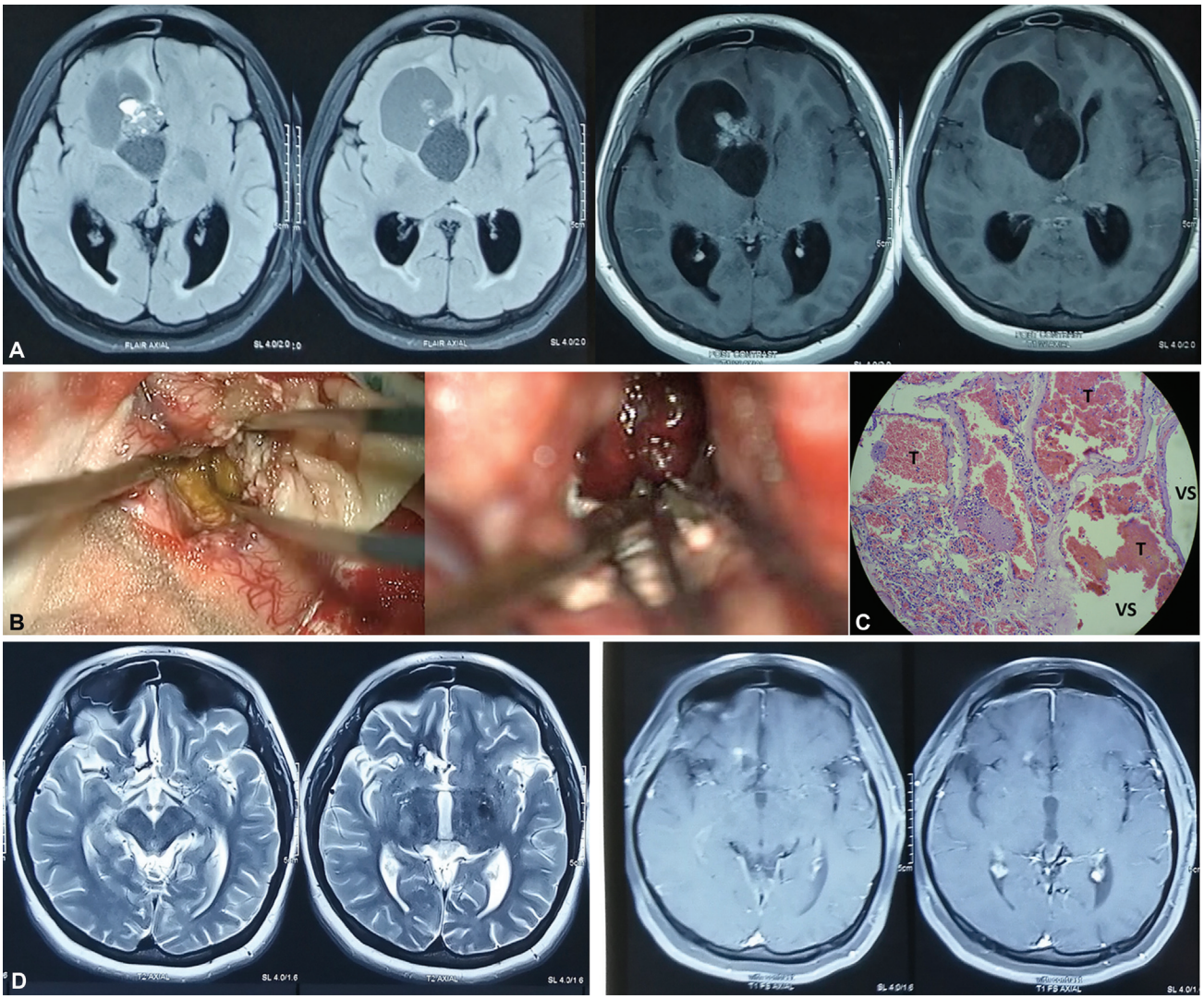

Fig. 2 (**A**) Fluid-attenuated inversion recovery (*left*) and postcontrast (*right*) axial magnetic resonance imagings (MRIs) of a 14-year-old girl with a basifrontal cerebral cavernous malformation with a large intraventricular cystic component causing midline shift, encroachment of the foramen of Monro and hydrocephalus. (**B**) Intraoperative images of the same patient showing the superficial cystic part (*left*) containing xanthochromic fluid, and the deeper mulberry solid nodule (*right*). (**C**) Histopathology showing large vascular spaces (VS) filled with newly formed thrombi (T). (**D**) Postoperative T2-weighted (*left*) and postcontrast (*right*) MRIs showing complete excision of the lesion, with residual hemoglobin degradation products in the right anteroinferior frontal region, along with complete resolution of the mass effect and hydrocephalus.

visualized. After having drained the cyst fluid, the wall was excised completely (►**Fig. 4B**) in a piecemeal fashion. The closure was done after confirmation of hemostasis.

Postoperatively, he had swallowing dysfunction (which improved over the following 5–6 months); ataxia (for which appropriate physiotherapy was begun), which also gradually improved; and urinary retention, for which the advice of a urologist was sought, and he was started on oral tamsulosin and bethanechol. After 2 months, he was given a successful catheter-free urinary trial. He has remained well ever since, and his postoperative MRI (►**Fig. 4C**) showed no residual or recurrent lesion.

Case 5: A 23-year-old man presented with generalized seizures. Examination showed no neurological deficit and MRI showed a frontal cystic cavernoma with a recent bleed (►**Fig. 5A**). He reported a similar episode 10 years ago and a similar pathology was seen on his MRI, which at that time showed a left parieto-occipital cCCM (►**Fig. 5B**). He was offered surgical excision, but the family decided against surgical intervention at the time. There was no similar family history. As the earlier lesion had resolved without intervention, he has presently decided to remain under close follow-up and opt for surgical excision if a worsening of his symptoms occurs or if the lesion shows any further growth on follow-up imaging.

Results

A total of 42 publications describing 52 cases were analyzed (►**Table 1**).

In the experience of the senior author, out of a total of 119 operated cavernoma patients from 2000 to 2021, 4 patients had predominantly cystic lesions (prevalence of 3.36%). One patient with a cCCM is under observation.

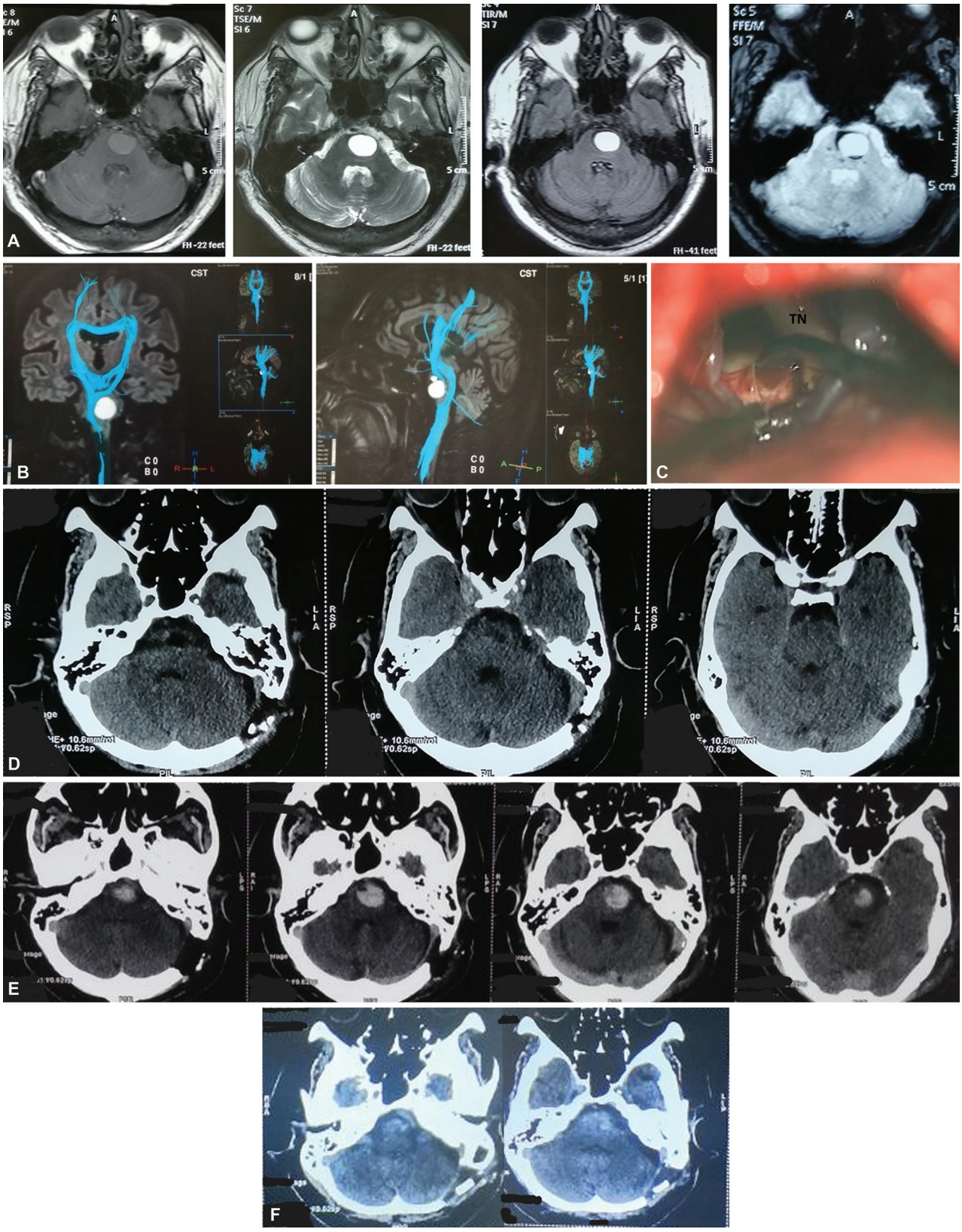

Fig. 3 (**A**) (*Left* to *right*) T1-weighted (T1W), T2W, fluid-attenuated inversion recovery and gradient echo (GRE) images of a 61-year-old gentleman with a purely cystic pontine lesion. GRE shows a fluid level within and a peripheral hypointense rim of hemosiderin suggestive of a cavernoma. (**B**) Diffusion tensor images (tractography) showing that the corticospinal tract was displaced to the right and behind the lesion. (**C**) Intraoperative photograph showing the incision in the pons in the peritrigeminal zone (near the root entry zone of the trigeminal nerve [TN]) and drainage of xanthochromic cystic fluid followed by excision of the rim. (**D**) Immediate postoperative computed tomography (CT) scan showing gross total excision. (**E**) CT scan done on the fifth postoperative day which showed a hematoma at the site of the cyst. (**F**) CT scan after second surgery for evacuation of hematoma and excision of residual capsule.

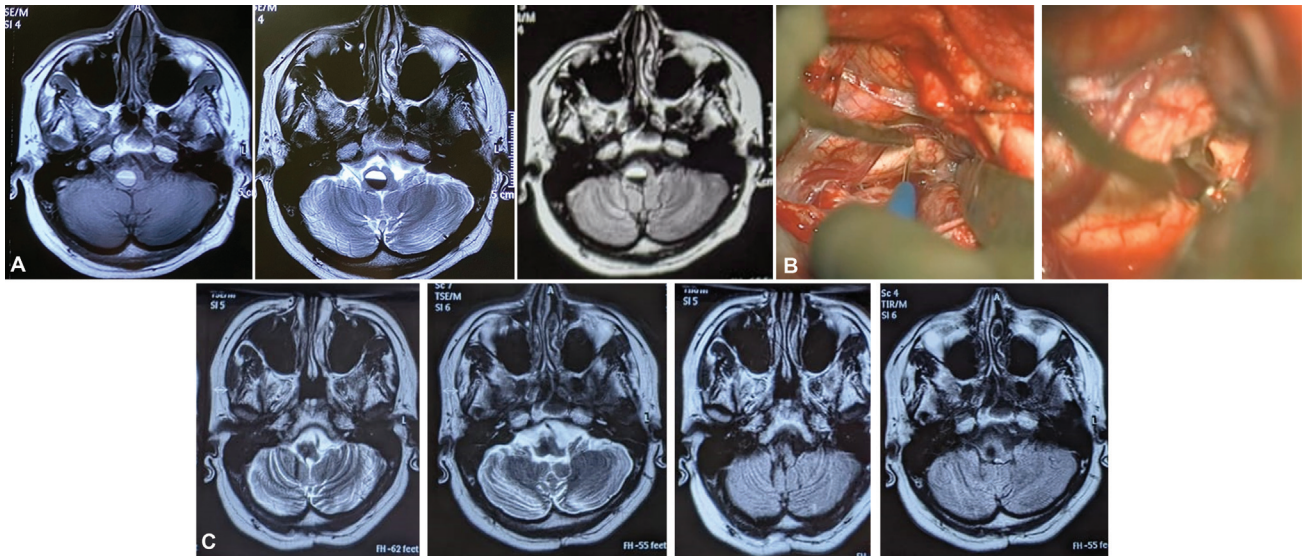

Fig. 4 (**A**) T1-weighted (T1W, *left*), T2W (*middle*) and fluid-attenuated inversion recovery (FLAIR; *right*) magnetic resonance imagings (MRIs) of a 31-year-old gentleman, showing a cystic lesion with a fluid level in the medulla oblongata. The T2W image shows a peripheral hypointense rim suggestive of a cavernous malformation. (**B**) Intraoperative images showing the incision in the medulla in the posterolateral zone (*left*) and excision of the cavernoma wall using a tumor forceps (*right*). (**C**) Postoperative T2W (*left*) and FLAIR (*right*) MRIs showing complete excision of the cystic cavernoma with gliotic changes.

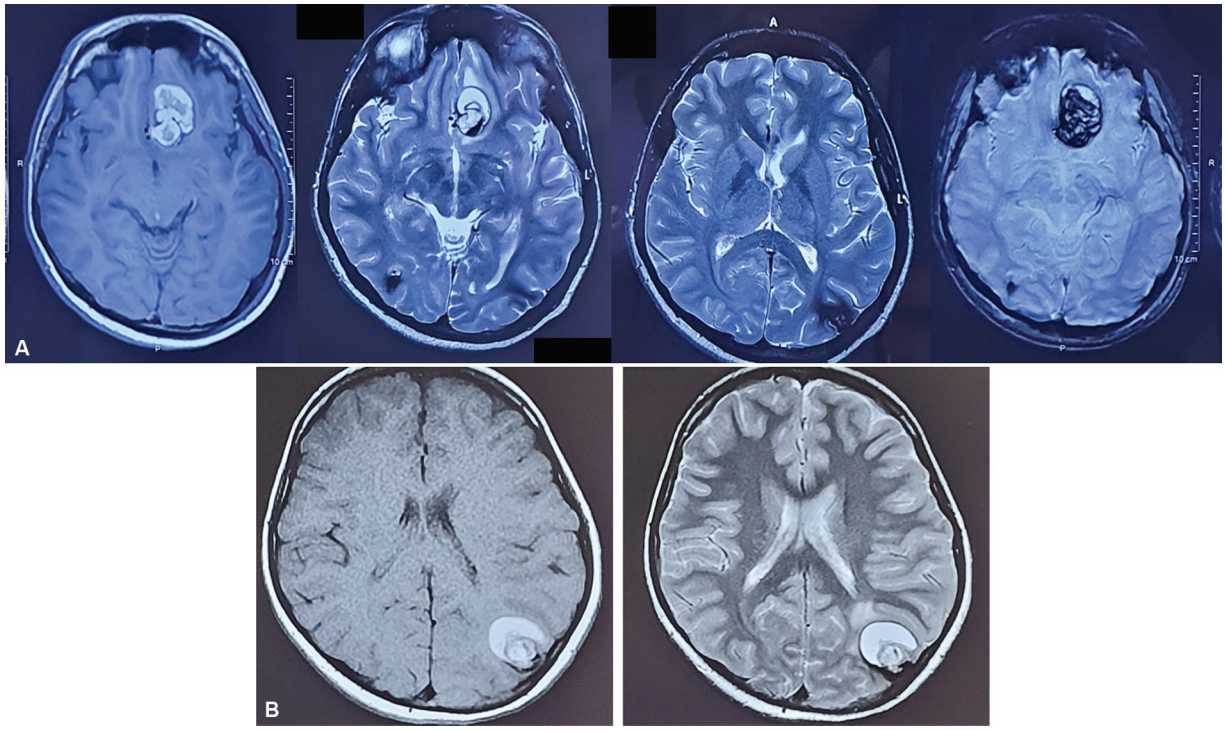

Fig. 5 (**A**) T1-weighted (T1W, *left*), T2W (*middle*) and gradient echo (GRE; *right*) magnetic resonance imagings (MRIs) of a 23-year-old man who presented to us with a left basifrontal cystic cerebral cavernous malformation (cCCM) with an internal solid component, and peripheral hemosiderin staining seen on GRE. Of note, the site of the previous left parieto-occipital cCCM is marked by hemosiderin staining. (**B**) T1W and T2W MRIs of the same patient who had a left parieto-occipital cCCM 10 years prior to presentation. The iso- to hypointense solid component with the deeper cystic component is seen with a peripheral hemosiderin ring, most marked posteriorly.

The median age of presentation of cCCMs was 29.5 years. There were 25 male patients and 27 female patients, with an almost 1:1 M:F ratio. Among our five patients, four of them were male and one was female.

Twenty-nine patients showed cCCMs in the supratentorial compartment, and 21 patients showed lesions in the infratentorial compartment. Two patients showed lesions in both compartments. Among our five patients, three had lesions in

the infratentorial compartment (of which two were intrinsic in the brain stem and one was encroaching on the middle cerebellar peduncle).

Multiple cCCMs were reported in four patients. Our last patient had multiple cCCMs, though these lesions were separated in time.

At presentation, 39/52 (75%) patients had symptoms due to the mass effect of the lesion, 34/52 (65.38%) patients had features of raised ICP at presentation, and only 11/52 (21.15%) patients had seizures. All our four operated patients had a focal neurological deficit (FND) due to the mass effect of the lesion and two of them had features of raised ICP. Our last patient presented with seizures.

Calcification (either on imaging or intraoperatively) was seen in 11/52 patients. None of our four patients showed calcification.

Gross complete excision was done in 36 (69.23%) patients, 2 (3.85%) patients underwent subtotal resection, and the extent of resection was not reported in 14 (26.93%) patients. All four of our operated patients underwent gross complete excision, but two of them underwent a second surgery.

Of the 52 patients, the outcome was not reported in four patients. Of the 48 in whom the outcome was reported, 38 (73.08%) improved after surgery, and transient worsening followed by improvement was seen in one patient. One patient developed a permanent worsening of the pre-existing FND, and two more developed new permanent FNDs. Five patients who had presented with FNDs, had no improvement in these symptoms after surgery; however, three of these patients had symptoms of raised ICP before surgery, which did improve. Death occurred in one patient. All our four operated patients improved after surgery; although three of them showed a transient worsening of their neurological deficits.

Discussion

In the experience of the senior author, out of a total of 119 CCM patients who were operated upon from 2000 to 2021, there were 4 such operated patients with cCCMs (prevalence of 3.36% in our surgical series of CCMs). The current series of 5 patients, to the best of our knowledge, is the largest series of cCCM published in literature, in addition to Knerlich et al who also publised a series of 5 patients.

In our literature review of 52 cases of cCCMs (►**Table 1**), we found that the median age at presentation was 29.5 years (mean age was 30.89 years), with the range of presentation being from 4 months to 76 years. Five of fifty-two (9.62%) patients were infants and 18/52 (34.62%) patients belonged to the pediatric age group (18 years and under). Two of our four operated patients belonged to the pediatric age group. In our review of 52 cCCMs, we found an almost 1:1 male-female ratio (25 male and 27 female patients).

Multiple CCMs have been reported to occur in about 10 to 30% of sporadic cases and up to 84% of familial cases.[36,40] To the best of our knowledge, there are only four cases of multiple de novo cCCMs reported previously in the literature.[4,6,11,32] Patient no. 5 in the current series (our last patient) had multiple cCCMs; however, these occured at a time interval of 10 years. Patient 5 in the current series is thus only the 5th case in literature with multiple de novo cCCMs. Familial CCMs are generally reported in about 20 to 50% of patients.[35,40] In our literature review of 52 patients with cCCMs, familial cases were seen in only two patients.[4,16] None of our patients had a family history of CCMs.

In our review of cCCMs, we found that 29 (55.76%) patients had lesions in the supratentorial compartment, 21 (40.38%) had lesions in the infratentorial compartment, and 2 (3.85%) had lesions in both compartments. In Ohba's review of cCCMs, it was found that 64% of patients had supratentorial lesions and 36% of patients had infratentorial lesions.[4] Among our five patients with cCCMs, three of them had lesions in the infratentorial compartment and two patients had supratentorial lesions. Hence, it is evident that for cCCMs, the lesions are disproportionately more commonly seen in the infratentorial compartment when compared with conventional CCMs.[4]

In cCCMs, we found that 39 (75%) patients had symptoms of a FND at presentation, attributable to the local mass effect caused by the lesion. Thirty-four (65.38%) patients had symptoms of raised ICP at presentation, and only 11 (21.15%) patients had seizures at presentation.

Although there is a higher incidence of cCCMs in the infratentorial compartment as compared to conventional CCMs, this disparity in the presentation cannot be attributed to lesion location alone; and it is evident that cCCMs do present more often with symptoms of a FND (due to local mass effect) or raised intracranial pressure, than with seizures; even when they occur in the supratentorial compartment. Only one of our five patients presented with seizures and four of them had symptoms of a FND that were attributable to the mass effect caused by the lesion. Two of our patients also had raised intracranial pressure.

Cyst formation in CCMs occurs due to recurrent episodes of hemorrhage from vascular sinusoids or the neocapillaries of the cyst wall, which causes changes in osmotic pressure across the membrane of the CCM (which is histologically similar to the outer membrane of a chronic subdural hematoma), which in turn leads to gradual fluid accumulation, cystic change, and subsequent growth.[4–6,10–12,14,30,40,41] Other mechanisms include ectasia of vascular channels, capillary budding, repeated hemorrhages causing obliteration of septae between adjacent sinusoids leading to their incorporation, and organization and encapsulation of a perilesional hemorrhage.[6,10,11,29] Another hypothesis states that they can show significant growth even in the absence of a prior hemorrhagic event (which may be due to an inherent proliferative mechanism in the lesion itself), which makes them mimic other neoplasms, and adds to diagnostic challenges.[29,36] Based on our limited experience, we believe it is a combination of multiple factors that leads to cyst formation.[15,45] As far as the risk of rebleeding is concerned, the cyst wall may indeed contain the malformation that most likely led to a re-bleed in patient no. 3, and a small remnant of the cyst was noted intraoperatively and subsequently excised. Interestingly, patient no. 5 in the series, not only had a spontaneous resolution of a previous cCCM but also

developed a new cCCM in a different location altogether. Thus, there may also be an unknown genetic predisposition in the development of cCCMs. All this points to a multifactorial origin of cCCMs, rather than a single mechanism.

The above mechanisms of cystic change can lead to a plethora of features on imaging. In most, a mixed intensity nodule is seen on T1W and T2W images, along with iso- to high-intensity cysts on T2W images, the periphery of which often shows a low-intensity rim. The nodules and cyst walls can show enhancement.[4] Enhancement of the cyst wall is seen due to the presence of neocapillaries and inflammatory cells in the fibrous walls.[10] However, due to their different blood supply profiles, enhancement patterns can vary significantly and can range from no enhancement at all to marked enhancement.[12] In our review of the cCCMs reported in the literature, of the lesions that showed enhancement, most of them showed it to a minimal degree. Other features can include a multistage hemorrhagic lesion with a cystic cavity and a hemosiderin rim.[5] Surrounding edema is generally not common,[4] but can occur[5,14,15,17,29,37,40] and cause confusion in diagnosis. In terms of findings of calcifications, in our review of cCCMs, we found that calcification (either on imaging or intra-operatively or both) was reported in 11/52 (21.15%) patients. None of our five patients showed any evidence of calcification.

The differential diagnoses of cCCMs include other intracranial cystic lesions, especially neoplasms such as hemangioblastoma, astrocytoma, oligodendroglioma, meningioma, and metastases.[4,5,11,21] Other non-neoplastic differentials include abscesses and parasitic cysts.[4,5,11] When they occur in locations such as the CPA, they can be confused for cystic acoustic neuromas.[12] When they occur in the region of the optic pathway, they can be confused for optic gliomas, craniopharyngiomas, thrombosed aneurysms, cystic pituitary adenomas, or even germ cell tumors.[8,18] Therefore, the possibility of a CCM should be considered in almost all intracranial cystic or solid-cystic lesions, especially where the imaging morphology does not give enough diagnostic clarity. GRE and susceptibility-weighted imaging sequences are the most sensitive for the detection of hemosiderin and can help in obtaining the right diagnosis.

There is a general agreement that the incidental finding of an asymptomatic CCM, especially in the absence of hemorrhage, is an indication for observation.[46] Because patients with cCCMs usually show some symptoms (more commonly due to local mass effect and/or raised intracranial pressure), surgical treatment is generally necessary.[4]

The appropriate timing of surgery is controversial and has been debated,[5,11] and it is commonly believed that attempting surgery in the subacute stage is fruitful as it allows time for the hematoma to liquefy and partially resolve that allows better intraoperative visualization and a better plane of dissection.[46]

Complete removal of the solid component or nodule is recommended in cCCMs; but the surgical management of the cyst wall has been debated. The cyst wall can either be completely removed, partially resected, or completely left behind after simply draining the cyst contents. This is considered to be the best course of action if the cyst wall is adherent to the surrounding brain and its complete removal is likely to induce severe morbidity.[4] However, it is also known that the cyst wall consists of neocapillaries and is lined by endothelium-derived cells, which can lead to reaccumulation of the cyst and lesion recurrence; hence, its complete removal is suggested if it is easily possible and an appropriate plane of dissection is obtained.[15,45] In our literature review of 52 patients with cCCMs, gross total excision was reported in 36 (69.23%) patients, subtotal/partial resection was reported in 2 (3.85%) patients, and the extent of resection was not reported in the remaining 14 (26.93%) patients.

In our experience of smaller-sized cCCMs in the brain stem (case 3 and case 4), we found that the collapse of the cyst cavity (which occurs after the cyst fluid has been drained) is a significant obstacle to complete excision of the cyst wall. This led to incomplete cyst wall excision in one of these patients (case 3) that led to a re-bleed and ultimately a re-exploratory surgery in which the excision of the remainder of the cyst wall was done, apart from hematoma evacuation. We also noticed a re-bleed in one more patient (case 1) which likely occurred due to incomplete excision. In our experience, a residual lesion leading to a subsequent re-hemorrhage can significantly deter an immediate good functional outcome in these benign lesions; because the cavity, especially if at depth, is difficult to inspect for any residual lesion (once collapse of the cystic cavity occurs after its contents have been drained). Our experience based on the surgical findings of patients no. 1 and 3 also supports the surgical principle of attempting safe and total excision of the solid and cystic component.

Intraoperative neuronavigation, intraoperative neuromonitoring, preoperative fiber tracking, awake craniotomy, and endoscope assistance are useful adjuncts for the safe excision of CCMs. In eloquent areas, sharp microdissection is preferred, and minimal resection of surrounding hemosiderin-stained tissue is advocated.[38] In addition, since case 3 showed good excision on CT but still a residual with bleeding was noted subsequently, it may be reasonable to get an immediate postoperative MRI instead of a CT to assess the true extent of resection.

The prognosis after surgery for cCCMs is generally favorable. In our review, out of 48 patients in whom the surgical outcome was reported, we found that 38 patients improved after surgery. One patient improved after transient worsening. Features of raised ICP improved after surgery in all those who had presented with these symptoms. Five of the patients who had presented with FNDs had no improvement in these symptoms after surgery. Two patients developed a new FND, and one patient developed a permanent worsening of the pre-existing FND. Death occurred in one patient. All our four operated patients improved after surgery, although three of them improved after an initial transient worsening.

Conclusion

cCCMs are uncommon and they should be considered in the differential diagnosis of any cystic intracranial mass lesion. They may have a multifactorial cause of origin and they

present with features of local mass effect and/or raised intracranial pressure, and less commonly with seizures. Their variable appearance on imaging leads to diagnostic dilemmas. However, the surgical principles governing their treatment include safe resection of both the solid and cystic components remain the same as for conventional CCMs; and the outcome is generally favorable even though a transient worsening may be seen.

Abbreviations

CCM – cerebral cavernous malformation
cCCM – cystic cerebral cavernous malformation
FND – focal neurological deficit
MRI – magnetic resonance imaging
CT – computed tomography
ICP – intracranial pressure
CPA – cerebellopontine angle
CSF – cerebrospinal fluid
GRE – gradient echo
SWI – susceptibility-weighted imaging

Informed Consent

Patients/parents of the patients included in the study were informed that their/their child's clinical data and imaging photographs may be used for educational purposes such as presentation in conferences/journals, and consent was obtained. No personal identifying information has been submitted in this manuscript or in ►**Figs. 1** to **5**.

Funding

None.

Conflict of Interest

None declared.

Acknowledgement

The authors would like to thank Dr. Keyuri Patel, consultant pathologist, at the Bombay Hospital for her help with selection of the appropriate histopathology image of one of our patients, for this publication.

References

1 Shroff K, Deopujari C, Karmarkar V, Mohanty C. Paediatric giant cavernomas: report of three cases with a review of the literature. Childs Nerv Syst 2021;37(12):3835–3845
2 Vaquero J, Cabezudo JM, Leunda G. Cystic cavernous haemangiomas of the brain. Acta Neurochir (Wien) 1983;67(1-2):135–138
3 Brunori A, Chiappetta F. Cystic extra-axial cavernoma of the cerebellopontine angle. Surg Neurol 1996;46(05):475–476
4 Ohba S, Shimizu K, Shibao S, Nakagawa T, Murakami H. Cystic cavernous angiomas. Neurosurg Rev 2010;33(04):395–400
5 Kim W-H, Lim D-J, Choi J-I, Ha S-K, Kim S-D, Kim S-H. Unusual presentation of cerebral cavernous malformation. J Cerebrovasc Endovasc Neurosurg 2015;17(03):257–262
6 Cibula JE, Uthman BM, Strickler ST, Quisling RG, Friedman WA, Rojiani AM. Calcified cystic lesions in a patient with epilepsy and progressive dementia. J Neuroimaging 1998;8(02):97–102
7 Kadota O, Sakaki S, Kumon Y, Ohta S, Kohno K. Large cystic cavernous angioma of the cerebellum–case report. Neurol Med Chir (Tokyo) 1994;34(11):768–772
8 Abou-Al-Shaar H, Bahatheq A, Takroni R, Al-Thubaiti I. Optic chiasmal cavernous angioma: a rare suprasellar vascular malformation. Surg Neurol Int 2016;7(19, Suppl 18):S523–S526
9 Hatashita S, Miyajima M, Koga N. Cystic cavernous angioma–case report. Neurol Med Chir (Tokyo) 1991;31(07):414–416
10 Muccio CF, Catapano G, Di Blasi A, Esposito G, Cerase A. Giant cystic intraventricular cerebral cavernous malformation: MRI with pathologic correlation. A case report. Neuroradiol J 2008; 21(04):547–550
11 Efe IE, Aydin OU, Alabulut A, Celik O, Aydin K. Multiple large-size cystic cerebral cavernomas. World Neurosurg 2020;139:410–414
12 Huang H, Xu K, Qu L, Li Y, Yu J. Cystic cavernous malformation of the cerebellopontine angle: case report and literature review. World J Surg Oncol 2011;9(01):36
13 Yeo JJY, Chang KTE, Ng LP, Seow WT, Low DCY, Low SYY. Cystic cavernoma of fourth ventricle in pediatric patient. World Neurosurg 2018;111:255–257
14 Sato K, Kubota T. Large calcified cystic cavernous angioma in the thalamus–case report. Neurol Med Chir (Tokyo) 1995;35(02): 100–103
15 Steiger HJ, Markwalder TM, Reulen HJ. Clinicopathological relations of cerebral cavernous angiomas: observations in eleven cases. Neurosurgery 1987;21(06):879–884
16 Knerlich-Lukoschus F, Steinbok P, Dunham C, Cochrane DD. Cerebellar cavernous malformation in pediatric patients: defining clinical, neuroimaging, and therapeutic characteristics. J Neurosurg Pediatr 2015;16(03):256–266
17 Villaseñor-Ledezma J, Budke M, Alvarez-Salgado J-A, Cañizares M-A, Moreno L, Villarejo F. Pediatric cerebellar giant cavernous malformation: case report and review of literature. Childs Nerv Syst 2017;33(12):2187–2191
18 Klein LH, Fermaglich J, Kattah J, Luessenhop AJ, Luessenhop AJ. Cavernous hemangioma of optic chiasm, optic nerves and right optic tract. Case report and review of literature. Virchows Arch A Pathol Anat Histol 1979;383(02):225–231
19 Ramina R, Ingunza W, Vonofakos D. Cystic cerebral cavernous angioma with dense calcification. Case report. J Neurosurg 1980; 52(02):259–262
20 Khosla VK, Banerjee AK, Mathuriya SN, Mehta S. Giant cystic cavernoma in a child. Case report. J Neurosurg 1984;60(06): 1297–1299
21 Bellotti C, Medina M, Oliveri G, Barrale S, Ettorre F. Cystic cavernous angiomas of the posterior fossa. Report of three cases. J Neurosurg 1985;63(05):797–799
22 Iplikçioğlu AC, Benli K, Bertan V, Ruacan S. Cystic cavernous hemangioma of the cerebellopontine angle: case report. Neurosurgery 1986;19(04):641–642
23 Gangemi M, Longatti P, Maiuri F, Cinalli G, Carteri A. Cerebral cavernous angiomas in the first year of life. Neurosurgery 1989; 25(03):465–468, discussion 468–469
24 Okada Y, Shima T, Matsumura S, Nishida M, Yamada T, Hatayama T. Cystic cavernous hemangioma in the frontal lobe in an infant–case report. Neurol Med Chir (Tokyo) 1989;29(01):40–43
25 Nakasu S, Yoshida M, Nakajima M, Handa J. Cystic cavernous angioma in an infant: CT features. J Comput Assist Tomogr 1991; 15(01):163–165
26 Ferreira NP, Ferreira MP. Optic nerve apoplexy caused by a cavernous angioma: case report. Neurosurgery 1992;30(02):262–264
27 Lai PH, Hsu SS, Pan HB, Yang CF. Intracranial cystic cavernous angioma: a case report. Kaohsiung J Med Sci 1998;14(09): 593–598
28 Vajramani GV, Devi BI, Hegde T, Srikanth SG, Shankar SK. Cystic cavernous malformation of the cerebellopontine angle. Clin Neurol Neurosurg 1998;100(02):133–137
29 Siddiqui AA, Jooma R. Neoplastic growth of cerebral cavernous malformation presenting with impending cerebral herniation: a case report and review of the literature on de novo growth of cavernomas. Surg Neurol 2001;56(01):42–45

30 Chicani CF, Miller NR, Tamargo RJ. Giant cavernous malformation of the occipital lobe. J Neuroophthalmol 2003;23(02):151–153
31 Stevenson CB, Johnson MD, Thompson RC. Cystic cavernous malformation of the cerebellopontine angle. Case illustration. J Neurosurg 2005;103(05):931
32 Yagi K, Kageji T, Nagahiro S, Murayama Y. Multiple cystic cavernous angiomas associated with hemorrhage. Acta Neurochir (Wien) 2005;147(02):201–203, discussion 203
33 Lim S-C, Hong R, Kim Y-S, Jang S-J. Large cystic cavernous angioma of the cerebellum mimicking pilocytic astrocytoma. J Neurooncol 2006;79(02):169–170
34 Zakaria MA, Abdullah JM, George JP, Mutum SS, Lee NN. Third ventricular cavernous angioma. Med J Malaysia 2006;61(02): 229–232
35 van Lindert EJ, Tan TC, Grotenhuis JA, Wesseling P. Giant cavernous hemangiomas: report of three cases. Neurosurg Rev 2007;30 (01):83–92, discussion 92
36 Son DW, Lee SW, Choi CH. Giant cavernous malformation : a case report and review of the literature. J Korean Neurosurg Soc 2008; 43(04):198–200
37 Srivastava C, Singh SK, Ojha BK, Chandra A, Srivastava S. Large cystic target lesion: an unusual presentation of cavernoma. Neurol India 2010;58(05):813–814
38 Moon KS, Jung S, Lee KH, Lee MC. Cavernous hemangioma of the abducens nerve: clinical implication of duplicated variants: case report. Neurosurgery 2011;69(03):E756–E760, discussion E760
39 Otani N, Wada K, Sakakibara F, Takeuchi S, Nagatani K. A cystic haemorrhagic lesion located in the cerebellopontine angle cistern. Cavernous angioma. J Clin Neurosci 2012;19(11):1551, 1608
40 Kim I-C, Kwon K-Y, Rhee J-J, Lee J-W, Hur J-W, Lee H-K. Giant cystic cerebral cavernous malformation with multiple calcification - case report. J Cerebrovasc Endovasc Neurosurg 2013;15(03):255–259
41 Giacobbo Scavo C, Roperto R, Cacciotti G, Mastronardi L. Cystic progression of a cavernous malformation at the level of the trigeminal root entry zone presenting with sudden onset of trigeminal neuralgia. J Craniofac Surg 2018;29(08):e728–e730
42 Lu VM, Daniels DJ. Large cystic cavernous malformation in infant with novel KRIT1 gene abnormality. World Neurosurg 2019; 130:304–305
43 Tarabay A, Rocca A, Maeder P, Simonin A, Messerer M, Daniel RT. Extra-axial cavernoma of the cerebellopontine angle: a case study and review of literature. World Neurosurg 2019;128:415–421
44 Jang TG, Cha SH, Cho WH. Contralateral interhemispheric transcallosal approach for thalamic cystic cavernous malformation. Brain Tumor Res Treat 2021;9(02):87–92
45 Wang C, Yu B, Zhang F, Zheng K, Feng Y. Pathological changes in surgically resected cystic cerebral cavernous malformation 13 years after radiosurgery: case report and review of the literature. World Neurosurg 2020;143:392–397
46 Deopujari CE, Jacob T, Karmarkar V. Surgical approaches to deep seated cavernous malformations. J Neurosurg Imaging Techniques 2016;1(02):52–65

