



# Minimal-Invasive Mitral Valve Repair after Breast Augmentation

Thibault Schaeffer<sup>1</sup> Luca Koechlin<sup>1</sup> Elisabeth Artemis Kappos<sup>2,3</sup> Friedrich Stefan Eckstein<sup>1</sup>

<sup>1</sup>Department of Cardiac Surgery, University Hospital Basel, Basel, Switzerland

<sup>2</sup>Department of Plastic, Reconstructive, Aesthetic and Handsurgery, University Hospital Basel, Basel, Switzerland

<sup>3</sup>University of Basel, Basel, Switzerland

**Address for correspondence** Thibault Schaeffer, MD, Department of Cardiac Surgery, University Hospital Basel, Basel, BS, Switzerland (e-mail: thibaultsch@hotmail.com).

Thorac Cardiovasc Surg Rep 2023;12:e24–e27.

## Abstract

### Keywords

- ▶ minimally invasive surgery
- ▶ cardiovascular surgery
- ▶ mitral valve surgery

Minimal-invasive mitral valve surgery after breast augmentation is an ongoing interdisciplinary challenge. Notably, the perioperative explantation of the breast implant, as reported in most cases, is of questionable benefit. We herein report on successful minimal-invasive mitral valve repair after subpectoral breast augmentation with perioperative preservation of the breast implant in situ.

## Introduction

First described in the late 1990s, minimal-invasive mitral valve surgery (MIMVS) has gained in popularity to become the preferred approach for isolated mitral valve procedures in numerous centers in recent years.<sup>1</sup> Performed via right anterior mini-thoracotomy, MIMVS has been associated with fewer wound infections, less blood transfusions, and faster recovery time compared with the conventional sternotomy approach.<sup>2–4</sup>

Breast augmentation is the most common cosmetic surgical procedure worldwide.<sup>5</sup> While the number of procedures remains stable, patients with breast implants requiring mitral valve surgery may become increasingly common as the population ages. Breast implants represent a technical challenge for right anterior mini-thoracotomy and have been considered a relative contraindication for MIMVS.<sup>6</sup> However, the literature is scarce describing this particular clinical scenario.

We herein report on successful minimal-invasive mitral valve repair in a patient with subpectoral breast implants.

## Case Description

A 55-year-old female patient presented with severe mitral regurgitation (MR) due to flail leaflet of the P2 scallop. Mitral valve repair was indicated based on progressive left ventricular dilation, left atrial enlargement, and elevated invasive pulmonary pressures. Medical history was relevant for bilateral subpectoral breast augmentation (Polytech Silimed GmbH, Dieburg, Germany) 20 years earlier. A preoperative consultation with a plastic surgeon assessed the satisfying cosmetic results, with no indication for implant removal or exchange. Objectively grade III capsular contracture and asymmetry were noted and discussed with the patient.

After endotracheal intubation with a double-lumen tube, the patient was placed in a supine position with 30-degree elevation of the right hemithorax. Via 2.5 cm incision in the left groin, the femoral vessels were cannulated using the Seldinger technique and echocardiographic guidance for establishment of cardiopulmonary bypass. Simultaneously, the right hemithorax was opened via a 5-cm incision along the original inframammary scar (–Fig. 1). While entering the thorax,

received

April 20, 2022

accepted after revision

January 28, 2023

DOI <https://doi.org/>

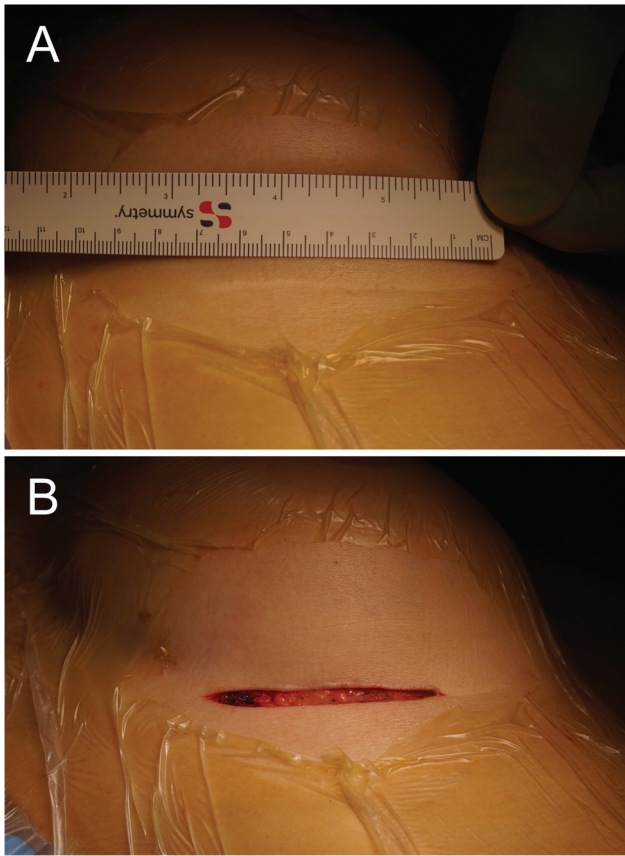
10.1055/s-0043-1767696.

ISSN 2194-7635.

© 2023. The Author(s).

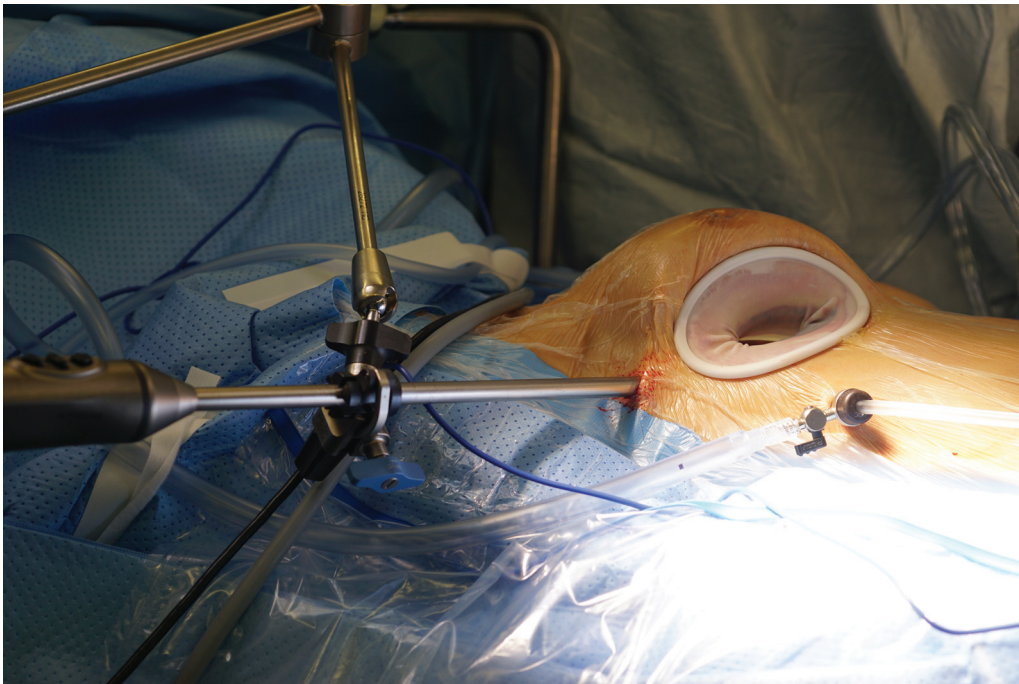
This is an open access article published by Thieme under the terms of the Creative Commons Attribution-NonDerivative-NonCommercial-License, permitting copying and reproduction so long as the original work is given appropriate credit. Contents may not be used for commercial purposes, or adapted, remixed, transformed or built upon. (<https://creativecommons.org/licenses/by-nc-nd/4.0/>)

Georg Thieme Verlag KG, Rüdigerstraße 14, 70469 Stuttgart, Germany



**Fig. 1** Inframammary scar from the breast augmentation (A) before and (B) after surgical incision.

the periprosthetic capsule of the breast implant was accidentally opened with no damage to the implant itself. A soft tissue retractor was placed in the fourth intercostal space and CO<sub>2</sub> was insufflated in the right hemithorax continuously (► **Fig. 2**).



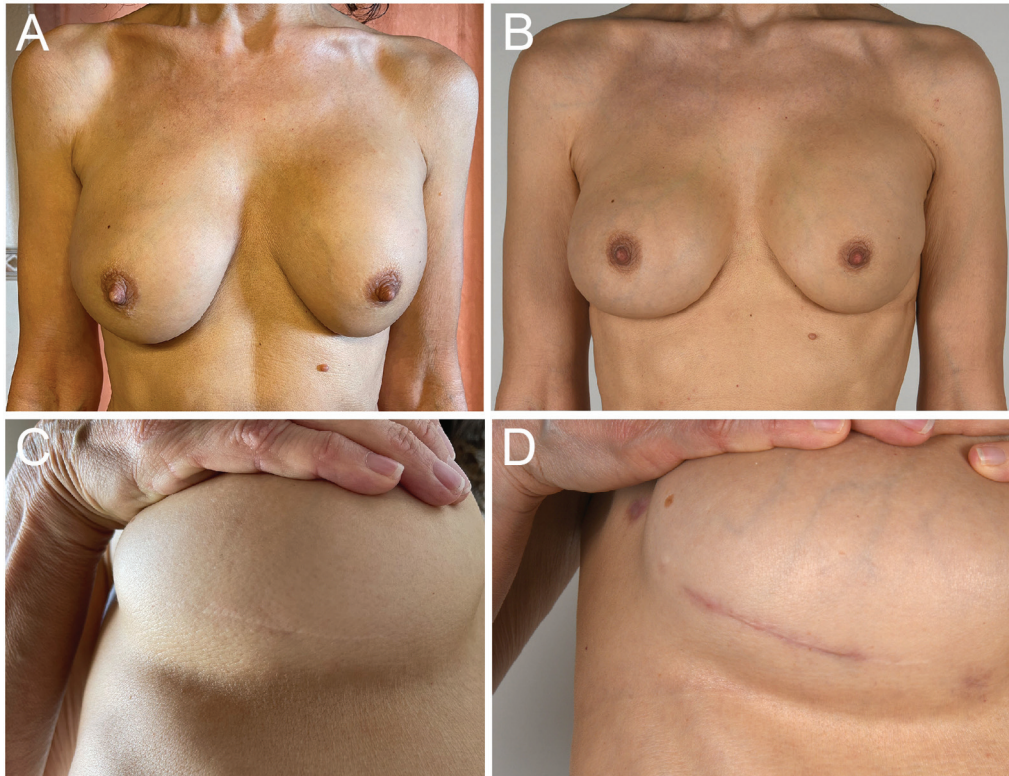
**Fig. 2** Operative setting after placement of the soft retractor, trocar, and camera.

After aortic cross-clamping, cardiac arrest was achieved with crystalloid cardioplegia (St. Thomas). The left atrial retractor was placed through a right parasternal, transthoracic puncture distant from the breast implant. The mitral valve was exposed via left atriotomy. The P2 ruptured chordae tendineae were identified and replaced with two 14-mm Gore-Tex loops from the free edge of P2 to the posteromedial papillary muscle. The repair was completed with a 38-mm ring annuloplasty (Physio II 5200, Edwards Lifesciences, Irvine, California, United States). The left atrium was closed, ventricle and atrium were de-aired, and the aorta declamped after 92-minute cross-clamp time. Transesophageal echocardiography assessed the valve repair with trivial residual MR. After pericardium closure, chest tubes were placed, and the 4th and 5th ribs stabilized with two interrupted nonabsorbable sutures. The breast implant was irrigated with povidone-iodine solution and the periprosthetic capsule carefully reattached to the fourth rib using a running absorbable suture. The inframammary incision was closed with absorbable sutures. Simultaneously, cannulas were removed as the cardiopulmonary bypass was weaned, the femoral artery was reconstructed, and the groin closed with absorbable sutures.

The postoperative course was uneventful. Echocardiography before discharge showed a mild residual MR. After 2 months, clinical examination revealed no local complications and satisfying cosmetics, without significant change when compared with preoperatively (► **Fig. 3**). The patient herself was very satisfied with the functional, as well as the aesthetic outcome.

## Discussion

This case illustrates the feasibility of MIMVS after breast augmentation through a right inframammary incision with perioperative preservation of the breast implant in situ.



**Fig. 3** (A, C) Preoperative and (B, D) postoperative photographs of the patient's breast with close-up on the right inframammary incision.

Evidence-based recommendations for management of patients with history of breast augmentation undergoing MIMVS are lacking. Serious complications such as breast implant rupture have been reported after minimal-invasive closure of atrium septum defect using right anterior thoracotomy.<sup>7</sup>

In most reported cases, the right breast implant was explanted and reimplanted during MIMVS, as it was considered an obstacle to access the thorax.<sup>8-11</sup> Thus, some authors advocated the perioperative explantation and extracorporeal preservation of the implant for MIMVS as standard.<sup>12</sup> However, intraoperative manipulation of the implant has been associated with several complications such as implant leakage, breast deformity, and secondary implant migration.<sup>9,13,14</sup>

Pervaiz et al reported a successful MIMVS after breast augmentation without explanting the prosthesis.<sup>11</sup> Also, Je et al reported a successful minimal-invasive combined atrium septum defect closure and tricuspid valve reconstruction with capsule preservation of a breast implant.<sup>15</sup> The last authors considered this approach only suitable after breast augmentation through a circumareolar incision.

We opted for the same right inframammary incision as originally used for the breast augmentation, and left the breast implant in situ. Exposition was excellent using a soft tissue retractor and the breast implant did at no time compromise the procedure. Importantly, apart from the inframammary incision, to which we prefer the circumareolar incision for nonoperated breasts, nothing was changed from the routine technique to access the thorax in this case. An accidental

breach in the periprosthetic capsule could be repaired at the end of the procedure without further complication. To avoid capsule injury, careful and blunt dissection of the thoracic wall, as well as gentle introduction and retrieval of the soft tissue retractor are warranted. The use of a mechanical retractor within the intercostal space should be avoided. If opened, careful irrigation of the surgical field should be performed and the capsule closed with running suture. If the risk of thoracic hernia is deemed high, mesh reinforcement of the thoracic wall or conversion from subpectoral to subglandular position have been suggested to prevent secondary implant migration.<sup>14</sup> The expertise of a plastic surgeon before planning MIMVS in patients with breast augmentation is warranted. Plastic surgery expertise is required to detect defects that would anticipate the replacement of a breast implant, and is necessary in case of intraoperative damage of the implant. Finally, the degree of capsular contracture, which might hamper the cephalad mobilization of the breast during the thoracotomy and reduce the exposure, is better assessed by a specialist.

Primarily intended nowadays for early-life repair of congenital heart defect, right vertical infra-axillary mini-thoracotomy has also been reported for mitral valve repair in small adult cohorts with excellent clinical and cosmetic results.<sup>16</sup> To the best of our knowledge, right vertical infra-axillary mini-thoracotomy has not been described to address the present clinical scenario but could be envisaged as an alternative approach for MIMVS in case of very adherent or oversized breast implants that would preclude anterior mini-thoracotomy.

In the current state of knowledge, the best surgical strategy has not yet been defined to offer patients with breast implants a minimally invasive approach maintaining an optimal level of intraoperative safety and satisfactory cosmetic results. The role of the implant size, surface, filling, incision site, and anatomical placement remains to be defined.

## Conclusion

Both minimal invasive surgery and breast augmentation are increasingly common. The management of breast implants during MIMVS is technically challenging and several surgical approaches have been reported with various outcomes. We advocate the perioperative preservation of the breast implant in situ to minimize the risk of damage and secondary migration of the prosthesis. The involvement of a plastic surgeon in the preoperative work-up is warranted.

### Authors' Contributions

T.S. wrote the manuscript. L.K. and E.A.K. reviewed the manuscript. F.E. performed the surgical procedure and reviewed the manuscript. All authors read and approved the final manuscript.

### Ethical Approval

Written informed consent for publication was obtained from the patient.

### Funding

The authors received no financial support for the publication of this report.

### Conflict of Interest

The authors report no conflict of interest.

### Acknowledgments

We acknowledge, Prof. Dr. med Lars Englberger who kindly reviewed this manuscript.

## References

- 1 Beckmann A, Meyer R, Lewandowski J, Markewitz A, Gummert J. German Heart Surgery Report 2020: the annual updated registry of the German Society for Thoracic and Cardiovascular Surgery. *Thorac Cardiovasc Surg* 2021;69(04):294–307
- 2 Cao C, Gupta S, Chandrakumar D, et al. A meta-analysis of minimally invasive versus conventional mitral valve repair for patients with degenerative mitral disease. *Ann Cardiothorac Surg* 2013;2(06):693–703
- 3 Moscarelli M, Fattouch K, Casula R, Speziale G, Lancellotti P, Athanasiou T. What is the role of minimally invasive mitral valve surgery in high-risk patients? A meta-analysis of observational studies. *Ann Thorac Surg* 2016;101(03):981–989
- 4 Al Otaibi A, Gupta S, Belley-Cote EP, et al. Mini-thoracotomy vs. conventional sternotomy mitral valve surgery: a systematic review and meta-analysis. *J Cardiovasc Surg (Torino)* 2017;58(03):489–496
- 5 International Society of aesthetic Plastic Surgery. *Aesthetic/Cosmetic Procedures Global Survey*. 2020:1–60
- 6 Dagenais F. Minimally invasive mitral valve surgery: evolution, techniques and outcomes. *Future Cardiol* 2008;4(06):609–616
- 7 Cremer JT, Böning A, Anssar MB, et al. Different approaches for minimally invasive closure of atrial septal defects. *Ann Thorac Surg* 1999;67(06):1648–1652
- 8 Shafiq AE, Su JW, Hendrickson M, Mihaljevic T, Gillinov AM. Right inframammary mini-thoracotomy approach to the mitral valve in women with breast implants. *Innovations (Phila)* 2009;4(05):278–281
- 9 Baker RY, Nguyen TJ, Hernandez AM, Wong AK, Baker CJ, Starnes VA. Breast implants and minimally invasive cardiac surgery: a case series. *Ann Plast Surg* 2012;69(01):10–13
- 10 Cetinkaya A, Borsche A, Hein S, Bramlage P, Schoenburg M, Richter M. Explantation and reimplantation of a breast implant to facilitate minimally invasive mitral valve surgery and cryoablation of atrial fibrillation. *Clin Case Rep* 2019;7(06):1181–1184
- 11 Pervaiz H, Rehman A, Khalid S, Cheema FH. Management for breast implants in patients undergoing mitral valve surgery through a right minithoracotomy. *J Card Surg* 2014;29(03):323–324
- 12 Marin Cuartas M, Javadikasgari H, Pfannmueller B, et al. Mitral valve repair: robotic and other minimally invasive approaches. *Prog Cardiovasc Dis* 2017;60(03):394–404
- 13 Fong TC, Hoffmann B. Images in clinical medicine. Disappearance of a breast prosthesis during Pilates. *N Engl J Med* 2011;365(24):2305–2305
- 14 Songcharoen SJ, McClure M, Aru RG, Songcharoen S. Intrathoracic migration of a breast implant after minimally invasive cardiac surgery. *Ann Plast Surg* 2015;74(03):274–276
- 15 Je HG, Kang PJ, Lee SK. Minimally invasive cardiac surgical procedure in a patient with breast implants by use of a fibrous capsule preservation method. *Ann Thorac Surg* 2014;97(05):e143–e144
- 16 Wu Z, Pan J, Wang Q, Zhou Q, Wang D. Surgical repair of mitral valve prolapse through a minimal right vertical infraaxillary thoracotomy. *J Card Surg* 2012;27(05):533–537