Article published online: 2023-06-14

High-Flow Nasal Oxygen Therapy for Management of Postoperative Pneumocephalus

Fahmeena Begum[1] Srilata Moningi[1] T. Narasimha Murthy[1]

[1] Department of Anaesthesiology and Intensive Care, Nizam's Institute of Medical Sciences, Hyderabad, Telangana, India

J Neuroanaesthesiol Crit Care 2023;10:118–120.

Address for correspondence Fahmeena Begum, MD, Department of Anaesthesiology and Intensive Care, Nizam's Institute of Medical Sciences, Punjagutta, Hyderabad 500082, Telangana, India (e-mail: fahmeena27@gmail.com).

Abstract

Postoperative pneumocephalus (PNC) is very common in craniotomy surgeries. It can be asymptomatic or if present in more volumes can cause symptoms such as lethargy, headache, confusion, or even severe neurological deficit. Treatment of pneumocephalus with supplemental oxygen via facemask is a common neurosurgical practice. There is not much evidence of use of high-flow nasal oxygen therapy (HFNOT) for the management of PNC. Here we report a case of an 8-year-old boy with postoperative symptomatic pneumocephalus, which resolved with the application of supplemental oxygen via a high-flow nasal cannula with 30 L/min flow and FiO_2 of 0.7 over 72 hours. High-flow nasal oxygen therapy can be an effective modality of treatment for postoperative PNC with added advantages of patient comfort and maintenance of warmth and moisture of the respiratory tract.

Keywords
- postoperative pneumocephalus
- supplemental oxygen
- high-flow nasal oxygen therapy

Introduction

Postoperative pneumocephalus (PNC) is a very common complication in craniotomy surgeries; however, it can occur even with surgeries requiring only burr hole. It can be asymptomatic or if present in more volumes can cause symptoms such as lethargy, headache, confusion, or even severe neurological deficit. Treatment of pneumocephalus with supplemental oxygen via facemask is a common neurosurgical practice although not supported by enough scientific evidence. However, there are case series that show that the process of resorption of pneumocephalus was exaggerated with supplemental oxygen.[1] There is sparse evidence of use of high-flow nasal oxygen therapy (HFNOT) for the management of PNC.

Case Report

An 8-year-old boy weighing 20 kg was brought to the emergency medicine department with complaints of headache and altered sensorium for the last 1 week. He was a known case of craniopharyngioma, for which excision was done 15 months ago. The patient had right-sided ventriculo-peritoneal (VP) shunt in situ. Computerized tomography (CT) brain revealed multi-lobulated and dilated lesion in suprasellar and infrasellar region with slit ventricles (►**Fig. 1A**).

Left-sided trans-cerebellar cysto-peritoneal shunt placement was done under general anesthesia. The child was apparently alright postoperatively except being lethargic.

On imaging, on postoperative day 1, ventricles were found to be collapsed and there was pneumocephalus (►**Fig. 1B**).

article published online
June 14, 2023

DOI https://doi.org/10.1055/s-0043-1763269.
ISSN 2348-0548.

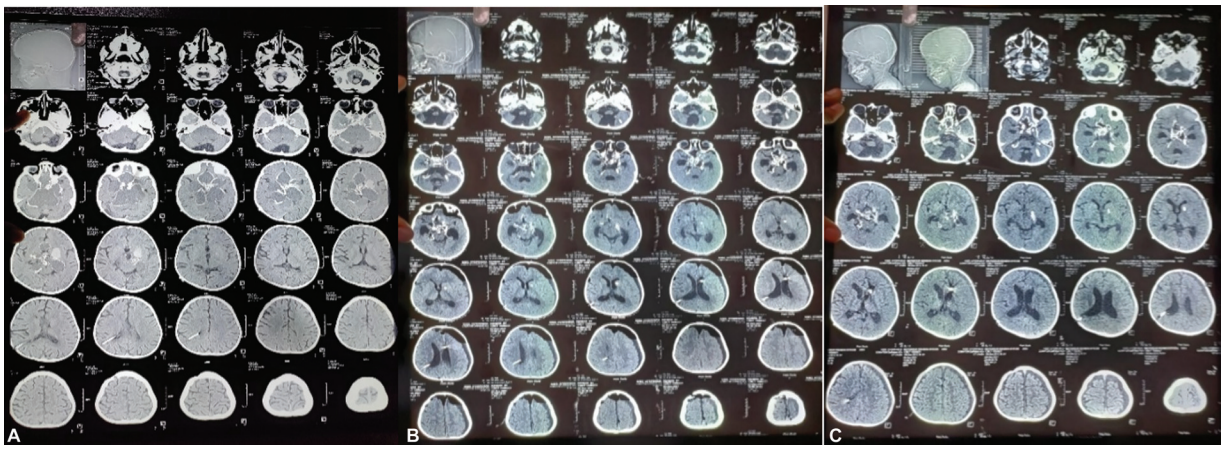

Fig. 1 **(A)** CT scan before surgery showing multilobulated dilated lesions. **(B)** CT scan showing pneumocephalus. **(C)** CT scan showing resorption of pneumocephalus.

Hence, the VP shunt was blocked to reduce over-drainage. In spite of this, there was not much neurological improvement. and the patient was managed conservatively.

Therefore, HFNOT was planned to manage pneumocephalus. He was kept on high-flow nasal cannula with 30 L/min flows and 0.7 FiO_2 for around 72 hours. Serial X-rays of the skull were taken in these 3 days that showed gradual resorption of air as shown in ►**Fig. 2**. The child's neurological status improved gradually during these 3 days and he started accepting feeds. Also, the CT scan of the brain confirmed complete resolution of the pneumocephalus (►**Fig. 1C**). However, serial arterial blood gas analyses (ABGs) were not done. No chest X-ray was done during the course of management.

Discussion

Although pneumocephalus can be asymptomatic usually, it can cause major complications as well. There have been various attempts to enhance the resorption of air in the cranium. A commonly practiced technique is the delivery of supplemental oxygen therapy to enhance the resorption of air in post-craniotomy pneumocephalus.[2,3] Increasing the concentration of inspired oxygen has shown to enhance the resolution of pneumocephalus in a mathematical model.[4] Higher oxygen concentration in inspired air leads to faster nitrogen washout from the lungs, thus causing diffusion of the nitrogen from the intracranial space into the blood along its concentration gradient and then out of the lungs.[4]

Different modes of oxygen delivery include simple face mask, nasal cannula, non-rebreather mask, high-flow nasal cannula. High flow nasal oxygen therapy has added advantages over other devices, which include the following: It provides heated and humidified oxygen which helps in maintaining the warmth and moisture of the respiratory tract, thus preventing the retention of secretions and infections; provides small amount of PEEP and high concentration of oxygen that can be delivered via HFNC helps in hastening the nitrogen washout from the lungs; and also comfortable for the patient thus improving compliance with the therapy when compared with other oxygen delivery devices.[5]

Although a high FiO_2 is known to cause pulmonary toxicity, FiO_2 of 1.0% for 24 to 48 hours has shown to be tolerated by humans without causing much harm.[6]

There is not much evidence of use of high-flow nasal cannula as a mode for management of postoperative pneumocephalus except a few case series that demonstrated effective resorption of pneumocephalus with HFNOT.[5]

Our case report also shows complete resolution of postoperative pneumocephalus with the use of a high-flow nasal cannula.

Conclusion

High-flow nasal oxygen therapy (HFNOT) can be an effective modality of treatment for postoperative PNC with added advantages of patient comfort and maintenance of warmth and moisture of the respiratory tract by providing heated and humidified

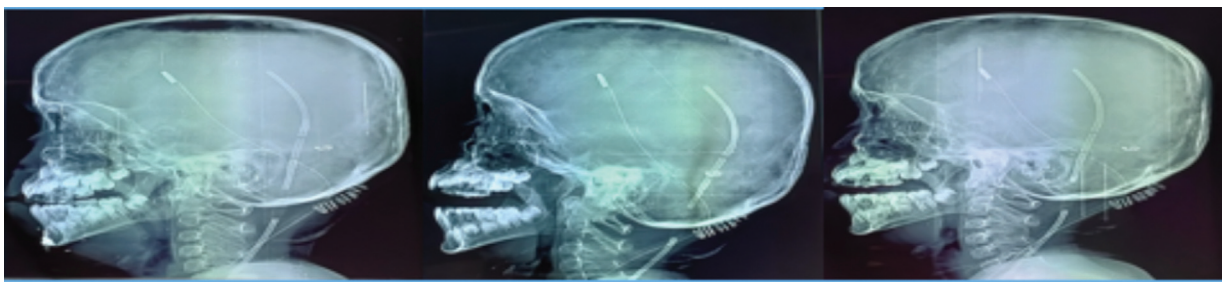

Fig. 2 Serial X-rays during oxygen therapy.

flow. Further studies comparing effectiveness HFNOT with other modalities of oxygen therapy for management of pneumocephalus will be needed to enhance the evidence.

Conflict of Interest
None declared.

References

1 Gore PA, Maan H, Chang S, Pitt AM, Spetzler RF, Nakaji P. Normobaric oxygen therapy strategies in the treatment of postcraniotomy pneumocephalus. J Neurosurg 2008;108(05):926–929
2 Spetzler RF, Zabramski JM. Cerebrospinal fluid fistulae: Their management and repair. In: Youmans JR, ed. Neurological Surgery: A Comprehensive Reference Guide to the Diagnosis and Management of Neurosurgical Problems. 3rd ed. Philadelphia, WB Saunders; 1990:2275, 9
3 Hong B, Biertz F, Raab P, et al. Normobaric hyperoxia for treatment of pneumocephalus after posterior fossa surgery in the semi-sitting position: a prospective randomized controlled trial. PLoS One 2015;10(05):e0125710
4 Dexter F, Reasoner DK. Theoretical assessment of normobaric oxygen therapy to treat pneumocephalus. Anesthesiology 1996; 84(02):442–447
5 Siegel JL, Hampton K, Rabinstein AA, McLaughlin D, Diaz-Gomez JL. Oxygen therapy with high-flow nasal cannula as an effective treatment for perioperative pneumocephalus: case illustrations and pathophysiological review. Neurocrit Care 2018;29(03): 366–373
6 Klein J. Normobaric pulmonary oxygen toxicity. Anesth Analg 1990;70(02):195–207