






Comparative Study Between Single Layer and Double Layer Graft Technique in Tympanoplasty for Subtotal Tympanic Membrane Perforation

Ahmed Abdel Rahman Abdel Aziz¹  Montaser Abdel Salam Hafez¹  Ashraf Gamal Mahmoud¹ 
AbdelMoneim H. Hamad¹ 

¹Department of Otorhinolaryngology, Faculty of Medicine, El Minia university, Egypt

Int Arch Otorhinolaryngol

Address for correspondence Ahmed Abdel Rahman Abdel Aziz, Associated professor, Department of Otorhinolaryngology Faculty of Medicine, El Minia, Egypt (e-mail: Ahmed_ent77@yahoo.com; Ahmed.abdelaziz@mu.edu.eg).

Abstract

Introduction Tympanoplasty is the main treatment of mucosal type of chronic suppurative otitis media.

Objective The aim of the present study was to compare clinical outcomes in terms of healing and audiological outcomes of two groups. The authors used single layer graft (perichondrium with cartilage island) graft in one group and double layer grafts (perichondrium cartilage island composite plus temporalis fascia) were used in the second group.

Methods Forty patients complained of chronic suppurative otitis media safe type with subtotal perforation subdivided into two groups. The first group author used single-layer perichondrium with cartilage island graft (composite graft) while in the second group authors used double graft in the form of perichondrium/cartilage island (composite graft) plus temporalis fascia.

Results There was no significant difference in the mean Air bone gap (ABG) between pre- and post-operative audiometry in subjects who had single layer tympanoplasty. There was a significant difference in the mean ABG between pre- and postoperative audiometry in subjects who had double layer tympanoplasty. There was a significant difference in the mean ABG differences between subjects who had single layer tympanoplasty and double layer tympanoplasty. Also, there was a significant difference in the healing of the tympanic membrane between subjects who had single layer tympanoplasty and double layer tympanoplasty.

Conclusion Tympanoplasty by double graft (temporalis fascia and tragal cartilage/perichondrium) achieved a considerable improvement in healing of the tympanic membrane TM with lower risk for residual perforation or graft rejection.

Keywords

- ▶ otitis media
- ▶ ear diseases
- ▶ hearing disorders

received
July 1, 2022
accepted
August 24, 2022

DOI <https://doi.org/10.1055/s-0043-1761174>.
ISSN 1809-9777.

© 2023. Fundação Otorrinolaringologia. All rights reserved.
This is an open access article published by Thieme under the terms of the Creative Commons Attribution-NonDerivative-NonCommercial-License, permitting copying and reproduction so long as the original work is given appropriate credit. Contents may not be used for commercial purposes, or adapted, remixed, transformed or built upon. (<https://creativecommons.org/licenses/by-nc-nd/4.0/>)
Thieme Revinter Publicações Ltda., Rua do Matoso 170, Rio de Janeiro, RJ, CEP 20270-135, Brazil

Introduction

Tympanoplasty is the cornerstone in the treatment of mucosal type of chronic suppurative otitis media (CSOM).¹

The classification of tympanic membrane (TM) perforation is made according to site, size, or etiology. Subtotal perforation is considered when there is a huge perforation of the pars tensa with preservation of some of its parts.²

OR when it involves the 4 quadrants of TM with TM remnant.³

There are issues in subtotal perforation reconstruction as there is not enough support provided by the remnant of TM anteriorly; therefore, medialization of graft and blocking of the eustachian tube (ET) opening may occur and there is also a high possibility of residual perforation in the anterior quadrant.⁴

Using tragal cartilage to support temporalis fascia graft is a novel technique and seems to have certain advantages as it gives more support anteriorly, preventing the graft from dropping in the middle ear and preventing it from retracting backwards.⁵

Objective

The aim of the present study was to compare clinical outcomes in terms of healing and audiological outcomes of two groups group. The authors used single layer (perichondrium with cartilage island) graft in one group, and double layer graft (perichondrium cartilage island composite plus temporalis fascia) was used in the second group with denovo step (tucking of temporalis fascia between the anterior edge of the tragal cartilage and the anterior meatal wall).

Materials and Methods

The present study was approved by the ethical committee of the Faculty of Medicine of El Minia university (approval number 623-3/2020), and informed written consent was obtained from the participants after detailed explanation of the study and its purpose. The authors prospectively compared clinical outcomes in terms of healing & audiological outcomes of two groups. In the first group, the authors used single-layer perichondrium with cartilage island graft (composite graft) while in the second group the authors used double graft in the form of perichondrium/cartilage island (composite graft) plus temporalis fascia. A total of 40 cases were included in the present study.

Inclusion Criteria

- Patients > 18 years old.
- Subtotal perforation.
- Air bone gap not > 35 dB
- The ear must be dry at least 3 months with healthy middle ear mucosa before the operation.

Exclusion Criteria

- Patients < 18 years old.

Air bone gap > 35 dB.

sensorineural hearing loss (SNHL) and mixed Hearing loss Unsafe Chronic suppurative otitis media (CSOM).

Previous ear surgery

In patients with associated upper respiratory tract infections (URTI), the operation was postponed.

Presence of any predisposing factors obstructing the Eustachian tube (ET) like symptomatizing deviated septum, nasal allergy septum, hypertrophic rhinitis, nasal or nasopharyngeal masses.

Operative Technique

All operations were performed under general anesthesia by using microscope after the performance of laboratory investigation, electrocardiogram (ECG) and internal medicine fitness.

- Postauricular incision
- Refreshing the edge of the perforation
- Elevation of tympanomeatal flap
- Harvesting of the graft:
 - Tragal Cartilage with Perichondrium
 - Temporalis fascia
- Applying of the harvested graft

Group 1

Twenty cases were included in this group.

The composite graft is held and introduced into the meatus by cup forceps, and then it is spread out in underlay manner to be lateral to the middle ear mucosa as well as under and medial to the handle of the malleus and the TM remnant with the perichondrium toward the external auditory canal.

Group 2

Twenty cases were included in this group.

After applying the composite graft as in group 1,¹ the temporalis fascia is put over the handle of the malleus and under the remnant of the tympanic membrane (over underlay technique) with the additional step of tucking of temporalis fascia under anterior border of tragal cartilage (between anterior border of cartilage and anterior meatal wall). ► **Fig. 1**

Results

Data Analysis and Statistics

Total Cases Impose

The two groups comprised 40 cases divided into 20 cases in group 1 and 20 cases in group 2.

All statistical calculations were performed using IBM SPSS Statistics for Windows, version 20 (IBM Corp., Armonk, NY, USA). Cleaning of data as a first step was done to detect missing values and invalid responses.

Quantitative data were presented by mean and standard deviation (SD) while qualitative data were presented by frequency distribution. The chi-squared test and the Fisher

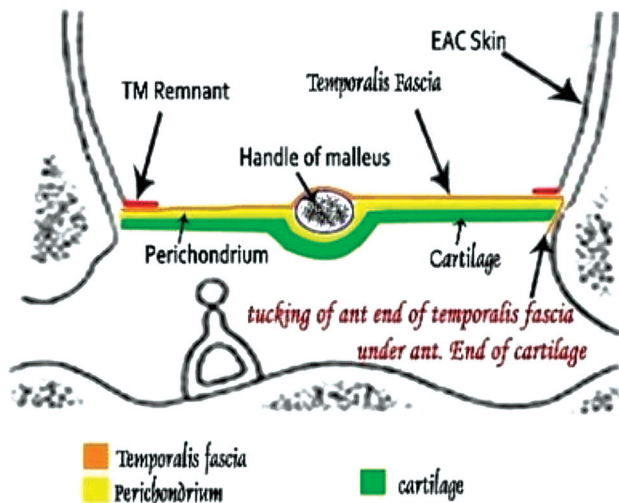


Fig. 1 Illustration for group 2 graft applying.

exact test were “used if > 20% of cells are < 5” to compare between proportions. The Wilcoxon Signed Ranks test was used to compare two means before and after for the same group while the Mann-Whitney test and the independent t-test were used to compare means between two groups.

P-values < 0.05 were considered statistically significant and all statistical tests were 2 tailed. The age of patients ranged from 18 to 44 years old in Group 1 and from 18 to 35 years old in Group 2, with a mean of 28.75 years old and an SD of 7.08 n both groups. There is no significant difference in the age groups regarding the age distribution in both groups with ($p = 0.1$).

Sex

Males represented 30% (12 cases) of the cases while females represented 70% (28 cases) in the present study, with no significant difference between both groups with ($p = 0.49$).

There was no significant difference in the mean ABG between the pre- and postoperative audiometry in subjects who had single layer tympanoplasty (► **Table 1**).

There was a significant difference in the mean ABG between the pre- and postoperative audiometry in subjects who had double layer tympanoplasty (► **Table 1**).

There was a significant difference in the mean ABG differences between subjects who had single layer tympanoplasty and double layer tympanoplasty (-2.35 versus -6.98, respectively) ($p = 0.015$) (► **Table 2**).

There was a significant difference in the healing of the TM between subjects who had single layer tympanoplasty and double layer tympanoplasty ($p = 0.02$) (► **Table 1**; ► **Fig. 2-3**).

The mean ABG difference was calculated by subtracting the preoperative mean air bone gap from the mean postoperative ABG.

There was a significant difference in the mean ABG differences between subjects who had single layer tympanoplasty and double layer tympanoplasty (mean -2.35 versus -6.98, respectively) ($p = 0.015$) (► **Table 3**).

Discussion

It seems that different grafts used in tympanoplasty have advantages and disadvantages. The otologist should compare between them and judge what is the most appropriate for the case and his surgical aim.

Also, over the decades, otologists have tried hard to modify various tympanoplasty techniques to achieve the most appropriate technique for graft uptake and hearing, such as palisade cartilage, composite graft, temporalis fascia reinforced by cartilage, sandwich, and modified sandwich techniques.

In the present study, the authors tried to gain from advantages and avoid most disadvantages of the used graft. Also, the authors tried to reap benefits of both the underlay and the over-underlay technique at the same time. Usage of tragal cartilage in the underlay technique with temporalis fascia in the over-underlay technique is a special technique as the fascia provides great healing power for the procedure and while it will shrink, the tragal cartilage will present to provide the support to temporalis fascia. Also, it will guard the temporalis fascia against negative pressure in cases of chronic eustachian tube dysfunction.

Lack of support in the anterior part of the perforation was a challenging issue and the authors of the present study try to overcome this by tucking the fascia under the anterior end of the cartilage (between the anterior edge of the cartilage and the anterior meatal wall).

In the present study, the authors compared this modified technique with the classic technique using composite graft (tragal cartilage + perichondrium) and the results showed significant improvement for double graft in comparison with composite graft only regarding graft uptake and hearing improvement.

The double graft technique has achieved complete closure of perforation in 100% of cases with 70% in the single layer group, which is statistically significant ($p = 0.02$).

Table 1 Comparison of pre- and post-operative Air bone gap for the studied groups

Tympanoplasty groups	Preoperative mean \pm SD	Postoperative mean \pm SD	p-value
Single layer	22.65 \pm 8.46	20.30 \pm 9.83	0.07
Double layer	20.88 \pm 8.88	13.90 \pm 6.82	< 0.0001*

Abbreviations: SD, standard deviation.

Table 2 Comparison of Air bone gap difference for the studied groups = (Hearing gain)

ABG difference	Tympanoplasty groups		p-value
	Single layer	Double layer	
Mean ± SD	- 2.35 ± 5.57	- 6.98 ± 5.84	0.015*

Abbreviations: SD, standard deviation.

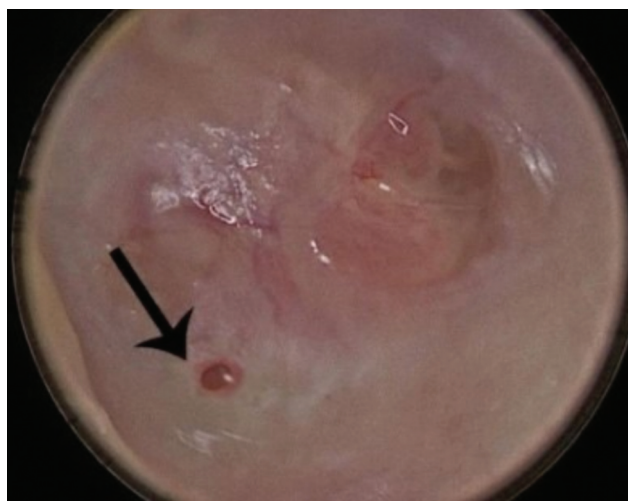


Fig. 2 Residual TM perforation in case of Group 1 tympanoplasty.

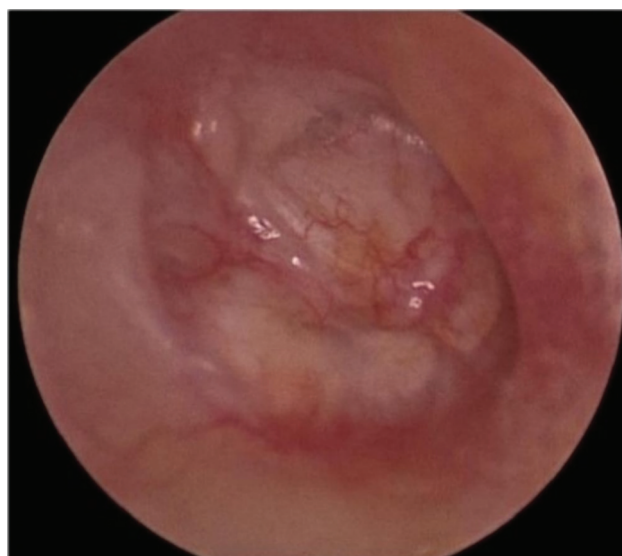

Fig. 3 Complete healing of the graft in case of group 2 tympanoplasty.

Table 3 Comparison of tympanic membrane healing between the studied groups

Healing	Tympanoplasty groups		p-value
	Single layer n (%)	Double layer n (%)	
No residual	14 (70)	20 (100)	0.02*
Small pinpoint	6 (30)	0	

Also, regarding hearing Postoperative ABG closure was (6.85 ± 5.66) and (2.35 ± 5.57) in double & composite graft respectively.

This low postoperative ABG closure may be explained by the fact that the authors tried to exclude any ossicular pathology in our cases, so the mean preoperative ABG was (20.88 ± 8.88) in the double graft group, which improved to 13.90 ± 6.82 postoperatively, while in the composite graft group the mean preoperative ABG was 22.65 ± 8.46 and became 20.30 ± 9.83 postoperatively.

The results of the study by Kolethekkat et al correlate with the results of group two of the present study as TM closure was successful in 94.7% of the cases (54 out of 57 cases) that underwent tympanoplasty using temporalis fascia reinforced by cartilage rim with preoperative ABG was 27.52 ± 10.06 dB and became 14.41 ± 7.00 dB respectively. While TM closure was (70%) of cases (40 out of 58 cases) using only temporalis fascia with pre- and postoperative ABG were 23.37 8.07 dB and 17.59 9.36 dB respectively. In Kolethekkat et al study cymba concha cartilage is applied

as horseshoe shaped along Tympanic annulus (supporting Anterior, posterior and inferior part of temporalis fascia).⁶

In the present study, cartilage graft used as one plate in the double graft group in comparison with Kolethekkat et al., who sculptured the conchal cartilage in the form of annular graft authors of current study believe that cartilage as one plate is more stable and support to temporalis fascia graft than horseshoe shaped cymba concha cartilage.

Tek et al. described a tympanoplasty technique using the cartilage from the cymba concha for reinforcement of the temporalis fascia (group 1) in comparison with another group using only temporalis fascia (group 2).⁷

The study suggested a significant difference between two groups as successful graft uptake was 86.5% in group 1 while it was 67.5% in group 2. But there is no significant difference between 2 groups in Postoperative ABG closure as it was (23.87 ± 7.73) & (23.03 ± 8.95) and became (12.09 ± 5.90) and (13.11 ± 7.13) in group¹ and group² respectively. This study correlate with current study regarding graft uptake which is better significantly in group using the cartilage for reinforcement of temporalis fascia.

The relatively improvement of ABG between preoperative and postoperative pure tone audiogram in the study of Tek et al than the current study may be explained by the fact that the study of Tak et al., was done on subtotal total and large central perforation while current study was done on subtotal tympanic membrane perforation only.

The study by Bedri et al. compared 3 groups:
Group 1: Tragal perichondrium, (single graft).

Group 2: perichondrium with cartilage island graft.

Group 3: Double layer graft using tragal perichondrium over the manubrium and perichondrium over tragal cartilage under the handle of the malleus.⁸

This study showed that closure of TM was better in group³ by 90.3%, while closure rates in group 1 were 76% and, in group 2, 78%, which correlates with the present study, while no significant difference in the hearing improvement in the postoperative hearing between 3 groups which differs from current study.

Rout et al. performed a comparative study between 2 groups, each group containing 150 ears with subtotal tympanic membrane perforation.⁹

Group¹ was surgically managed using temporalis fascia with the underlay technique while group² used temporalis fascia in underlay pattern and cartilage which cut to small slices and put under temporalis fascia.

In group 1: graft was taken in 124 cases (82.67%) with significant hearing improvement (≥ 10 dB) occurring in 92 out of 124 (74.19%) cases.

In group 2: graft was taken in 143 cases (95.34%) with significant hearing improvement occurring in 104 out of 143 (72.72%) cases.

Limitations

The limitation of the present study was when considering the number of cases in the double graft group and the experience of the surgeon (in the present study, all operations were performed by one surgeon with 20 years of experience).

Conclusion

Tympanoplasty by double graft (temporalis fascia and tragal cartilage / perichondrium) achieved a considerable improvement in healing of TM with lower risk for residual perforation

or graft rejection and is also better than single layer (composite tragal cartilage and perichondrium) regarding post-operative improvement of hearing.

Conflict of Interests

The authors have no conflict of interests to declare.

References

- 1 Deb T, Ray D. A study of the bacteriological profile of chronic suppurative otitis media in agartala. *Indian J Otolaryngol Head Neck Surg* 2012;64(04):326–329
- 2 Adegbiyi WA, Olajide GT, Olajuyin OA, Olatoke F, Nwawolo CC. Pattern of tympanic membrane perforation in a tertiary hospital in Nigeria. *Niger J Clin Pract* 2018;21(08):1044–1049
- 3 Linares Casas A, Ruiz R, De Pauli D. Endoscopic type 1 tympanoplasty; a composite graft technique for subtotal and total perforations. *Eur Arch Otorhinolaryngol* 2022;279(01):181–186
- 4 Mundra RK, Sinha R, Agrawal R. Tympanoplasty in subtotal perforation with graft supported by a slice of cartilage: a study with near 100 % results. *Indian J Otolaryngol Head Neck Surg* 2013;65(3, Suppl 3):631–635
- 5 Kulkarni S, Kulkarni V, Burse K, Sancheti V, Roy G. Cartilage support for fascia graft in type I tympanoplasty. *Indian J Otolaryngol Head Neck Surg* 2014;66(03):291–296
- 6 Kolethekkat AA, Al Abri R, Al Zaabi K, et al. Cartilage rim augmented fascia tympanoplasty: a more effective composite graft model than temporalis fascia tympanoplasty. *J Laryngol Otol* 2018;132(06):497–504
- 7 Tek A, Karaman M, Uslu C, et al. Audiological and graft take results of cartilage reinforcement tympanoplasty (a new technique) versus fascia. *Eur Arch Otorhinolaryngol* 2012;269(04):1117–1126
- 8 Bedri EH, Korra B, Redleaf M, Worku A. Double-layer tympanic membrane graft in type I tympanoplasty. *Annals of otology. Ann Otol Rhinol Laryngol* 2019;128(09):795–801
- 9 Rout MR, Mohanty D, Das CP, Prasad PV. Temporalis fascia graft versus composite graft in chronic suppurative otitis media with subtotal and total perforations. *Indian Journal of Otology* 2018;24(01):23–27