



# Evaluation of Flap Shrinkage Using Magnetic Resonance Imaging Follow-up in the Treatment of Oral Cancer

Philipp Thoenissen, MD, DDS<sup>1</sup> Andreas M. Bucher, MD<sup>2</sup> Anja Heselich, MD, DDS, PhD<sup>1</sup>  
Robert Sader, MD, DDS, PhD<sup>1</sup> Thomas Vogl, MD, PhD<sup>2</sup> Shahram Ghanaati, MD, DDS, PhD<sup>1</sup>

<sup>1</sup>Clinic for Cranio-Maxillo-Facial and Facial Plastic Surgery, University Medical Center Frankfurt, Frankfurt, Frankfurt/Main, Germany

<sup>2</sup>Department of Diagnostic and Interventional Radiology, University Medical Center Frankfurt, Frankfurt/Main, Germany

**Address for correspondence** Philipp Thoenissen, MD, DDS, Clinic for Maxillofacial and Plastic Surgery, University Medical Center Frankfurt, Theodor-Stern-Kai 7, 60950 Frankfurt/Main, Germany (e-mail: philipp.thoenissen@kgu.de).

J Reconstr Microsurg Open 2023;8:e12–e17.

## Abstract

**Objective** Tumor resection and reconstruction in patients with oral squamous cell carcinoma often involves free flaps followed by radiation therapy. Volume loss of free flaps is common following transplantation and radiation therapy. Therefore, this study investigates the volume loss of free radial forearm flaps in the field of craniomaxillo-facial surgery.

**Methods** In a retrospective single-center clinical study, postsurgery magnetic resonance imaging (MRI) was analyzed in patients with a free radial forearm flap. Additional functional outcomes were observed. The size of transplants and volume shrinkage were measured over time. Additional functional outcomes were observed with a questionnaire at any follow-up. Transplant size and volume shrinkage were evaluated in 12 patients and showed a mean transplant volume loss in radial forearm free flaps of 33% within 100 weeks postsurgery.

**Results** Depending on the site of transplantation, volume loss differed between the buccal region (38.33%), alveolar process (36.29%), and tongue (17.50%) and loss varied according to both radiation and chemotherapy (51.5%) or adjuvant radiotherapy (51.5%) compared with none of those (30%). Nine patients (75%) stated full functional satisfaction after this evaluation period.

**Conclusion** MRI follow-up imaging is an adequate tool for measuring the volume shrinkage of free flaps. This study proves that overcorrection of flaps is necessary by expecting a loss of volume that depends on the site of transplantation and adjuvant therapy to reach a satisfying quality of life.

## Keywords

- ▶ MRI
- ▶ free flap surgery
- ▶ microsurgery

Oral cancer is a common disease and is treated in cooperation with oromaxillofacial surgeons, pathologists, radiologists, and radiotherapists.

The number of patients with oral cancer is increasing. The age-dependent rate is 5.5 in women and 18.3 in men in the

European Union.<sup>1</sup> Two main entities, oral squamous carcinoma and adenoid cystic carcinoma, account for these tumors. The main goal of oral cancer therapy is the rehabilitation of quality of life and overall survival. Depending on tumor size, lymph node involvement, stage, and expansion therapy

received

May 23, 2022

accepted after revision

September 29, 2022

DOI <https://doi.org/>

10.1055/s-0043-1760756.

ISSN 2377-0813.

© 2023. The Author(s).

This is an open access article published by Thieme under the terms of the Creative Commons Attribution License, permitting unrestricted use, distribution, and reproduction so long as the original work is properly cited. (<https://creativecommons.org/licenses/by/4.0/>)

Thieme Medical Publishers, Inc., 333 Seventh Avenue, 18th Floor, New York, NY 10001, USA

consist of surgery, radiotherapy, and chemotherapy. Standard care in Germany and Europe is tumor resection and reconstruction involving compound free flaps followed by radiation therapy.<sup>2,3</sup> Follow-up is routinely performed clinically and using imaging techniques, such as computed tomography (CT) and magnetic resonance imaging (MRI) for at least a 5-year period.<sup>4</sup>

To reach a satisfying quality of life for patients, flap size, volume, and constitution must be considered. Flap shrinkage is common following transplantation and radiation therapy. However, there is no standard for overestimating different flaps and knowledge about individual flap shrinkage. With knowledge about shrinkage of free radial forearm transplants, flaps considered in this study were raised with a plus of 30% in width and height to reach satisfying volume and function.

Therefore, the objective of this study was to use MRI follow-up imaging to assess the volume loss of radial forearm free flaps after craniomaxillofacial tumor ablative surgery.

## Methods

In this retrospective study, 12 consecutive patients with oral cancer and reconstruction with a radial forearm free flap of the university hospital Frankfurt between 1 January 2018 and 31 December 2018 were evaluated. Institutional review board approval was given (SKH-2-2019; 4/09).

The following inclusion criteria were applied: primary resection of oral cancer and defect coverage by radial forearm free flap. The exclusion criterion was local surgical intervention after primary resection within the observation period. Noted parameters were tumor stage according to TNM classification (tumor, node, metastasis), sex, age, time of surgery, and flap type.

Radiation therapy was applied according to local protocols using intensity-modulated radiation therapy and image-guided radiation therapy.

Volume measurements consist of MRI follow-up scans. MRI scans were performed routinely during the trial for guideline surveillance to detect local relapse or metastasis. No additional MRI scans were performed for the study.

### Data Acquisition

Follow-up MRI was acquired for all patients with a field strength of 3 Tesla (Siemens Magnetom Prisma Fit, Siemens Healthineers, Forchheim, Germany).<sup>5</sup> Each examination included a noncontrast-enhanced, nonfat-suppressed T1 spin echo sequence (T1 TSE). Only these sequences were used for volumetry. T1 TSE was acquired in both axial and coronal orientations at equal slice thickness (→ **Table 1**). This workflow has been described earlier by the authors.<sup>6</sup> Imaging was planned to include the thoracic-cervical junction up to the skull base. If severe motion artifacts occurred, image sequences were repeated up to two times. The best image series was included if the repeated acquisition was performed. Patients with examinations of insufficient image quality were excluded from the analysis.

**Table 1** Overview of MRI details of the protocol for sequences using T1 in axial orientation

MRI Protocol	T1 axial
MRI scanner model	Magnetom Prisma Fit
Sequence type	T1 turbo spin echo
Repetition time	659 milliseconds
Echo time	12 milliseconds
Orientation	Transverse
Coding direction	anterior-posterior
Slice thickness	4 mm
Distance factor	20%
Voxel size	0.7 × 0.7 × 4.0 mm
Field of view	270 mm
Concatenations	2
Fat suppression	No

Abbreviation: MRI, magnetic resonance imaging.

### Volume Changes

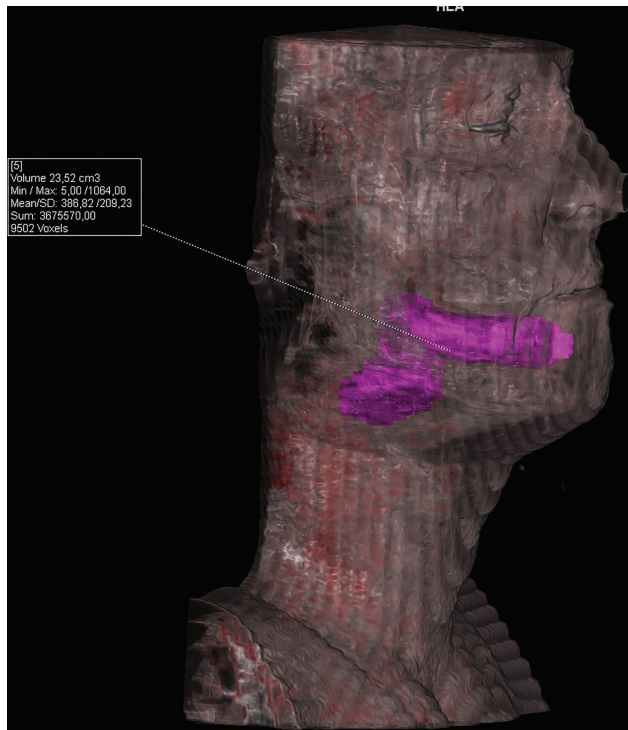
Volumetry was performed on a GE (Version VB10B, Siemens Health care Forchheim, Germany). All measurements used the 3D region of interest (ROI) tool in 3D mode. All image sets were presented in random order using a random number generator without repetition. Raters were blinded to the patient's name and examination date. Axial and coronal orientations were pooled together for this randomization. Measurements were taken to include the entire flap tissue, including the vessel stem. Recorded parameters were volume in cubic-centimeters and numbers of ROIs.

Measurements were drawn by a radiologist with 5 years of experience in reading craniomaxillofacial (CMF) imaging together with a CMF fellow with 4 years of surgical experience. Volumetry was performed on axial-oriented series. 3D volumetry was checked in the 3D segmentation mode.

The border of the transplant was delineated manually using the brushing tool included in the software postsurgery MR scan. All slices depicting the transplant were used to delineate borders. The border was identified due to differences in intensity values of aspects of transplant and surrounding tissue. Volume was measured by using the software's internal measuring tool. The automated segmentation tool of the software was used (→ **Fig. 1**).

In the postoperative MRI scans, the border of the transplant was delineated in the same manner at three different time points.

According to the time of primary surgery, five-time intervals were set and MRI scans were set to groups. In the case of the presence of more than one MRI per interval, a mean value was calculated. The following groups were set as follows: 1 to 10, 11 to 20, 21 to 30, 31 to 50, and 51 to 100 weeks post-surgery.



**Fig. 1** Postoperative MRI with delineation of the radial forearm free flap (purple) using digital marking after complete tumor resection of a patient with oral squamous cell carcinoma (OSCC) in the right mandible. The volume of the flap, including the vessel, was measured to be 23.52 cm<sup>3</sup>.

**Statistical Analysis**

All statistical analyses were performed using commercially available statistics software Prism for Mac OS (Version 8 GraphPad, La Jolla, USA). Testing was performed for normal distribution by the Friedman test. Categorical variables are presented as percentages, continuous variables as the mean ± standard deviation or median and interquartile range in

cases of nonnormal distribution. *p*-Values less than 0.05 were considered to be statistically significant.

**Results**

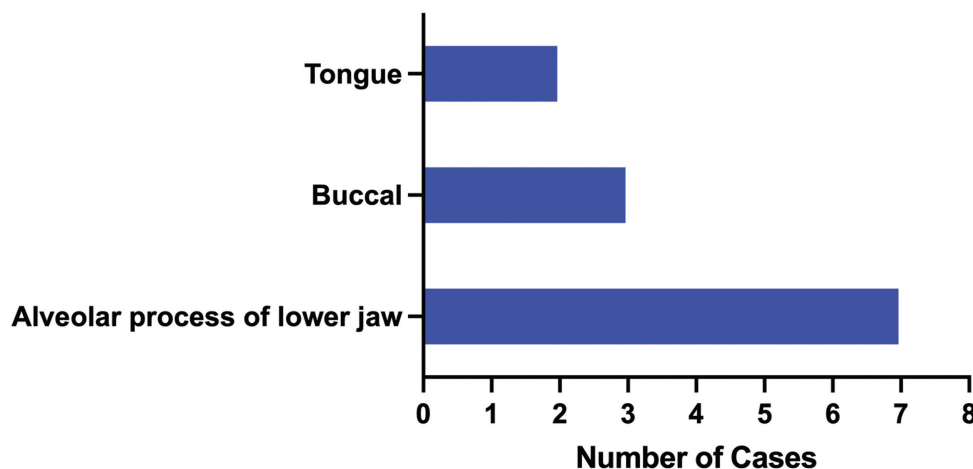
A total of 35 consecutive patients were enrolled in this study. Finally, 12 patients fit the inclusion criteria and were evaluated for flap shrinkage. Seventeen patients had to be excluded due to insufficient follow-up imaging, the switch of modality from MRI to CT, and a surgical intervention or relapse and death.

The mean age of all patients was 59.33 ± 11.06 years. Of them, seven patients were female and five were male. Eleven patients were diagnosed with oral squamous cell carcinoma, and one patient was diagnosed with mucoepidermoid carcinoma. The TNM classification T stage was as follows: T1 = 1 (8%), T2 = 5 (42%), T3 = 3 (25%), and T4 = 3 (25%). The localizations of the tumor and the flap were the alveolar process, buccal region, and tongue (►Fig. 2). Six patients received adjuvant radiation and chemotherapy; in two patients, adjuvant radiation therapy was administered alone, and four patients did not receive any adjuvant treatment. In three patients, functional abnormalities occurred: no oral vestibule was presented as the basis for prosthetic rehabilitation after transplantation<sup>2</sup> or constrained mouth opening<sup>1</sup> (►Table 2). These patients needed secondary correctional

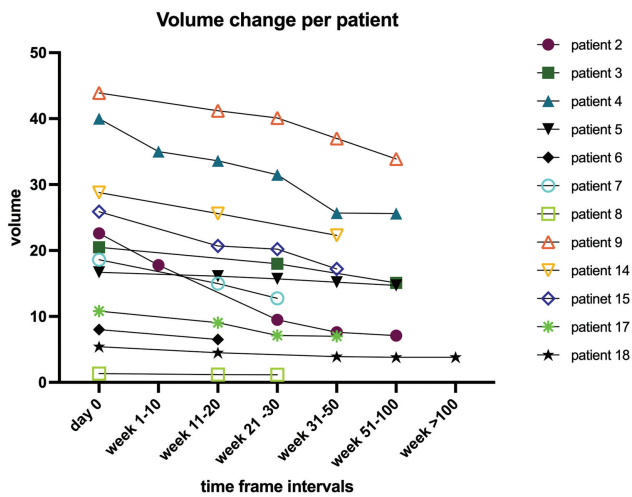
**Table 2** A list of different functional disorders and complaints at the time of last imaging for each patient

Impairments	Number	Percent
No functional abnormality	9	75%
No oral vestibule	2	16.7%
Constrained mouth opening	1	8.3%

**Localization**



**Fig. 2** Distribution of different tumor and flap localizations: most flaps have been transferred to cover defects on the alveolar process of the lower jaw, followed by the buccal and tongue.



**Fig. 3** Volume loss of 12 radial forearm free flaps in the patients' collective from the starting point postsurgery/post adjuvant therapy and within the five periods of time in an up to 100 weeks postsurgery.

surgery to improve dysfunction. The remaining nine patients (75%) stated no functional disability.

The first MRI was obtained within a 3-month period after surgery. In cases of radiation or a combination of radiation and chemotherapy, MRI was conducted within 3 months after the completion of adjuvant therapy. In addition to this postoperative MRI scan, 51 further MRI scans were analyzed. The maximum number of MRI scans was 10 per patient. On average, patients received 5.25 postoperative MRI scans. The period of evaluation was 100 weeks.

The initial volume of the transplant was 20.21 cm<sup>3</sup> and decreased to 16.70 cm<sup>3</sup> by 32.67% in a 100-week period ( $p = 0.001$ ; ► **Fig. 3**).

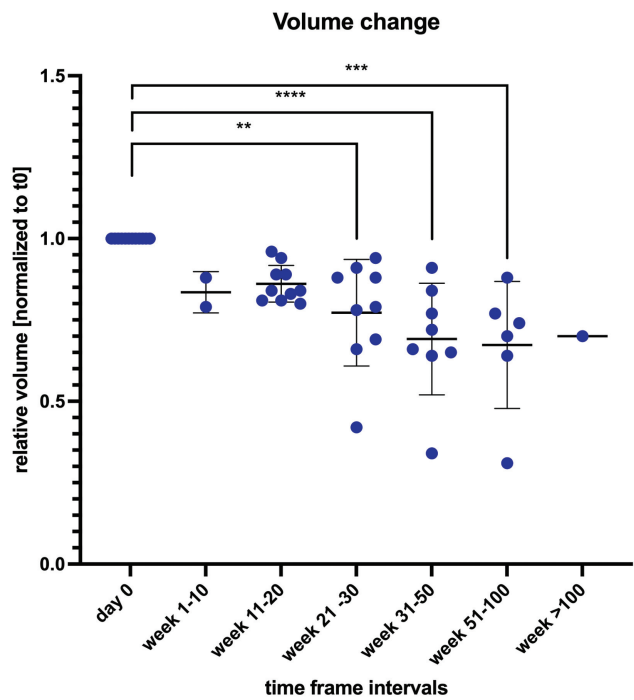
Flap shrinkage was significant at 21 to 30 weeks, with a reduction of 22.68% ( $p = 0.0031$ ). The volume loss between the postsurgical measure and the time interval of weeks 31 to 50 was 30.88% ( $p < 0.0001$ ; ► **Fig. 4**). No significant differences in flap shrinkage were observed between the interval groups.

Volume loss for the group of patients treated with radiation and chemotherapy was 51.5%. In contrast, the decrease for the group of patients with adjuvant radiation alone was 26%. Flaps in the group of patients without any adjuvant therapy lost 30% of their starting volume. Between these groups, no significant difference was observed (► **Fig. 5**).

Volume loss for flaps transplanted to the alveolar process was 36.29%, buccal 38.33%; flaps used to reconstruct the tongue lost 17.50%. The difference between those groups was not significant ( $p = 0.4335$ ).

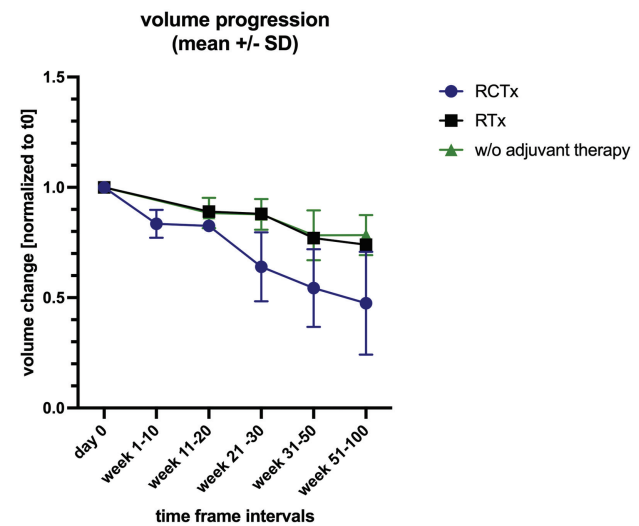
### Discussion

This study evaluated volume loss of radial forearm free flap transplants in patients with oral tumor resection and reconstruction using MRI follow-up imaging. Building time intervals and by manually delineating the flap border in each MRI, the shrinkage of radial forearm free flaps in a 100-week period was observed to be 33%. In three patients, abnormal



**Fig. 4** Volume loss of 12 patients with pooled measurements and indication for significant differences: \*\* = 0.0031, \*\*\*\* < 0.0001, \*\*\* = 0.0001.

functions occurred that needed surgical intervention as a basis for complete oral rehabilitation. Consequently, the original idea of overestimation of the size of radial forearm free flaps led to an acceptable postsurgery status. These results point to a confirmation that overcorrection of free flaps is necessary to reach satisfying results in oral reconstruction.



**Fig. 5** Volume loss for the different patients with radial forearm free flaps for the different groups. Six patients received adjuvant radiation and chemotherapy, and two received radiation therapy; four patients did not undergo any adjuvant therapy. The volume loss of patients with radiation therapy and without any adjuvant therapy was equal and differed from that of the group of patients undergoing radiation and chemotherapy without any significance.

To achieve the best outcome of surgery, volume changes of overcorrected free radial forearm transplants after tumor resection in the oral cavity were measured. Therefore, MRI follow-up is proven to be a proper method for the measurement of radial forearm free flaps.<sup>6</sup> Depending on the type, the constitution of the flap and the site of transplantation volume changes over time are different. The alterations in volume due to time depend on the constitution of flaps and adjuvant therapy.<sup>7-9</sup> To prevent complications and impairment due to flap shrinkage, it is widely accepted that volume loss after transplantation can be compensated by overcorrection.<sup>10</sup> Park and Shim showed a volume loss of the transverse abdominis muscle of 5.56% in the first 9 months after surgery.<sup>11</sup> Haykal et al reported a volume loss for free abdominal flaps of 23% in a small study group.<sup>12</sup> Cho et al found a volume loss for a local pectoralis major myocutaneous flap of 10.8% and a loss for an anterolateral thigh flap of 24.8%.<sup>13</sup> Bittermann et al found an average shrinkage of 34.4% considering latissimus dorsi free flaps.<sup>14</sup> Tarsitano et al found a mean flap volume loss of 34.7% when observing anterolateral thigh flaps. Joo et al depicted a 40% decrease in the volume of radial forearm free flaps in a 5-year follow-up period.<sup>15</sup> On these grounds, overestimation from 10, 20, and 40%, or a factor of 1.4, is recommended.<sup>9,13-15</sup> However, a plus of 30% in width and length to the tumor site was applied to the raised flap and was not concordant with the volume loss of 30%.

Facing the overall volume loss is generally recommended to overestimate the volume that is to be provided for defect closure. Concerning the influence of radiation therapy, different findings compete. This study showed a volume loss of 50% for patients undergoing radiation and chemotherapy postsurgery. Due to the reduced number of patients, there was no significant finding. Cho et al compared postoperative volume loss of free flaps and local flaps and found no influence of radiation therapy on volume loss.<sup>13</sup> Tarsitano et al found a significant difference in volume loss in their study analyzing postoperative changes in free anterolateral thigh flap: a loss of 44.2% for patients with radiation therapy compared with 19.8% was observed.<sup>9</sup> Bittermann et al also found no statistical significance in patients who underwent radiation therapy.<sup>16</sup> Hohlweg-Majert et al also found no difference in graft vitality regardless of irradiation.<sup>17</sup> Razavi et al discussed a protective influence of irradiation on volume loss; on the contrary, increased patient age was determined to be a factor in increasing volume loss.<sup>18</sup> However, this is a question still to be solved.

Concerning the constitution of the flap, Kang et al 2021 postulated that the fatty proportion in pedicled myocutaneous latissimus dorsi flaps is not undergoing shrinkage. Instead, the muscle is accountable for flap shrinkage.<sup>19</sup>

Additionally, as the volume changes also differ by the site of transplantation, more attention needs to be paid to this issue. The present study demonstrates a relatively low volume change for the site of the tongue (17.50%). However, the volume losses for the alveolar process and buccal region were nearly equal (26.29 vs. 38.33%). As such, the size of a

flap needs to be adjusted for the different transplant localizations of the oral cavity.

In particular, radial forearm free flaps should not lose any volume, as there is less muscle within the composition of the transplant.<sup>20</sup> The findings of the study may be partially due to the small size of radial forearm flaps, which makes it difficult to identify the borders of this type of flap. Additionally, the results show some difficulty in imaging, as metal artifacts caused by dental implants impede the delineation of borders. Artifacts might increase this inaccuracy.

Due to the change in the modality in follow-up from CT to MRI, patients had to be excluded from this study. Different modalities make it difficult to compare results with findings in the literature, as CT and MRI are not used consistently in the evaluation of flap shrinkage.

Although CT and MRI are considered of equal value in primary and restaging, one modality should be determined for a patient, with attention given to individual requirements.

## Conclusion

MRI is standard in the diagnosis and follow-up examinations of oral cancer patients and showed in this study 33% volume loss after transplantation of free radial forearm flaps over an average 100-week period. Therefore, it is recommended to overestimate the volume of free flaps for defect closure in CMF surgery to achieve the best function and patient satisfaction. The different sites of transplantation are the key factor for flap shrinkage and need to be considered, as volume loss varies between the buccal region, alveolar process, and tongue. Additional preclinical and clinical research is needed to identify the reason and extent of flap shrinkage for different transplants.

## Conflict of Interest

None declared.

## References

- 1 Kaatsch P, Spix C, Katalinic A, et al. Krebs in Deutschland 2011/2012. Robert Koch-Institut; 2015
- 2 Wolff K-D, Bootz F, Beck J et al. Diagnostik und Therapie des Mundhöhlenkarzinoms. Leitlinienprogramm Onkologie der AWMW, Deutschen Krebsgesellschaft e.V. und Deutschen Krebshilfe e.V.; 2012
- 3 Kansy K, Mueller AA, Mücke T, et al. Microsurgical reconstruction of the head and neck region: current concepts of maxillofacial surgery units worldwide. *J Craniomaxillofac Surg* 2015;43(08): 1364-1368
- 4 Wolff K-D, Follmann M, Nast A. The diagnosis and treatment of oral cavity cancer. *Dtsch Arztebl Int* 2012;109(48):829-835
- 5 Verduijn GM, Bartels LW, Raaijmakers CP, Terhaard CH, Pameijer FA, van den Berg CA. Magnetic resonance imaging protocol optimization for delineation of gross tumor volume in hypopharyngeal and laryngeal tumors. *Int J Radiat Oncol Biol Phys* 2009;74 (02):630-636
- 6 Thoenissen P, Heslich A, Sader R, Vogl TJ, Ghanaati S, Bucher AM. Three-dimensional magnetic resonance imaging volumetry of radial forearm flap reconstructions after craniomaxillofacial tumor resection. *J Craniofac Surg* 2020;31(05):e465-e469
- 7 Kimata Y, Sakuraba M, Hishinuma S, et al. Analysis of the relations between the shape of the reconstructed tongue and postoperative

- functions after subtotal or total glossectomy. *Laryngoscope* 2003; 113(05):905–909
- 8 Mücke T, Rau A, Weitz J, et al. Influence of irradiation and oncologic surgery on head and neck microsurgical reconstructions. *Oral Oncol* 2012;48(04):367–371
  - 9 Tarsitano A, Battaglia S, Cipriani R, Marchetti C. Microvascular reconstruction of the tongue using a free anterolateral thigh flap: three-dimensional evaluation of volume loss after radiotherapy. *J Craniomaxillofac Surg* 2016;44(09):1287–1291
  - 10 Yun IS, Lee DW, Lee WJ, Lew DH, Choi EC, Rah DK. Correlation of neotongue volume changes with functional outcomes after long-term follow-up of total glossectomy. *J Craniofac Surg* 2010;21(01):111–116
  - 11 Park SU, Shim JS. Assessment of breast volume change after transverse rectus abdominis myocutaneous flap. *Arch Plast Surg* 2012;39(06):631–635
  - 12 Haykal S, White CP, Guay NA. An estimation of volume loss after radiation therapy on free flap breast reconstruction. *Plast Reconstr Surg* 2013;131(06):937e–939e
  - 13 Cho KJ, Joo YH, Sun DI, Kim MS. Perioperative clinical factors affecting volume changes of reconstructed flaps in head and neck cancer patients: free versus regional flaps. *Eur Arch Otorhinolaryngol* 2011;268(07):1061–1065
  - 14 Bittermann G, Thönissen P, Poxleitner P, Zimmerer R, Vach K, Metzger MC. Microvascular transplants in head and neck reconstruction: 3D evaluation of volume loss. *J Craniomaxillofac Surg* 2015;43(08):1319–1324
  - 15 Joo YH, Hwang SH, Sun DI, Park JO, Cho KJ, Kim MS. Assessment of volume changes of radial forearm free flaps in head and neck cancer: long-term results. *Oral Oncol* 2011;47(01):72–75
  - 16 Bittermann G, Scheifele C, Prokic V, et al. Description of a method: computer generated virtual model for accurate localisation of tumour margins, standardised resection, and planning of radiation treatment in head & neck cancer surgery. *J Craniomaxillofac Surg* 2013;41(04):279–281
  - 17 Hohlweg-Majert B, Ristow O, Gust K, Kehl V, Wolff KD, Pigorsch S. Impact of radiotherapy on microsurgical reconstruction of the head and neck. *J Cancer Res Clin Oncol* 2012;138(11):1799–1811
  - 18 Razavi CR, Hostetter J, Shukla A, et al. Predictors of free flap volume loss in nonosseous reconstruction of head and neck oncologic defects. *Ear Nose Throat J* 2022;101(01):48–53
  - 19 Kang CM, Shim JS, Park SH, Jeong YJ, Seol KH, Kwak SG. Volume change of muscle and fat portions of latissimus dorsi myocutaneous flap after breast reconstruction. *Plast Reconstr Surg Glob Open* 2021;9(04):e3536
  - 20 Yang GF, Chen PJ, Gao YZ, et al. Forearm free skin flap transplantation: a report of 56 cases. 1981. *Br J Plast Surg* 1997;50(03):162–165