Volumetric Assessment of Swallowing Muscles: A Comparison of CT and MRI Segmentation

Volumetrische Erfassung der Schluckmuskulatur: Ein Vergleich von CT und MRT Segmentation

Authors

Kim Barbara Sporns[1], Uta Hanning[1], Rene Schmidt[2], Paul Muhle[3], Rainer Wirth[4], Sebastian Zimmer[1], Rainer Dziewas[3], Sonja Suntrup-Krueger[3], Peter Bernhard Sporns[1], Walter Heindel[1], Wolfram Schwindt[1]

Affiliations

1 Department of Clinical Radiology, University Hospital of Muenster, Muenster, Germany
2 Institute of Biostatistics and Clinical Research, University of Muenster, Germany
3 Department of Neurology, University Hospital of Muenster, Germany
4 Department of Geriatric Medicine, Universitätsklinikum Marien Hospital Herne, Ruhr-University of Bochum, Bochum, Germany

Key words

computed tomography, magnetic resonance imaging, segmentation, muscle atrophy, sarcopenia, swallowing muscles

received 09.07.2017
accepted 11.09.2017

Bibliography

DOI https://doi.org/10.1055/s-0043-120529
Published online: 3.11.2017
Fortschr Röntgenstr 2018; 190: 441–446

ISSN 1438-9029

Correspondence

Kim Sporns, MD
Department of Clinical Radiology, University Hospital of Muenster, Albert-Schweitzer Campus 1, Gebäude A1, 48149 Muenster, Germany
Tel.: ++49/2 51/8 34 41 51
KimBarbara.Sporns@ukmuenster.de

ZUSAMMENFASSUNG

Einleitung Retrospektive, auf CT-Daten basierende Studien, beschreiben eine hohe Korrelation zwischen einer Atrophie der Schluckmuskulatur und dem Alter der Patienten, sowie dem Schweregrad einer Dysphagie und der Aspirationsgefahr. Die ionisierende Strahlung stellt bei CT-Untersuchungen jedoch eine ethische Barriere für eine weitere Evaluation dieser Resultate mittels prospektiver Studien dar. Daher besteht ein Bedarf die Effektivität anderer Methoden, die ohne Strahlung auskommen und hochwertige Weichteilkontraste liefern, zu evaluieren. Das Ziel der vorliegenden Studie war es daher die Muskel-Volumetrie der Schluckmuskultur von Patienten in CT und MRT zu vergleichen.

Methoden Retrospektive Studie von 21 Patienten (Medianes Alter 46,6 Jahre; Geschlecht: 11 Frauen) die ein CT und MRT der Halsregion in einem Zeitfenster von weniger als 50 Tagen bei Verdacht auf eine Neoplasie der Halsregion erhalten haben. Die CT's und MRT's wurden mittels Medical Imaging Toolkit (MITK) segmentiert und die erhaltenen Muskelvolumina wurden mittels Äquivalenztest getestet. Multiples Testen wurden mittels Bonferroni-Test korrigiert und der mögliche Einfluss der Zeit zwischen den Untersuchungen wurde mittels Korrelationsanalyse getestet. Das Einverständnis des lokalen Ethikkomitees liegt vor.

Ergebnisse Die medianen Volumina für den Musculus digastricus im CT betragen 3051 mm^3 (links) und 2969 mm^3 (rechts), und im MRT 3218 mm^3 (links) und 3027 mm^3 (rechts). Das mediane Volumen des Musculus geniohyoideus betrug im CT 6580 mm^3 und im MRT 6648 mm^3. Die Interrater Reliabilität war für alle segmentierten Muskeln hoch. Das mittlere Zeitintervall zwischen CT und MRT betrug 34 Tage (IQR 25; 41). Es lag keine signifikante Assoziation der Zeit zwischen den Untersuchungen und dem Unterschied der Muskelvolumina vor (linker M. digastricus $r = 0{,}003$ und rechter M. digastricus $r = -0{,}008$; M. geniohyoideus $r = 0{,}075$).

Schlussfolgerung Die CT und MRT basierte Volumetrie der Schluckmuskulatur ist möglich und gleichwertig. Der potentielle Vorteil der MRT ist die Anwendbarkeit in prospektiven Studien ohne ionisierende Strahlung.

Kernaussagen

- Die CT und MRT basierte Segmentation der Schluckmuskulatur ist gleichwertig.
- Der Vorteil der MRT ist die fehlende ionisierende Strahlung.
- Für prospektive Studien kommt damit primär die MRT in Betracht.

ABSTRACT

Purpose Recent retrospective studies have proposed a high correlation between atrophy of swallowing muscles, age, severity of dysphagia and aspiration status based on computed

tomography (CT). However, ionizing radiation poses an ethical barrier to research in prospective non-patient populations. Hence, there is a need to prove the efficacy of techniques that rely on noninvasive methods and produce high-resolution soft tissue images such as magnetic resonance imaging (MRI). The objective of this study was therefore to compare the segmentation results of swallowing muscles using CT and MRI.

Methods Retrospective study of 21 patients (median age: 46.6; gender: 11 female) who underwent CT and MRI of the head and neck region within a time frame of less than 50 days because of suspected head and neck cancer using contrast agent. CT and MR images were segmented by two blinded readers using Medical Imaging Toolkit (MITK) and both modalities were tested (with the equivalence test) regarding the segmented muscle volumes. Adjustment for multiple testing was performed using the Bonferroni test and the potential time effect of the muscle volumes and the time interval between the modalities was assessed by a spearman correlation. The study was approved by the local ethics committee.

Results The median volumes for each muscle belly of the digastric muscle derived from CT were 3051 mm^3 (left) and 2969 mm^3 (right), and from MRI they were 3218 mm^3 (left) and 3027 mm^3 (right). The median volume of the geniohyoid muscle was 6580 mm^3 on CT and 6648 mm^3 on MRI. The interrater reliability was high for all segmented muscles. The mean time interval between the CT and MRI examinations was 34 days (IQR 25; 41). The muscle differences of each muscle between the two modalities did not reveal significant correlation to the time interval between the examinations (digastric left $r = 0.003$ and digastric right $r = -0.008$; geniohyoid muscle $r = 0.075$).

Conclusion CT-based segmentation and MRI-based segmentation of the digastric and geniohyoid muscle are equally feasible. The potential advantage of MRI for prospective studies is the absence of ionizing radiation.

Key Points

- CT-based segmentation and MRI-based segmentation of the swallowing muscles are equally feasible.
- The advantage of MRI is the absence of ionizing radiation.
- MRI should therefore be deployed for future prospective studies.

Citation Format

- Sporns KB, Hanning U, Schmidt R et al. Volumetric Assessment of Swallowing Muscles: A Comparison of CT and MRI Segmentation. Fortschr Röntgenstr 2018; 190: 441–446

Purpose

Different approaches for the morphometric assessment of skeletal muscles using a variety of imaging techniques have been reported. In contrast, changes in morphometry of the head and neck muscles have received little attention so far. Only initial results using two dimensional approaches in computed tomography (CT) [1] and comparing magnetic resonance imaging (MRI) and ultrasonographic measurements [2] have been published.

Several suprahyoid muscles play a key role in the characteristic movement of the hyoid bone during swallowing. For example, the geniohyoid (GH) muscle connects the posterior aspect of the mandible in the midline with the anterior surface of the body of the hyoid bone. The GH muscle's contraction drives the hyoid bone upward and forward together with the mylohyoid, stylohyoid, and anterior belly of the digastric muscles [3]. Sarcopenia of these muscles may play an important role in reducing hyoid bone movement and thus results in an increased risk of dysphagia in affected patients [1].

Feng et al. [1] found an interesting association between atrophy of the geniohyoid muscle and aspiration status in older adults using simplified CT measurements. In a recent publication our group described an association of age and severity of dysphagia with muscle atrophy using three-dimensional semi-automated segmentation of different swallowing muscles [4]. However, ionizing radiation poses an ethical barrier to research when using CT imaging to investigate muscle size in prospective non-patient populations. So far, no studies have compared CT and MRI regarding assessment of this muscle group. Therefore, there is a need to prove the efficacy of techniques that rely on non-radiating methods and produce high-resolution soft tissue images, such as MRI.

This study aims to compare the muscle volumes of submental muscles (geniohyoid muscle and anterior belly of the digastric muscles) obtained from both CT and MRI images to see whether equal muscle volumes can be achieved with magnetic resonance imaging. If MRI provided similar results in the segmentation of swallowing muscles, changes in the musculature responsible for swallowing could be examined without ionizing radiation in prospective studies.

Methods

Study design and setting

A retrospective observational study was conducted using data of patients who had undergone computed tomography angiography and magnetic resonance imaging of the head and neck region at the Department of Clinical Radiology at the University Hospital of Muenster within a time frame of less than 50 days. All patients had undergone CT first and MRI afterwards using contrast agent because a neoplasia in the head and neck region was suspected.

Patients were included if: 1) they had undergone CT and MRI within a time frame of less than 50 days and 2) a neoplasia in the head and neck region was suspected. No patients were excluded.

Of the 21 included patients, 11 (52.4 %) were female and 10 (47.6 %) were male. The median age was 46.6 (35.6 – 57.8) years.

All examinations were part of routine clinical care. The study was approved by the local ethics committee. As the nature of the

study was purely retrospective, the review board waived the need for informed consent. The identity of each documented patient is completely anonymized.

Imaging protocol and data post-processing

CT scans were performed on a 128-slice dual-source CT scanner (Somatom Definition Flash; Siemens Medical Solutions, Forchheim, Germany). CTA was obtained with the following parameters: 120 kV, 175 mAs, 1.0-mm slice reconstruction, 1-mm increment, 0.6-mm collimation, 0.8 pitch, H20f soft kernel. In all scans contrast medium was used (80 mL Ultravist 370 and 50 mL NaCl flush at 4 mL/s, scan start 6 seconds after bolus tracking at the level of the ascending aorta).

MRI was performed using a 3 Tesla MRI (Philips Ingenia 3.0 T, Philips, Eindhoven, The Netherlands). We obtained coronal and axial T1-weighted images (TE/TR = 7508/595 267 ms, TI = 0 ms, slice thickness = 4.4 mm) using a phased array coil. In all patients 1 mmol/kg of gadolinium-based contrast agent (Gadolinium Omniscan; GE Healthcare, Chicago, IL, USA) was administered by the technical assistant.

On coronal CTA and MRI T1-weighted images, the geniohyoid muscle and the anterior parts of the digastric muscles were segmented slice by slice on both sides using Medical Imaging Toolkit (MITK 2.4.0.0, Heidelberg, Germany). In the following steps segmentations were adjusted semi-automatically in the other dimensions (▶ **Fig. 1, 2**). This was done by two different readers blinded to the patient's swallowing function and all clinical information.

Statistical analysis

Univariable distribution of metric variables is described by median and interquartile range. Differences between CT and MRI muscle volumes were tested using a test of equivalence. We defined an equivalence range of $x = 200\ mm^3$. The two diagnostic modalities were defined as equivalent when the differences between CT and MRI volumes were less than x.

Accordingly, for each of the three muscles (i = 1/2: left/right anterior belly of the digastric muscle, i = 3: geniohyoid muscle), the following one-sided null hypotheses were tested by Wilcoxon signed-rank test on a multiple significance level of 5 %: "CT volume ≥ MRI volume + x" (H_{i+}) and "CT volume ≤ MRI volume – x" (H_{i-}). If null hypotheses H_{i+} and H_{i-} can both be rejected for some i, the level of deviation between both modalities is less than x for muscle i (|CT.vol – MRI.vol | < x) and consequently both modalities have been shown to be equivalent for muscle i.

Adjustment for multiple testing was performed using the closed testing procedure [5] with each intersection null hypothesis being tested using a Bonferroni test while taking into account that the intersection of null hypotheses H_{i+} and H_{i-} is empty for each i = 1, 2, 3.

In order to investigate a potential time effect on the muscle volumes, we calculated muscle volume differences between MRI and CT (Δ "MR-CT" volume in mm^3) for each muscle and assessed the correlation with the time interval between the modalities using Spearman's rho. Interrater reliability of the segmented muscle volumes was quantified using the intra-class correlation coefficient (ICC).

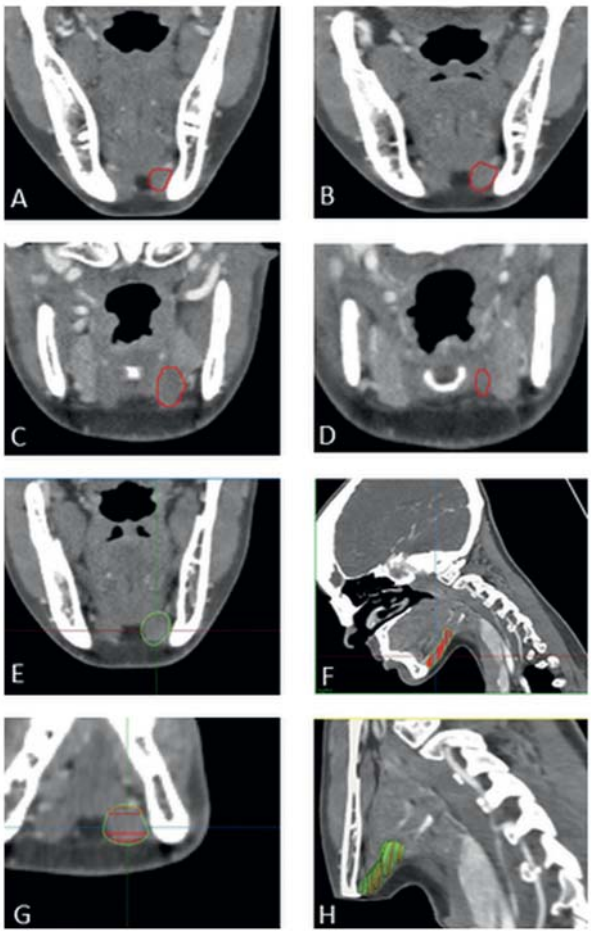

▶ **Fig. 1** CT segmentation process of the anterior body of the digastric muscle (left and right) and the geniohyoid muscle. **A–E** First the muscle was segmented slice by slice in coronal CT images (here exemplary the left digastric muscle). In the next step three-dimensional muscle volumes were calculated automatically using the programs interpolation function. **F, G** Finally the accuracy of the coronal segmentation was checked using the axial images and the sagittal multiplanar reconstructions. If necessary, corrections of the segmentation were performed using all three dimensions. Image **H** shows the 3 D visualization of the left digastric muscle as segmented before.

▶ **Abb. 1** Illustration der CT Volumetrie des Musculus digastricus und Musculus geniohyoideus. **A–E** Zunächst wurde der Muskel Schicht für Schicht in den coronalen CT-Bildern segmentiert (hier exemplarisch der linke Musculus digastricus). Im nächsten Schritt werden automatisch mittels Interpolationsfunktion des Programms 3-dimensionale Muskelvolumina berechnet. **F, G** Abschließend wird die Richtigkeit der coronalen Segmentierung in den axialen Schichten und den sagittalen Rekonstruktionen überprüft und gegebenenfalls korrigiert. **H** zeigt die 3D-Visualisierung des linken Musculus digastricus nach der Segmentation.

Statistical analyses were performed in SPSS version 24 (IBM Corporation, Armonk NY).

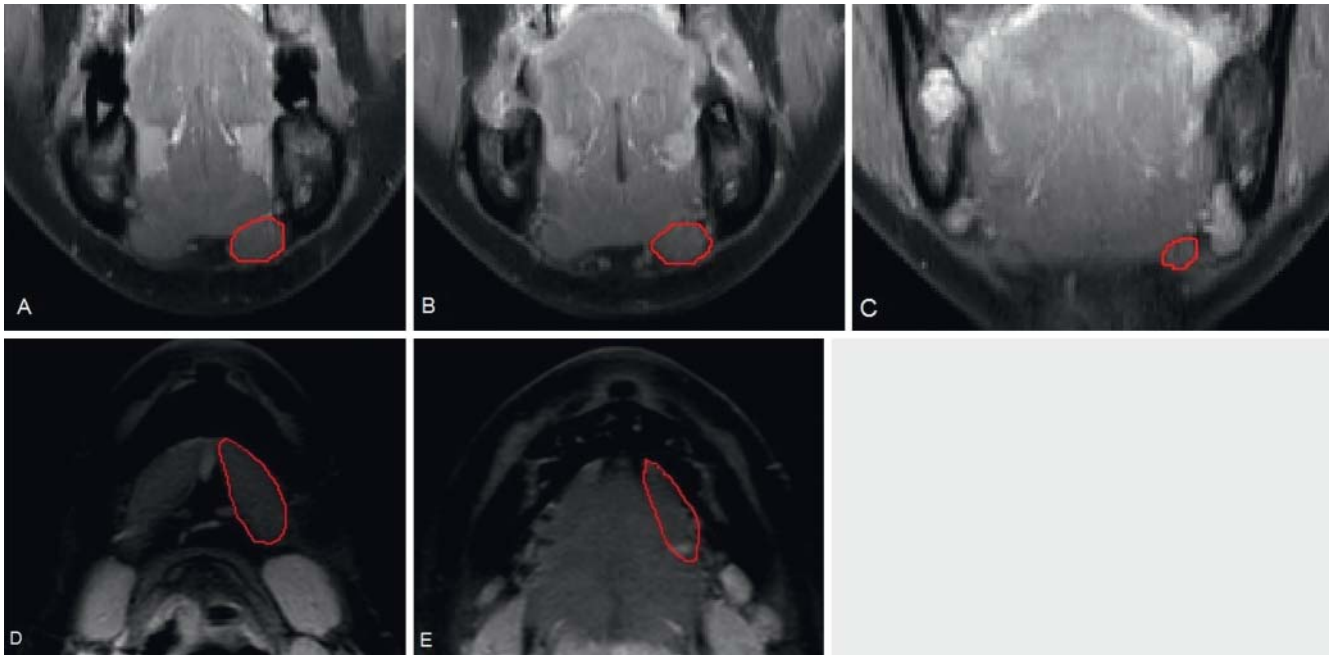

▶ **Fig. 2** MRI segmentation process of the anterior body of the digastric muscle (left and right) and the geniohyoid muscle. **A–C** Analog to CT, the muscle was segmented slice by slice in coronal MR images (here exemplary the left digastric muscle). **D, E** In the next step the accuracy of the coronal segmentation was checked using the axial images and if necessary corrections of the segmentation were performed.

▶ **Abb. 2** Illustration der MRT Volumetrie des Musculus digastricus und Musculus geniohyoideus. **A–C** Analog zum CT wurde der Muskel in den coronalen Sequenzen Schicht für Schicht volumetriert (hier exemplarisch der linke Musculus digastricus). **D, E** Im nächsten Schritt wurde die Genauigkeit der Segmentation in den axialen Schichten überprüft und anschließend gegebenenfalls Änderungen vorgenommen.

Results

All included patients had tumors of the head and neck region (14 laryngeal cancers, 6 pharyngeal cancers, 1 sarcoma).

The median volumes for each anterior belly of the digastric muscle derived from CT were 3051 mm^3 (left) and 2969 mm^3 (right), and those derived from MRI were 3218 mm^3 (left) and 3027 mm^3 (right). The median volume of the geniohyoid muscle was 6580 mm^3 on CT and 6648 mm^3 on MRI (▶ **Table 1**). Interrater reliability was high for all segmented muscles; values on CT were 0.996 (95 % confidence interval = 0.991; 0.999) for the left anterior belly of the digastric muscle, 0.994 (0.986; 0.998) for the right anterior belly of the digastric muscle and 0.998 (0.995; 0.999) for the geniohyoid muscle and for MRI they were 0.976 (0.942; 0.990); 0.998 (0.994; 0.999); 0.999 (0.998; 1.000), respectively.

All six null hypotheses regarding CT- and MRI-based segmentation could be rejected at a multiple significance level of 5 % (▶ **Table 2**).

The mean time interval between the CT and MRI examinations was 34 days (IQR 25; 41). The muscle differences of each muscle between the two modalities did not reveal a noticeable correlation to the time interval between the examinations ("MRI – CT" volume: left and right anterior bellies of the digastric muscle ($r = 0.003$ and $r = -0.008$) and the geniohyoid muscle ($r = 0.075$).

Discussion

This is the first study to correlate the measurement of swallowing muscles using CT and MRI images. We included the anterior part of the digastric muscles on both sides and the geniohyoid muscle for their good contrast and discrimination in both techniques. Our results show that volume segmentation in both techniques is equal within an equivalence range of $x = 200$ mm^3. Moreover, the high interrater reliability suggests a good reproducibility of our results in future studies.

So far, automated muscle segmentation has been used for example to quantify skeletal muscles of the abdomen and of the paravertebral lumbar muscles on CT and MR images [6, 7]. The technique we used has been established for more than a decade for different segmentation processes [8] including adipose tissue measurements [9] and segmentation of bone metastases [10]. In the clinical routine muscle segmentation can be useful especially when deployed automatically to determine whole-body muscle mass and thereby quantify the progress of chronic diseases or conditions, i. e., (autoimmune) myositis or sarcopenia [6, 7].

With regards to the swallowing musculature, previous studies used less precise CT-based two-dimensional parameters, in particular diameters of the geniohyoid muscle [1], CT-based evaluations of the density of the masseter and the medial pterygoid [11] and tongue thickness measurement with ultrasound [12].

Advantages of magnetic resonance imaging include better soft-tissue contrast compared with CT images allowing for better discrimination of above-mentioned muscles even for inexper-

▶ **Table 1** Comparison between CT and MRI muscle volumes of the anterior body of the digastric muscles (left and right) and the geniohyoid muscle.

muscle volumes in mm^3	median (IQR)	minimum	maximum
CT left anterior body of the digastric muscle, mm^3	3051 (2808; 3612)	912	4901
MRI left anterior body of the digastric muscle, mm^3	3092 (2555; 3463)	852	5552
CT right anterior body of the digastric muscle, mm^3	2969 (2787; 3618)	1412	5003
MRI right anterior body of the digastric muscle, mm^3	3027 (2665; 3580)	1305	5101
CT geniohyoid muscle, mm^3	6580 (5891; 8145)	2531	9012
MRI geniohyoid muscle, mm^3	6648 (5900; 8145)	2474	8985

CT = computed tomography; MRI = magnetic resonance imaging; IQR = interquartile range.

▶ **Table 2** Equivalence test of CT and MRI muscle volumes of the anterior body of the digastric muscles (left and right) and the geniohyoid muscle.

	muscle volume	CT volume, median (IQR)	MRI volume, median (IQR)	p-value of H_{i+}/H_{i-}
1	left anterior body of the digastric muscle, mm^3	3051 (2808; 3612)	3092 (2555; 3463)	0.001/0.001
2	right anterior body of the digastric muscle, mm^3	2969 (2787; 3618)	3027 (2665; 3580)	< 0.001/< 0.001
3	geniohyoid muscle, mm^3	6580 (5891; 8145)	6648 (5900; 8145)	< 0.001/< 0.001

For each of the three muscles (i = 1, 2, 3) the following one-sided null hypotheses were tested by Wilcoxon signed-rank test: "CT volume ≥ MRT volume + x" (H_{i+}) and "CT volume ≤ MRT volume – x" (H_{i-}). We defined an equivalence range of x = 200 mm^3. Given are multiplicity adjusted p-values for each null hypothesis.

ienced raters. CT and MRI images are both easily reproducible offering an objective follow-up for each patient. According to our results, the potential disadvantage of MRI with longer acquisition times potentially leading to more swallowing artifacts does not seem to be relevant for muscle segmentation processes. Although the coil used for MRI dictates the head position to some extent with the possible consequence of a decreased length of the submental muscle group, we did not observe a systematical bias when deploying a multi-dimensional segmentation approach.

Our findings have implications for swallowing research and clinical management of dysphagia. A previous study of our group that found an association between atrophy of the submental muscles, age and severity of dysphagia was based on CT [4]. However, prospective studies require noninvasive assessment without ionizing radiation. Quantifying decreases in submental muscle volumes may provide insight into the underlying mechanisms of dysphagia caused by sarcopenia (the degeneration of skeletal muscle associated with aging) or muscle weakness.

Some limitations of this study that are due to the retrospective nature of data acquisition need to be addressed. We chose coronal and axial T1- weighted images as the MRI images. Even though our results confirm the equality of CT and MRI segmentation, three-dimensional MR images would probably allow for even more accurate measurements and should therefore be deployed in future prospective studies. The period in between the CT and MRI scans may have presented another possible limitation. To minimize the chance of a relevant muscle gain or loss during this lag time, we included only patients with a relatively short time span of less than 50 days between the two examinations (median follow-up time in our study was 34 days). Therefore, in our study the time between the two examinations showed no relevant impact on the muscle volume differences of both methods.

CONCLUSION/CLINICAL RELEVANCE

CT-based segmentation and MRI-based segmentation of the digastric and geniohyoid muscle are equally feasible. The potential advantage of MRI for prospective studies is the absence of ionizing radiation.

Conflict of Interest

The authors declare that they have no conflict of interest.

References

[1] Feng X, Todd T, Lintzenich CR et al. Aging-related geniohyoid muscle atrophy is related to aspiration status in healthy older adults. J Gerontol A Biol Sci Med Sci 2013; 68: 853 – 860

[2] Macrae PR, Jones RD, Myall DJ et al. Cross-sectional area of the anterior belly of the digastric muscle: comparison of MRI and ultrasound measures. Dysphagia 2013; 28: 375 – 380

[3] Pearson WG Jr, Langmore SE, Zumwalt AC. Evaluating the structural properties of suprahyoid muscles and their potential for moving the hyoid. Dysphagia 2011; 26: 345 – 351

[4] Sporns P, Muhle P, Hanning U et al. Atrophy of Swallowing Muscles Is Associated With Severity of Dysphagia and Age in Patients With Acute Stroke. J Am Med Dir Assoc. 2017; 18: 635.e1 – 635.e7

[5] Marcus R, Peritz E, Gabriel K. On closed testing procedures with special reference to ordered analysis of variance. Biometrika 1976; 63: 655 – 660

[6] Jones KI, Doleman B, Scott S et al. Simple psoas cross-sectional area measurement is a quick and easy method to assess sarcopenia and predicts major surgical complications. Colorectal Dis 2015; 17: O20 – O26

[7] Sinelnikov A, Qu C, Fetzer DT et al. Measurement of skeletal muscle area: Comparison of CT and MR imaging. Eur J Radiol 2016; 85: 1716 – 1721

[8] Nolden M, Zelzer S, Seitel A et al. The Medical Imaging Interaction Toolkit: challenges and advances: 10 years of open-source development. Int J Comput Assist Radiol Surg 2013; 8: 607 – 620

[9] Wald D, Teucher B, Dinkel J et al. Automatic quantification of subcutaneous and visceral adipose tissue from whole-body magnetic resonance images suitable for large cohort studies. J Magn Reson Imaging 2012; 36: 1421 – 1434

[10] Bretschi M, Franzle A, Merz M et al. Assessing treatment response of osteolytic lesions by manual volumetry, automatic segmentation, and RECIST in experimental bone metastases. Acad Radiol 2014; 21: 1177 – 1184

[11] Newton JP, Yemm R, Abel RW et al. Changes in human jaw muscles with age and dental state. Gerodontology 1993; 10: 16 – 22

[12] Tamura F, Kikutani T, Tohara T et al. Tongue thickness relates to nutritional status in the elderly. Dysphagia 2012; 27: 556 – 561