Thieme

Metastatic duodenal germ cell tumor diagnosed with endoscopic ultrasound

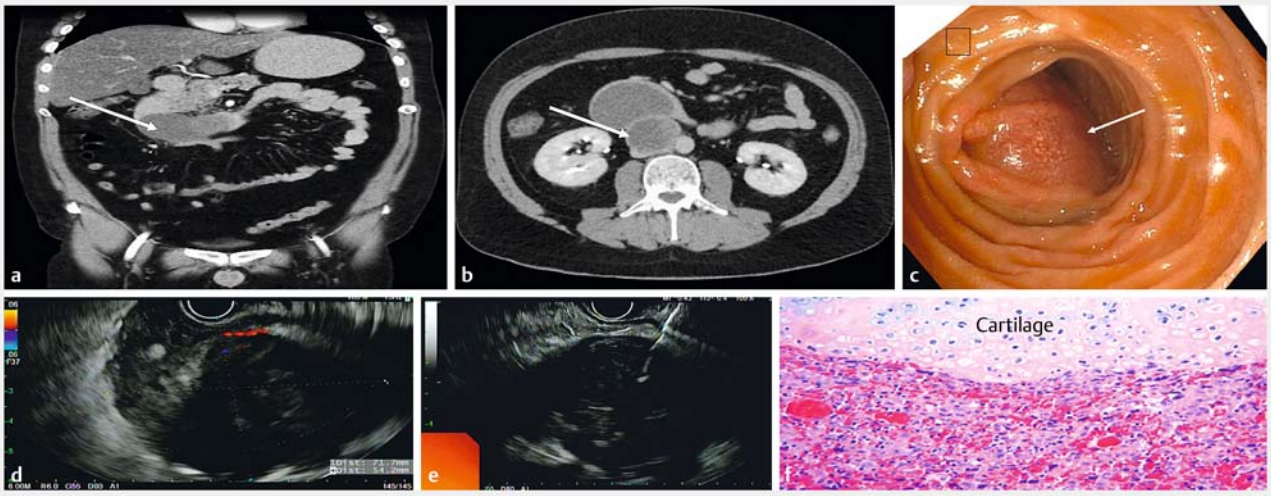

▶ **Fig. 1** Evaluation and diagnosis of a retroperitoneal mass. **a** Coronal computed tomography (CT) of the abdomen showed a retroperitoneal mass (arrow). **b** Transverse CT of the abdomen showed the same mass (arrow). **c** Upper endoscopy showed a subepithelial near-obstructive mass (arrow) in the second portion of the duodenum. **d** Endoscopic ultrasound showed a 7 × 5.4 cm solid cystic duodenal mass. **e** Fine-needle biopsy of the duodenal mass was performed. **f** Histology of the resected duodenal mass showed the presence of cartilage, consistent with mixed germ cell tumor.

Testicular tumors are the most common solid tumors reported in young males aged 15–35 years [1, 2]. These tumors frequently metastasize to retroperitoneal lymph nodes, but only 5% of these tumors seed the gastrointestinal (GI) tract [3, 4], with the duodenum being the least common site (1.4%) [4]. Local extension from the retroperitoneal lymph node into the GI tract is the common method of spread.

We report on a 44-year-old man with symptoms of gastric outlet obstruction. Computed tomography (CT) of the abdomen showed a bilobed retroperitoneal mass of 7 × 5 cm compressing the duodenum, suspicious for duplication cyst (▶ **Fig. 1 a, b**). Esophagogastroduodenoscopy showed a subepithelial near-obstructive mass in the second portion of the duodenum, which appeared cystic on palpation with closed forceps (▶ **Fig. 1 c**). Endoscopic ultrasound (EUS) showed a 7 × 5.4 cm solid cystic mass (▶ **Fig. 1 d**). Fine-needle biopsy (FNB) with a 22-gauge needle (▶ **Fig. 1 e**) revealed poorly differentiated epithelioid carcinoma, with unknown primary. Given the patient's age, testicular tumor was a highly likely differential diagnosis.

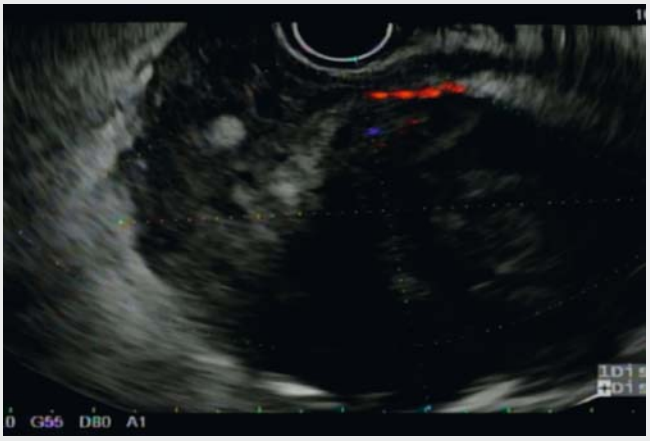

▶ **Video 1** A duodenal mass was evaluated by endoscopic ultrasound. Upon biopsy, the mass was shown to be a metastatic germ cell tumor from the testis.

The patient underwent pancreas-sparing duodenal resection. Histology showed a mixed germ cell tumor with unusual presence of cartilage (▶ **Fig. 1 f**). Ultrasound of the testes showed a 1.7 cm

This document was downloaded for personal use only. Unauthorized distribution is strictly prohibited.

right testicular mass, which was resected, and histology was consistent with mixed germ cell tumor. Staging revealed bony metastasis. The patient is currently undergoing chemotherapy.

This case highlights a testicular mixed germ cell tumor with metastasis to the duodenum, which is rare (1.4 %). In addition, hematogenous spread without the local involvement of the lymph nodes was noted, which is also a rare phenomenon. EUS-FNB confirmed a previously unsuspected malignancy, prompting a search for the primary and subsequent surgical management.

In young males with upper gastrointestinal tumors, metastasis from a testicular mass should always be considered. EUS-FNB can provide valuable information.

Endoscopy_UCTN_Code_CCL_1AF_2AG_3AD

Competing interests

None

The authors

Nayana George[1], Abhilash Perisetti[2], Saikiran Raghavapuram[1], Debdeep Banerjee[3], Enoch Kuo[4], Benjamin Tharian[1]

1 Division of Gastroenterology and Hepatology, Department of Internal Medicine, University of Arkansas for Medical Sciences, Little Rock, Arkansas, United States
2 Department of Family and Community Medicine, Texas Tech University Health Sciences Center, Lubbock, Texas, United States
3 Department of Medicine, University of Florida College of Medicine, Gainesville, Florida, United States
4 Department of Pathology, University of Arkansas for Medical Sciences, Little Rock, Arkansas, United States

Corresponding author

Saikiran Raghavapuram, MD
Division of Gastroenterology and Hepatology, Department of Internal Medicine, University of Arkansas for Medical Sciences, 4301 West Markham, slot # 509, Little Rock, AR-72205, United States
Fax: +1-501-526-4596
Saikiran6@gmail.com

References

[1] Konheim JA, Israel JA, Delacroix SE. Klinefelter syndrome with poor risk extragonadal germ cell tumor. Urol Case Rep 2016; 10: 1 – 3
[2] Fu S, Avezbakiyev B, Zhi W et al. Germ cell cancer presenting as gastrointestinal bleeding and developing brain metastases: case report and review of the literature. Future Oncol 2012; 8: 1487 – 1493
[3] Morinaga M, Osada T, Kon K et al. Metastatic seminoma in the duodenum: diagnosis with endoscopy followed by successful treatment. Intern Med 2014; 53: 2777 – 2781
[4] Bain AJ, Owens DJ, Savides TJ. Image of the month. Upper gastrointestinal bleeding caused by metastatic testicular choriocarcinoma. Clin Gastroenterol Hepatol 2009; 8: A22

Bibliography
DOI https://doi.org/10.1055/s-0043-119979
Published online: 10.11.2017
Endoscopy 2018; 50: E27–E28
© Georg Thieme Verlag KG
Stuttgart · New York
ISSN 0013-726X

ENDOSCOPY E-VIDEOS
https://eref.thieme.de/e-videos

Endoscopy E-Videos is a free access online section, reporting on interesting cases and new techniques in gastroenterological endoscopy. All papers include a high quality video and all contributions are freely accessible online.

This section has its own submission website at https://mc.manuscriptcentral.com/e-videos

This document was downloaded for personal use only. Unauthorized distribution is strictly prohibited.