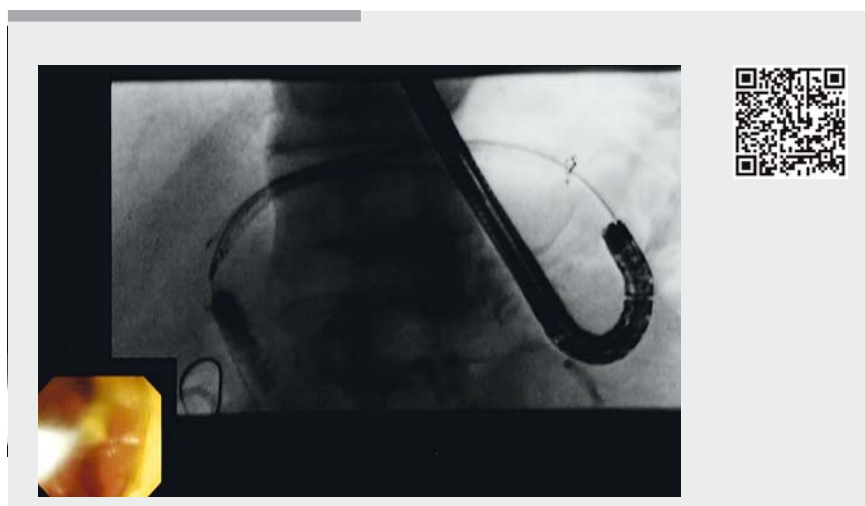


## Rescue antegrade diathermic dilation of hyperplastic tissue at partially covered metallic stent after EUS-guided hepaticogastrostomy

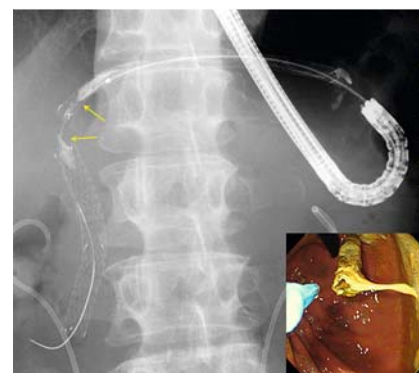Endoscopic ultrasonography-guided antegrade stenting (EUS-AGS) and EUS-guided hepaticogastrostomy (EUS-HGS) are suitable for obstructive jaundice associated with gastric outlet obstruction or surgically altered anatomy [1]. Recently, a long partially covered self-expandable metallic stent (LPC-SEMS) has been developed to prevent stent migration and bile leakage and allow safe and effective EUS-HGS. However, one disadvantage of the LPC-SEMS is tissue hyperplasia at the uncovered portion of the stent [2]. Here, we present the case of a patient who underwent a rescue procedure using antegrade diathermic dilation for hyperplastic tissue occlusion of an LPC-SEMS and for tumor ingrowth into an uncovered SEMS placed for EUS-AGS. A 60-year-old man with unresectable gastric cancer was admitted with gastric outlet obstruction and obstructive jaundice. He had undergone EUS-AGS using an uncovered metallic stent and EUS-HGS using a LPC-SEMS (diameter 6 mm, length 120 mm, uncovered proximal portion 10 mm; Taewoong Medical, Seoul, Korea). He again developed obstructive jaundice 7 months later. Antegrade cholangiography via the LPC-SEMS revealed perihilar bile duct stricture due to hyperplasia at the LPC-SEMS (► Fig. 1). It was not possible to pass a tapered endoscopic retrograde cholangiopancreatography (ERCP) catheter through the stricture (► Video 1). We successfully dilated the stricture using 6-Fr wire-guided diathermic dilation (Cysto-Gastro-Set; Endo-Flex, Voerde, Germany) (► Fig. 2, ► Video 1). Antegrade cholangiography showed free drainage through the previously hyperplastic area at the uncovered portion of the stent. No stent was placed as the previously occluded LPC-SEMS was now patent (► Fig. 3). Subsequent antegrade cholangiography revealed occlusion of the uncovered metallic stent due to tumor ingrowth



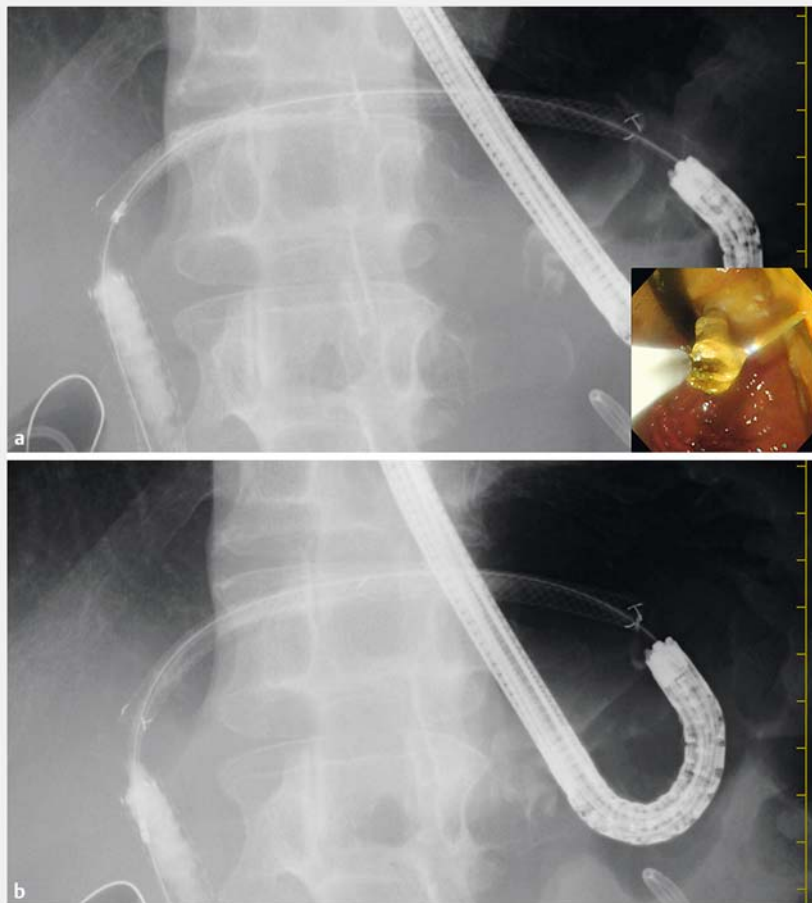
► **Video 1** Antegrade diathermic dilation and stenting technique to treat: (i) hyperplastic tissue occlusion of a long partially covered self-expanding metal stent (LPC-SEMS); and (ii) recurrent distal biliary obstruction by tumor ingrowth into an uncovered SEMS, following endoscopic ultrasonography-guided hepaticogastrostomy and antegrade stenting 7 months previously in a 60-year-old man.

(► Fig. 4a). Passage was successfully obtained with antegrade diathermic dilation (► Fig. 4b). Finally, an ultraslim uncovered SEMS (BileRush Selective, 5.7-Fr, diameter 10 mm; Piolax Medical Devices, Kanagawa, Japan) was placed using a stent-in-stent method, without complications (► Fig. 5, ► Video 1). Recurrent biliary obstruction caused by tissue hyperplasia is an unresolved major problem of the LPC-SEMS, and the optimal rescue technique has not been established. EUS-guided antegrade diathermic dilation has been recently reported [3–5]. To our knowledge, this is the first report of rescue for hyperplastic tissue occlusion of an LPC-SEMS that used wire-guided antegrade diathermic dilation with no need for secondary stenting. This rescue technique is a useful method of recanalization of an LPC-SEMS occluded by hyperplastic tissue.

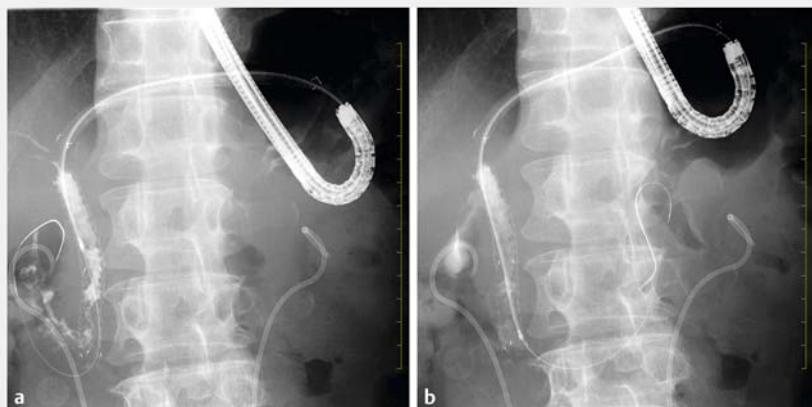
Endoscopy\_UCTN\_Code\_CPL\_1AK\_2AC



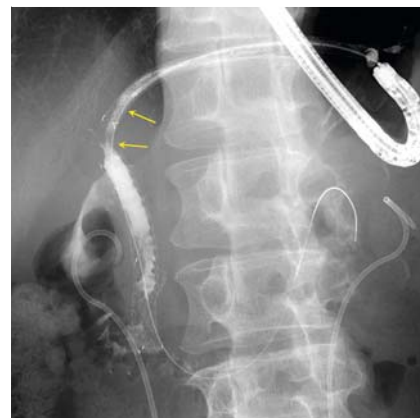► **Fig. 1** Radiographic image from a 60-year-old man, showing perihilar bile duct stricture due to hyperplasia (arrows) at the long partially covered self-expandable metallic stent (LPC-SEMS), after endoscopic ultrasonography-guided hepaticogastrostomy 7 months earlier (inset: endoscopic image).



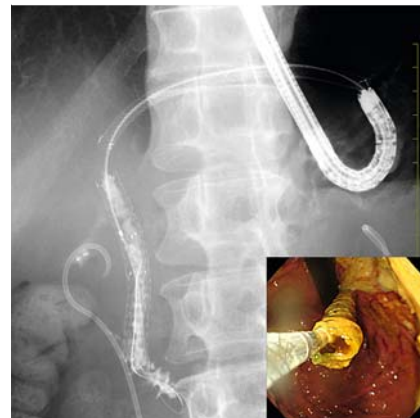► **Fig. 2** Radiographic image showing wire-guided antegrade diathermic dilation for hyperplastic tissue at the LPC-SEMS. **a** Before diathermic dilation; inset: endoscopic image. **b** After diathermic dilation.



► **Fig. 4** Radiographic images: **a** Tumor ingrowth in the uncovered self-expandable metallic stent in the distal bile duct, placed at endoscopic ultrasonography-guided antegrade procedure 7 months earlier. **b** Wire-guided antegrade diathermic dilation for the tumor ingrowth.



► **Fig. 3** Radiographic image showing free drainage through the previously hyperplastic area (arrows) at the uncovered portion of the LPC-SEMS after wire-guided antegrade diathermic dilation.



► **Fig. 5** Radiographic image showing antegrade placement of ultraslim uncovered self-expandable metallic stent using the stent-in-stent method (inset: endoscopic image).

### Competing interests

Dr. Kawakami is a consultant to and gives lectures for Piolax Medical Devices, Kanagawa, Japan. The other authors declare no conflict of interests for this article.

### The Authors

**Hiroshi Kawakami**<sup>1,2</sup>, **Yoshimasa Kubota**<sup>1,2</sup>, **Tesshin Ban**<sup>1,2</sup>

1 Department of Gastroenterology and Hepatology, Faculty of Medicine, University of Miyazaki, Miyazaki, Japan

2 Center for Digestive Disease, University of Miyazaki Hospital, Miyazaki, Japan

## Corresponding author

### Hiroshi Kawakami, MD, PhD

Department of Gastroenterology and Hepatology, Faculty of Medicine, University of Miyazaki, 5200 Kihara, Kiyotake, Miyazaki, Miyazaki 889-1692, Japan  
Fax: +81-985-859802  
hiropon@med.miyazaki-u.ac.jp

## References

- [1] Kawakami H, Kubota Y. Endoscopic ultrasonography-guided antegrade stenting combined with hepaticogastrostomy/hepaticojejunostomy using ultraslim instruments. *Endoscopy* 2017; 49: E88 – E89
- [2] Nakai Y, Isayama H, Yamamoto N et al. Safety and effectiveness of a long, partially covered metal stent for endoscopic ultrasound-guided hepaticogastrostomy in patients with malignant biliary obstruction. *Endoscopy* 2016; 48: 1125 – 1128

- [3] Kawakami H, Kuwatani M, Sakamoto N. Endoscopic ultrasound-guided antegrade diathermic dilation followed by self-expandable metallic stent placement for anastomotic stricture after hepaticojejunostomy (with video). *Dig Endosc* 2014; 26: 121 – 122
- [4] Kawakami H, Kuwatani M, Kawakubo K et al. Endoscopic ultrasound-guided antegrade diathermic dilation followed by self-expandable metal stent placement for malignant distal biliary stricture. *Endoscopy* 2014: UCTN: 46 (Suppl. 01): E328 – E329
- [5] Kawakami H, Kuwatani M, Kawakubo K et al. Endoscopic ultrasonography-guided antegrade diathermic dilation for the treatment of complete obstruction of a pancreaticogastrostomy. *Endoscopy* 2014: UCTN: 46 (Suppl. 01): E517 – E518

## Bibliography

DOI <https://doi.org/10.1055/s-0043-117941>  
Published online: 13.9.2017  
*Endoscopy* 2017; 49: E285–E287  
© Georg Thieme Verlag KG  
Stuttgart · New York  
ISSN 0013-726X

## ENDOSCOPY E-VIDEOS <https://eref.thieme.de/e-videos>



*Endoscopy E-Videos* is a free access online section, reporting on interesting cases and new techniques in gastroenterological endoscopy. All papers include a high quality video and all contributions are freely accessible online.

This section has its own submission website at  
<https://mc.manuscriptcentral.com/e-videos>