

Endoscopic ultrasonography-guided photodynamic therapy for recurrent intraductal papillary mucinous neoplasm of the pancreas

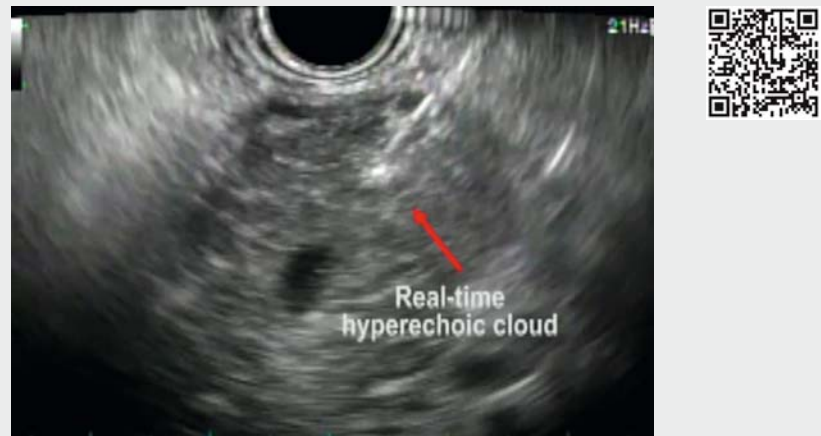Recurrence rates after partial pancreatectomy in patients with a noninvasive intraductal papillary mucinous neoplasm (IPMN) of the pancreas are reported as being 5.4% to 10.7% [1–3]. A recent case demonstrated the possibility of using photodynamic therapy (PDT) as an alternative therapeutic option for IPMN [4]. Herein, we present a patient who was treated with endoscopic ultrasonography (EUS)-guided PDT, which was used as an alternative, minimally invasive option for recurrent IPMN of the pancreas.

A 50-year-old man was admitted with recurrent pancreatitis. He had a history of distal pancreatectomy for combined-type IPMN 2 years previously, and the resection margins had been positive. A computed tomography (CT) scan revealed swelling of the remnant pancreas with a 13-mm hypodense lesion and prominent main pancreatic duct (MPD) dilatation. EUS-guided needle biopsy of a 5-mm nodular lesion in the MPD and a 15-mm hypoechoic mass in the stump demonstrated recurrent IPMN with low grade dysplasia (► **Fig. 1**). The patient re-

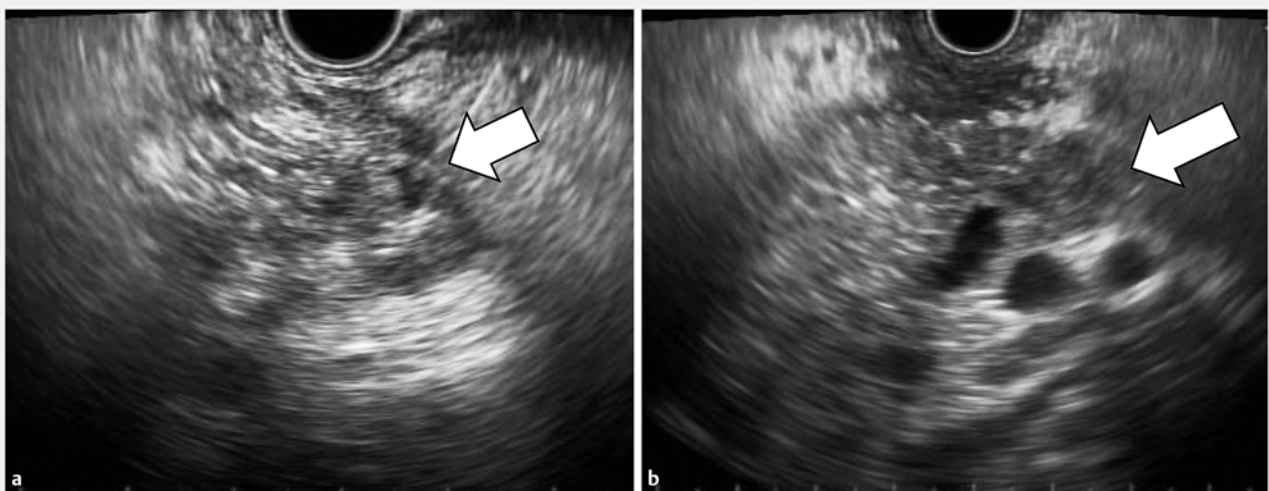
fused to undergo total pancreatectomy, so we decided to perform EUS-guided PDT (► **Video 1**) [5].

Photolon (a chlorin e6 derivative; Belmedpreparaty, Belarus) was administered at a dose of 2.5 mg/kg, 3 hours be-

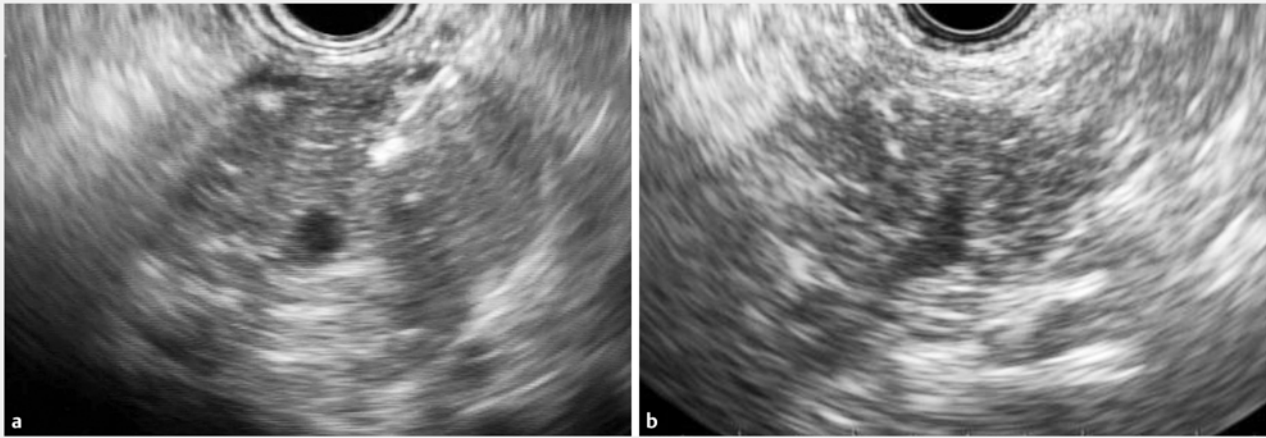
fore the procedure. The flexible laser-light probe (a quartz core and polymer cladding; PhotoGlow Inc., Yarmouth, Massachusetts, USA) was preloaded inside a 19G EUS fine needle aspiration (FNA) needle (Cook Endoscopy, Winston-



► **Video 1** Endoscopic ultrasonography-guided photodynamic therapy for recurrent non-invasive intraductal papillary mucinous neoplasm (IPMN) of the pancreas following a previous distal pancreatectomy.



► **Fig. 1** Endoscopic ultrasonography (EUS) image showing: **a** a 5-mm nodular lesion in the main pancreatic duct; **b** a 15-mm hypoechoic mass in the stump.



► **Fig. 2** Endoscopic ultrasonography (EUS) images showing: **a** a hyperechoic cloud in the area surrounding the laser diffuser tip during EUS-guided photodynamic therapy (PDT); **b** no evidence of tumor recurrence 2 years after the PDT.

Salem, North Carolina, USA) and was inserted into the recurrent tumor. The tumor was then illuminated with a wavelength of 660 nm (► **Fig. 2 a**). The energy dose was 100 J/cm of the diffuser length; the power of irradiation was 400 mW/cm of the diffuser length in each procedure. The total irradiation time in each needle pass was 250 seconds.

At follow-up EUS 2 years after the PDT, there was no evidence of recurrence (► **Fig. 2 b**). EUS-guided biopsy at the pancreas stump showed only acinar cells and interstitial fibrosis. The patient experienced no further episodes of pancreatitis during the follow-up period. This study was approved by the Institutional Review Board of Asan Medical Center (IRB number: 2015-0111).

Endoscopy_UCTN_Code_TTT_1AS_2AD

Competing interests

None

The Authors

Sun-Ho Lee^{*}, Hoonsub So^{*}, Seungwhan Shin, Nah Kyum Lee, Do Hyun Park

Division of Gastroenterology, Department of Internal Medicine, University of Ulsan College of Medicine, Asan Medical Center, Seoul, South Korea

* Contributed equally to this article

Corresponding author

Do Hyun Park, MD, PhD

Division of Gastroenterology, Department of Internal Medicine, University of Ulsan College of Medicine, Asan Medical Center, 88, Olympic-Ro 43-Gil, Songpa-Gu, Seoul 05505, Korea
Fax: +82-2-4760824
dhpark@amc.seoul.kr

References

- [1] Kang MJ, Jang JY, Lee KB et al. Long-term prospective cohort study of patients undergoing pancreatectomy for intraductal papillary mucinous neoplasm of the pancreas: implications for postoperative surveillance. *Ann Surg* 2014; 260: 356–363
- [2] Passot G, Lebeau R, Hervieu V et al. Recurrences after surgical resection of intraductal papillary mucinous neoplasm of the pancreas: a single-center study of recurrence predictive factors. *Pancreas* 2012; 41: 137–141
- [3] Schnelldorfer T, Sarr MG, Nagorney DM et al. Experience with 208 resections for intraductal papillary mucinous neoplasm of the pancreas. *Arch Surg* 2008; 143: 639–646; discussion 646
- [4] Topazian M, Zhong N, Baron TH et al. Photodynamic therapy of intraductal papillary mucinous neoplasm. *Endoscopy* 2012; 44: 213–215
- [5] Choi JH, Oh D, Lee JH et al. Initial human experience of endoscopic ultrasound-guided photodynamic therapy with a novel photosensitizer and a flexible laser-light catheter. *Endoscopy* 2015; 47: 1035–1038

Bibliography

DOI <https://doi.org/10.1055/s-0043-117938>
Published online: 2017
Endoscopy
© Georg Thieme Verlag KG
Stuttgart · New York
ISSN 0013-726X

ENDOSCOPY E-VIDEOS <https://eref.thieme.de/e-videos>



Endoscopy E-Videos is a free access online section, reporting on interesting cases and new techniques in gastroenterological endoscopy. All papers include a high quality video and all contributions are freely accessible online.

This section has its own submission website at
<https://mc.manuscriptcentral.com/e-videos>