Thieme

Linked color imaging (LCI), a novel image-enhanced endoscopy technology, emphasizes the color of early gastric cancer

OPEN ACCESS

Authors
Hiromitsu Kanzaki[1], Ryuta Takenaka[2], Yoshiro Kawahara[3], Daisuke Kawai[2], Yuka Obayashi[1], Yuki Baba[1], Hiroyuki Sakae[1], Tatsuhiro Gotoda[1], Yoshiyasu Kono[1], Ko Miura[1], Masaya Iwamuro[1], Seiji Kawano[1], Takehiro Tanaka[4], Hiroyuki Okada[1,3]

Institutions
1 Department of Gastroenterology and Hepatology, Okayama University Graduate School of Medicine, Dentistry, and Pharmaceutical Sciences, Okayama, Japan
2 Department of Gastroenterology, Tsuyama Chuo Hospital, Tsuyama, Japan
3 Department of Endoscopy, Okayama University Hospital, Okayama, Japan
4 Department of Pathology, Okayama University Hospital, Okayama, Japan

submitted 20.3.2017
accepted after revision 30.6.2017

Bibliography
DOI https://doi.org/10.1055/s-0043-117881 |
Endoscopy International Open 2017; 05: E1005–E1013
© Georg Thieme Verlag KG Stuttgart · New York
ISSN 2364-3722

Corresponding author
Dr. Hiromitsu Kanzaki, Department of Gastroenterology and Hepatology, Okayama University Graduate School of Medicine, Dentistry, and Pharmaceutical Sciences, 2-5-1 Shikata-cho, Kita-ku, Okayama 700-8558, Japan
kanzaki@qc4.so-net.ne.jp

ABSTRACT

Background and study aims Linked color imaging (LCI) and blue laser imaging (BLI) are novel image-enhanced endoscopy technologies with strong, unique color enhancement. We investigated the efficacy of LCI and BLI-bright compared to conventional white light imaging (WLI) by measuring the color difference between early gastric cancer lesions and the surrounding mucosa.

Patients and methods Images of early gastric cancer scheduled for endoscopic submucosal dissection were captured by LCI, BLI-bright, and WLI under the same conditions. Color values of the lesion and surrounding mucosa were defined as the average of the color value in each region of interest. Color differences between the lesion and surrounding mucosa (ΔE) were examined in each mode. The color value was assessed using the CIE L*a*b* color space (CIE: Commission Internationale d'Eclairage).

Results We collected images of 43 lesions from 42 patients. Average ΔE values with LCI, BLI-bright, and WLI were 11.02, 5.04, and 5.99, respectively. The ΔE was significantly higher with LCI than with WLI ($P<0.001$). Limited to cases of small ΔE with WLI, the ΔE was approximately 3 times higher with LCI than with WLI (7.18 vs. 2.25). The ΔE with LCI was larger when the surrounding mucosa had severe intestinal metaplasia ($P=0.04$). The average color value of a lesion and the surrounding mucosa differed. This value did not have a sufficient cut-off point between the lesion and surrounding mucosa to distinguish them, even with LCI.

Conclusion LCI had a larger ΔE than WLI. It may allow easy recognition and early detection of gastric cancer, even for inexperienced endoscopists.

Introduction

Gastric cancer is the fifth most common cause of cancer-related mortality in the world [1]. Despite advances in chemotherapy, the overall survival of patients with gastric cancer remains poor. To improve the prognosis, detection at an early stage is necessary [2]. Screening esophagogastroduodenoscopy is an effective examination for the early detection of gastric cancer [3–5].

Early gastric cancer involves only slight morphological findings and color differences in relation to the surrounding mucosa. As the difference is subtle, it is difficult for physicians who are unfamiliar with the diagnosis of early gastric cancer and even expert endoscopists to detect it [6, 7].

Several reports have demonstrated the efficacy of equipment-based image-enhanced endoscopy (IEE) for diagnosing and detecting early gastrointestinal cancer [8 – 10]. Its superiority results from the enhancement of the lesion color and ability to demarcate the lesion and surrounding mucosa. The efficacy of magnified endoscopy with IEE for the diagnosis of early gastric cancer has been widely reported [11 – 14]. There have been reports of the advantages of IEE without magnification, but these were a pilot study and a small sample group [15, 16]. The efficacy of IEE without magnification for the detection of early gastric cancer is still controversial. This lack of information is possibly because of the subtle color difference between gastric cancer lesions and the surrounding mucosa, even with IEE.

Linked color imaging (LCI) and blue laser imaging (BLI) are novel IEE technologies developed by Fujifilm Corporation (Tokyo, Japan). These endoscopic technologies use narrowband short wavelength light. Blue and green color information and red color information are separately corrected. BLI uses blue and green color information to produce red color-enhanced images, as in narrowband imaging (NBI). LCI uses the information of all three colors. Unlike conventional white light imaging (WLI), the captured image is output with color enhancement in its own color range (e. g., red is changed to vivid red and white to clear white) by unique image processing [17 – 21].

We speculated that this novel IEE system could produce a larger color difference between an early gastric cancer lesion and the surrounding mucosa. This difference may allow the early recognition of a lesion, even for less experienced physicians. Moreover, we speculated that the unique color of cancer could be determined by using LCI.

In this study, we investigated the visibility of early gastric cancer in each mode by evaluating the color difference between the cancer lesion and surrounding mucosa. We attempted to determine a cancer's unique color with LCI by measuring the color value of the lesion and surrounding mucosa.

Patients and methods

This study was conducted as a retrospective image analysis study. Patients who were examined using the LASEREO system (FujiFilm Corporation) before they underwent endoscopic submucosal dissection (ESD) at Okayama University Hospital (Okayama City, Japan) and Tsuyama Chuo Hospital (Tsuyama, Japan) from October 2014 to January 2016 were included in this study.

The ethical review boards of Okayama University Hospital and Tsuyama Chuo Hospital approved this retrospective chart review and analysis of the procedural data used in this study.

Instruments

The LASEREO system (Fujifilm, Tokyo, Japan) with an upper gastrointestinal endoscope (EG-L590ZW; Fujifilm) was used in this study. This endoscopy system uses 410-nm and 450-nm narrowband lasers instead of the conventional Xenon lamp, and produces three modes of IEE in addition to the conventional WLI: BLI, BLI-bright, and LCI. The 450-nm wavelength light excites a phosphor in the tip of the scope to produce a wide wavelength light. The 410-nm wavelength light is a narrowband blue light that is strongly absorbed by a red object; therefore, this light is used to enhance red-colored objects. Blue and green information and red information are separately corrected by a charge-coupled device sensor in the tip of the scope. A BLI image consists of the blue and green information from the narrowband blue light illumination and produces red-enhanced images. The BLI-bright mode has sufficient light quantity with narrowband blue light to brighten a wide organ, such as the stomach, while producing a BLI-like image that enhances blood vessels on the surface of the mucosa [22]. An LCI image is acquired by the same illumination as BLI-bright. However, further image processing is carried out so that it has an appearance similar to WLI and that its colors are displayed more vividly (e. g., red is changed to vivid red and white to clear white). The IEE modes can be instantly changed using a button on the endoscopy handle. In this study, the WLI, BLI-bright, and LCI modes were used.

Image acquisition

We captured the early gastric cancer lesion images under the same conditions with WLI, BLI-bright and LCI. The endoscopic images of each lesion were captured carefully from a mid-range distance in WLI, BLI-bright, and LCI modes such that a similar distance and overall lightness were achieved in all the images taken in each mode. The border line of cancer and normal mucosa was captured with magnification in BLI. The images were taken by three expert endoscopists (Okayama University Hospital: HK and YK, Tsuyama Chuo hospital: RT).

Image selection

One image from each mode (i. e., WLI, BLI-bright, and LCI) was selected per lesion (▶ **Fig. 1**). The cases that met any of the following conditions were excluded: an image of a lesion not taken at the mid-range distance in all three IEE modes; an image for which mucosal color analysis was difficult because of an unusual color occupying the dominant area of the region of interest (ROI), such as an attachment of blood or pus or halation and shadow; lesion considered to be primarily an adenoma; lesion larger than 30 mm; and remnant stomach.

Image processing and color analysis

The color processing and analysis was performed with Adobe Photoshop CS4 (Adobe Systems Inc., San Jose, California, United States). The algorithm used to locate the ROI in the selected image is shown in ▶ **Fig. 2**. First, the border line between the lesion and surrounding mucosa was drawn on the image in reference to the histological examination of the ESD-resected tissue and many other endoscopic images captured through the procedure including with magnification. Second, an outside line was drawn parallel to the border line; the area enclosed by this line was twice as large as the area enclosed by the border line. Third, an inside line was drawn parallel to the border line; the

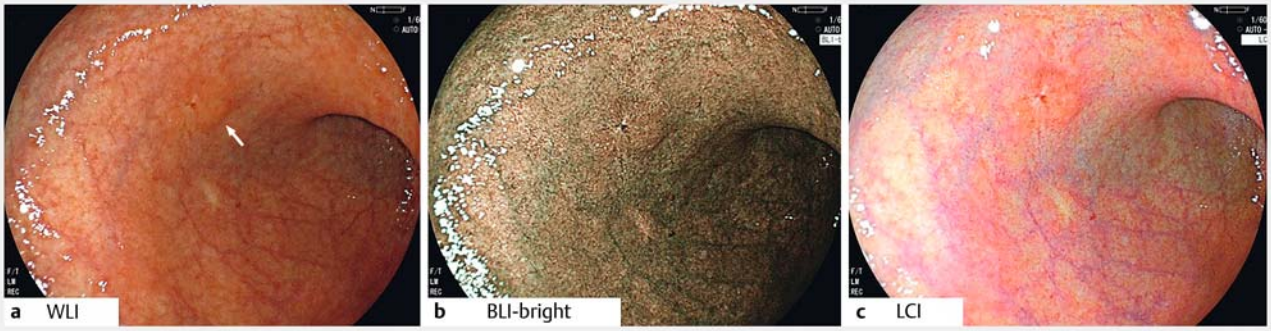

▶ **Fig. 1** Imaging characteristics of the linked color imaging (LCI) and blue laser imaging (BLI)-bright modes.

width between the border line and the inside line was the same as the width between the outside line and the border line. A rectangle was drawn in the center of the lesion along the same illuminance axis with a width 1/4 to 1/3 as large as the width of the lesion. The axis of the rectangle was also set to avoid unusual color areas like shadow in the ROI of the surrounding mucosa. The ROI of the lesion and surrounding mucosa was the area enclosed by these lines. All the WLI, BLI-bright and LCI images underwent this image processing (▶ **Fig. 3**).

Small areas of unusual color due to attachment of mucus, bleeding, or halation were partially excluded from the ROI. The color values of the lesion (L^*_l, a^*_l, b^*_l) and surrounding mucosa (L^*_s, a^*_s, b^*_s) were defined as the average of the color value in each ROI using the CIE L*a*b* color space (CIE: Commission Internationale d'Eclairage) developed by the International Commission on Illumination in 1976 [23] (▶ **Fig. 4**). The color value was expressed with the three-dimensional color parameters L* (black to white; range, 0 to + 100), a* (green to red; range, – 128 to + 127), and b* (blue to yellow; – 128 to + 127). A positive value represented a shift toward white in axis L*, red in axis a*, and yellow in axis b*, which represent all colors visible to the human eye [24, 25]; in other words, the CIE L*a*b* color model approximates human color perception. The relative perceptual differences between any two colors can be approximated by the color distance between them, as expressed by the CIE L*a*b* color value (i. e., L*, a*, and b*). The color difference between the lesion and surrounding mucosa (ΔE) is expressed by the following equation:

$$\Delta E = \sqrt{(L^*_l - L^*_s)^2 + (a^*_l - a^*_s)^2 + (b^*_l - b^*_s)^2}$$

The ΔE is expressed according to the evaluation criterion of the National Bureau of Standards (NBS) units of color difference (▶ **Table 1**). The ΔE was converted to NBS units using the following formula [26]: NBS units = ΔE × 0.92.

The ΔE in each mode was calculated and compared to that of WLI. The relationship between the ΔE and background factors of the patients and lesions was investigated in each mode.

The average color value of the lesion and surrounding mucosa was measured and compared in each mode to investigate the cancer's unique color.

Evaluation of background factors

The evaluation of endoscopic atrophy was based on the Kimura-Takemoto classification [27] and regarded as mild for C-I and C-II, moderate for C-III and O-I, and severe for O-II and O-III.

ESD was performed for all lesions that were used in this study. Resected specimens were step-sectioned lengthwise at 2-mm intervals [28] and then stained with hematoxylin and eosin for the histological examination. We evaluated the morphologic type, lesion size, histological type, histological assessment of inflammation, atrophy and intestinal metaplasia of the surrounding mucosa, based on the updated Sydney System [29]. A score of 1 or below was classified as mild, and a score of 2 or above was classified as severe. An expert pathologist performed all histological assessments.

To assess patients' *Helicobacter pylori* (H. pylori) status, at least 2 of the following examinations were performed in all patients: histological evaluation, bacterial culture, urea breath test, and serological *H. pylori* antibody test. We defined patients with positive *H. pylori* test results as having present *H. pylori* status. As *H. pylori* infection leads to intestinal metaplasia [30], patients with negative *H. pylori* test results and intestinal metaplasia in the surrounding mucosa were regarded as being in the post-infection phase. Patients with negative *H. pylori* test result and no intestinal metaplasia were defined as not infected.

Statistics

All statistical analyses were performed with statistical software (JMP PRO, version 12; SAS Institute Inc., Cary, North Carolina, United States). The relationship between the color difference and background factor in each mode was compared using the Student's t-test. A comparison of the color difference between WLI and the other modes, and the color value between the lesion and the surrounding mucosa was examined using the Wilcoxon signed-rank test. The cut-off point of the color value between the lesion and surrounding mucosa was determined by receiver operator characteristics curve (ROC) analysis. A two-sided $P < 0.05$ was considered statistically significant.

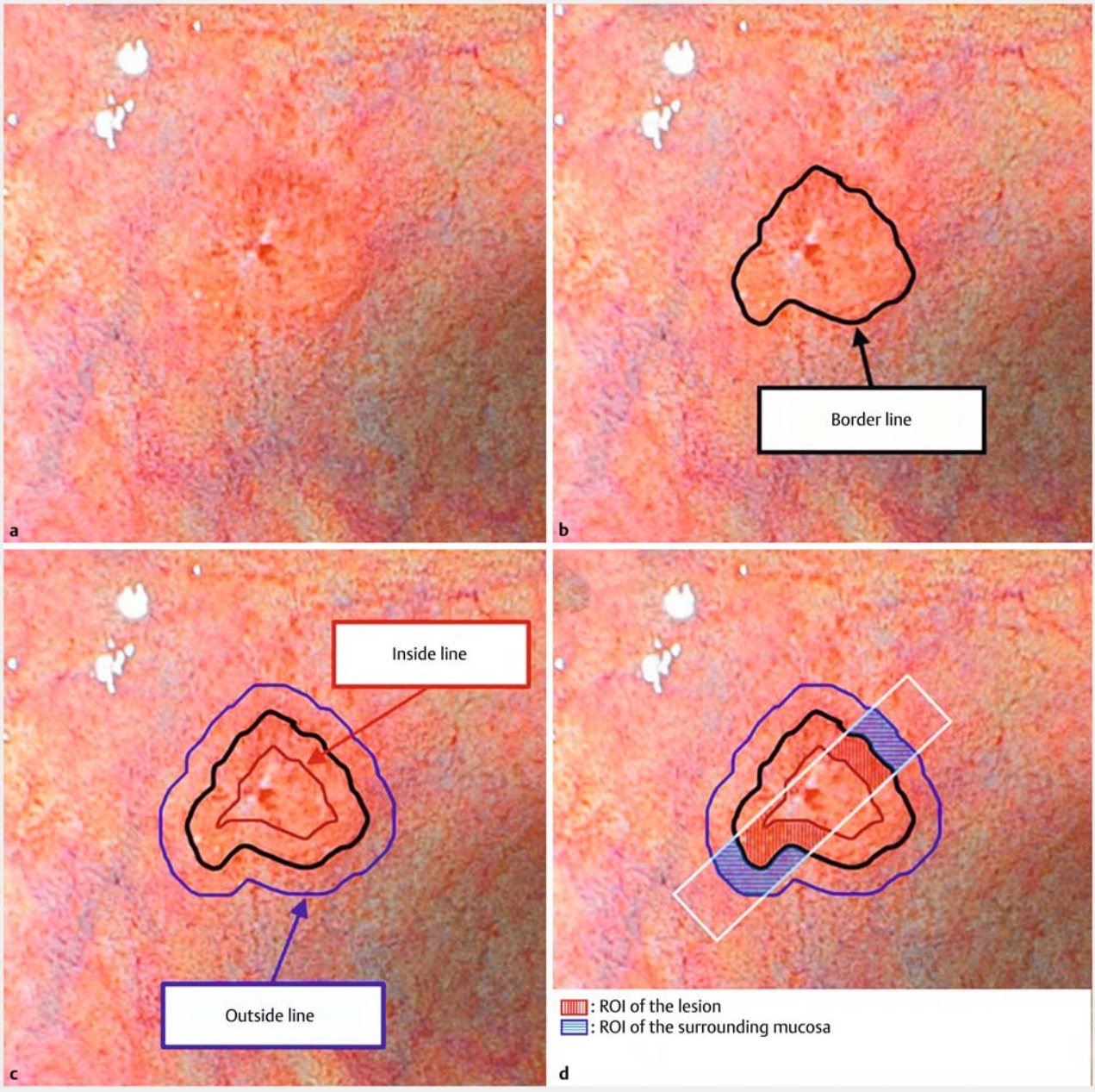

▶ **Fig. 2** Image processing method used in the current study. **a** The image of the lesion is prepared, and the area of interest is extracted. **b** The border line between the lesion and surrounding mucosa was drawn based on the histological examination of the resected tissue using endoscopic submucosal dissection and other endoscopic images captured through the procedure including with magnification. **c** The inside and outside lines are drawn equidistant from the border line. **d** A rectangle intersecting the lesion along the minor axis of the stomach is drawn. The regions of interest (ROI) of the lesion and the surrounding mucosa are enclosed within these lines. The color value of the lesion and surrounding mucosa is represented by the average value within each ROI. The color difference between the lesion and surrounding mucosa (ΔE) is the difference between the averaged color value in the ROI of the lesion and the ROI of the surrounding mucosa.

Results

From October 2014 to January 2016, 101 lesions from 98 patients were examined using the LASEREO system before ESD at Okayama University Hospital and Tsuyama Chuo Hospital by three expert endoscopists. Almost half of the cases were excluded, and that was mainly because of the presence of shadow, halation, or adhesion of blood and pus in the ROI. The images of 43 lesions from 42 patients met our inclusion criteria and were sent for color analysis (▶ **Fig. 5**).

The patient and lesion characteristics in this study are shown in ▶ **Table 2**. The average ΔE values with WLI, BLI-bright, and LCI were 5.99, 5.04, and 11.02, respectively (▶ **Table 3**). The ΔE value with LCI was significantly higher and approximately

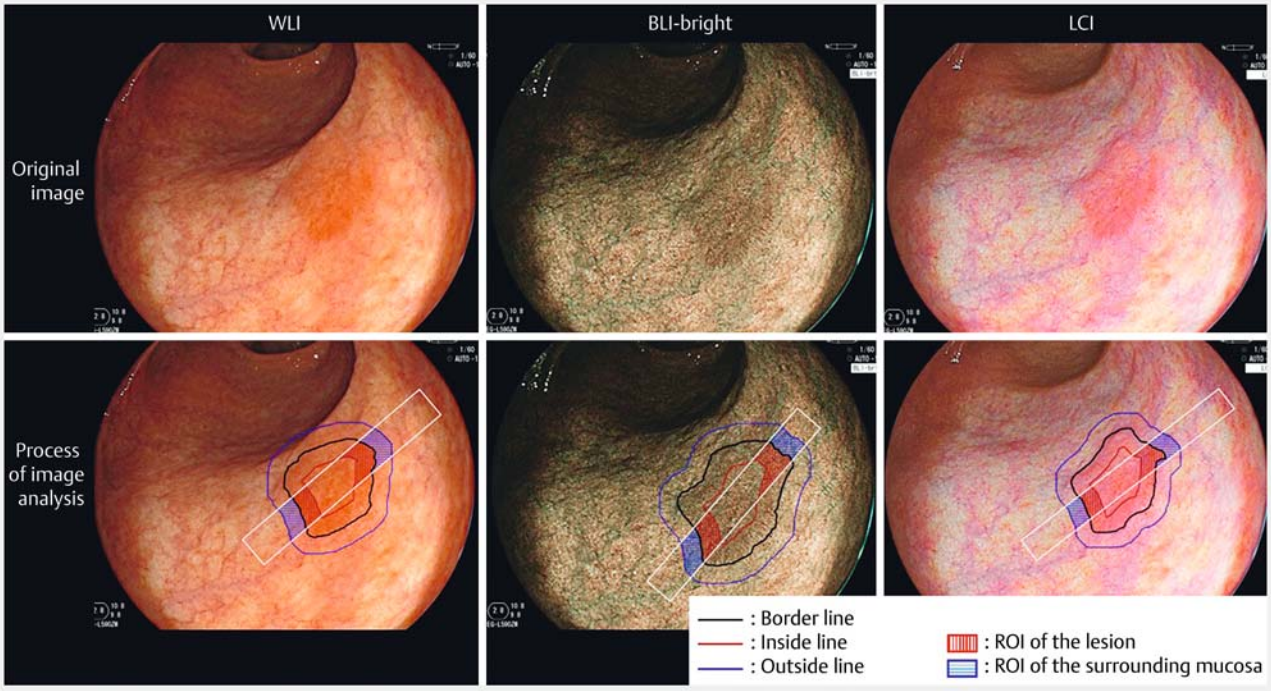

▶ **Fig. 3** The image of process of color analysis by each mode. WLI, white light imaging; BLI, blue laser imaging; LCI, linked color imaging.

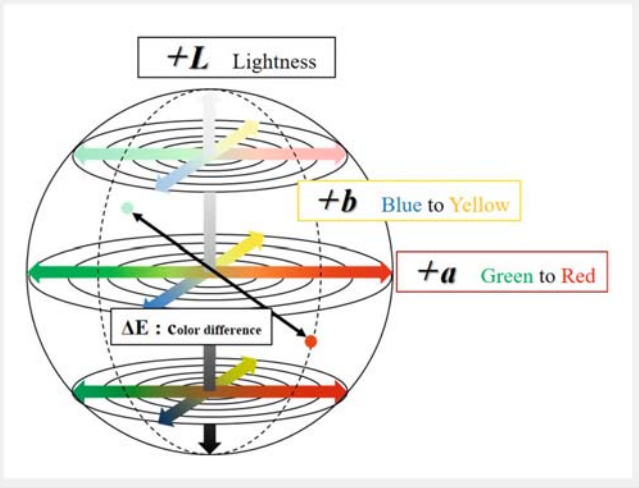

▶ **Fig. 4** The CIE L*a*b* color space (CIE: Commission Internationale d'Eclairage). The CIE L*a*b* color space is a color-opponent space with three dimensions: L* (i. e., lightness), a* (i. e., red to green), and b* (i. e., yellow to blue). The color difference between the lesion and surrounding mucosa (i. e., ΔE) is calculated in the L*a*b* space as the distance between 2 points (black double arrow). It approximates the visual differences detected by the human eye.

twice that of WLI. Assessment of the color difference, based on the NBS unit, indicated that it was appreciable in WLI and BLI-bright, but it was one grade higher (much) in LCI.

We selected lesions for which the ΔE value with WLI was less than 3. There were only seven such lesions; however, the average ΔE of these lesions was approximately three times higher with LCI than with WLI (7.18 vs. 2.25) (▶ **Table 4**). Assessment of the color difference-based NBS unit indicated that it was only noticeable with WLI and BLI-bright, but it was two grades higher (much) with LCI.

▶ **Table 1** The evaluation criteria of color difference, based on the National Bureau of Standards (NBS) unit.

NBS unit	Evaluation criterion
0 – 0.5	Trace
0.5 – 1.5	Slight
1.5 – 3.0	Noticeable
3.0 – 6.0	Appreciable
6.0 – 12.0	Much
12.0 –	Very much

The association between the ΔE and background factors in each mode is presented in ▶ **Table 5**. The presence of *H. pylori* infection with BLI-bright and severe intestinal metaplasia of the surrounding mucosa with LCI resulted in a significantly higher ΔE.

The color value of a lesion had a significantly higher score than the surrounding mucosa in axes a* and b* in WLI, axis a* in BLI-bright, and axes a* and b* in LCI. However, the color value of the lesion and surrounding mucosa primarily overlapped (▶ **Fig. 6**). LCI had the most significant difference between the lesion and surrounding mucosa.

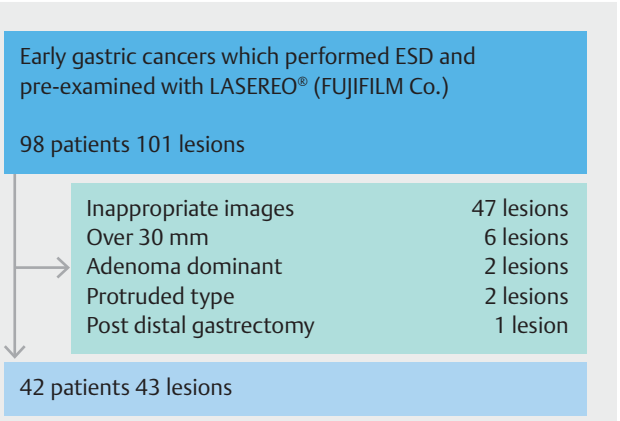

▶ **Fig. 5** A flowchart demonstrating the selection of patients and lesions. ESD, endoscopic submucosal dissection.

To detect the unique color value of cancer, we analyzed the cut-off point between the lesion and surrounding mucosa in LCI using ROC analysis. The most suitable points of axis a* and axis b* were >36.5 and >18.7, respectively. The sensitivity, specificity, and area under the curve were, respectively, 60.4%, 76.8%, and 0.71 for axis a*; and 81.4%, 60.5%, and 0.71 for axis b*. The sensitivity and specificity of the lesions that met both cut-off points were 51.2% and 86.0%, respectively.

Discussion

Identifying morphological changes and color differences between a cancer lesion and surrounding mucosa are two primary factors for detecting early gastric cancer. A characteristic of IEE is the enhancement and change in color. In our study, LCI showed a significantly larger color difference between the lesion and surrounding mucosa, compared to WLI. The color difference in LCI was approximately twice as high as that in WLI. According to the NBS, the average calculated color difference yielded by WLI was considered "appreciable or prominent" while that yielded by LCI was considered "much or excessively marked". For lesions with only "noticeable and below" average calculated color difference, LCI yielded three times greater amplification. We were able to more easily distinguish lesions from the normal mucosa with the additional color contrast provided by LCI. Therefore, LCI might be more useful than WLI for the detection of early gastric cancer.

In our study, no remarkable differences between BLI-bright and WLI were noted. Like NBI, the BLI-bright mode uses narrow-band short wavelength light and produces red color-enhanced images. Many studies reported the superiority of cancer detection by NBI in the esophagus [8–9]. We believe this technology is effective in environments with less color variation such as the esophagus. The components of the color difference between the lesion and surrounding mucosa in WLI consists of two dimensions (a* and b*). Therefore, enhancing only a* (i.e., red) was insufficient to demarcate cancers in the stomach.

LCI enabled better color discrimination when there was high intestinal metaplasia in the surrounding mucosa. There is one

▶ **Table 2** Patient and lesion characteristics.

Patient characteristics	n = 42
▪ Sex, male/female	34/8
▪ Age, years (median, range)	74 (52–89)
▪ Endoscopic atrophy[1] (mild/moderate/severe)	4/14/24
▪ *H. pylori*[2] status (present/postinfection)	18/24
Lesion characteristics	n = 43
▪ Location (upper/middle/lower)	3/24/16
▪ morphologic type[3] (0-IIa/0-IIb/0-IIc)	10/3/30
▪ Histology[4] (tub1/tub2/por/other)	34/9/0/0
▪ Invasion depth (M/SM)	40/3
▪ Size (mm), median (range)	12.0 (2–26)

[1] Kimura-Takemoto Classification C1–2, mild; C3–O1, moderate; O2–3, severe
[2] *Helicobacter pylori*
[3] Paris classification, 0-IIa: slightly elevated, 0-IIb: flat, 0-IIc: slightly depressed
[4] Histological classification, tub1: well differentiated adenocarcinoma, tub2: moderate differentiated adenocarcinoma, por: poorly differentiated adenocarcinoma

▶ **Table 3** Color difference between the region of interest of the lesion and the surrounding mucosa.

	WLI	BLI-bright	LCI
ΔE (color difference)	5.99	5.04	11.02
▪ *P* value (compared to WLI)	—	0.02	<0.001
▪ ΔL (Lightness)	−0.02 —	−1.76 0.001	−0.55 n.s.
▪ Δa (Green to red)	2.68 —	1.49 0.04	5.71 <0.001
▪ Δb (Blue to yellow)	2.89 —	0.06 <0.001	5.45 <0.001
NBS unit ▪ Evaluation criteria	5.51 Appreciable	4.64 Appreciable	10.14 Much

WLI, white light imaging; BLI, blue laser imaging; LCI, linked color imaging

▶ **Table 4** ΔE and National Bureau of Standards unit in the cases of a value of <3 ΔE with WLI (n = 7).

	WLI	BLI-bright	LCI
ΔE (color difference)	2.25	2.90	7.18
▪ *P* value (compared to WLI)	—	0.16	0.02
NBS unit ▪ Evaluation criteria	2.07 Noticeable	2.67 Noticeable	6.61 Much

WLI, white light imaging; BLI, blue laser imaging; LCI, linked color imaging

▶ **Table 5** Association of ΔE and background factors in each mode.

		WLI (ΔE)	*P*	BLI-bright (ΔE)	*P*	LCI (ΔE)	*P*
Cancer-related factor							
▪ Location	Upper – middle Lower	5.73 6.44	n.s.	5.25 4.68	n.s.	10.75 11.48	n.s.
▪ Morphologic type[1]	0 – IIa 0 – IIb 0 – IIc	6.05 4.10 6.16	n.s.	4.95 4.36 5.14	n.s.	10.04 10.84 11.37	n.s.
▪ Histological type[2]	tub1 tub2	5.92 6.26	n.s.	4.68 6.40	n.s.	10.93 11.39	n.s.
▪ Size	≤ 10 mm > 10 mm	5.99 5.99	n.s.	5.16 4.87	n.s.	11.28 10.67	n.s.
Environmental factor							
▪ Endoscopic atrophy[3]	Mild to moderate Severe	5.31 6.53	n.s.	4.80 5.23	n.s.	9.68 12.08	n.s.
▪ H. pylori[4] status	Present Postinfection	6.38 5.72	n.s.	6.10 4.28	0.03	11.22 10.88	n.s.
▪ Inflammatory cell infiltration[5]	Severe Mild	5.15 6.24	n.s.	6.07 4.73	n.s.	10.39 11.22	n.s.
▪ Intestinal metaplasia[5]	Severe Mild	6.35 5.55	n.s.	4.90 5.22	n.s.	12.17 9.58	0.04
▪ Atrophy[5]	Severe Mild	6.36 5.37	n.s.	4.93 5.23	n.s.	11.57 10.10	n.s.

[1] Paris classification, 0 – IIa: slightly elevated type, 0-IIb: flat type, 0-IIc: slightly depressed type
[2] Histological classification, tub1: well differentiated adenocarcinoma, tub2: moderate differentiated adenocarcinoma, por: poorly differentiated adenocarcinoma
[3] Kimura – Takemoto Classification, C1 – 2, mild; C3 – O1, moderate; O2 – 3, severe.
[4] *Helicobacter pylori*
[5] Updated Sydney system score of the surrounding mucosa.

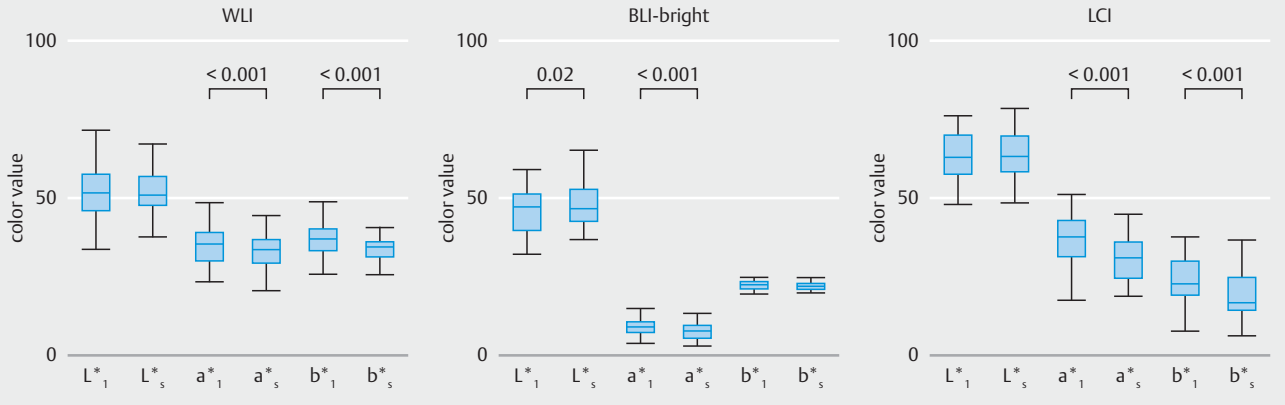

▶ **Fig. 6** Color value of the lesion and surrounding mucosa. Columns L*, a* and b* indicate the color value of each dimension. The subscript "l" and "s" indicate "lesion" and "surrounding mucosa," respectively. WLI, white light imaging; BLI, blue laser imaging; LCI, linked color imaging.

report of using LCI to detect intestinal metaplasia [19]. The mucosa with intestinal metaplasia is white in WLI, but lavender in LCI. The color of white is located at the center of axis a* and b*, but lavender has a negative b*-coordinate. Gastric cancer is primarily red, i. e., a positive b*-coordinate. Therefore, the color difference of the lesions with high intestinal metaplasia in the surrounding mucosa of LCI was greater than that of WLI.

The BLI-bright mode showed a significantly greater color difference in the presence of *H. pylori* infection than that post-infection. In cases of post-infection with *H. pylori*, the background

color occasionally changes to red at the site of atrophic mucosa [31]. In our study, there was atrophy in the surrounding mucosa in most cases, and the color of the lesion was potentially red. The BLI-bright mode only enhanced red color information. Thus, in post-infection cases, the color of the surrounding mucosa and lesion were similar in the BLI-bright mode. The smaller ΔE of post-infection cases in BLI-bright mode caused the significant difference.

Patients with chronic gastritis had a varicolored mucosa. By using LCI, the mucosa with subtle color differences with the surrounding mucosa may be highlighted. It is speculated that the detection of false-positive lesions (i.e., noncancerous color-enhanced areas) may be increased. In such a situation, magnified endoscopy with BLI or NBI can differentiate cancerous and noncancerous lesions [11 – 14]. For the early detection of gastric cancer, recognizing a prospective lesion is important. If a questionable lesion can be detected, the endoscopist can determine if it is a cancerous or noncancerous lesion by using magnified endoscopy with IEE. Therefore, our results may lead to the early recognition of cancerous lesions.

The color value of the lesion was significantly different from that of the surrounding mucosa in each mode. However, the color values of the lesion and surrounding mucosa greatly overlapped. The cut-off color value between the lesion and surrounding mucosa had a low sensitivity and specificity that was insufficient for clinical use, even when using LCI, which showed the largest difference between the lesion and surrounding mucosa. Based on our data, it was difficult to determine the unique color characteristics of gastric cancer. Therefore, the key factor to detecting a cancerous lesion is the color difference between the lesion and surrounding mucosa, not the unique color.

Recently, Suzuki et al. reported the efficacy of LCI for improving the visibility of flat colorectal lesion compared with WLI and BLI. [32]. That study found an improvement in visibility by non-expert endoscopists, unlike BLI. The higher color difference between the lesion and surrounding mucosa might lead to the improvement of visibility even for non-expert endoscopists. The basic and objective data of the present study seem to support this finding.

Our study has several limitations. First, the images could not be stored concurrently in each mode; therefore, the filming conditions were not precisely identical. However, several images were captured for each case and mode, and the most similar images were selected for this study. Second, it was difficult to verify the accuracy of the border line between the lesion and normal mucosa. The resected specimen was step-sectioned at 2-mm intervals and evaluated by an expert pathologist. The pathologist diagnosed the area of cancer and drew a line encircling the cancer area on the photograph of the resected specimen. Moreover, magnified endoscopic images of the border line were stored in all procedures. Based on these images, the border line was drawn. We believe our strategy is sufficient to analyze the border line between the lesion and the surrounding mucosa. Further, we defined the ROI within a certain range and took the average color value within the area, suggesting that the margin of error is acceptable. Third, many lesions were excluded at the point of image selection in this study because of dissimilarity in the photographic conditions in each mode or the number being insufficient for analysis. This factor may have led to a potential selection bias for lesions that were easily photographed from the front. Fourth, only the cases of differentiated type cancers were included in this study. As we only included patients who were scheduled for endoscopic resection, there was a lack of data regarding undifferentiated tumors, which might also represent a selection bias. Finally, the color of early gastric cancer was not always homogeneous. All lesions were biopsied before the procedure. Thus, external factors may have produced some color change. We excluded the areas of erosion and vivid redness caused by the biopsy inside a lesion. Also, we analyzed color not as a point but as an area. We believe the influence of color heterogeneity was thereby reduced.

Conclusion

In conclusion, this study indicates that the color of early gastric cancer lesions differs from the surrounding normal mucosa, but it is not unique. It is therefore difficult to diagnose early gastric cancer by measuring only the color value. LCI produces the most vivid contrast between cancer lesions and the surrounding mucosa. Thus, LCI may facilitate the early and easy recognition of gastric cancer, even by inexperienced endoscopists. To prove the efficacy of LCI for early gastric cancer detection, randomized, controlled clinical trials are needed.

Acknowledgements

The authors are grateful to Y. Teramura of Fujifilm Corporation (Tokyo, Japan) for his advice on the analysis method of color differences.

Competing interests

None

References

[1] Stewart BW, Wild CP. World cancer report 2014. Lyon: World Health Organization; 2014

[2] Nieminen A, Kokkola A, Yla-Liedenpohja J et al. Early gastric cancer: clinical characteristics and results of surgery. Dig Surg 2009; 26: 378 – 383

[3] Oh HJ, Kim JS. Clinical practice guidelines for endoscope reprocessing. Clin Endosc 2015; 48: 364 – 368

[4] Jang JY. The past, present, and future of image-enhanced endoscopy. Clin Endosc 2015; 48: 466 – 475

[5] Nam SY, Choi IJ, Park KW et al. Effect of repeated endoscopic screening on the incidence and treatment of gastric cancer in health screenees. Eur J Gastroenterol Hepatol 2009; 21: 855 – 860

[6] Lee HL, Eun CS, Lee OY et al. When do we miss synchronous gastric neoplasms with endoscopy? Gastrointest Endosc 2010; 71: 1159 – 1165

[7] Raftopoulos SC, Segarajasingam DS, Burke V et al. A cohort study of missed and new cancers after esophagogastroduodenoscopy. Am J Gastroenterol 2010; 105: 1292 – 1297

[8] Muto M, Minashi K, Yano T et al. Early detection of superficial squamous cell carcinoma in the head and neck region and esophagus by narrow band imaging: a multicenter randomized controlled trial. J Clin Oncol 2010; 28: 1566 – 1572

[9] Takenaka R, Kawahara Y, Okada H et al. Narrow-band imaging provides reliable screening for esophageal malignancy in patients with head and neck cancers. Am J Gastroenterol 2009; 104: 2942 – 2948

[10] Ishihara R, Inoue T, Hanaoka N et al. Autofluorescence imaging endoscopy for screening of esophageal squamous mucosal high-grade neoplasia: a phase II study. J Gastroenterol Hepatol 2012; 27: 86 – 90

[11] Dohi O, Yagi N, Majima A et al. Diagnostic ability of magnifying endoscopy with blue laser imaging for early gastric cancer: a prospective study. Gastric Cancer 2017; 20: 297 – 303

[12] Nakayoshi T, Tajiri H, Matsuda K et al. Magnifying endoscopy combined with narrow band imaging system for early gastric cancer: correlation of vascular pattern with histopathology (including video). Endoscopy 2004; 36: 1080 – 1084

[13] Ezoe Y, Muto M, Horimatsu T et al. Magnifying narrow-band imaging versus magnifying white-light imaging for the differential diagnosis of gastric small depressive lesions: a prospective study. Gastrointest Endosc 2010; 71: 477 – 484

[14] Ezoe Y, Muto M, Uedo N et al. Magnifying narrowband imaging is more accurate than conventional white-light imaging in diagnosis of gastric mucosal cancer. Gastroenterology 2011; 141: 2017 – 2025

[15] Tada K, Oda I, Yokoi C et al. Pilot study on clinical effectiveness of autofluorescence imaging for early gastric cancer diagnosis by less experienced endoscopists. Diagn Ther Endosc 2011: doi:10.1155/ 2011/ 419136

[16] Xirouchakis E, Laoudi F, Tsartsali L et al. Screening for gastric premalignant lesions with narrow band imaging, white light and updated Sydney protocol or both? Dig Dis Sci 2013; 58: 1084 – 90

[17] Dohi O, Yagi N, Onozawa Y et al. Linked color imaging improves endoscopic diagnosis of active Helicobacter pylori infection. Endosc Int Open 2016; 4: E800 – E805

[18] Sun X, Dong T, Bi Y et al. Linked color imaging application for improving the endoscopic diagnosis accuracy: a pilot study. Sci Rep 2016; 6: 33473

[19] Ono S, Abiko S, Kato M. Linked color imaging enhances gastric cancer in gastric intestinal metaplasia. Dig Endosc 2017; 29: 230 – 231

[20] Fukuda H, Miura Y, Hayashi Y et al. Linked color imaging technology facilitates early detection of flat gastric cancers. Clin J Gastroenterol 2015; 8: 385 – 389

[21] Suzuki T, Hara T, Kitagawa Y et al. Magnified endoscopic observation of early colorectal cancer by linked color imaging with crystal violet staining (with video). Gastrointest Endosc 2016; 84: 726 – 729

[22] Kaneko K, Oono Y, Yano T et al. Effect of novel bright image enhanced endoscopy using blue laser imaging (BLI). Endosc Int Open 2014; 2: E212 – E219

[23] Kuehni RG. Color-tolerance data and the tentative CIE 1976 Lab formula. J Opt Soc Am 1976; 66: 497 – 500

[24] Sato Y, Sagawa T, Hirakawa M et al. Clinical utility of capsule endoscopy with flexible spectral imaging color enhancement for diagnosis of small bowel lesions. Endosc Int Open 2014; 2: E80 – E87

[25] Waldemarin RF, Terra PC, Pinto LR et al. Color change in acrylic resin processed in three ways after immersion in water, cola, coffee, mate and wine. Acta Odontol Latinoam 2013; 26: 138 – 143

[26] Central Bureau of CIE [International Commission on Illumination]. Colorimetry – Technical Report. CIE Pub. No. 15. 3rd ed. Vienna: International Commission on Illumination; 2004: Available: http:// www.cdvplus.cz/file/3-publikace-cie15-2004/ (Accessed 2017 Feb 19)

[27] Kimura K, Takemoto T. An endoscopic recognition of the atrophic border and its significance in chronic gastritis. Endoscopy 1969; 3: 87 – 97

[28] Nagata K, Shimizu M. Pathological evaluation of gastrointestinal endoscopic submucosal dissection materials based on Japanese guidelines. World J Gastrointest Endosc 2012; 4: 489 – 499

[29] Dixon MF, Genta RM, Yardley JH et al. Classification and grading of gastritis. The updated Sydney System. International Workshop on the Histopathology of Gastritis, Houston 1994. Am J Surg Pathol 1996; 20: 1161 – 1181

[30] Correa P. Helicobacter pylori and gastric carcinogenesis. Am J Surg Pathol 1995; 19: S37 – S42

[31] Kato M, Terao S, Adachi K et al. Changes in endoscopic findings of gastritis after cure of H. pylori infection: multicenter prospective trial. Dig Endosc 2013; 25: 264 – 273

[32] Suzuki T, Hara T, Kitagawa Y et al. Linked-color imaging improves endoscopic visibility of colorectal nongranular flat lesions. Gastrointestinal Endosc 2017: doi:10.1016/ j.gie.2017.01.044