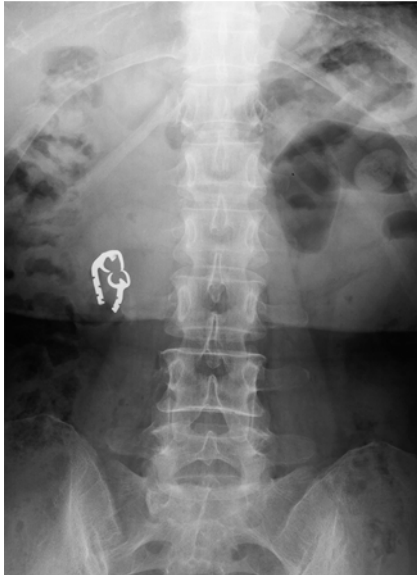

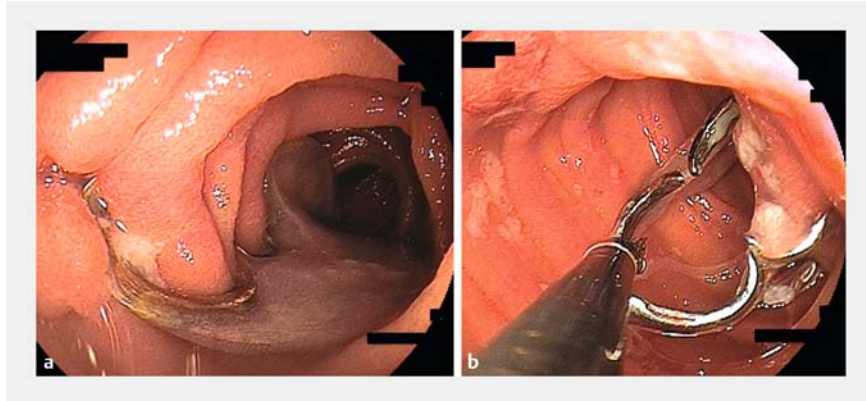
Extraction of an ingested denture embedded in the jejunum by mucosal cutting



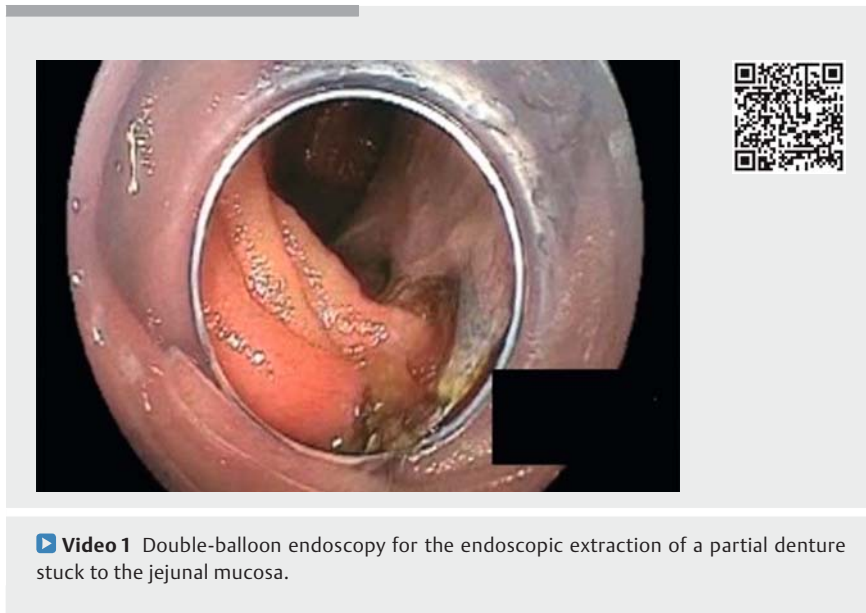
► **Fig. 1** Abdominal radiograph shows a denture with sharp elongated teeth and a hook lodged in the small intestine.

A 55-year-old woman accidentally ingested a denture, and it did not pass per anus after 4 days. Her local doctor followed her for 15 days, but the denture did not pass, and she was referred to our institution. She did not complain of any abdominal symptoms, and laboratory data did not show any abnormal findings. Abdominal radiograph (► **Fig. 1**) and computed tomography scan showed a denture lodged in the jejunum. Antegrade double-balloon enteroscopy showed sharp, elongated teeth embedded in the jejunal mucosa (► **Fig. 2**).

Forceps extraction was attempted first but was unsuccessful because the elongated part of the denture was lodged deep in the mucosa. Five days later, forceps extraction was attempted again using a short double-balloon endoscope, but the hook prevented extraction. Next, using endoscopic ultrasonography, we confirmed that the hook of the denture was in the thickened mucosal layer of the jejunum. Therefore, after injecting normal saline into the submucosa, we cut the mucosa with a needle-knife



► **Fig. 2** Endoscopic findings of double-balloon enteroscopy. **a** A denture with a hook is lodged in the jejunal mucosa. **b** Forceps grasp part of the denture.



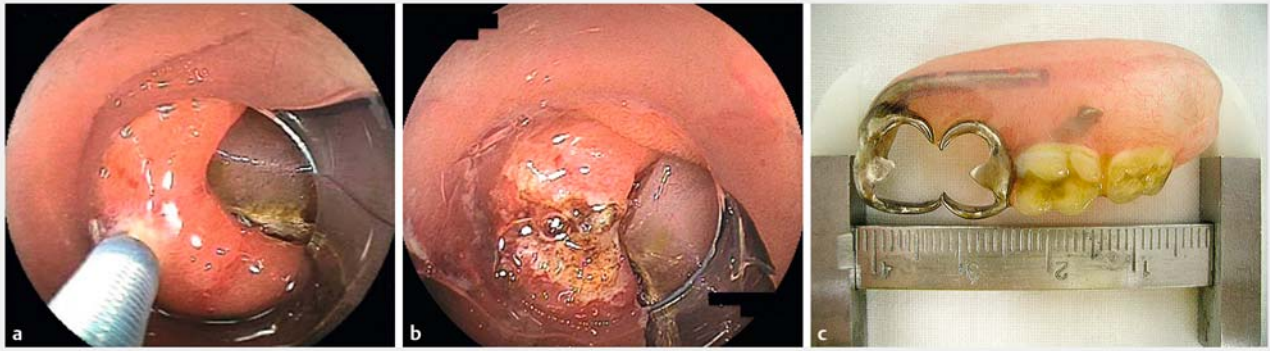
► **Video 1** Double-balloon endoscopy for the endoscopic extraction of a partial denture stuck to the jejunal mucosa.

(► **Fig. 3**). After freeing it from the mucosa, the denture was extracted endoscopically.

Foreign bodies in the small intestine are relatively rare, but they do risk perforation and therefore necessitate surgical intervention [1]. Nakamura et al. reported three patients with ingested dentures among 22 patients with foreign bodies in the small intestine [2]. Although forceps extraction of dentures was successful in two of the three patients, one remained deep in the ileal wall and was removed

surgically after failure of endoscopic extraction [2]. In the present case, we overcame the problem of the denture hook being stuck in the jejunal mucosa by using the endoscopic mucosal cutting technique and extracting the denture without surgery.

In conclusion, mucosal cutting during double-balloon endoscopy is useful for the extraction of a sharp foreign body embedded in the small intestine, after confirming the depth of embedment.



► **Fig. 3** Endoscopic intervention using double-balloon endoscope. **a** Mucosal incision after injection of normal saline. **b** Incised jejunal mucosa. **c** Extracted denture, 4.4×2.2 cm.

Endoscopy_UCTN_Code_CCL_1AC_2AH

Competing interests

Dr. Yamamoto has patents for double-balloon enteroscopy produced by Fujifilm Corp. He is also a consultant for Fujifilm and has received honoraria, grants, and royalties from the company. Drs. Yano and Hayashi have received honoraria from Fujifilm.

The Authors

Takahito Takezawa¹, Satoshi Shinozaki^{1,2}, Tomonori Yano¹, Keijiro Sunada¹, Yoshikazu Hayashi¹, Alan K. Lefor³, Hironori Yamamoto¹

- 1 Division of Gastroenterology, Department of Medicine, Jichi Medical University, Shimotsuke, Japan
- 2 Shinozaki Medical Clinic, Utsunomiya, Japan
- 3 Department of Surgery, Jichi Medical University, Shimotsuke, Japan

Corresponding author

Hironori Yamamoto, MD, PhD

Division of Gastroenterology, Department of Medicine, Jichi Medical University, 3311-1 Yakushiji, Shimotsuke, Tochigi, 329-0498, Japan
 Fax: +81-285-448297
 ireef@jichi.ac.jp

References

- [1] Nicolodi GC, Trippia CR, Caboclo MF et al. Intestinal perforation by an ingested foreign body. *Radiol Bras* 2016; 49: 295–299
- [2] Nakamura M, Hirooka Y, Watanabe O et al. Minimally invasive extraction of a foreign body from the small intestine using double-balloon endoscopy. *Nagoya J Med Sci* 2015; 77: 189–194

Bibliography

DOI <https://doi.org/10.1055/s-0043-115896>
 Published online: 31.7.2017
 Endoscopy 2017; 49: E262–E263
 © Georg Thieme Verlag KG
 Stuttgart · New York
 ISSN 0013-726X

ENDOSCOPY E-VIDEOS

<https://eref.thieme.de/e-videos>



Endoscopy E-Videos is a free access online section, reporting on interesting cases and new techniques in gastroenterological endoscopy. All papers include a high quality video and all contributions are freely accessible online.

This section has its own submission website at <https://mc.manuscriptcentral.com/e-videos>