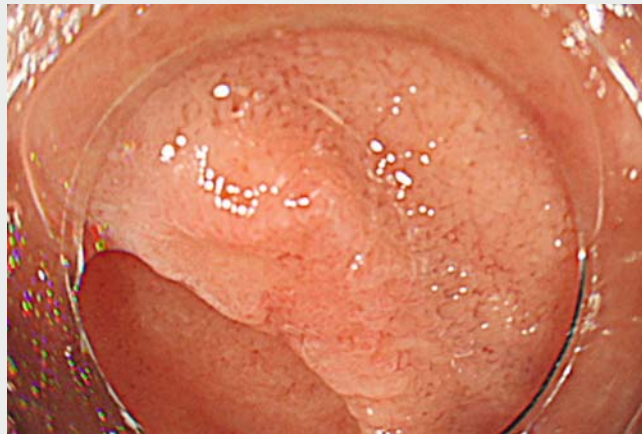

## Surgery avoided by the use of over-the-scope clips for severe duodenal complications associated with endoscopic mucosal resection

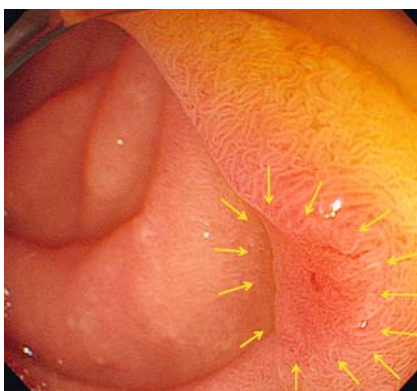
During endoscopic treatment for duodenal neoplasm, hazardous complications such as perforation and bleeding sometimes occur owing to the anatomical characteristics of the duodenum [1–3]. Although surgical repair has been traditionally required for these complications, the procedure is invasive and complicated [4]. A currently available over-the-scope clip (OTSC; Ovesco Endoscopy, Tübingen, Germany) has provided excellent outcomes for gastrointestinal refractory bleeding and full-thickness defects [5]. Here, we describe a notable case in which iatrogenic duodenal complications could be managed with OTSCs. A 56-year-old man presented with a duodenal adenoma that showed a reddish and flat elevated lesion, approximately 10 mm in diameter, located in the posterior wall of the second duodenal portion (►Fig. 1). After submucosal injection, cap-assisted endoscopic mucosal resection (EMR) was performed under carbon dioxide insufflation. A large full-thickness perforation, 20 mm in diameter, occurred (►Fig. 2a), and spurting arterial bleeding was seen (►Fig. 2b). The bleeding was accompanied by hemorrhagic shock and was immediately controlled using hemo-

static forceps (Coagrasper; Olympus, Tokyo, Japan). OTSCs were then applied to close the defect at the perforation site, after obtaining informed consent. Grasping forceps (Twingrasper; Ovesco Endoscopy) were used to approximate the edges of the large defect. The defect was mostly closed by one OTSC (t type,

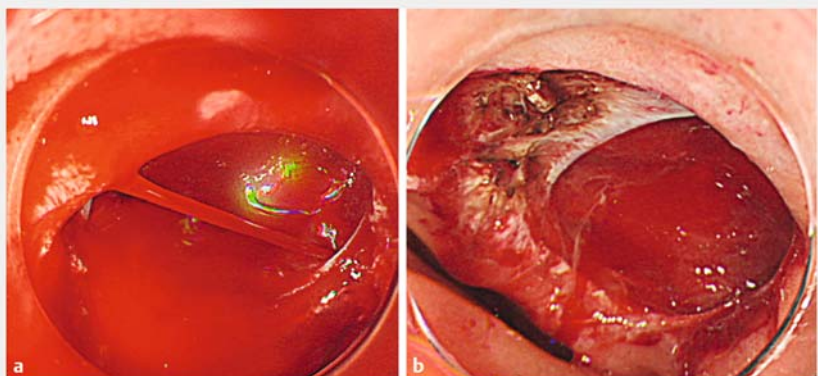
9 mm), and the remaining defect was closed by an additional OTSC using simple suction (►Fig. 3, ►Video 1). A radiographic examination 5 days later confirmed no leakage at the perforation site (►Fig. 4). The patient was discharged without additional interventions 19 days later. A histological examination revealed



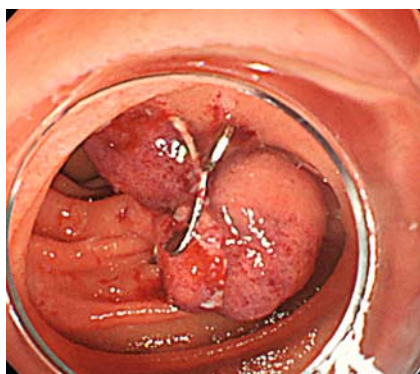►Video 1 Cap-assisted endoscopic mucosal resection was performed for a tumor located in the second duodenal portion. A large full-thickness perforation occurred with spurting arterial bleeding. After complete hemostasis was achieved using hemostatic forceps, the defect was successfully closed by two over-the-scope clips.



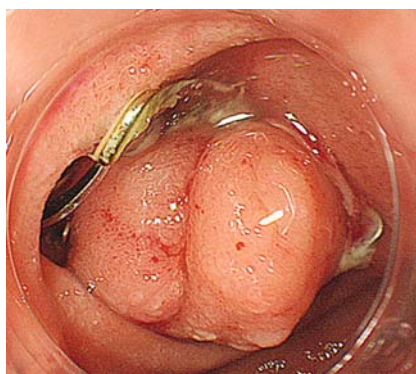►Fig. 1 An upper gastrointestinal endoscopy revealed a reddish and flat elevated lesion (yellow allows), approximately 10 mm in diameter, located in the posterior wall of the second duodenal portion.



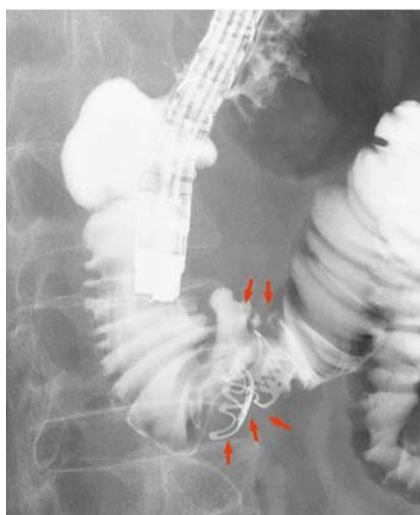
►Fig. 2 Endoscopic views. **a** A large full-thickness perforation, 20 mm in diameter, occurred with exposure of the muscle layer after performing cap-assisted endoscopic mucosal resection. **b** Spurting arterial bleeding was seen at the edge of the perforation site.



► **Fig. 3** The whole defect was completely closed by two over-the-scope clips (t type, 9 mm).



► **Fig. 5** Complete closure of the defect was confirmed 2 months later.



► **Fig. 4** A radiograph confirmed no leakage at the perforation site 5 days later. The red arrows show the perforation site closed by over-the-scope clips.

curative resection of a tubular adenoma with moderate-grade dysplasia. Follow-up endoscopy 2 months later confirmed complete closure of the defect (► **Fig. 5**). This case demonstrates that OTSC rescue may be a minimally invasive therapy option for a life-threatening complication such as a large duodenal perforation with spurting bleeding.

Endoscopy\_UCTN\_Code\_CPL\_1AH\_2AZ

### Competing interests

None

### The Authors

**Noriko Nishiyama, Hirohito Mori, Hideki Kobara, Shintaro Fujihara, Nobuya Kobayashi, Tatsuo Yachida, Tsutomu Masaki**  
Department of Gastroenterology and Neurology, Faculty of Medicine, Kagawa University, Kagawa, Japan

### Corresponding author

**Noriko Nishiyama, MD, PhD**  
Department of Gastroenterology and Neurology, Faculty of Medicine, Kagawa University, 1750-1 Ikenobe, Miki, Kita, Kagawa 761-0793, Japan  
Fax: +81-87-8912158  
n-nori@med.kagawa-u.ac.jp

### References

- [1] Nonaka S, Oda I, Tada K et al. Clinical outcome of endoscopic resection for nonampullary duodenal tumors. *Endoscopy* 2015; 47: 129–135
- [2] Hoteya S, Yahagi N, Iizuka T et al. Endoscopic submucosal dissection for nonampullary large superficial adenocarcinoma/adenoma of the duodenum: feasibility and long-term outcomes. *Endosc Int Open* 2013; 1: 2–7
- [3] Mori H, Ayaki M, Kobara H et al. Suitable closure for post-duodenal endoscopic resection taking medical costs into consideration. *World J Gastroenterol* 2015; 21: 5281–5286
- [4] Farnell MB, Sakorafas GH, Sarr MG et al. Villous tumors of the duodenum: reappraisal of local vs. extended resection. *J Gastrointest Surg* 2000; 4: 13–21
- [5] Haito-Chavez Y, Law JK, Kratt T et al. International multicenter experience with an over-the-scope clipping device for endoscopic management of GI defects (with video). *Gastrointest Endosc* 2014; 80: 610–622

### Bibliography

DOI <https://doi.org/10.1055/s-0043-115891>  
Published online: 3.8.2017  
*Endoscopy* 2017; 49: E279–E280  
© Georg Thieme Verlag KG  
Stuttgart · New York  
ISSN 0013-726X

### ENDOSCOPY E-VIDEOS

<https://eref.thieme.de/e-videos>



*Endoscopy E-Videos* is a free access online section, reporting on interesting cases and new techniques in gastroenterological endoscopy. All papers include a high quality video and all contributions are freely accessible online.

This section has its own submission website at  
<https://mc.manuscriptcentral.com/e-videos>