

Endoscopic ultrasound-guided gastrojejunostomy: a novel technique

Endoscopic ultrasound (EUS)-guided gastroenterostomy with placement of a lumen-apposing metal stent has emerged as a novel, minimally invasive therapeutic option for patients with gastric outlet obstruction (GOO) [1–3]. The most challenging aspect of the procedure is immobilizing the jejunal loop in order to create the fistulous tract and deploy the stent. Several different techniques have been described [1–3]. We present a novel approach involving the use of a second endoscope that is advanced through a previously placed percutaneous gastrostomy (PEG) site to within the target jejunal lumen in order to provide traction on the wire, and to facilitate fistula creation and stent placement.

A 68-year-old man presented with GOO following surgical resection for pancreatic cancer. Enteral stenting and PEG-jejunostomy tube placement were unsuccessful for palliation. Therefore, EUS-guided gastroenterostomy was performed using a novel rendezvous technique (► **Video 1**).

The echoendoscope was used to identify and access the jejunum from within the gastric lumen, and a wire was advanced into the targeted jejunal loop. A concur-

rent small-diameter endoscope was advanced percutaneously through the PEG site and across the malignant obstruction into the jejunum, where the coiled guidewire was visualized and grasped by a pediatric biopsy forceps. This provided traction on the wire, which facilitated transgastric cautery-assisted fistula creation and stent placement with a lumen-apposing metal stent (► **Fig. 1**). After stent placement, both endoscopes were removed and the PEG site was closed intragastrically with an over-the-scope clip. At 3-month follow-up, the patient was still able to tolerate a soft diet.

In conclusion, EUS-guided gastroenterostomy using this rendezvous technique was safe and efficacious, and should be considered in patients with GOO who have a previously placed PEG tube.

Endoscopy_UCTN_Code_TTT_1AS_2AB

Competing interests

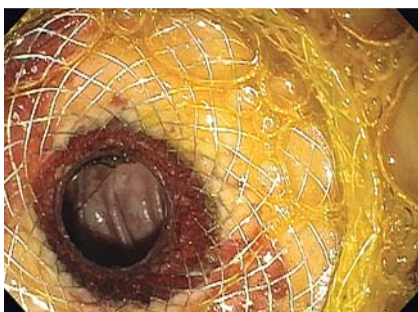Michel Kahaleh MD: has received grant support from Boston Scientific, Fujinon, EMcision, Xlumen Inc., W.L. Gore, MaunaKea, Apollo Endosurgery, Cook Endoscopy, ASPIRE Bariatrics, GI Dynamics, NinePoint Medical, Merit Medical, Olympus and MI Tech. He is a consultant for Boston Scientific, Xlumen Inc., Concordia Laboratories Inc, ABBvie, and MaunaKea Tech.

All other authors have no conflicts of interest to report.

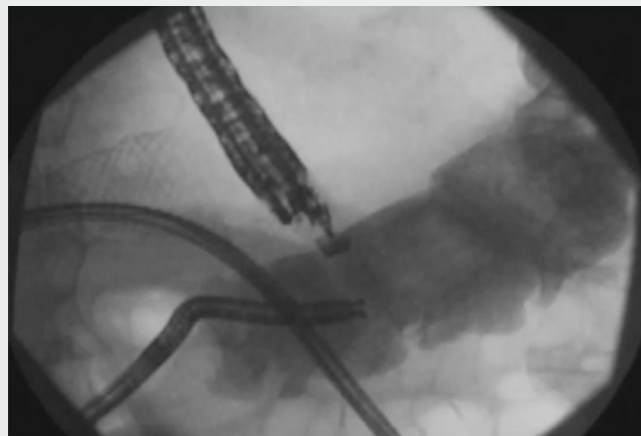
The Authors

Amy Tyberg, Manuel Perez-Miranda, Steven Zerbo, Todd H. Baron, Michel Kahaleh

Division of Gastroenterology and Hepatology, Weil Cornell Medical, New York, United States



► **Fig. 1** Endoscopic image of a gastrojejunal lumen-apposing metal stent.



► **Video 1** Endoscopic ultrasound-guided gastroenterostomy using a novel rendezvous technique.



Corresponding author

Michel Kahaleh, MD

Division of Gastroenterology and
Hepatology, Weill Cornell Medical College,
New York, NY 10021, United States
Fax: +1-646-962-0110
mkahaleh@gmail.com

References

- [1] Tyberg A, Perez-Miranda M, Sanchez-Ocana R et al. Endoscopic ultrasound-guided gastrojejunostomy with a lumen-apposing metal stent: a multicenter, international experience. *Endosc Int Open* 2016; 4: E276 – E281

- [2] Itoi T, Ishii K, Ikeuchi N et al. Prospective evaluation of endoscopic ultrasonography-guided double-balloon-occluded gastrojejunostomy bypass (EPASS) for malignant gastric outlet obstruction. *Gut* 2016; 65: 193 – 195
- [3] Khashab MA, Kumbhari V, Grimm IS et al. EUS-guided gastroenterostomy: the first U.S. clinical experience (with video). *Gastrointest Endosc* 2015; 82: 932 – 938

Bibliography

DOI <https://doi.org/10.1055/s-0043-115886>
Published online: 31.7.2017
Endoscopy 2017; 49: E252–E253
© Georg Thieme Verlag KG
Stuttgart · New York
ISSN 0013-726X

ENDOSCOPY E-VIDEOS

<https://eref.thieme.de/e-videos>



Endoscopy E-Videos is a free access online section, reporting on interesting cases and new techniques in gastroenterological endoscopy. All papers include a high quality video and all contributions are freely accessible online.

This section has its own submission website at
<https://mc.manuscriptcentral.com/e-videos>