

Safety and efficacy of coaxial lumen-apposing metal stents in the management of refractory gastrointestinal luminal strictures: a multicenter study

OPEN
ACCESS

Authors

Fateh Bazerbachi¹, Jason D. Heffley², Barham K. Abu Dayyeh¹, Jose Nieto³, Eric J. Vargas¹, Tarek Sawas¹, Raja Zaghlool¹, Navtej S. Buttar¹, Mark D. Topazian¹, Louis M. Wong Kee Song¹, Michael Levy¹, Steve Keilin², Qiang Cai², Field F. Willingham²

Institutions

- 1 Division of Gastroenterology and Hepatology, Mayo Clinic, Rochester, Minnesota, United States
- 2 Division of Digestive Diseases, Department of Medicine, Emory University, Atlanta, Georgia, United States
- 3 Borland-Groover Clinic, Jacksonville, Florida, United States

submitted 9.3.2017

accepted after revision 29.5.2017

Bibliography

DOI <https://doi.org/10.1055/s-0043-114665> |
Endoscopy International Open 2017; 05: E861–E867
© Georg Thieme Verlag KG Stuttgart · New York
ISSN 2364-3722

Corresponding author

Barham K. Abu Dayyeh, MD MPH, Division of Gastroenterology and Hepatology, Mayo Clinic, 200 First Street SW, Rochester, Minnesota 55905, United States
Fax: +1-507-538-5820
abudayyeh.barham@mayo.edu

ABSTRACT

Background and aims Benign gastrointestinal (GI) strictures are often refractory to standard endoscopic interventions. Fully covered coaxial lumen-apposing metal stents (LAMS) have emerged as a novel therapy for these strictures. The aim of this study was to evaluate the safety and efficacy of LAMS for refractory GI strictures.

Patients and methods A retrospective analysis was performed for patients who underwent LAMS placement for benign luminal strictures in three US centers between Janu-

ary 2014 and December 2016. The primary outcomes were technical success and initial clinical success of LAMS placement. Secondary outcomes were stent migration, rate of re-intervention, and adverse events.

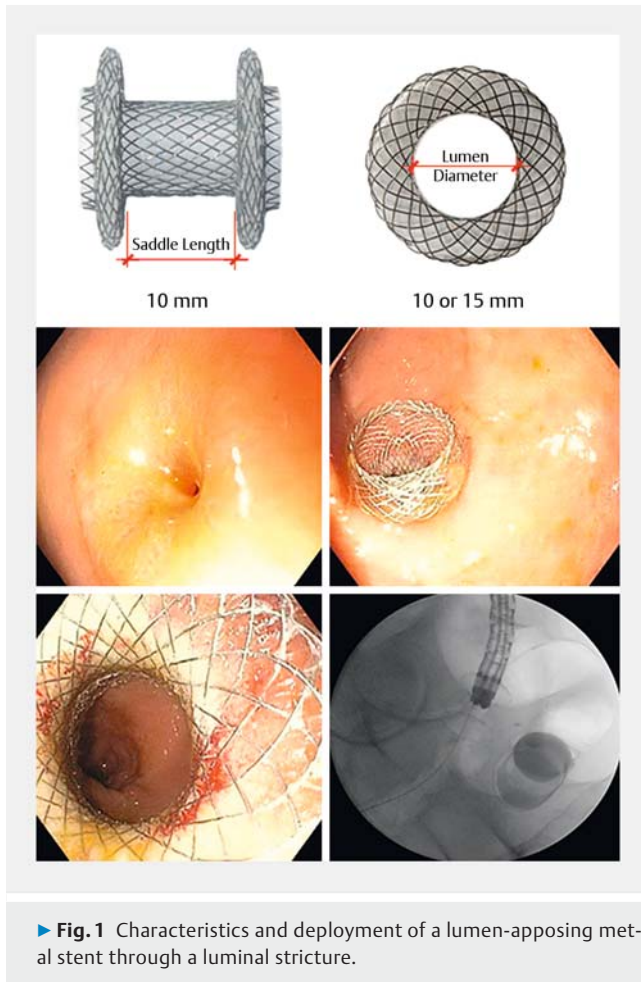
Results A total of 49 patients underwent 56 LAMS placement procedures. Previous treatment had failed in 39 patients (79.6%), and anastomotic strictures were the indication in 77.6% (38/49), with the most common site being gastrojejunal (34.7% [17/49]). Technical success was achieved in all procedures and initial clinical success was achieved in 96.4% of all procedures (54/56). Patient initial clinical success was 95.9% (47/49). Stent migration occurred in 17.9% of procedures, and was more likely to occur at sites in the lower GI tract ($P=0.02$). The mean stent dwell time was 100.6 days, and the mean follow-up was 169.8 days. Minor adverse events, not requiring hospitalization, occurred in 33.9% of procedures, including subsequent stricture progression (10.7%). In cases where LAMS were removed, mean follow-up time was 102.2 days. The re-intervention rate was 75% at 300 days follow-up after stent removal. Of the LAMS placed at anastomotic strictures, 36.4% required re-intervention, with approximately two-thirds of these re-interventions requiring placement of a new stent or surgery.

Conclusion LAMS placement was successful for the management of refractory GI strictures, with good technical and initial clinical success rates. However, re-intervention rates after LAMS removal were high, and many strictures were not resolved by an extended period of stenting with these coaxial stents. LAMS placement offers additional therapeutic options and in selected cases might be considered a destination therapy for patients with recalcitrant benign strictures.

Introduction

Endoscopic therapy is the first-line approach for many benign gastrointestinal (GI) strictures, owing to excellent safety profiles and high success rates. In addition, for many GI strictures,

there are few other desirable therapeutic options available. Despite the short-term success in stricture resolution with through-the-scope balloon dilation therapy, with or without intralesional steroid injection [1], or with needle-knife incisional therapy [2], a substantial portion of these strictures recur or



► **Fig. 1** Characteristics and deployment of a lumen-apposing metal stent through a luminal stricture.

prove refractory [3,4]. Endoluminal stenting has been employed in these cases, typically with fully covered, self-expandable metal stents (FCSEMS); however, this approach is complicated by a high rate of stent migration, patient intolerance, or iatrogenic stricture formation, which result from the inherent design limitations of long cylindrical stents [5].

Lumen-apposing metal stents (LAMS; AXIOS, Boston Scientific Inc., Marlborough, Massachusetts, USA) were originally developed for access to and drainage of pancreatic fluid collections [6]. The wagon-wheel configuration of the LAMS provides an anchoring mechanism that secures the flanges of the stent at the proximal and distal aspects of luminal strictures, making them less prone to migration and potentially suitable for treatment of benign refractory strictures [7,8]. The flexible, silicone-covered, nitinol-braided LAMS is deployed through a 10.5 Fr catheter. The flanges, short saddle, and moderate radial force of the LAMS may decrease the risk of migration and improve patient tolerance, possibly allowing for a longer dwell time. Data regarding the use of this stent for luminal GI strictures have been limited to small case series with limited postintervention information and short follow-up duration. Furthermore, the use of this stent for luminal strictures remains off-label. We aim to report the largest multicenter US experience on the use of LAMS in the management of refractory intraluminal GI strictures.

Patients and methods

Data collection

This study was a retrospective, multicenter effort involving three high-volume tertiary care centers in the United States. Consecutive patients who underwent LAMS placement for benign GI strictures from January 2014 to December 2016 were identified from electronic medical records. The off-label indication of the procedure was explained to the patient and informed consent was obtained. Demographic, procedural, and outcome data were abstracted from the electronic medical records. The study was approved by the Institutional Review Board of each medical center.

Definitions

Upper GI strictures were defined as any stricture site above the ligament of Treitz or, for anastomotic strictures, any esophageal or gastric anastomosis. The endoscopist determined the refractory nature of strictures clinically and endoscopically; this was defined as requiring at least two endoscopic procedures without improvement in stricture appearance compared with the index endoscopy.

Technical success was defined as satisfactory stent deployment across the stricture based on endoscopic and fluoroscopic appearance. Initial clinical success was defined as resolution of the symptoms that had prompted treatment over the follow-up period, regardless of recurrence following removal of LAMS. The last follow-up was defined as the last visit with the patient, whether in clinic or by telecommunication (phone, electronic messages).

Stent tolerability was classified as: 1) not tolerated, requiring early removal; 2) achievement of the planned length of dwell time, despite significant intolerance symptoms that required hospitalization; 3) planned dwell time with minor intolerance symptoms that did not necessitate urgent medical attention or hospitalization; 4) fully tolerated without any complications.

Bleeding was defined as any event (hematemesis, melena, or hematochezia) deemed at the time to be related to stent placement, with or without a drop in hemoglobin. Stricture progression was defined as stricture formation adjacent to the proximal or distal flanges of the LAMS, detected at the time of any follow-up procedure. Stent removal was either planned, as determined by the treating physician, or premature if an adverse event arose.

Endoscopic technique

The method for LAMS deployment has been described previously [9]. Briefly, procedures were conducted using a forward-viewing therapeutic endoscope or an oblique-viewing therapeutic linear echoendoscope. In some cases, a guidewire was introduced across the stricture under fluoroscopic guidance. The LAMS was positioned and deployed across the stricture under endoscopic and fluoroscopic guidance (► **Fig. 1**, ► **Video 1**).

Study outcomes

The primary outcomes were technical success and initial clinical success of LAMS placement. Secondary outcomes were stent migration, rate of re-intervention, and adverse events.

Data analysis

As some patients underwent the placement of sequential LAMS, we performed separate patient-oriented ($n=49$) and procedure-oriented ($n=56$) analyses. This allowed examination of the characteristics of patients who underwent LAMS stenting, as well as the performance of all LAMS procedures as a whole.

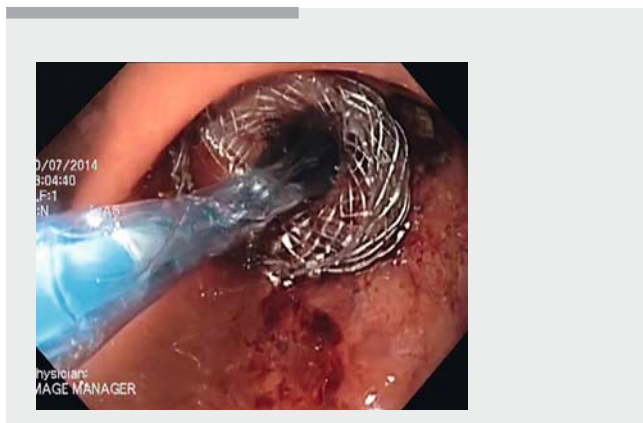
To evaluate the durability of the response, a Kaplan–Meier curve was generated. Using this method, an analysis was undertaken to determine the need for re-intervention after LAMS removal. For this analysis, the resulting Kaplan–Meier curve started at the time of LAMS extraction, with the end point as time of last follow-up. The denominator for this analysis was the number of procedures ($n=56$), as we wanted to evaluate the performance of every LAMS.

Data were compared for anastomotic strictures and non-anastomotic strictures. A chi-squared analysis and/or Fischer's exact test were used for categorical variables, and a *t* test was used to compare means of continuous variables. SPSS version 24.0 (IBM Corp, Armonk, New York, USA), was used to conduct the statistical analysis.

Results

Demographics and baseline characteristics

A total of 49 patients (28 women; mean age 51.4 years [range 7–85]) underwent a total of 56 LAMS placement procedures during the study period. Previous treatment had failed in 79.6% of patients (79.2% balloon dilations, 4.3% steroid injection in addition to dilation; 27.7% FCSEMS). In 77.6% (38/49) of patients, anastomotic strictures were the indication for LAMS placement. Other etiologies included peptic ulcer-related strictures (16.3%; 8/49), radiation-induced strictures (2.0%; 1/49), and miscellaneous (4.1%; 2/49). The most common site for



Video 1 Deployment of a lumen-apposing metal stent across a gastrointestinal luminal stricture.

LAMS deployment was at a gastrojejunal anastomosis (17/49 [34.7%]). Other sites included esophagogastric (4.1%; 2/49), esophagojejunal (10.2%; 5/49), colocolonic (14.3%; 7/49) anastomoses, and the pyloric channel (14.3%; 7/49).

LAMS (15 mm diameter) were deployed across strictures with mean length of 10.5 mm (range 5–40 mm). **Table 1** details the demographic and baseline characteristics for the patient sample. **Fig. 2** details the patient recruitment, initial clinical success and failure, and need for re-intervention for all patients.

Procedural outcomes and efficacy

Technical success in LAMS placement was achieved in all procedures, and initial clinical success was achieved following 96.4% of procedures (54/56). The mean duration of follow-up was 169.8 days (range 1–577 days). During follow-up, 35/56 LAMS (62.5%) were removed, with a mean dwell time of 100.6 days (range 7–550 days). The mean follow-up after LAMS removal was 102.2 days.

During follow-up, re-intervention after removal of LAMS occurred in 17 cases, with the majority (16/17) being in cases of anastomotic strictures. More than half of re-interventions were needed by 90 days following removal of LAMS, and the re-intervention rate was 75% at 300 days follow-up after stent removal (**Fig. 3**). Re-interventions included balloon dilation in 6/17 procedures, placement of second stent in 8/17 (another LAMS needed in 5/17 cases), and surgery in 3/17 procedures. Detailed results for procedural and outcome data, and re-intervention data are shown in **Table 2** and **Table 3**, respectively.

Patient-oriented outcomes

Technical success of LAMS placement was achieved in all patients, and initial clinical success was achieved in 95.9% of patients (47/49). The mean duration of follow-up was 172.2 days (range 1–577 days). During follow-up, LAMS were removed in 61.2% of patients (30/49), with an average dwell time of 91.9 days (range 7–550 days).

Following LAMS removal, 15 patients (30.6%) required re-intervention, with 14 of these occurring in cases of anastomotic strictures (14/38 36.8%). Indwelling stents were not removed for the following reasons: 1) treatment was ongoing ($n=8$); 2), the stent had migrated and fallen out, without being removed by the endoscopist (this was discovered on follow-up imaging or follow-up repeat endoscopy; $n=3$); 3) patients were lost to follow-up ($n=3$); 4) LAMS placement was deemed destination therapy based on clinical judgement ($n=5$). Destination therapy means that after appropriate consent of the patient, the stent was left in place indefinitely with only imaging and/or endoscopic follow-up examinations to assess position and/or migration; these patients did not respond to multiple invasive attempts at treatment of the stricture and were deemed to be unsuitable candidates for surgery.

Stent migration

LAMS migration occurred in 17.9% of procedures (10/56); all migrated stents were either retrieved endoscopically or passed spontaneously. The migrated stents were predominantly those

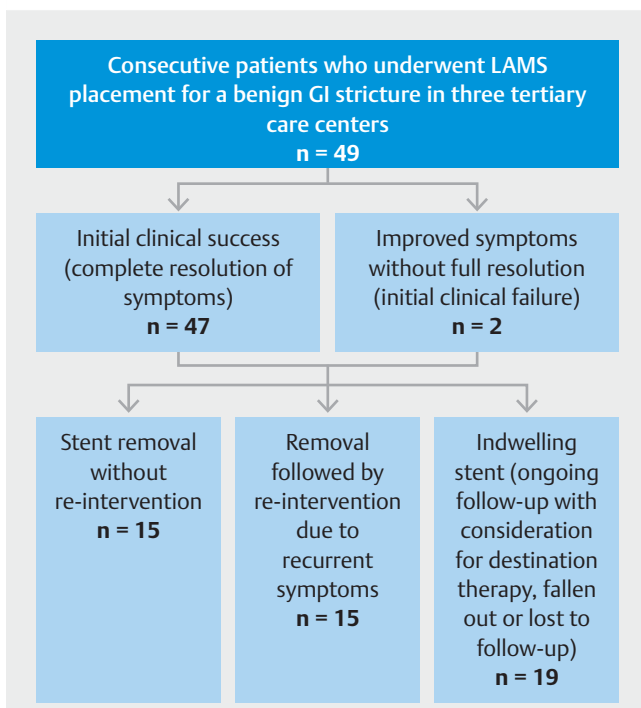
► **Table 1** Baseline characteristics and prior treatment.

	Patients (n = 49)	Nonanastomotic strictures (n = 11)	Anastomotic strictures (n = 38)	P value
Age, mean, years	51.4	57.2	49.7	0.18
Men, n (%)	21 (42.9)	4 (36.4)	17 (44.7)	0.74
BMI, mean, kg/m ²	23.7	23.7	23.6	0.99
Caucasian, n (%)	45 (91.8)	11 (100)	34 (89.5)	0.74
Refractory strictures ¹ , n (%)	39 (79.6)	10 (90.9)	29 (76.3)	0.42
Prior dilations ² , n (%)				
▪ ≥ 3 dilation sessions (%)	7/48 (14.6)	3 (27.3)	4/37 (10.8)	0.28
▪ < 3 dilation sessions (%)	31/48 (64.6)	7 (63.6)	24/37 (64.9)	
Prior steroid injection (%)	2/47 (4.3)	1 (9.1)	1/36 (2.8)	0.42
Prior FCSEMS, n (%)	13/47 (27.7)	2 (18.2)	11/36 (30.6)	0.70
Migration of prior FCSEMS, n (%)	5/46 (10.9)	1 (9.1)	4/35 (11.4)	> 0.99

BMI, body mass index; FCSEMS, fully-covered self-expandable metal stent; LAMS, lumen-apposing metal stent.

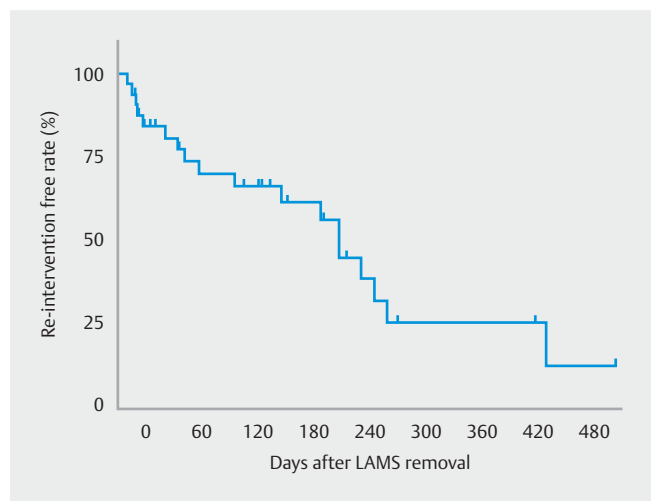
¹ The endoscopist determined the refractory nature of strictures clinically and endoscopically; this was defined as requiring at least two endoscopic procedures without improvement in index stricture appearance. Strictures that were treated immediately with LAMS (~20%) were clinically judged to warrant this management owing to multiple factors, such as anatomic location and appearance on index endoscopy.

² If an unknown number of dilations were performed, cases were categorized as <3 dilations.



► **Fig. 2** Flow chart detailing patient recruitment, initial clinical success, and follow-up of patients in the study. LAMS, lumen-apposing metal stent; GI, gastrointestinal.

inserted for lower GI strictures rather than upper GI strictures (45.5% [5/11] vs. 11.1% [5/45], respectively; $P=0.02$). Average duration from placement until migration was 54 days (range 6–215 days). Of the 10 migrated stents, only 2 caused symptoms; 8 were asymptomatic, and were discovered either on routine imaging or endoscopic scheduled follow-up.



► **Fig. 3** Rate of recurrence of symptoms leading to re-intervention in patients who underwent removal of lumen-apposing metal stents (LAMS). In this graph, the start point is date of LAMS removal, and the end point is the last follow-up (visit or call).

Procedural adverse events

The overall stent-related complication-free rate was 66.1% (37/56). None of the patients with an indwelling stent had any major adverse events during follow-up. Minor adverse events occurred in 33.9% (19/56) of procedures, none of which required hospitalization. LAMS were well tolerated, with 78.6% (44/56) fully tolerating the stent with no documented symptoms, 10.7% (6/56) having minor intolerance not necessitating hospitalization, 7.1% (4/56) with significant intolerance requiring medical attention (e. g. emergency room visits, clinic visits)

► **Table 2** Procedure and outcome variables.

Etiology	All procedures (n=56)	Nonanastomotic strictures (n=12)	Anastomotic strictures (n=44)	P value
Stricture length, mean, mm (n=51)	10.53	9.9	10.7	0.76
Procedure time, mean, minutes (n=35) (diagnostic and therapeutic endoscopy) ¹	46.8	49.8 (n=8)	46.0 (n=27)	0.80
Procedure time, mean, minutes (n=15) (therapeutic endoscopy only) ¹	3.8	4.0 (n=3)	3.75 (n=12)	0.76
Stent specifications, n (%)				
▪ 10 × 10 mm	1 (1.8)	0	1 (2.3)	
▪ 10 × 15 mm	55 (98.2)	12 (100)	43 (97.7)	
Stent removed, n (%)	35 (62.5)	5 (41.7)	30 (68.2)	0.12
Dwell time if removed, mean, days	100.6	175.4	88.2	0.41
Any adverse event, n (%)	19 (33.9)	2 (16.7)	17 (38.6)	0.19
▪ Pain	2 (3.6)	0	2 (4.5)	>0.99
▪ Bleeding	2 (3.6)	0	2 (4.5)	>0.99
▪ Perforation	0	0	0	
▪ Infection	1 (1.8)	0	1 (2.3)	>0.99
▪ Occlusion	3 (5.4)	1 (8.3)	2 (4.5)	0.52
▪ Adjacent stricture	6 (10.7)	1 (8.3)	5 (11.4)	>0.99
Mortality not related to LAMS, n (%)	2 (3.6)	1 (8.3)	1 (2.3)	0.39
Died with stent in place, n (%)	1 (1.8)	1 (8.3)	0	0.21
Time to complication, mean, days	74.2	279	51.4	0.48
Technical success, n (%)	56 (100)	12 (100)	44 (100)	
Initial clinical success, n (%)	54 (96.4)	12 (100)	42 (95.5)	>0.99
Secondary outcome: LAMS migration, n (%)	10 (17.9)	1 (8.3)	9 (20.5)	0.67
Follow-up time, mean, days	169.8	259.6	145.3	0.06

LAMS, lumen-apposing metal stent.

¹ Procedure time is reported for two separate groups depending on if the procedure time included both a diagnostic endoscopy and stent placement (diagnostic and therapeutic endoscopy), or just stent placement (therapeutic endoscopy only).

► **Table 3** Clinical success and re-intervention after removal of lumen-apposing metal stent.

	All procedures (n=56)	Nonanastomotic strictures (n=12)	Anastomotic strictures (n=44)	P value
Re-intervention performed, n (%)	17 (30.4)	1 (8.3)	16 (36.4)	0.08
▪ Balloon dilation, n (%)	6 (35.3)	0	6 (37.5)	
▪ Surgical resection, n (%)	2 (11.8)	0	2 (12.5)	
▪ Replaced with LAMS, n (%)	5 (29.4)	1 (100)	4 (25.0)	
▪ Replaced with Soleus stent, n (%)	2 (11.8)	0	2 (12.5)	
▪ Replaced with WallFlex stent, n (%)	1 (5.9)	0	1 (6.25)	
▪ Surgical Hegart dilation, n (%)	1 (5.9)	0	1 (6.25)	
Time to re-intervention ¹ , mean (SD), days	49.7 (78.3)	0	52.8 (79.8)	0.53

LAMS, lumen-apposing metal stent.

¹ Time to re-intervention is reported as the number of days elapsed between the date of initial stent extraction and re-intervention of any kind.

but completing the planned duration of stents, and 3.6% (2/56) not tolerating the stent and requiring early removal.

Adverse events included stent occlusion (5.4%), pain necessitating early removal (3.6%), minor GI bleeding not requiring hospitalization (3.6%), and an infectious complication in one patient (1.8%), which manifested as suspected sepsis and resolved with antibiotics (► **Table 2**). There were no perforations or stent-related deaths.

A stricture developed adjacent to the flanges in six procedures (10.7%), requiring replacement of the LAMS in one case. Of the LAMS that were removed, whether unplanned or planned, 17/56 (30.4%) required re-intervention owing to recurrence of symptoms (► **Table 3**). Comparison of anastomotic and nonanastomotic strictures did not reveal any significant differences in adverse events.

Discussion

Refractory GI strictures are often difficult to manage and, in many cases, there is no straightforward surgical approach to address them. Failure of traditional long cylindrical FCSEMS is usually attributed to high migration rates and poor tolerance, which limit the duration of therapy [9]. Intolerance of traditional stents may occur in 15% of patients [10], and up to 30% may experience significant chest pain, with almost half of them needing admission to hospital [11]. Furthermore, the migration rate is very high, exceeding 50% when not sutured [11], and up to 33% despite in situ suturing [8]. It seems that approaches to prevent migration, such as endoscopic suturing and over-the-scope clip placement, do not appear to improve patient tolerance; in addition, these methods increase procedure time, are technically challenging, and may not be readily available [8, 12]. In our study, we found that the average dwell time achieved with LAMS was superior to that reported for FCSEMS (100 vs. 21 days, respectively), with a lower migration rate compared with reported rates for unsutured or even sutured traditional stents (~18% vs. ~50% vs. 33%, respectively) [8, 10, 11]. LAMS migration events did not cause major complications, and most were noted incidentally on routine follow-up imaging or endoscopy. Overall, the findings from this study suggest that LAMS tolerability is very high compared with traditional stents [10, 11].

Although LAMS were well tolerated, when they were removed, most of the symptoms recurred owing to the recalcitrant nature of the strictures being treated. The re-intervention rate was high following stent removal, reaching almost 75% for those patients who reached 300 days of follow-up. Given this observation, a destination therapy strategy is reasonable given the relative tolerability and safety of LAMS. This opinion is supported by the fact that the majority of these strictures had already failed to resolve following multiple endoscopic sessions for dilation, steroid injections, needle-knife excisional therapy, and/or traditional stenting. Moreover, despite complete symptom resolution during the LAMS dwelling time, there was a high rate of stricture recurrence following stent removal. This may provide preliminary insight that a destination therapy strategy might be safe and effective in selected patients, and may repre-

sent a paradigm shift in the management of recalcitrant benign strictures when surgical options are not feasible or when the patient is not a surgical candidate. Initial clinical success of this intervention was demonstrated in the majority of patients who were treated with this strategy, but the long-term success has yet to be determined.

Traditional endoprosthetics do not alter the natural history of recalcitrant strictures [13], and our results do not show that LAMS are superior in this regard. In fact, this observation strengthens the possible role of LAMS placement as destination therapy in view of the aforementioned advantages, and in the absence of a safe and feasible surgical intervention. A minority of patients may remain symptom free after LAMS removal; thus, it is reasonable to attempt a stent-free trial to avoid destination therapy with LAMS. Nonetheless, a prospective controlled trial is needed to establish the long-term efficacy and safety of such a strategy, and the utility of LAMS as a first-line approach to luminal strictures.

Although our results are concordant with recently published reports in terms of high technical success for LAMS deployment, there are several limitations. Although it is the largest series to date, it was retrospective in nature, the overall sample size was relatively small, and no control arm was included. Second, follow-up was limited considering the novelty of this application. Third, we did not conduct a formal cost-effectiveness analysis of LAMS in the treatment of refractory strictures. Fourth, although we examined intermediate-term results (average follow-up being almost 6 months), we could not examine long-term results of this strategy given the limited follow-up time. Finally, we could not evaluate the behavior of these strictures in ethnic groups other than Caucasians. We acknowledge that different ethnicities may display different responses to therapy, which stems from variations in baseline cicatricial or healing characteristics [14]. We attempted to compensate for some of these shortcomings by displaying the granular characteristics, and by examining the pre- and post-treatment course in an adequate number of patients with greater follow-up.

In conclusion, LAMS placement was successful in the management of benign GI strictures, with high technical and initial clinical success rates in a cohort of patients who had exhausted or were poor candidates for traditional approaches. In refractory strictures, LAMS appear to be better tolerated and safer than conventional stents, and can remain in situ for longer periods, palliating symptoms over months of dwell time. Re-intervention rates after LAMS removal remain high, and many strictures are not resolved by an extended period of stenting with these coaxial stents. In the absence of other surgical or endoscopic alternatives, our data suggest that LAMS may be feasible and effective as a destination therapy. The performance characteristics and relative benefit of LAMS can be assessed further in a prospective randomized trial that examines the long-term durability and safety of this approach.

Competing interests

None

References

- [1] Ramage J Jr, Rumalla A, Baron TH et al. A prospective, randomized, double-blind, placebo-controlled trial of endoscopic steroid injection therapy for recalcitrant esophageal peptic strictures. *Am J Gastroenterol* 2005; 100: 2419–2425
- [2] Samanta J, Dhaka N, Sinha SK et al. Endoscopic incisional therapy for benign esophageal strictures: technique and results. *World J Gastrointest Endosc* 2015; 7: 1318–1326
- [3] de Wijkerslooth LR, Vleggaar FP, Siersema PD. Endoscopic management of difficult or recurrent esophageal strictures. *Am J Gastroenterol* 2011; 106: 2080–2091
- [4] Agnew SR, Pandya SP, Reynolds RP et al. Predictors for frequent esophageal dilations of benign peptic strictures. *Dig Dis Sci* 1996; 41: 931–936
- [5] Choi WJ, Park JJ, Park J et al. Effects of the temporary placement of a self-expandable metallic stent in benign pyloric stenosis. *Gut Liver* 2013; 7: 417–422
- [6] Walter D, Will U, Sanchez-Yague A et al. A novel lumen-apposing metal stent for endoscopic ultrasound-guided drainage of pancreatic fluid collections: a prospective cohort study. *Endoscopy* 2015; 47: 63–67
- [7] Adler DG. Esophageal placement of a lumen-apposing metal stent in a patient with a chronic anastomotic stricture. *Gastrointest Endosc* 2017; 85: 1291–1293
- [8] Fujii LL, Bonin EA, Baron TH et al. Utility of an endoscopic suturing system for prevention of covered luminal stent migration in the upper GI tract. *Gastrointest Endosc* 2013; 78: 787–793
- [9] Thomas T, Abrams KR, Subramanian V et al. Esophageal stents for benign refractory strictures: a meta-analysis. *Endoscopy* 2011; 43: 386–393
- [10] Suzuki T, Siddiqui A, Taylor LJ et al. Clinical outcomes, efficacy, and adverse events in patients undergoing esophageal stent placement for benign indications: a large multicenter study. *J Clin Gastroenterol* 2016; 50: 373–378
- [11] Dan D, Gannavarapu B, Lee J et al. Removable esophageal stents have poor efficacy for the treatment of refractory benign esophageal strictures (RBES). *Dis Esophagus* 2014; 27: 511–517
- [12] Wadhwa RP, Kozarek RA, France RE et al. Use of self-expandable metallic stents in benign GI diseases. *Gastrointest Endosc* 2003; 58: 207–212
- [13] Repici A, Small AJ, Mendelson A et al. Natural history and management of refractory benign esophageal strictures. *Gastrointest Endosc* 2016; 84: 222–228
- [14] Pasricha S, Li N, Bulsiewicz WJ et al. Sex and race and/or ethnicity differences in patients undergoing radiofrequency ablation for Barrett's esophagus: results from the U.S. RFA Registry. *Gastrointest Endosc* 2015; 82: 276–284