

Cholangioscopy-directed lithotripsy for a large bile duct stone: the “donut technique”

Conventionally, choledocholithiasis is managed by endoscopic retrograde cholangiopancreatography (ERCP), and it accounts for at least 50% of the approximately 52 000 ERCPs performed in the UK each year [1–5]. Bile duct stone clearance traditionally involves the performance of ERCP with biliary sphincterotomy (or sphincteroplasty), followed by the removal of stones from the biliary tree using an extraction balloon, with or without the use of a basket or mechanical lithotripter. Stones may be difficult to remove at ERCP owing to a range of factors, including size (e.g. stones >15 mm), number, location (e.g. intrahepatic or within the cystic duct), and other anatomical factors (e.g. stones above strictures).

Cholangioscopy was first introduced in 1975 as a dual-operator “mother–baby” technique and allowed direct visualization of intraductal stones and fragmentation of stones with laser or electrohydraulic lithotripsy (EHL). The technique fell out of widespread use because of technical and endoscopic limitations. In 2006, a single-operator cholangioscope was introduced (Spyglass; Boston Scientific Inc., Natick Massachusetts, USA), which reinvigorated the use of cholangioscopy in the management of difficult bile duct stones. In 2015, a second-generation Spyglass cholangioscope (Spyglass DS; Boston Scientific Inc.) was developed, with improved visualization and scope movement, and a larger (1.3 mm) working channel.

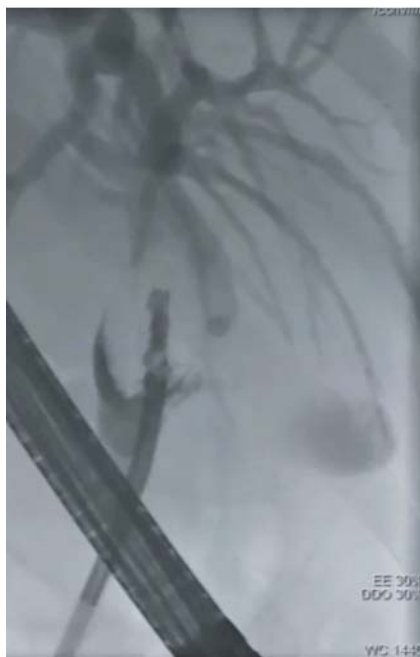Here we report the case of a 46-year-old woman who underwent cholangioscopy for an impacted 3-cm common bile duct

stone after three failed conventional ERCPs at her local hospital. We elected to perform an ERCP combined with cholangioscopy. Despite visually directed EHL, the stone could not be cracked, and therefore a tunnel was created through the stone (► Fig. 1), as shown in ► Video 1. This allowed a wire to be passed through the stone, which was then cracked using a dilating balloon. Subsequent uncomplicated stone clearance followed, with successful bile duct clearance.

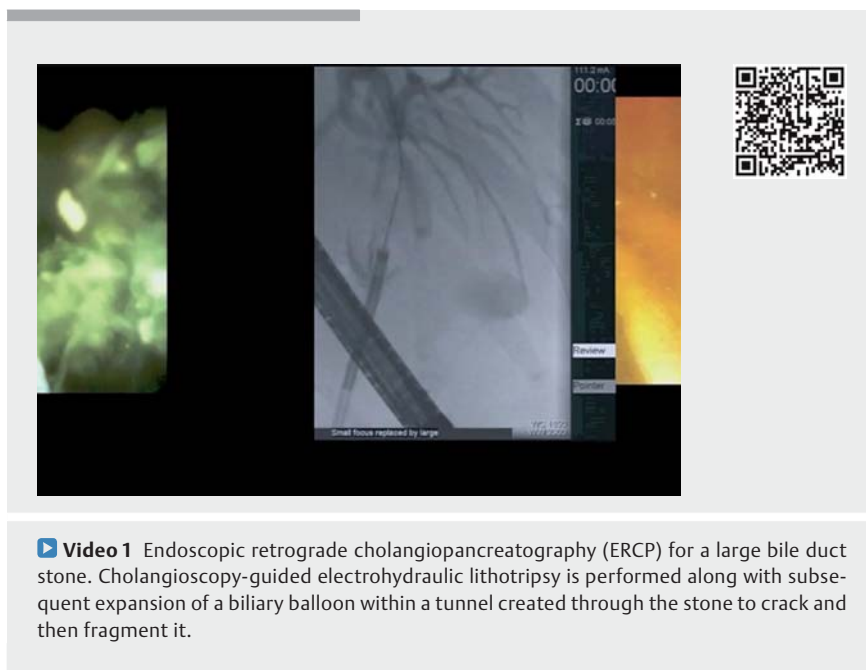
Endoscopy_UCTN_Code_TTT_1AR_2AH

Competing interests

Dr. Webster received honoraria from Boston Scientific.



► **Fig. 1** Cholangiogram showing the cholangioscope passing through the tunnel created with the electrohydraulic lithotripsy probe.



► **Video 1** Endoscopic retrograde cholangiopancreatography (ERCP) for a large bile duct stone. Cholangioscopy-guided electrohydraulic lithotripsy is performed along with subsequent expansion of a biliary balloon within a tunnel created through the stone to crack and then fragment it.

The Authors

Noor L. H. Bekkali, Sham Direkze, George J. M. Webster

GI services, Pancreato-biliary diseases,
University College London Hospitals, London,
UK

Corresponding author

George Webster, MD

University College London Hospitals,
250 Euston Road, NW1 2PG, London,
United Kingdom
Fax: +44-203-4479218
george.webster@uclh.nhs.uk

References

- [1] Everhart JE, Ruhl CE. Burden of digestive diseases in the United States Part III: Liver, biliary tract, and pancreas. *Gastroenterology* 2009; 136: 1134–1144
- [2] Everhart JE, Khare M, Hill M et al. Prevalence and ethnic differences in gallbladder disease in the United States. *Gastroenterology* 1999; 117: 632–639
- [3] Ko CW, Lee SP. Epidemiology and natural history of common bile duct stones and prediction of disease. *Gastrointest Endosc* 2002; 56: S165–S169
- [4] McHenry L, Lehman G. Difficult bile duct stones. *Curr Treat Options Gastroenterol* 2006; 9: 123–132
- [5] Baillie J, Testoni P-A. Are we meeting the standards set for ERCP? *Gut* 2007; 56: 744–746

ENDOSCOPY E-VIDEOS

<https://eref.thieme.de/e-videos>



Endoscopy E-Videos is a free access online section, reporting on interesting cases and new techniques in gastroenterological endoscopy. All papers include a high quality video and all contributions are freely accessible online.

This section has its own submission website at
<https://mc.manuscriptcentral.com/e-videos>

Bibliography

DOI <https://doi.org/10.1055/s-0043-113815>
Published online: 18.7.2017
Endoscopy 2017; 49: 1008–1009
© Georg Thieme Verlag KG
Stuttgart · New York
ISSN 0013-726X