

Road Map fluoroscopy successfully guides endoscopic interventions in the esophagus



Authors

Jochen Weigt¹, Wilfried Obst¹, Arne Kandulski¹, Maciej Pech², Ali Canbay¹, Peter Malfertheiner¹

Institutions

- 1 Department of Gastroenterology, Hepatology and Infectious Diseases, Otto-von-Guericke University, Magdeburg, Germany
- 2 Department of Radiology and Nuclear Medicine, Otto-von-Guericke University, Magdeburg, Germany

submitted 1.8.2016

accepted after revision 2.5.2017

Bibliography

DOI <https://doi.org/10.1055/s-0043-111719> |
Endoscopy International Open 2017; 05: E608–E612
© Georg Thieme Verlag KG Stuttgart · New York
ISSN 2364-3722

Corresponding author

Jochen Weigt, Department of Gastroenterology, Hepatology and Infectious Diseases, Otto-von-Guericke University, Leipziger Str 44, Magdeburg 39120, Germany
Fax: +493916713105
jochen.weigt@med.ovgu.de

ABSTRACT

Background and study aims Road Map (RM) fluoroscopy is a radiological technique that enables visualization of anatomic structures using image subtraction at peak opacifica-

tion. RM fluoroscopy has never previously been evaluated for use in endoscopy. The aim of this study was to evaluate the usefulness of RM in guiding endoscopic intervention in the esophagus.

Patients and methods This was a monocentric observational trial of consecutive patients with esophageal strictures in a university hospital. Twenty-seven investigations using RM were performed in 24 patients undergoing esophageal endoscopy. Indications for the procedure were balloon dilatation (n = 7 including 2 pneumatic balloon dilatations for treatment of achalasia), bougie dilatation (n = 7) and diagnostic endoscopy (n = 1). In addition, 12 stents, 7 partially covered and 5 fully covered, were placed using RM as a guide for determination of stent length and diameter. Stents were deployed under RM guidance.

Results In all procedures, RM successfully guided the intervention. Endoscopic control endoscopy confirmed adequate stent placement in all cases.

The feeling of resistance during bougie dilation matched the RM-predicted location of the stenosis. With the help of RM imaging, dilatation balloons were easily centered inside the stenosis and thus slipping of the balloon was avoided. There were no adverse events.

Conclusion RM allows permanent and accurate radiographic imaging of stenoses and esophageal anatomic changes. It is an easy and safe method of guiding endoscopic interventions that require radiological imaging.

Introduction

Digital subtraction angiography is a standard radiological method to enhance the contrast of anatomic structures after opacification with contrast media. Structures that are not of interest are deleted from the image by subtraction of image information. A variation of this technique is called Road Map (RM) fluoroscopy, in which an image at peak opacification is used as a mask for subsequent subtraction images [1]. Although the opacification is only performed once, the gathered information remains on the image throughout the investigation. With this technique, advancement of guidewires, stents or catheters can be viewed without additional marking or contrast injection. In addition, anatomical features such as length

or diameter of stenosis can be measured precisely [1–4]. At present, 3D-RM is used clinically in the setting of transarterial treatment of cerebral aneurysms [5].

Although esophageal stent placement has been reported to be safe without fluoroscopic guidance [6–8], use of fluoroscopy during stent deployment has not ceased.

Clinically, despite a lack of evidence, mucosal marking with injection of lipiodol (e.g. for stent implantation) or with external radiopaque markers is used by endoscopists to assist stent placement. This may no longer be necessary if RM is used to guide the procedure.

The use of RM has never previously been evaluated for use in endoscopic procedures. The goal of this study was to evaluate

the usefulness of RM to guide endoscopic intervention in the esophagus.

Patients and methods

All consecutive patients with esophageal strictures requiring endoscopy were enrolled in a monocentric observational trial at a University hospital. All patients gave written informed consent. Clinical trial registry was not performed. Patients were all investigated in recumbent position under sedation with midazolam or propofol. After endoscopic identification of the stenosis, an RM (Philips Multidiagnost Eleva, Philips Healthcare, Netherlands) scan was performed using 20 to 40 mL of water-soluble contrast media (Peritracast 300/60% Dr. Franz Köhler Chemie GmbH, Bensheim, Germany) which was applied through the working channel of a gastroscope (Fujifilm EG530NW or Olympus GIF-Q 180). RM recording requires stable fluoroscopy of the region of interest to generate a mask for consecutive subtraction. Thereafter, contrast medium was injected. After RM all further fluoroscopy images contained the subtraction overlay. All fluoroscopic examinations were performed with pulsed fluoroscopy at 2 Hz. Directly following RM completion, the esophagus was cleared of fluid to minimize the risk of aspiration. All further interventions and measurements were performed using the RM images.

Stenoses were subdivided into simple and complex. Simple strictures were defined as short (<2 cm) and straight and allowed passage of the diagnostic endoscope, while complex stenoses were longer, narrower and tortuous. The student's *t*-test was applied to express differences in patient subgroups. A *P* value below 0.05 was considered significant.

Results

Twenty-seven investigations were performed in 24 patients (median age: 70, range 4 months-89 years; male: 15 female: 9).

Indications for interventions were: balloon dilatation (*n*=7 including 2 pneumatic balloon dilatations for the treatment of achalasia), bougie dilatation (*n*=7) and diagnostic radiography without intervention: *n*=1 (see also ► **Table 1**).

A total of 19 patients were treated for stenosis. Of them, 11 had complex strictures and 8 had simple strictures. In addition, 12 stents, 7 partially covered and 5 fully covered, were placed using RM to guide determination of stent length and diameter. Stents were deployed under RM guidance (► **Fig. 1**). Endoscopic control revealed adequate stent position in all cases. The stent was selected according to measurements of the length of the stenosis as well as diameter of healthy esophagus adjacent to the stricture. Available stents that fitted the measured dimensions best were implanted (example: ► **Fig. 1**).

We placed a 30-mm long and 10-mm diameter fully covered stent with short flanges (Pseudocyst Stent Leufen Medical, Berlin, Germany) into a 3 ½-month-old baby suffering from esophageal atresia with remnant fistula and anastomotic stricture after surgery. The stent was removed after 3 weeks without migration. During this interval the stricture resolved and the fistula completely healed.

In all procedures RM fluoroscopy successfully guided the intervention. The feeling of resistance during bougie dilatation exactly matched the location of the stenosis on Road Map fluoroscopic projection (► **Fig. 2**). With the help of RM imaging, dilatation balloons were easily centered inside the stenosis and thus balloon slippage was avoided (► **Fig. 3**).

Mean radiation exposure expressed as dose area product was 218.12 Gy*m² (range 0.39 Gy*m² – 746.6 Gy*m²). Mean radiation exposure was higher during stent implantations compared to all other interventions (328.2 Gy*m² vs. 126.3 Gy*m²; *P*=0.0125). No difference in radiation exposure was seen comparing patients with simple strictures and complex strictures (118 Gy*m² vs. 259 Gy*m²; *P*=0.1736).

No adverse events occurred.

Discussion

The results of our investigation demonstrate the technical and clinical feasibility of RM imaging to guide endoscopic esophageal interventions.

For stent placement, RM fluoroscopy allows exact measurement of the length of the stenosis and the size of the adjacent tubular esophagus, facilitating choice of the most appropriate stent for the individual. Correct sizing of the placed stent is important to minimize risk of migration of fully covered stents [9]. In addition, marking the stenosis with external markers or injection with lipiodol appears to be less precise and might no longer be necessary. Until now, no scientific data have been available about use of radiopaque markers during esophageal stent implantation or dilatation. Marking the distal margin of a stenosis with lipiodol injection can be particularly difficult as the needle cannot be positioned at the exact end of the stenosis due to the narrowed space inside the stenosis. If lipiodol fluid drops out of the needle, it will be visible during the rest of the examination and thereby interfere with or even mislead the image interpretation.

Precise implantation of self-expandable metal stents reportedly can be monitored by transnasal endoscopy [10, 11]. However, that technique demands a second investigator and the availability of a transnasal gastroscope. In addition, use of transnasal gastroscopes is of particular use for stent positioning in proximal stenosis, where precise positioning of the stent is mandatory [11].

RM guidance with exact imaging of the stenosis was also helpful for Balloon and bougie dilatation by allowing the diameter of the dilatation device to be accurately chosen and to improve haptic feedback, particularly for bougie dilatation. The diameter of the dilatation device (Bougie/Balloon) is not only dependent on the stricture itself but also on the diameter of the adjacent esophagus. RM fluoroscopy helps to determine the exact anatomical features of a stenosis (length, diameter, percentage of healthy luminal diameter) and increases accuracy. A 10-year retrospective analysis of perforations that occurred during esophageal dilatation concluded that the diameter of dilatation balloons and bougies should be carefully considered. Perforations in this cohort occurred in strictures smaller than 10 mm in diameter that were dilated to diameters less than 12 mm

► **Table 1** Summary of clinical and technical features of all investigations.

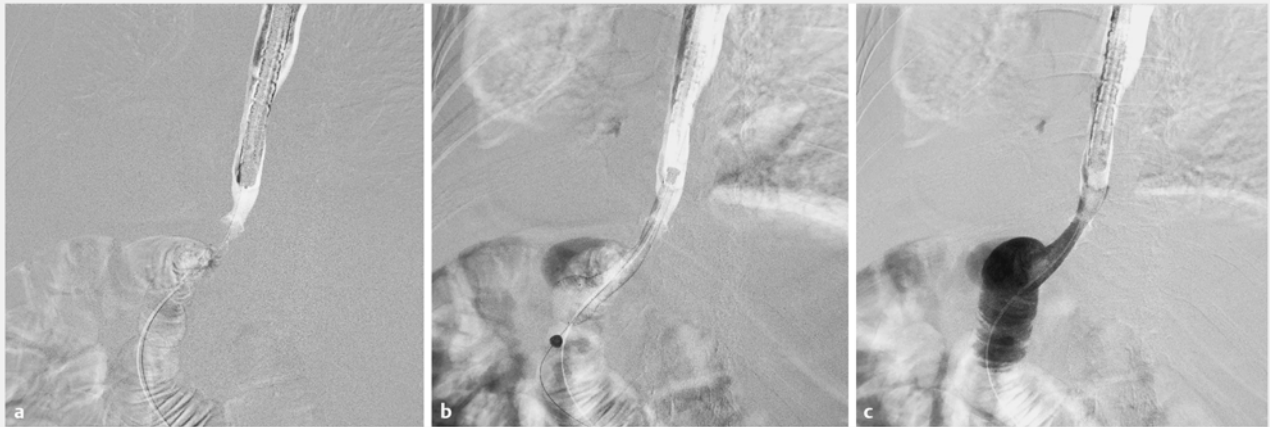
Nr.	Initials	Sex	Age	Stricture type	Intervention	Dose area product Gy*m ²	Classification
1	KHS	F	49	Compression caused by mediastinal metastasis of colon cancer	PCMS	138	c
2	BH	M	73	Esophageal cancer	PCMS	316	c
3	TH	F	81	Achalasia	FCSEMS	124	n.a.
4	RI	F	79	Achalasia	FCSEMS	244	n.a.
5	JC	F	79	Post-radiation stenosis	Dilatation 15 mm	9.3	s
6	KP	M	67	Peptic stenosis	Bougienage 10 mm	40,6	s
7	MP	M	61	Caustic injury	Dilatation 10 mm	90,6	c
8	DG	M	89	EGJ outflow obstruction	Dilatation 20 mm	159.8	s
9	MK	M	61	Peptic stenosis	Bougienage 14 mm	63.6	s
10	MK	M	61	Peptic stenosis	Bougienage 14 mm	68.5	s
11	EE	M	62	Peptic stenosis	only imaging	159.4	s
12	HS	F	65	Esophageal cancer	PCMS	664.9	c
13	SN	M	39	Peptic stenosis, intramural pseudo-diverticulosis	Bougienage 12 mm	162.1	c
14	FH	M	84	Achalasia	Pneumatic dilatation 30 mm	277.6	n.a.
15	GK	M	79	Peptic stenosis	Dilatation 12 mm	80.3	c
16	GK	M	79	Peptic stenosis	FCSEMS	334.7	c
17	GK	M	79	Peptic stenosis	Dilatation 12 mm	96.9	c
18	HH	F	72	Peptic stenosis	PCMS	139.7	s
19	WS	M	89	Esophageal cancer	PCMS	746.6	c
20	BG	M	70	Esophageal cancer	Bougienage 12 mm	70.06	c
21	HU	M	63	Esophageal cancer	PCMS	537.9	c
22	KP	M	67	Peptic stenosis	Bougienage 14 mm	318.7	s
23	KD	F	66	Post-dilatation perforation	FCSEMS	405.5	n.a.
24	JL	M	0,25	Post-surgical stenosis and fistula in esophageal atresia	FCSEMS	0.39	c
25	BE	F	82	Echalasia	Pneumatic dilatation 30 mm	251	n.a.
26	KHS	F	49	Esophageal cancer	PCMS	49.4	c
27	WE	M	70	Peptic stenosis	Bougienage 14 mm	52.6	s

PCMS, partially covered metal stent; FCSEMS, fully covered metal stent. The diameters behind dilatation and bougienage reflect the maximum diameter used in the intervention. Stenoses were subdivided into complex (c) and simple (s) stenosis.

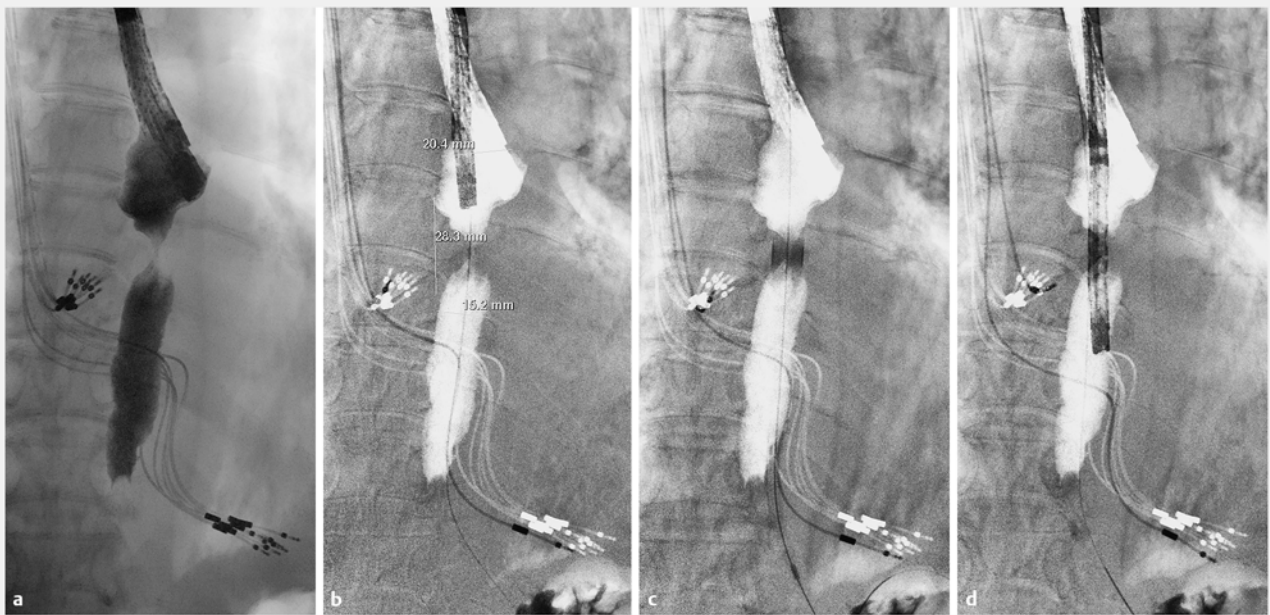
[12]. These results should be interpreted with caution because the exact method of assessment of luminal diameter is not explained and the endoscopic estimation of diameter is not sufficiently precise compared to objective radiological measurement. The main advantage of RM fluoroscopy in this setting is to have additional information about the esophageal lumen adjacent to the stricture. The value of this information has also never been evaluated in a study.

Another method for evaluating strictures in detail is impedance planimetry. Impedance planimetry shows high concordance to fluoroscopic investigations and gives information about the luminal diameter and mechanical compliance of the stenosis [13].

Because the RM image of the stricture is only virtual, movement of the patient after the imaging should be strictly avoided. The small movements that may occur naturally as the result of breathing, insufflation or movement of the endoscope dur-



► **Fig. 1** Road Map fluoroscopy of a malignant anastomotic stricture after gastrectomy for gastric cancer. **a** The narrowed distal esophagus and the small bowel can clearly be visualized. A guidewire is already in place. **b** Positioning of the stent delivery system. **c** Contrast passage directly after the deployment of the stent (additional contrast appears dark in Road Map).



► **Fig. 2** Case of a patient with a short peptic stricture in the lower third of the esophagus. **a** Fluoroscopic image during contrast deployment. **b** Road Map image including measurements for therapeutic intervention. **c** Passage of the bougie (12 mm). **d** Endoscope passage after intervention

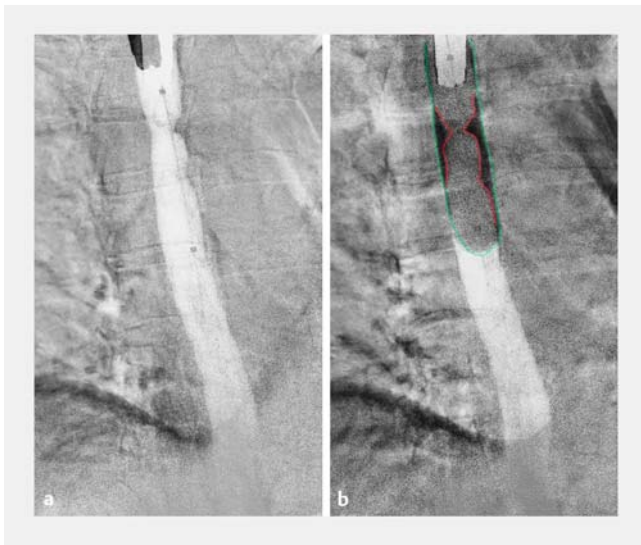
ing intervention, however, are acceptable. If larger movements occur a new RM should be performed for safety reasons. RM guidance may be also useful in assessment of other anatomic structures of the gastrointestinal tract, however, peristalsis in the small bowel or respiratory movement affecting the biliary tract may prove to be potential limitations.

A general limitation of our study is the lack of randomization and comparison to other techniques for endoscopic stricture therapy. Therefore, our study is only descriptive. Future research is needed to compare current methods with RM fluoro-

scopy to clarify its clinical value, although a gold standard technique for esophageal interventions has yet to be defined.

Conclusion

In conclusion, RM fluoroscopy allows permanent and accurate radiographic illustration of stenoses and anatomic changes during intervention. The contrast medium is only used at the beginning of the intervention. RM is easy to use and safe for guiding radiology-based endoscopic interventions in the



► **Fig. 3** Balloon dilatation of a stenosis after radiotherapy of esophageal squamous cell cancer. **a** Road Map image with the deflated CRE balloon. **b** Visualization of the stenosis during inflation of the CRE balloon. Notice the centered position of the balloon inside the stenosis. The esophageal lumen and the size of the balloon fit perfectly together. The green line outlines the shape of the diameter of the balloon. The red line marks the shape of the stenosis, which is still clearly visible during inflation of the balloon, thus giving direct information about the extent of dilatation.

esophagus. Finally, it appears that RM may help to determine the exact dimensions of stents better than endoscopy alone.

Acknowledgements

The authors thank Dr. Elizabeth Bird-Liebermann for support in writing and correcting the manuscript.

Competing interests

None

References

- [1] Turski PA, Stieghorst MF, Strother CM et al. Digital subtraction angiography "road map". *AJR Am J Roentgenol* 1982; 139: 1233–1234
- [2] Eckstein N, Orron DE, Vagman I et al. Digital road mapping image – a novel fluoroscopic real-time guide for selective transcervical catheterization in the treatment of proximal tubal obstruction. *Fertil Steril* 1992; 58: 850–853
- [3] Jackson JE, Adam A. Percutaneous transcaval tumour biopsy using a "road-map" technique. *Clin Radiol* 1991; 44: 195–196
- [4] McDermott JC, Babel SG, Crummy AB et al. Review of the uses of digital "road map" techniques in interventional radiology. *Ann Radiol (Paris)* 1989; 32: 11–13
- [5] Rossitti S, Pfister M. 3D Road-Mapping in the Endovascular Treatment of Cerebral Aneurysms and Arteriovenous Malformations. *Interv Neuroradiol J Peritherapeutic Neuroradiol Surg Proced Relat Neurosci* 2009; 15: 283–290
- [6] Austin AS, Khan Z, Cole AT et al. Placement of esophageal self-expanding metallic stents without fluoroscopy. *Gastrointest Endosc* 2001; 54: 357–359
- [7] Ben Soussan E, Antonietti M, Leclaire S et al. Palliative esophageal stent placement using endoscopic guidance without fluoroscopy. *Gastroentérologie Clin Biol* 2005; 29: 785–788
- [8] Wang Y-G, Tio T-L, Soehendra N. Endoscopic dilation of esophageal stricture without fluoroscopy is safe and effective. *World J Gastroenterol* 2002; 8: 766–768
- [9] Garbey M, Salmon R, Fikfak V et al. Esophageal stent migration: Testing few hypothesis with a simplified mathematical model. *Comput Biol Med* 2016; 79: 259–265
- [10] Borgulya M, Ell C, Pohl J. Transnasal endoscopy for direct visual control of esophageal stent placement without fluoroscopy. *Endoscopy* 2012; 44: 422–424
- [11] Lee KM, Shin SJ, Hwang JC et al. Proximal-releasing stent insertion under transnasal endoscopic guidance in patients with postoperative esophageal leakage. *Gastrointest Endosc* 2010; 72: 180–185
- [12] Hagel AF, Naegel A, Dauth W et al. Perforation during esophageal dilatation: a 10-year experience. *J Gastrointest Liver Dis JGLD* 2013; 22: 385–389
- [13] Scharitzer M, Lenglinger J, Schima W et al. Comparison of video-fluoroscopy and impedance planimetry for the evaluation of oesophageal stenosis: a retrospective study. *Eur Radiol* 2017; 27: 1760–1767