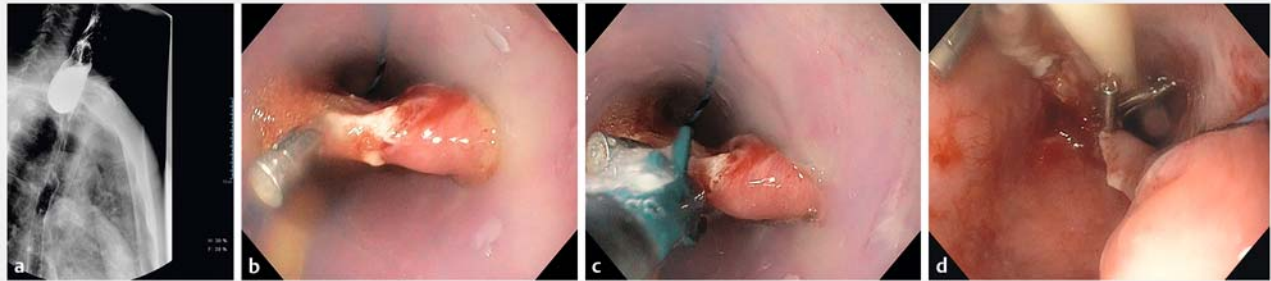


## Endoscopic treatment of Zenker's diverticulum using a stag beetle knife



**► Fig. 1** Endoscopic treatment of a Zenker's diverticulum. **a** Barium swallow showed a Zenker's diverticulum, 8 cm in size. **b** The Zenker's diverticulum overtube enables good visualization of the septum. **c** The Zenker's diverticulum overtube helps to define the base of the diverticulum and the length of the incision of the septum. **d** At the end of the procedure, three hemostatic clips were placed to prevent delayed bleeding and perforation.

Zenker's diverticulum can be treated successfully using flexible endoscopy [1]. Several methods have been used to cut the septum of the diverticulum, such as LigaSure (Medtronic, Minneapolis, Minnesota, USA), needle-knife, and other submucosal dissection devices. Recently, isolated cases using the stag beetle (SB) knife dissector, SB jr 3.5 mm, have been reported [2–4]. We present the case of a patient with a Zenker's diverticulum who was treated using an SB jr (Sumitomo Bakelite Co., Ltd, Japan) – an unusual device for this procedure.

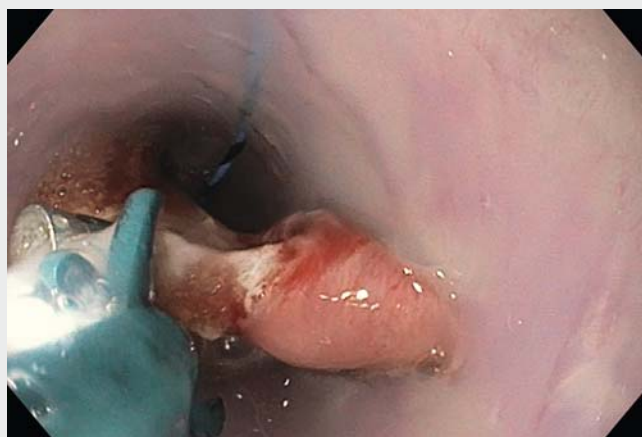A 72-year-old man with a history of chronic obstructive pulmonary disease was admitted to the hospital because of respiratory failure and weight loss. The patient had been experiencing progressive and severe dysphagia for several months. The barium study showed a Zenker's diverticulum of 8 cm in size (► Fig. 1 a). Dissection of the septum was planned.

As the patient was a high anesthetic risk, the procedure was performed under sedation with midazolam and propofol controlled by the endoscopist, without tracheal intubation (► Video 1). Initially, a Zenker's diverticulum overtube was not available, so we decided to perform the procedure using a hood and nasogastric tube with an SB standard 7 mm knife.

A PSD 60 Olympus Electrosurgical unit (Olympus, Tokyo, Japan) was used at Endocut mode 120W effect 1. The first current pulse was Forced coagulation 30W. However, the exposure of the septum was not adequate and after several cuts we decided to postpone the procedure until a Zenker's diverticulum overtube became available.

After several weeks, a Zenker's diverticulum overtube was obtained and was placed over a guidewire that had been in-

troducted into the esophagus under endoscopic view. When the Zenker's diverticulum overtube was in place, the septum was perfectly exposed (► Fig. 1 b), which allowed us to perform the procedure safely, quickly, and effectively. The procedure duration was 30 minutes and the length of the septum cut was 4 cm. The procedure was very well tolerated by the patient, with oxygen saturation of about 92%.



**► Video 1** Myotomy of a Zenker's diverticulum. After placing a Zenker's diverticulum overtube over a guidewire into the esophageal lumen, myotomy was performed using an SB junior 3.5 mm dissector, with great accuracy.

The Zenker's diverticulum overtube is important because it helps to identify the base of the diverticulum and define the length of the incision of the septum. In this case, we used the SB junior 3.5 mm dissector knife, which allows rotation and targeting of the cut with great accuracy (► **Fig. 1 c**). At the end of the procedure, three hemostatic clips were placed to prevent delayed bleeding and perforation (► **Fig. 1 d**). A barium swallow showed no extravasation of barium outside the esophageal lumen. The next day the patient swallowed liquids without any problems.

We present this case to highlight the following points. 1) Sedation managed by a nonanesthesiologist allowed the treatment of a patient with high surgical risk for tracheal intubation. 2) Use of a Zenker's diverticulum overtube is helpful to expose the septum clearly and define the length of the incision. 3) The SB knife enables accurate and targeted dissection of the septum.

Endoscopy\_UCTN\_Code\_TTT\_1AO\_2AD

### Competing interests

None

### The Authors

**Juan Manuel Martín-Guerrero<sup>1</sup>, Alba Belda-Cuesta<sup>1</sup>, Adan Lamilla-Fernández<sup>2</sup>**

- 1 Department of Gastroenterology, Hospital de la Merced, Osuna, Sevilla, Spain
- 2 Department of Internal Medicine Department, Hospital de la Merced, Osuna, Sevilla, Spain

### Corresponding author

**Juan Manuel Martín-Guerrero, MD, PhD**

Department of Gastroenterology, Hospital de la Merced, Avda. de la constitución nº 2, 41640. Osuna, Seville, Spain  
 Fax: +34-95-5077261  
 jornadasosuna@gmail.com

### References

- [1] Ishaq S, Hassan C, Antonello A et al. Flexible endoscopic treatment for Zenker's diverticulum: a systematic review and meta-analysis. *Gastrointest Endosc* 2016; 83: 1076 – 1089
- [2] Goelder S, Brueckner J, Messmann H. Endoscopic treatment of Zenker's diverticulum with the stag beetle knife (sb knife) – feasibility and follow-up. *Scand J Gastroenterol* 2016; 51: 1155 – 1158
- [3] Battaglia G, Antonello A, Realdon S et al. Flexible endoscopic treatment for Zenker's

diverticulum with the SB Knife. Preliminary results from a single-center experience. *Dig Endosc* 2015; 27: 728 – 733

- [4] Ramchandani M, Reddy D. New endoscopic "scissors" to treat Zenker's diverticulum (with video). *Gastrointest Endosc* 2013; 78: 645 – 648

### Bibliography

DOI <https://doi.org/10.1055/s-0043-111715>

Published online: 31.7.2017

*Endoscopy* 2017; 49: E223–E224

© Georg Thieme Verlag KG

Stuttgart · New York

ISSN 0013-726X

### ENDOSCOPY E-VIDEOS

<https://eref.thieme.de/e-videos>



*Endoscopy E-Videos* is a free access online section, reporting on interesting cases and new

techniques in gastroenterological endoscopy. All papers include a high quality video and all contributions are freely accessible online.

This section has its own submission website at

<https://mc.manuscriptcentral.com/e-videos>