

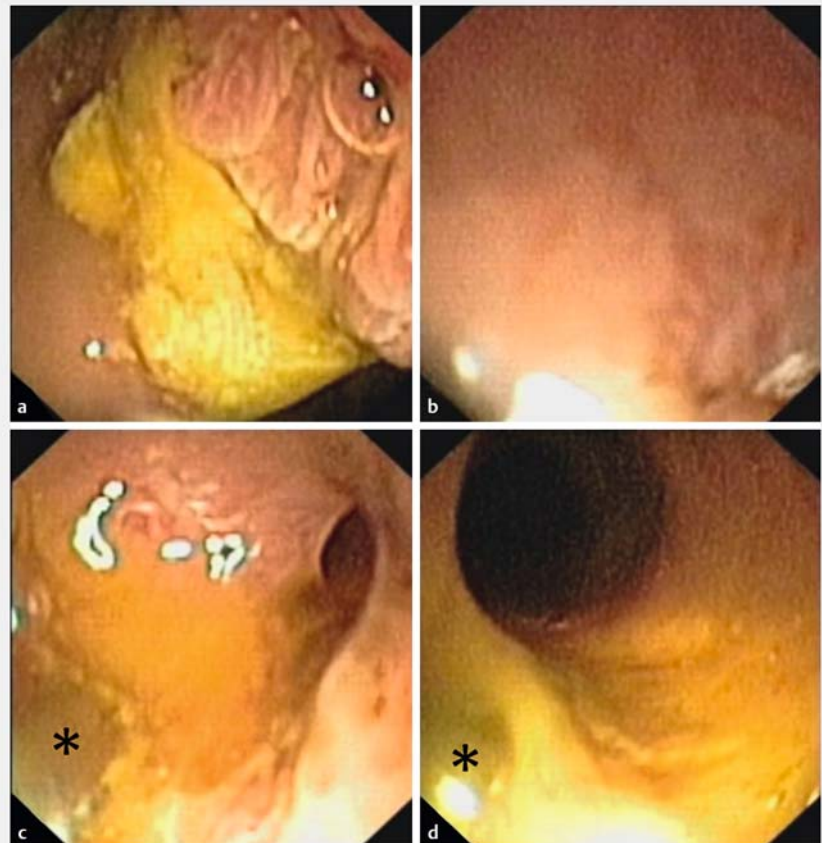
Knock-knock-knockin' on bile duct's door: the "tip-of-the-biopsy-forceps technique" – probing the route during freehand-intubated direct cholangioscopy

Direct cholangioscopy is a highly innovative field in pancreaticobiliary endoscopy; however, its wider dissemination is hampered by high technical procedural demands and/or the need for specialized equipment. Much technological progress is underway including clinical evaluation of double-bending cholangioscopes and next-generation anchoring balloons [1] [2]. By contrast, freehand intubation for direct cholangioscopy has largely been discredited by expert opinion, even though high rates of technical success have been published in single series and individual clinical reports [3].

Here, I report on a novel, easy-to-implement technique to facilitate freehand intubation, called the "tip-of-the-biopsy-forceps technique" (► [Video 1](#)). ► **Fig. 1 a** shows a papilla at the rim (2 o'clock position) of a periampullary diverticulum after medium-incision papillotomy, with an air bubble highlighting its entrance (Olympus XP-160, outer diameter 5.9 mm; Olympus, Hamburg, Germany). In successful freehand direct cholangioscopy, it is important to attain close tissue contact during intubation; however, this creates a higher risk of obscured visual orientation ("red out") (► **Fig. 1 b**). Similar to cap assistance in other endoscopy applications, gentle probing with the tip of a biopsy forceps achieves minimal distance from the mucosa, resulting in anatomic reorientation in an acutely angulated prepapillary bile duct (► **Fig. 1 c**; asterisk shows the tip of the forceps), which is firmly intubated in a stable scope position after adjusting the axis (► **Fig. 1 d**).

The presented novel rescue maneuver for difficult freehand intubation for direct cholangioscopy may provide valuable assistance in regaining orientation, while properly maintaining close contact with the papillary mucosa.

Endoscopy_UCTN_Code_TTT_1AR_2AK



► **Fig. 1** Successful freehand direct cholangioscopy using a "tip-of-the-biopsy-forceps technique." **a** View of the papilla on the rim of a periampullary diverticulum (2 o'clock position) after medium-incision papillotomy. Note the air bubble, which highlights the papilla entrance. **b** "Red out" after scope advancement for direct cholangioscopy by freehand intubation, with close contact with the papillary mucosa. **c** The "tip-of-the-biopsy-forceps technique", which is similar to cap-assisted endoscopy, is instrumental in achieving minimal mucosal distance, thus recovering visual orientation. **d** Stable intubation of the distal bile duct, with the tip of the forceps probing the route and helping to attain close mucosal contact. *Tip of the biopsy forceps.

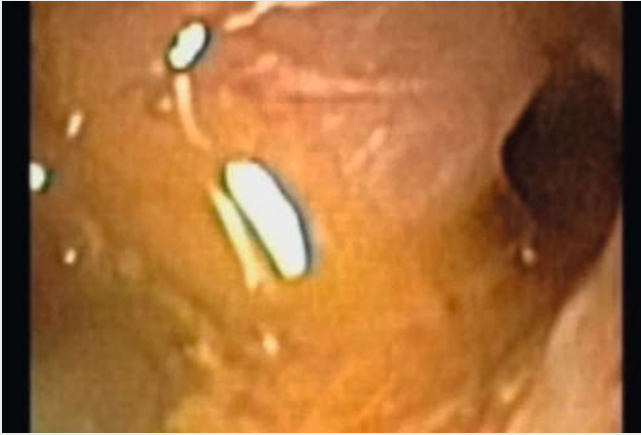Competing interests

None

The Author

Vincent Zimmer^{1,2}

- 1 Department of Medicine, Marienhausklinik St. Josef Kohlhof, Neunkirchen, Germany
- 2 Department of Medicine II, Saarland University Medical Center, Saarland University, Homburg, Germany



Video 1: The “tip-of-the-biopsy-forceps technique” to facilitate freehand intubation for direct cholangioscopy. This rescue technique is considered critical in reconciling the delicate balance between adequate mucosal contact and visual orientation during intubation of the papilla in a freehand fashion.

Corresponding author

Vincent Zimmer, MD

Department of Medicine, Marienhausklinik
St. Josef Kohlhof, Klinikweg 1–5, 66539
Neunkirchen, Germany
Fax: +49-6821-3632624
vincent.zimmer@gmx.de

References

- [1] Beyna T, Farnik H, Sarrazin C et al. Direct retrograde cholangioscopy with a new prototype double-bending cholangioscope. *Endoscopy* 2016; 48: 929–933
- [2] Lee YN, Moon JH, Choi HJ et al. A newly modified access balloon catheter for direct peroral cholangioscopy by using an ultraslim upper endoscope (with videos). *Gastrointest Endosc* 2016; 83: 240–247
- [3] Brauer BC, Chen YK, Shah RJ. Single-step direct cholangioscopy by freehand intubation using standard endoscopes for diagnosis and therapy of biliary diseases. *Am J Gastroenterol* 2012; 107: 1030–1035

Bibliography

DOI <https://doi.org/10.1055/s-0043-106047>
Endoscopy 2017; 49: E153–E154
© Georg Thieme Verlag KG
Stuttgart · New York
ISSN 0013-726X

ENDOSCOPY E-VIDEOS

<https://eref.thieme.de/e-videos>



Endoscopy E-Videos is a free access online section, reporting on interesting cases and new techniques in gastroenterological endoscopy. All papers include a high quality video and all contributions are freely accessible online.

This section has its own submission website at
<https://mc.manuscriptcentral.com/e-videos>