

Association Between Years of Experience and Ankle Joint Disorder in Male Student Basketball Players Based on Ultrasonography



Author

Yaeko Fukushima

Affiliation

Graduate School of Medicine, Kansai Medical University, Health Science, Osaka, Japan

Key words

basketball, ankle joint, ultrasound, ultrasonography

received 17.10.2016

revised 16.01.2017

accepted 10.02.2017

Bibliography

DOI <http://dx.doi.org/10.1055/s-0043-105069>

Ultrasound Int Open 2017; 3: E69–E75

© Georg Thieme Verlag KG Stuttgart · New York

ISSN 2199-7152

Correspondence

Dr. Yaeko Fukushima
Graduate School of Medicine
Kansai Medical University
Health Science
2-5-1 Shin-machi
573 1191, Osaka
Japan
Tel.: + 81/072/804 2821
bsk-80@outlook.com

ABSTRACT

Purpose The goal of the study was to survey ankle joint disorder in male senior high school and college student basketball players based on the results of an ultrasonographic medical check-up of the ankle joint.

Materials and Methods The subjects were 17 senior high school student and 19 college student basketball players. Ultrasonography, evaluation of ATFL injury, and examination of the talocrural joint region were performed. The subjects were grouped based on the presence or absence of old ATFL injury, and subjects with ATFL injury were classified by the injured region: fibular insertion site, parenchyma, and talar insertion site. The talocrural joint region was evaluated based on the areas of the lateral margin, central region, and medial margin, and sites with an irregular bone contour and osteophyte were counted individually. The questionnaire asked about the patients' history of ankle injuries.

Results A questionnaire survey revealed that 70–79% of all subjects had experienced a sprain at least once and 21–29% had frequently sprained the left or right foot 10 or more times in the past. On ultrasonography, there was no significant difference in ligament injury or injured site between the senior high school and college students, but the number of osteochondral findings in the talocrural joint region was significantly higher in the college students. In addition, the number of injured sites significantly increased in those with 10 or more years of playing experience.

Conclusion These results suggest that disorder of the talocrural joint region progresses with an increase in years of experience in student basketball players who do not take specific preventive measures against this injury.

Introduction

Inversion sprain of the ankle joint occurs frequently in basketball players and lateral ligament injuries of the ankle joint account for 45% of all traumas in basketball [1, 2]. Of these injuries, the incidence of anterior talofibular ligament injury is the highest [3], and this is the primary cause of lateral instability of the ankle joint, for which concomitant occurrence of osteochondral injury in the talocrural joint region is of concern [4–6]. McKay reported the rate of ankle injury and risk factors of ankle injuries in basketball players. The chronic ankle symptoms were as high as 74% [7]. Turner et al. reported physical activity levels in college students who have chronic ankle instability were decreased in comparison to the healthy group [8]. It is important to prevent these pathological conditions from developing, so children should be trained correctly from a young age [8, 9].

The repair process of osteochondral injury and impacts between bones in the talocrural joint due to frequent sprains promote osteo-

phyte formation and may cause pain and restriction of the range of motion [10–12]. Persistence of this condition may induce osteoarthritis of the ankle and markedly reduce ADL.

It has also recently been reported that ankle joint sprain may be a risk factor for anterior cruciate ligament injury of the knee [13]. Therefore, prevention of this pathological condition is important because it may trigger a disorder-trauma chain in athletes. However, understanding of the actual state of ankle joint disorder and its prevention is insufficient in student players. Moreover, medical care for student players is limited compared to that for professional and national sports teams. Thorough medical checkups of the joint should be performed for student players who are immature physically, and this may promote the development of promising players with reduced disorders.

With this background, we used a team approach including an orthopedist expert in ultrasonography diagnosis for musculoskeletal sports injuries, athletic trainers and physical therapists for

student basketball players as an educational activity for injury prevention. A questionnaire survey, ultrasonography screening, and physical condition checks were performed.

Ultrasonographic diagnostic equipment was set up in trainer booths in basketball competition venues in Kyoto Prefecture, and past sprains were surveyed by questionnaire. A simple flexibility evaluation (anteflexion, open-leg anteflexion, bending of the upper body backward, twisting the body at the waist (left and right), kicking the buttocks (left and right), lying down from sitting straight, open leg, and 5-grade evaluation of the ankle) was performed by physical therapists and trainers, and ankle joints were checked using ultrasound. Self-care guidance was provided to student players based on the results of the flexibility evaluation and ultrasonography. This simple flexibility evaluation method designed by Bright Body is used for regular student training.

We have previously found that frequent past sprains significantly increase osteochondral findings and that appropriate concomitant use of orthosis inhibits the increase in osteochondral findings in subjects with frequent sprains, based on ultrasonographic data in medical checkup of ankle joints in 71 senior high school student basketball players [14]. Ultrasonography is one of the convenient and helpful tools to screen for sports injuries. According to our results, wearing an ankle supporter might be useful for preventing the development of an osteophyte for young student basketball players [14].

In this current study, data collected from male senior high school and college student players were analyzed to investigate the influence of frequent sprains on the ankle joint.

Subjects and Methods

Subjects

The subjects were 17 senior high school students who participated in a senior high school student basketball competition in Kyoto prefecture (mean age: 16.4 years old) and 19 college students who played in the Kansai League Division 1 (mean age: 20.4 years old).

Methods

Ultrasonography of the ankle joint

Ultrasonographic diagnostic equipment (Noblus, Hitachi-Aloka Medical, Ltd., Tokyo) was set up in a trainer booth at a student basketball competition venue, and tests were performed by orthopedic surgeons with 8 or more years of experience in the ultrasonographic examination of motor organs. Senior high school and college student players who voluntarily participated in the checkup between games were examined. Subjects with no acute trauma were scanned using a 5–18 MHz radiofrequency linear probe (L64) while sitting on a chair with their legs straight and ankle flexed and resting on another chair with pressure on the heel to create a slight anterior stress. The presence of an old anterior talofibular ligament (ATFL) injury was evaluated based on the long-axis view visualized by scanning the lateral ankle joint. Subjects were evaluated as grades 0 or 1 (healthy ankle) and 2 or 3 (injured ankle), with reference to the ultrasonographic classification of old ATFL injury described by Cheng et al. [15] We set up the healthy ankle group and the injured ankle group and both feet of every player were evaluated in 5 min (► **Fig. 1a, b**). The injured ankle group was further

classified based on the injured region: fibular side, the central region of the ligament, and talar side [16]. In the long-axis view of the dorsal ankle joint scan, the talocrural joint was observed based on the area of the lateral margin, central region, and medial margin. The evaluation included several items, with counts of individual irregular bone contours and osteophytes.

Questionnaire

Physical findings (age, gender, height, and body weight), past sprains, the current status of ankle joint pain, and use of aids were evaluated via a questionnaire survey. An additional questionnaire survey was used to evaluate each joint. Subjects selected the number of sprains that they were aware of: 0, 1–4, 5–9, or ≥ 10 . Regarding current ankle joint pain, the presence of pain at rest and in motion was also surveyed. Finally, students were questioned about their use of orthosis during practice.

Statistical analysis

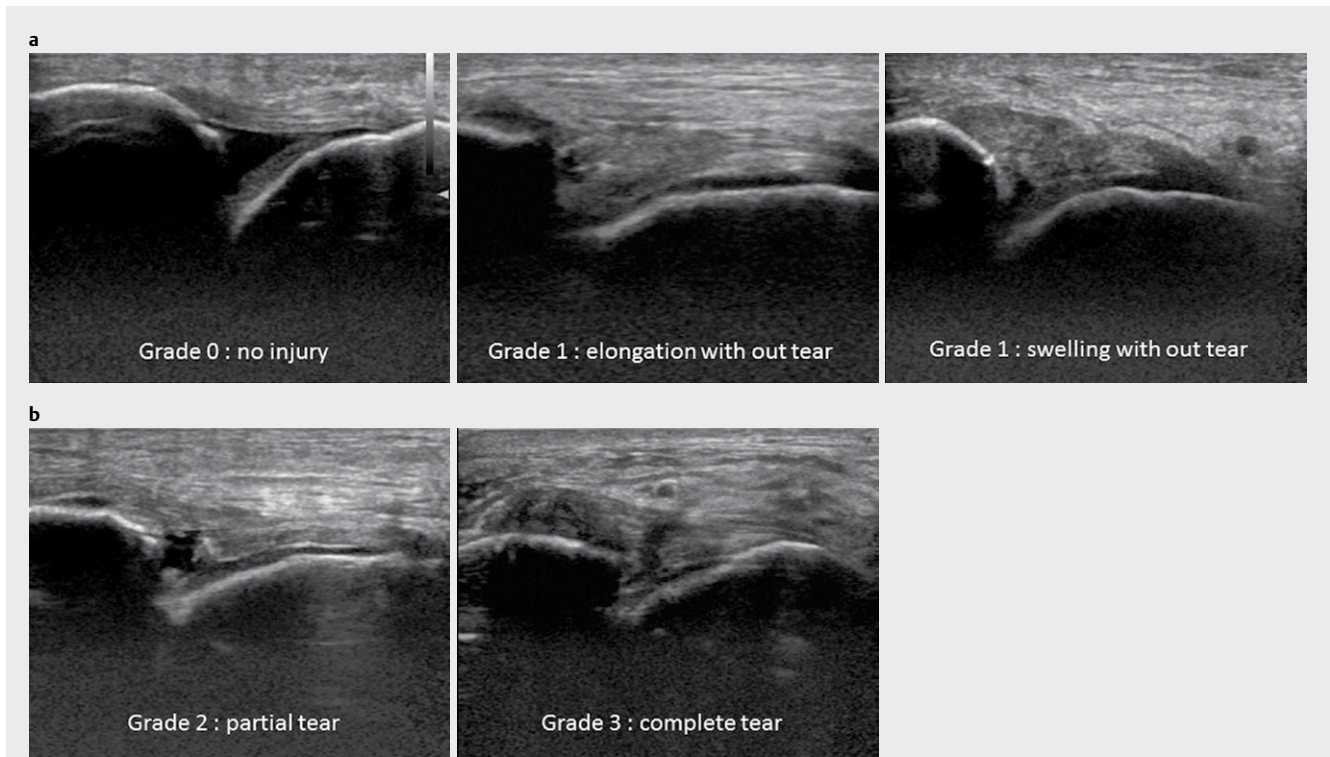
Data from the questionnaire were handled as qualitative variables, excluding physical findings, and used as ordinal and nominal scales. Between-group comparison of background factors was performed by a Mann-Whitney U-test. Subjects were divided into groups with < 10 and ≥ 10 previous sprains, groups with and without ATFL injury, and groups with and without osteochondral findings, and all measurement items were compared between the bilateral sides in the high school and college students using a χ^2 test. All analyses were performed using SPSS ver. 21 for Windows (SPSS Inc., USA), with the significance level set at $< 5\%$.

Results

Questionnaire findings

17 senior high school students who were members of Kyoto prefectural final 16-level clubs (mean age: 16.4 years old) and 19 college students who played in Kansai League Division 1 (mean age: 20.4 years old) voluntarily participated in the checkup. The mean height and body weight were 180.9 ± 8.5 cm and 72.5 ± 9.3 kg in the senior high school students, and 180.1 ± 7.2 cm and 74.1 ± 8.3 kg in the college students, with no significant difference between the groups. The mean years of experience in the respective groups were 8.1 ± 1.7 and 11.9 ± 2.5 years, with significantly longer experience in the college students ($P < 0.01$) (► **Table 1**). 16 of the 19 college students had experience ≥ 10 years (► **Fig. 2**).

Based on the questionnaire survey, 70.6% and 76.5% of the high school students and 73.7% and 79.0% of the college students had one or more past sprains on the right and left sides, respectively. More than 20% in both groups reported that they had ≥ 10 past sprains, suggesting the presence of frequent sprain-induced ankle joint instability (high school students: right, 29.4%; left, 23.5%; college students: right, 26.3%; left, 21.1%), with a higher frequency on the right side. Pain at rest on the right and left sides was present in 11.8% and 11.8% of the high school students, and in 15.8% and 10.5% of the college students; and pain in motion on the right and left sides was present in 29.4% and 35.3% of the senior high school students and 21.1% on both sides in the college students.



► **Fig. 1** **a** Healthy ankle group The healthy ankle group (grades 0: no injury and 1: elongation without tear and swelling without tear) has no old tears of the ATFL. **b** Injured ankle group The injured ankle group (grade 2: partial tear and grade 3: complete tear) has an old tear of the ATFL.

► **Table 1** Comparison of background factors in the groups.

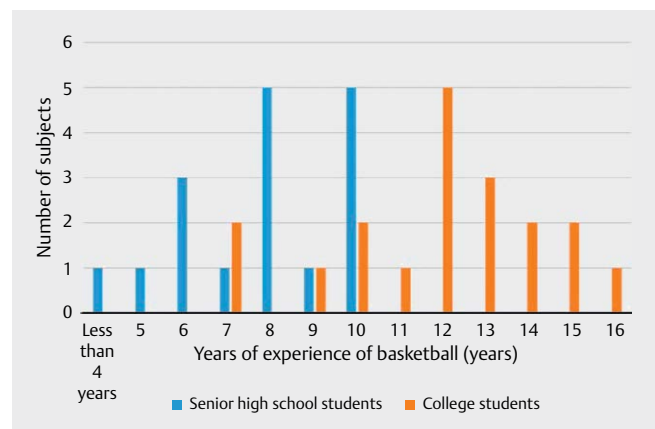
	Senior high school students (n = 17) (%)	College students (n = 19) (%)
Age	16.4 ± 0.9	20.0 ± 0.8 *
Height	180.9 ± 8.5	180.1 ± 7.2
Body weight	72.5 ± 9.3	74.1 ± 8.3
Years of basketball experience (years)	8.1 ± 1.7	11.9 ± 2.5 *

* P < 0.01, Mann-Whitney U-test

There was no significant laterality or difference between the high school and college students (► **Table 2**).

Ultrasonographic checkup of the lateral side (old ATFL injury)

Old ATFL injury was observed at high frequencies in senior high school and college students, with rates on the right and left sides of 64.8% and 82.4%, respectively, in the high school students, and 84.2% and 100%, respectively, in the college students. The frequency was higher on the left side in both groups (► **Table 3**). By region, the highest frequency (35.2%) was found in the central region of the ligament on the right side in the high school students.



► **Fig. 2** Years of basketball experience in all subjects 16 of the 19 college students had experience of ≥ 10 years. Therefore, we divided the subjects into 2 groups: one group with 10 or more years of experience and one group with less than 10 years of experience.

The frequency on the left side was 17.6%, whereas it was 36.8% on both sides in the college students. Rupture on the fibular side was found on the right and left sides in 17.6% and 35.3% of the high school students, and at higher rates of 26.3% and 42.1% in the college students. The rates of rupture of the talar side on the right and left sides were 0.0% and 17.6% in the high school students, and 5.3% and 0% in the college students. The rates of old fibular sprain fracture on the right and left sides were 11.8% and 5.9% in the high school students, and 15.8% on both sides in the college students.

The frequency of old talar sprain fracture was 0% on the right side in both groups, but 5.9% and 5.3% on the left side in the high school and college students, respectively (► **Table 3**).

Ultrasonographic checkup of the dorsal side (talocrural joint region)

The results of the ultrasonographic checkup of the talocrural joint region are shown in ► **Table 4**. Positive findings were detected at rates of 20.6% and 23.5% on the right and left sides in the senior high school students and at higher rates of 55.6% and 50.0% in the college students. By region, there were many findings in the lateral region on the bilateral sides in the high school students (right: medial side, 5.9%; central region, 2.9%; lateral side, 11.8%; left: medial side, 5.9%; central region, 8.9%; lateral side, 8.9%). In the college students, there were many findings in the central region on

the right side and lateral region on the left side (right: medial side, 11.1%; central region, 27.8%; lateral side 16.7%; left: medial side, 8.3%; central region, 19.4%; lateral side, 22.2%). There were no serious findings, such as intra-articular hematoma, synovial hyperplasia, apparent fracture, and lesions extending to subchondral bone. No osteochondral findings such as osteochondritis dissecans characteristic of the anterior talocrural joint region within the area could be shown by ultrasonography, but the college students had significantly more findings of osteophyte on the right side ($P < 0.05$) and also on the left side, although without a significant difference ($P = 0.068$) (► **Table 4**).

Comparison by years of experience of basketball (≥ 10 years vs. < 10 years)

The subjects were divided into groups with ≥ 10 ($n = 22$) and < 10 ($n = 14$) years of experience. The frequency of osteochondral findings in the talocrural joint region was significantly higher in the group with ≥ 10 years of experience on the bilateral sides (right: $P < 0.05$, left: $P < 0.01$) (► **Fig. 3**). The number of findings was also significantly higher in the group with ≥ 10 years of experience (right: $P < 0.05$, left: $P < 0.05$) (► **Fig. 4**).

Discussion

On ultrasonography, there was no significant difference in the presence of ligament injury or the injured site between senior high school and college students, but the number of osteochondral findings in the talocrural joint region was significantly higher in college students, and the frequency of disorder and number of impaired sites were significantly higher in the group with ≥ 10 years of experience. These findings show that disorder of the talocrural joint region on ultrasonography progresses with more years of experience in student players who do not take specific preventive measures. Medical care for student players is not as good as that for corporate and national sports teams. Active medical checkups of motor organs and educational activities for prevention in student

► **Table 2** Comparison of history of sprain and current pain in the 2 groups.

	Senior high school students (n = 17) (%)		College students (n = 19) (%)	
	Right foot	Left foot	Right foot	Left foot
Sprain in the past (one or more) (%)	70.6	76.5	73.7	79.0
Frequent sprain in the past (10 or more) (%)	29.4	23.5	26.3	21.1
Pain at rest (%)	11.8	11.8	15.8	10.5
Pain during motion (%)	29.4	35.3	21.1	21.1

χ^2 test was performed. There was no significant laterality or difference between the senior high school and college students

► **Table 3** Results for old ATFL injury on ultrasonography in the 2 groups.

Items	Right foot (n) (%)			Left foot (n) (%)		
	Senior high school students	College students	P	Senior high school students	College students	P
Old ATFL injury	64.8	84.2	0.168	82.4	100	0.095
Injured site						
n.p	35.2	15.8	0.673	17.6	0	0.185
Center of the ligament	35.2	36.8		17.6	36.8	
Fibular side	17.6	26.3		35.3	42.1	
Talar side	0	5.3		17.6	0	
Sprain fracture: fibular side	11.8	15.8		5.9	15.8	
Sprain fracture: talar side	0	0		5.9	5.3	

χ^2 test was performed. There were no significant differences for old ATFL injury between the senior high school group and the college students

► **Table 4** Findings in the talocrural joint region on ultrasonography in the 2 groups.

Items	Right foot (n) (%)			Left foot (n) (%)		
	Senior high school students	College students	P	Senior high school students	College students	P
Findings in talocrural joint	20.6	23.5	0.220	55.6	50.0	0.350
Injured site						
n.p	79.4	44.4	<0.05	76.5	50.0	0.068
Lateral region	11.8	16.7		8.9	22.2	
Central region	2.9	27.8		8.9	19.4	
Medial region	5.9	11.1		5.9	8.3	

χ^2 test was performed. There were no osteochondral findings characteristic of the talocrural joint region, but the college students had significantly more findings on the right side ($P < 0.05$) and also on the left side, although without a significant difference ($P = 0.068$)

players who are immature physically and lack knowledge may allow promising players to develop with fewer disorders.

Most senior high school students who play for Kyoto prefectural final 16-level clubs and then continue to play basketball in college will play in Kansai League Division 1. Height and body weight did not differ significantly between the student groups, and the only significant difference was found in years of basketball experience (high school students: 8.1 ± 1.7 years, college students: 11.9 ± 2.5 years). Since 16 of the 19 college students had ≥ 10 years of experience, the cutoff for grouping was set at 10 years.

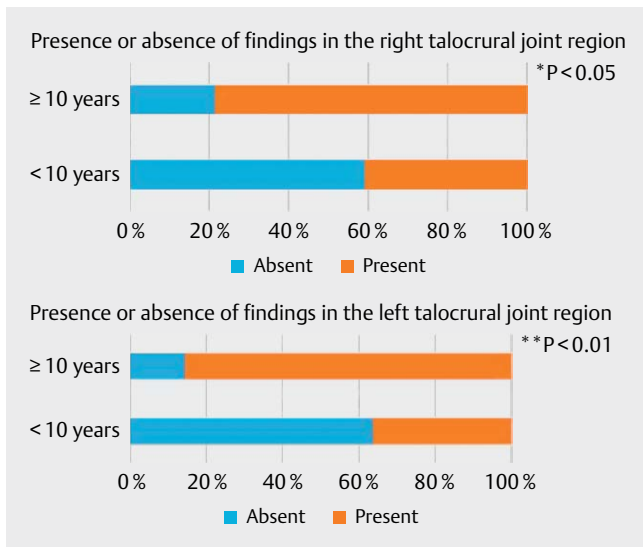
The number of past sprains determined from the questionnaire tended to be higher on the left side in both senior high school and college students, but frequent sprain also occurred on the right side. There was no significant association between the number of past sprains and current pain. In contrast, old ATFL injury was more common on the left side on ultrasonography in both groups. The dominant hand or leg was not investigated, but the frequency is not necessarily higher on the dominant side [17]. However, since many players are right-handed, they may have frequently stepped on the left leg. In the college students, the incidence of left foot injury was 100%, which is serious. Inversion sprain of the ankle joint is the most frequent basketball injury [7, 8, 18–21]. ATFL injury is caused by inversion of the ankle joint [3, 23, 24] and injury of the lateral ligament of the ankle joint caused by an inversion sprain has characteristics in each age group [16, 22]. In school-age players with incomplete bone maturation, inversion sprain of the ankle joint is likely to cause sprain fracture at the distal end of the fibula, to which the anterior talofibular ligament is attached [23]. The injury pattern becomes ATFL injury from junior high school age, and many cases occur at the fibular insertion site. In the current study, the rupture was frequently noted at the fibular insertion site and the central region of the ligament in both groups, suggesting the persistence of old injuries after school age. Many causes of ankle joint sprain have been suggested, including inversion and eversion muscle strengths of the ankle joint, balance ability, and problems with posture, but the mechanism is uncertain [24–28].

The mechanism of osteophyte formation is thought to involve a hyperplastic change to repair osteochondral injury caused by col-

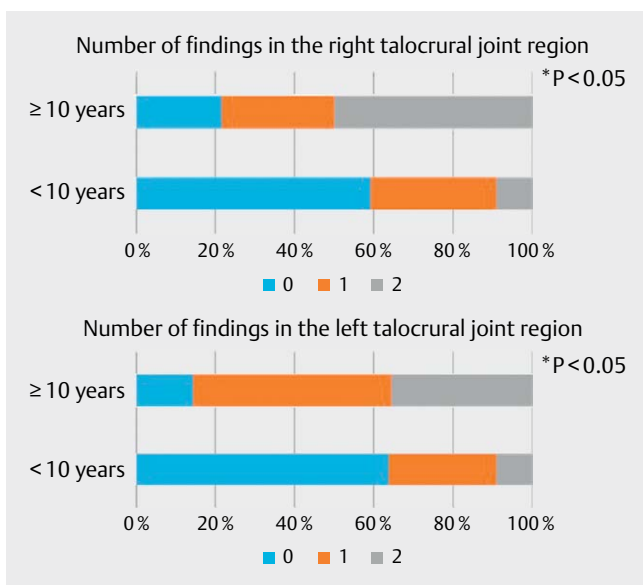
lisions between the lower end of the tibia and neck of the talus due to frequent repeated ankle joint sprains or distraction of the joint capsule and stress concentration on part of the joint [10, 11]. Instability on the lateral side of the ankle joint after sprain also plays a role [12]. Based on ultrasonographic checkups of the ankle joint in senior high school student basketball players, we previously reported that the presence of old ATFL injury was not necessarily involved in osteophyte formation, and a causal relationship with a high frequency of past sprain was observed. Based on arthroscopy in patients with lateral ligament injury of the ankle joint, cartilage injury was found in about 89% of acute cases and at a higher rate of 95% in chronic cases. In addition, injuries of grades 3 and 4 were observed in many chronic cases, showing aggravation in chronic cases [29]. In the current study, measured items were compared between senior high school and college students on each side. The number of osteochondral findings in the talocrural joint region on the right side was significantly higher in the college students ($P < 0.05$) and that on the left side was also higher in the college students, although the difference was not significant ($P = 0.068$). The mean ages of the groups were 16 and 20 years old, respectively, and both engaged in a substantial amount of practice. The increase in the number of osteochondral findings suggests the presence of burdens on the talocrural joint. Therefore, the prevention of repeated sprain may be more important, rather than the presence or site of injury.

The subjects were also grouped based on years of experience. The incidence of disorder of the talocrural joint region was significantly higher in the group with ≥ 10 years of experience, and the number of impaired sites was also significantly higher in this group. Ultrasonography showed that disorder of the talocrural joint region progresses with an increase in years of experience in student players who take no specific preventive measures. If motor organ checkup is actively performed, years of experience may be a risk factor.

In general, to evaluate acute or chronic lateral ligament injury and osteochondral findings of chronic ankle injury, CT scan (computed arthrothomography) is very useful. MRI (magnetic resonance imaging) is also a very helpful, accurate and noninvasive means of determining the severity of ligament injuries including bone and



► **Fig. 3** Presence or absence of findings in the right and left talocrural joint region. ** $P < 0.01$ * $P > 0.05$, Mann-Whitney U-test was performed. The frequency of osteochondral findings in the talocrural joint region was significantly higher in the group with ≥ 10 years of experience on the bilateral.



► **Fig. 4** Number of findings in the right talocrural joint region in the right and left talocrural joint region. * $P < 0.05$, Mann-Whitney U-test was performed. The number of findings was also significantly higher in the group with ≥ 10 years of experience.

soft tissues injury [30–33]. CT scan and MRI are usually performed at a hospital. However, ultrasonography is not limited with respect to the place of use and is a noninvasive and low-cost examination method. Recent ultrasonography machines are more easily carried around, so we can bring one to the sports field. Ultrasonography is a convenient and useful tool in the world of sports. It can be used for real-time examination of players in any kind of environment. With the scanning result, we can efficiently and quickly assess players for injury. However, the technique requires significant training.

In particular, ankle sprain is a very common injury that ultrasonography can examine to detect lateral injury with low cost and non-invasively. Ultrasonography performed by a highly skilled sonographer is the best method for ankle injury evaluation [34–38].

There are several limitations to this study. First, the number of subjects was small despite the study being a cross-sectional survey. However, the novelty of the use of noninvasive ultrasound by skilled operators at actual playing sites is of clinical significance. Players without a marked difference in competition level were selected as subjects. It is desirable to perform a longitudinal study in the same subjects, in addition to a large-scale nationwide survey. In this study, there were no other anatomical variants and pathological findings. However, it might be easy to encounter anatomical variants and injuries of the peroneal tendon complex on the lateral side of the ankle [39]. Finally, ultrasound elastography might be helpful and have great potential for clarifying the risk factors for injuries regarding ankle problems.

Conclusion

Student basketball players with a history of highly frequent ankle sprains and with 10 or more than 10 years of basketball experience should be prevented from getting worse.

An active motor organ checkup combined with an ultrasonographic examination may be important in future clinical developments with respect to injuries in basketball players.

Acknowledgements

We are grateful to Bright Body Ltd. and the Medical Committees of the Osaka Basketball Associations for their assistance with this study.

Conflict of interest

There is no conflict of interest to disclose with regard to this study.

References

- [1] Garrick JG. The frequency of injury, mechanism of injury, and epidemiology of ankle sprains. *Am J Sports Med* 1977; 5: 241–242
- [2] Lewis JE. Ankle arthroscopy and sports-related injuries, *Orthopaedic Knowledge Update: Foot and Ankle 2*. American Academy of Orthopaedic Surgeons 1998; 39–54
- [3] Otter SJ. The conservative management of lateral ankle sprains in the athlete. *Foot* 1999; 9: 12–17
- [4] Brand RL, Black HM, Cox JS. The natural history of inadequately treated ankle sprains. *Am J Sports Med* 1977; 5: 248–249
- [5] Hintermann B, Boss A, Schäfer D. Arthroscopic findings in patients with chronic ankle instability. *Am J Sports Med* 2002; 30: 402–409
- [6] Lee J, Hamilton G, Ford L. Associated intra-articular ankle pathologies in patients with chronic lateral ankle instability: Arthroscopic findings at the time of lateral ankle reconstruction. *Foot Ankle Spec* 2011; 4: 284–289
- [7] McKay GD, Goldie PA, Payne WR, Oakes BW. Ankle injuries in basketball: Injury rate and risk factors. *Br J Sports Med* 2001; 35: 103–108

- [8] Hubbard-Turner T, Turner MJ. Physical Activity Levels in College Students With Chronic Ankle Instability. *J Athl Train* 2015; 50: 742–747
- [9] Choi GW, Choi WJ, Youn HK et al. Osteochondral lesions of the talus are there any differences between osteochondral and chondral types? *The American Journal of Sports Medicine* 2014; 14: 1–7
- [10] Mioka T, Horibe S. Trauma and disorder of the ankle joint frequently noted in basketball players. *Journal of Clinical Sports Medicine* 2001; 18: 991–996
- [11] McMurray TR. Footballer's ankle. *J Bone Joint Surg.* 1950; 32-B: 68
- [12] Okabe T. Association between osteophyte in the ankle joint and instability of the lateral ankle joint and osteoarthritis of the ankle joint in soccer players. *Journal of the Chugoku-Shikoku Orthopaedic Association* 1991; 3: 99–100
- [13] Faude O, Junge A, Kindermann W et al. Risk factors for injuries in elite female soccer players. *Br J Sports Med* 2006; 40: 785–790
- [14] Fukushima Y. The relationship between cartilage lesions that were detected by ultrasound and the frequency of ankle sprains among high school basketball players. *J JaSOU* 2015; 27: 104–109
- [15] Cheng Y, Cai Y, Wang Y. Value of ultrasonography for detecting chronic injury of the lateral ligaments of the ankle joint compared with ultrasonography findings. *Br J Radiol* 2014; 87: 20130406
- [16] Takahashi S. Usefulness of ultrasound for diagnosis of the foot and ankle joint sprain. *Journal of Joint Surgery* 2014; 33: 52–56
- [17] Boyce SH, Quigley MA, Campbell S. Management of ankle sprains: A randomized controlled trial of the treatment of inversion injuries using an elastic support bandage or an Aircast ankle brace. *Br J Sports Med* 2005; 39: 91–96
- [18] Dick R, Hertel J, Agel J et al. Descriptive epidemiology of collegiate men's basketball injuries. National collegiate athletic association injury surveillance system, 1988–1989 through 2003–2004. *J Athl Train* 2007; 42: 194–201
- [19] Starkey C. Injuries and illness in the National Basketball Association: A 10-year perspective. *J Athl Train* 2000; 35: 161–167
- [20] Deitch JR, Starkey C, Walters SL et al. Injury risk in professional basketball players: a comparison of women's National Basketball Association and National Basketball Association athletes. *Am J Sports Med* 2006; 34: 1007–1083
- [21] Zelisko JA, Noble HB, Porter M. A comparison of men's and women's professional basketball injuries. *Am J Sports Med* 1982; 10: 297–299
- [22] Takahashi S. New development for ankle joint ligament injury: Progression of diagnostic technique and its application for treatment. Team doctor & trainer meeting. *The Journal of Clinical Sports Medicine* 2012; 29: 1155–1158
- [23] Minagawa Y. Advanced course of orthopedics: Ultrasonographic diagnosis and treatment: Where, what degree, and how. Ankle joint sprain. *Clinical Orthopaedic Surgery* 2014; 49: 79–87
- [24] Dabadghav R. Correlation of ankle eversion to inversion strength ratio and static balance in dominant and non-dominant limbs of basketball players. *J Sports Med Phys Fitness* 2016; 56: 422–427
- [25] McGuine TA, Greene JJ, Best T, Levenson G. Balance as a predictor of ankle injuries in high school basketball players. *Clin J Sports Med* 2000; 10: 239–244
- [26] Wang HK, Chen CH, Shiang TY, Jan MH, Lin KH. Risk-factor analysis of high school basketball-player ankle injuries: a prospective controlled cohort study evaluating postural sway, ankle strength, and flexibility. *Arch Phys Med Rehabil* 2006; 87: 821–825
- [27] Wilkerson GB, Pinerola JJ, Caturano RW. Invertor vs. evertor peak torque and power deficiencies associated with lateral ankle ligament injury. *J Orthop Sports Phys Ther* 1997; 26: 78–86
- [28] Baumhauer JF, Alosa DM, Renström AF, Trevino S, Beynonn B. A prospective study of ankle injury risk factors. *Am J Sports Med* 1995; 23: 564–570
- [29] Taga I, Shino K, Inoue M, Nakata K, Maeda A. Articular cartilage Lesions in ankles with Lateral ligament injury. *Am J Sports Med.* 1993; 21: 120–127
- [30] Schneck CD, Mesgarzadeh M, Bonakdarpour A. MR imaging of the most commonly injured ankle ligaments, part II: Ligaments injuries. *Radiology* 1992; 184: 507–512
- [31] Frey C, Bell J, Teresi L, Kerr R, Feder K. A comparison of MRI and clinical examination of acute lateral ankle sprains. *Foot Ankle Int* 1996; 17: 533–537
- [32] Kreitner KF, Ferber A, Grebe P, Runkel M, Berger S, Thelen M. Injuries of the lateral collateral ligaments of the ankle: Assessment with MR imaging. *Eur Radiol* 1999; 9: 519–524
- [33] Verhagen RA, Maas M, Dijkgraaf MG, Tol JL, Krips R, van Dijk CN. Prospective study on diagnostic strategies in osteochondral lesions of the talus: is MRI superior to helical CT? *J Bone Joint Surg Br* 2005; 87: 41–46
- [34] Naredo E, Moller I, Moragues C et al. Inter-observer reliability in musculoskeletal ultrasonography: Results from a “Teach-the-Teachers” rheumatologist course. *Ann Rheum Dis* 2006; 65: 14–19
- [35] Geusens E, Pans S, Van Breuseghem I, Brys P. Ultrasound in acute trauma of the ankle and hindfoot. *Emerg Radiol* 2002; 9: 283–288
- [36] Guillodo Y, Varache S, Saraux A. Value of ultrasonography for detecting ligament damage in athletes with chronic ankle instability compared to computed arthrotomography. *Foot and Ankle specialist* 2010; 3: 331–334
- [37] Badekas T, Takvorian M, Souras N. Treatment principles for osteochondral lesions in foot and ankle. *International Orthopaedics* 2013; 37: 1697–1706
- [38] Sonography of ankle ligaments. Philippe Peetrons, Viviane Creteur, Christian Bacq. *J Clin Ultrasound* 2004; 32: 491–499
- [39] US in peroneal tendon tear. Lucio Molini, Stefano Bianchi. *J Ultrasound* 2014; 17: 125–134