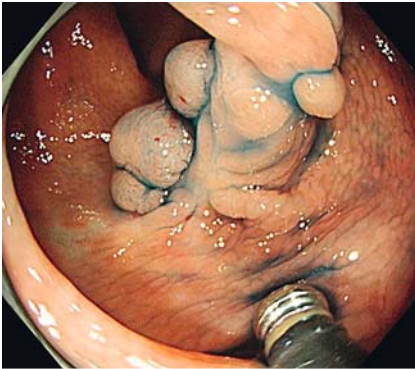
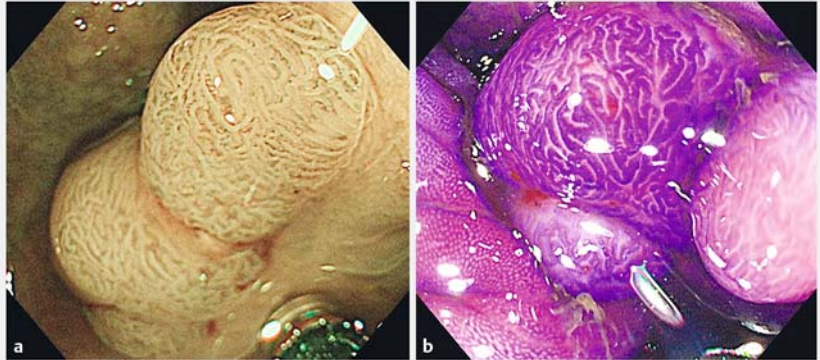


## Underwater endoscopic mucosal resection for complete R0 removal of a residual adenoma at a perforated scar in a patient with colostomy



► **Fig. 1** In an 82-year-old man, chromoendoscopy with indigo carmine showed a 12-mm polyp surrounded by multiple widespread scars on the dorsal side 20 cm proximal to his permanent sigmoidostomy.



► **Fig. 2 a** Magnified endoscopy with narrow band imaging showed regular vessels and surface structures and a corresponding capillary pattern type II according to Sano's classification. **b** Magnified chromoendoscopy following crystal violet staining showed branch-like pits. This was classified as a pit pattern type IV according to Kudo's classification.

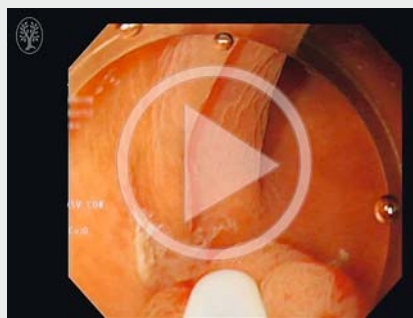
Endoscopic mucosal resection (EMR) of residual polyps is technically challenging, as submucosal fibrosis from the initial resection makes it difficult to lift the lesion during submucosal injection and to snare the entire tumor [1]. Endoscopic submucosal dissection (ESD) enables complete removal of such residual polyps [2] but presents some technical difficulties and is time-consuming [3]. An 82-year-old man with permanent sigmoidostomy was referred to our unit because of a residual polyp in the descending colon, seen at the 18-month surveillance test after EMR at another hospital. Perforation had occurred during EMR, and clip closure had been performed. Colonoscopy through the sigmoidostomy showed a 12-mm polyp surrounded by multiple widespread scars on the dorsal side 20 cm proximal to the colostomy (► **Fig. 1**). The lesion was diagnosed as an adenoma (► **Fig. 2 a, b**). Complete removal by ESD was considered difficult [4]. First, there was the possibility of severe and widespread submucosal fibrosis because of multiple deep ulcer scars. Second, traction would have to be limited, since it is difficult to change the po-

sition of a patient with a colostomy. Third, the polyp was difficult to visualize because of a collapsed colon wall caused by gas leakage through the colostomy. We therefore performed underwater EMR (► **Fig. 3** and ► **Fig. 4**, ► **Video 1**) [5]. En bloc resection without complications was achieved within 15 minutes. Histopathological examination showed

an adenoma with negative resection margins (► **Fig. 5**).

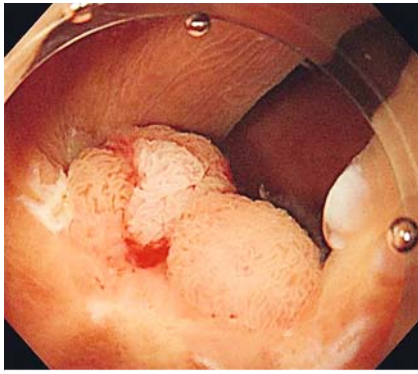
There were three advantages to using water immersion in the underwater EMR. First, water immersion allowed us to “float” the lesion away from the muscularis layer, allowing wide-field resection of the entire polyp and scars (► **Fig. 4**). Second, underwater EMR eliminated the

### ► Video 1

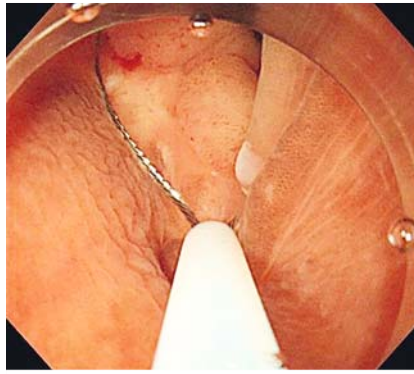


► **Video 1:** A residual polyp was removed completely by underwater endoscopic mucosal resection. Water immersion improved polyp visualization significantly, and allowed the entire scarring lesion to be captured using a “floating” effect rather than gravity.

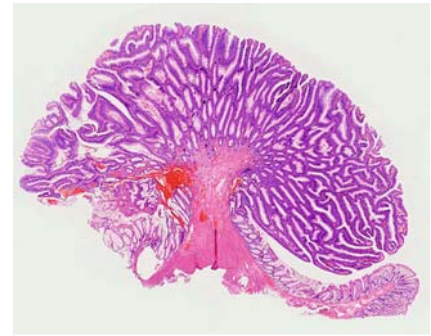




► **Fig. 3** After the area around the polyp had been marked with dots, saline was infused to provide stable and clear visualization.



► **Fig. 4** The entire polyp could be captured using a wide-field snare because of the “floating” effect created by water immersion.



► **Fig. 5** The histopathologic image showed an adenoma with negative resection margins.

need for the assistance of gravity. Finally, underwater EMR significantly improved endoscopic visualization (► **Fig. 3**). In summary, underwater EMR can be considered as a safe, time-saving, and effective option when the nature of a lesion makes it difficult to perform ESD.

Endoscopy\_UCTN\_Code\_TTT\_1AQ\_2AD

### Competing interests

None

### The Authors

**Kazuya Hosotani, Kenichiro Imai, Kinichi Hotta, Sayo Ito, Hiroyuki Ono**  
Division of Endoscopy, Shizuoka Cancer Center, Shizuoka, Japan

### Corresponding author

**Kenichiro Imai, MD**  
Division of Endoscopy, Shizuoka Cancer Center, 1007, Shimonagakubo, Nagaizumi-cho, Suntogun, Shizuoka, 411-8777, Japan  
Fax: +81-55-989-5783  
k.imai1977@gmail.com

### References

- [1] Uno Y, Munakata A. The non-lifting sign of invasive colon cancer. *Gastrointest Endosc* 1994; 40: 485–489
- [2] Sakamoto T, Saito Y, Matsuda T et al. Treatment strategy for recurrent or residual colorectal tumors after endoscopic resection. *Surg Endosc* 2011; 25: 255–260
- [3] Kim ES, Cho KB, Park KS et al. Factors predictive of perforation during endoscopic

submucosal dissection for the treatment of colorectal tumors. *Endoscopy* 2011; 43: 573–578

- [4] Imai K, Hotta K, Yamaguchi Y et al. Pre-operative indicators of failure of en bloc resection or perforation in colorectal endoscopic submucosal dissection: implications for lesion stratification by technical difficulties during stepwise training. *Gastrointest Endosc* 2016; 83: 954–962
- [5] Binmoeller KF, Weilert F, Shah J et al. “Underwater” EMR without submucosal injection for large sessile colorectal polyps (with video). *Gastrointest Endosc* 2012; 75: 1086–1091

### Bibliography

DOI <http://dx.doi.org/10.1055/s-0043-104520>  
*Endoscopy* 2017; 49: E121–E122  
© Georg Thieme Verlag KG  
Stuttgart · New York  
ISSN 0013-726X