



Imaging Recommendations for Diagnosis, Staging, and Management of Esophageal Cancer

Nivedita Chakrabarty¹ Abhishek Mahajan² Prachi Patil³ Manoranjan Chowhan⁴
Naveen Munmmudi⁵ Devayani Niyogi⁶ Deepak Dabkara⁷ Suryaveer Singh¹ Ajaykumar Singh⁸
Sanjana Devarmani¹ Varun Singh Dhull⁴ Kumar Prabhash⁸

¹ Department of Radiodiagnosis, Tata Memorial Centre, Homi Bhabha National Institute (HBNI), Tata Memorial Hospital, Mumbai, Maharashtra, India

² Department of Radiodiagnosis, The Clatterbridge Cancer Centre NHS Foundation Trust, Liverpool, United Kingdom

³ Department of Digestive Diseases and Clinical Nutrition, Tata Memorial Centre, Homi Bhabha National Institute (HBNI), Tata Memorial Hospital, Mumbai, Maharashtra, India

⁴ Department of Nuclear Medicine and PET/CT, Aditya Birla Memorial Hospital, Pune, Maharashtra, India

⁵ Department of Radiation Oncology, Tata Memorial Centre, Homi Bhabha National Institute (HBNI), Tata Memorial Hospital, Mumbai, Maharashtra, India

⁶ Department of Surgical Oncology, Tata Memorial Centre, Homi Bhabha National Institute (HBNI), Tata Memorial Hospital, Mumbai, Maharashtra, India

⁷ Department of Oncology, CHL Hospitals, Indore, Madhya Pradesh, India

⁸ Department of Medical Oncology, Tata Memorial Centre, Homi Bhabha National Institute (HBNI), Tata Memorial Hospital, Mumbai, Maharashtra, India

Address for correspondence Abhishek Mahajan, MD, Fellowship in Cancer Imaging, MRes (KCL, London), FRCR (UK), Department of Radiodiagnosis, The Clatterbridge Cancer Centre NHS Foundation Trust, Pembroke Place Liverpool, Liverpool L7 8YA, United Kingdom (e-mail: drabhishek.mahajan@yahoo.in).

Ind J Med Paediatr Oncol 2023;44:229–240.

Abstract

Early staging and treatment initiation affect prognosis of patients with esophageal and esophagogastric junction cancer; hence, it is imperative to have knowledge of proper choice of imaging modality for staging of these patients, to effectively convey relevant imaging findings to the treating physician/surgeon. It is also essential to be aware of pertinent imaging findings that need to be conveyed to the treating physician/surgeon at staging, and after treatment, including post-therapy complications (if any), so as to provide timely management to such patients. In this article, we have provided imaging guidelines for diagnosis, staging, post-therapy response evaluation, follow-up, and assessment of post-therapy complications of esophageal and esophagogastric junction cancer in a systematic manner. Besides, risk factors and clinical workup have also been elucidated. We have also attached comprehensive staging and post-therapy contrast-enhanced computed tomography and fluorodeoxyglucose-positron emission tomography/computed tomography-based synoptic reporting formats “ECI-RADS” and “pECI-RADS,” respectively, for esophageal and esophagogastric junction cancer in the supplement, for effective communication of imaging findings between a radiologist and the treating physician/surgeon.

Keywords

- ▶ esophageal cancer
- ▶ imaging guidelines
- ▶ staging
- ▶ post-therapy
- ▶ synoptic reporting formats

DOI <https://doi.org/10.1055/s-0042-1760324>.
ISSN 0971-5851.

© 2023. The Author(s).

This is an open access article published by Thieme under the terms of the Creative Commons Attribution License, permitting unrestricted use, distribution, and reproduction so long as the original work is properly cited. (<https://creativecommons.org/licenses/by/4.0/>)
Thieme Medical and Scientific Publishers Pvt. Ltd., A-12, 2nd Floor, Sector 2, Noida-201301 UP, India

Introduction

Esophageal cancer (EC) is the seventh most common cancer in the world (GLOBOCAN 2020).^{1,2} As per American Joint Committee on Cancer (AJCC), ECs have been divided into those located in the cervical, upper thoracic, middle thoracic, and lower thoracic esophagus (including the esophagogastric junction and up to 2 cm of gastric cardia).^{3,4} Squamous cell carcinoma (SCC) is the predominant EC subtype usually seen in the middle third and lower third of esophagus, while most of the adenocarcinomas (ACs) occur in the distal esophagus.^{3,5} Two to ten percent of all the cancers are located in the cervical esophagus and are of SCC subtype.^{6,7}

Risk Factors and Etiopathogenesis

Major risk factors for SCC include tobacco chewing and smoking and alcohol consumption. Achalasia and consumption of hot beverages are other predisposing factors. Main risk factors for AC include gastroesophageal reflux disease, Barrett's esophagus, obesity, and tobacco. Poor nutrition, mineral and vitamin deficiencies due to low intake of fruits and vegetables, radiotherapy for thoracic malignancies, and caustic ingestion predispose to both SCC and AC.⁸⁻¹⁰ Various somatic mutations implicated in the pathogenesis of EC have been identified, and most notable of them being mutations of TP53, a major tumor-suppressor gene, and PIK3CA.¹⁰

Epidemiology and Clinical Presentation

EC peaks in the seventh and eighth decades with 70% cases occurring in men.^{1,11} In the West, the incidence of SCC has declined, with AC now being the dominant subtype.¹² As per GLOBOCAN 2020 data, EC is the fifth most common cancer in terms of incidence and mortality in India, and ranks seventh and sixth, respectively, in terms of incidence and mortality worldwide.^{13,14} Patients are asymptomatic in early stages, in advanced stage, present with progressive dysphagia (solids then liquids), weight loss, hematemesis, melena, and hoarseness from recurrent laryngeal nerve involvement.¹⁵

Imaging Referral Guidelines

National Comprehensive Cancer Network (NCCN), European Society of Medical Oncology, AJCC, National Cancer Grid, and Indian College of Radiology and Imaging (ICRI) recommend endoscopic ultrasound (EUS) and contrast-enhanced computed tomography (CECT) with oral contrast for locoregional staging and fluorodeoxyglucose-positron emission tomography/computed tomography (FDG-PET/CT) for distant metastatic workup.^{4,16-19} ICRI specifically recommends the use of EUS only in early stage primary tumor evaluation of the middle third EC.¹⁹ In addition, American College of Radiology recommends the use of single water-soluble contrast esophagogram on fluoroscopy in the immediate postoperative period to detect fistula or leaks, and suggests CT scan for negative esophagogram when clinical suspicion is high.²⁰ Imaging-based clinical (cTNM) staging proposed by 8th edition AJCC is followed for esophagus and gastroesophageal junction (GEJ) epithelial cancers.⁴ ▶**Fig. 1** shows the NCCN imaging algorithm and ▶**Table 1** shows the 8th edition AJCC staging for EC.^{4,16}

EUS can differentiate the various layers of esophageal wall and has a sensitivity of 92 and 82%, respectively, for cT4 tumors and cT1 tumors.^{16,21} CECT best detects invasion of adjacent structures (pleura, pericardium, azygous vein, diaphragm, peritoneum, aorta, trachea, and vertebra).^{2,21,22} CT has a low accuracy for N staging showing a sensitivity of 30 to 60%, specificity of 60 to 80%, and accuracy 27 to 86% for lymph node more than 1cm.²¹ Whereas the sensitivity of PET/CT for detection of locoregional nodal involvement is also low (51%).¹⁶ EUS has a better sensitivity of 85% than either CT or PET/CT for the detection of nodal involvement.¹⁶ Metastasis that is occult on CT can be detected on FDG-PET/CT.¹⁶ PET/CT has a sensitivity and specificity of 69 and 93%, respectively, for M stage.⁴

Clinical/Diagnostic Workup (Excluding Imaging)

All patients should have a thorough history and clinical examination with particular reference to weight loss. Grade III/IV dysphagia points toward bulky primary and probably

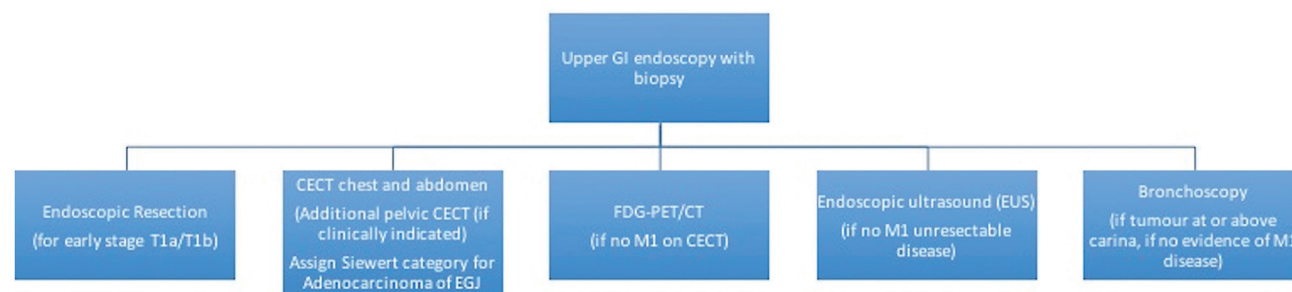


Fig. 1 Imaging guidelines for esophageal and esophagogastric junction tumors (adapted from NCCN guidelines version 2.2022).¹⁶ CECT, contrast-enhanced computed tomography; FDG-PET/CT, fluorodeoxyglucose-positron emission tomography/computed tomography; GI, gastrointestinal.

Table 1 The American Joint Committee on Cancer tumor-node-metastasis staging categories of esophagus and esophagogastric junction (8th edition)

Category	Criteria
T category	
TX	Tumor cannot be assessed
T0	No evidence of primary tumor
Tis	High-grade dysplasia, defined as malignant cells confined by the basement membrane
T1	Tumor invades the lamina propria, muscularis mucosae, or submucosa
T1a	Tumor invades the lamina propria or muscularis mucosae
T1b	Tumor invades the submucosa
T2	Tumor invades the muscularis propria
T3	Tumor invades adventitia
T4	Tumor invades adjacent structures
T4a	Tumor invades the pleura, pericardium, azygos vein, diaphragm, or peritoneum
T4b	Tumor invades other adjacent structures, such as aorta, vertebral body, or trachea
N category	
NX	Regional lymph nodes cannot be assessed
N0	No regional lymph node metastasis
N1	Metastasis in 1–2 regional lymph nodes
N2	Metastasis in 3–6 regional lymph nodes
N3	Metastasis in 7 or more regional lymph nodes
M category	
M0	No distant metastasis
M1	Distant metastasis

T3/T4 stage. Upper gastrointestinal (GI) endoscopy with multiple biopsies is required to have sufficient tissue for histopathological examination and biomarker testing.²³ Differentiation between squamous and AC histology has prognostic and therapeutic implication.²⁴ In case of esophageal SCC, ear nose throat (ENT) examination to evaluate oral cavity, oropharynx, and hypopharynx should be done by an ENT specialist. In case of tumors located at or above tracheal bifurcation, a tracheobronchoscopy should be done to rule out tracheal invasion and a synchronous cancer in aerodigestive tract.¹⁷

In locally advanced AC of GEJ, approximately 15% patients have peritoneal metastasis. Laparoscopy is advised in locally advanced GEJ AC to prevent futile surgeries.²⁵ For patients with metastatic disease, human epidermal growth factor receptor 2 testing by immunohistochemistry or fluorescence in situ hybridization for AC, mismatch repair deficiency/microsatellite instability, program death-ligand 1 (PD-L1) expression, and neurotrophic-tropomyosin receptor kinase fusion are advised to decide for targeted therapy/immunotherapy.²⁶

Imaging Guidelines

- a) Screening:** Routine screening for EC is not recommended.
b) Diagnosis: Upper GI endoscopy-guided biopsy is used for the diagnosis of primary tumor.²³ There are two types

of echoendoscopes available: radial and linear array. EUS using linear array echoendoscopes have a limited field but have the important ability to visualize a needle in real time and hence are used for tissue sampling. Endoscopy also helps in guiding nasogastric tube insertion for feeding when needed. In patients having clinically palpable and significant appearing supraclavicular node or liver metastasis, tissue diagnosis can be obtained from node or liver metastasis, when planned for palliative therapy.

c) Staging

Role of EUS

On EUS, five layers of the esophageal wall described are layer 1 (hyperechoic) superficial mucosa, layer 2 (hypoechoic) deep mucosa, layer 3 (hyperechoic) submucosa, layer 4 (hypoechoic) muscularis propria, and layer 5 (hyperechoic) adventitia. Tumors appear as hypoechoic lesions involving the wall layers, and malignant lymph nodes are typically seen in the vicinity of the tumor, appearing hypoechoic and round with smooth borders, and may be more than 10 mm in size.²⁷ The standard 7.5 to 12 MHz frequency transducers do not have adequate resolution to accurately “T” stage very early stage disease with mucosal involvement or superficial submucosal involvement, and a 20 MHz radial mini-probe may be needed for scanning in such cases. The accuracy of EUS

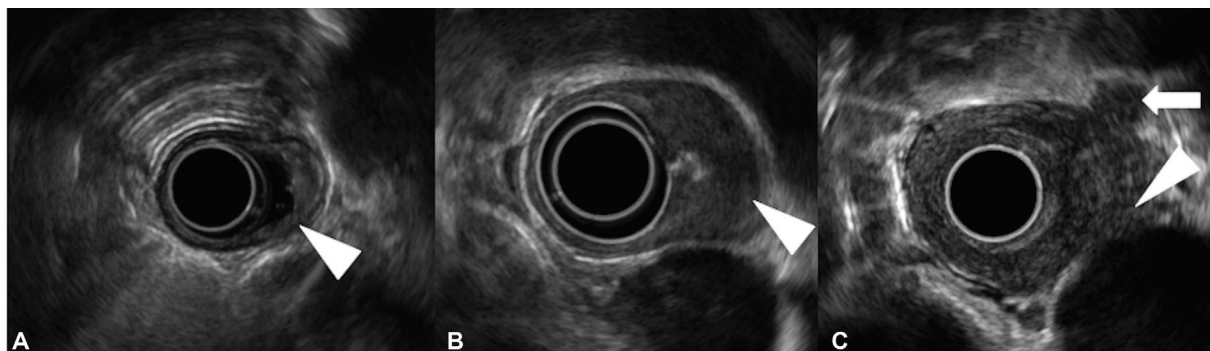


Fig. 2 Staging of esophageal cancer on endoscopic ultrasonography. (A) T1 tumor invading the submucosa (arrowhead). (B) T2 tumor invading the muscularis propria (arrowhead). (C) T4 tumor involving the aorta (arrowhead). A malignant regional lymph node is also seen (arrow).

increases with increasing T stage. EUS can be performed in patients with early-stage EC prior to endoscopic resection (ER) or in patients planned for upfront surgery, mainly to rule out lymph-node metastases in selected high-risk cases. Although EUS is the only modality for distinguishing different layers of esophageal wall, ER is more accurate than EUS for the staging of T1a/T1b EC and may also be therapeutic in some cases.¹⁶ When high-definition white-light or image-enhanced endoscopy is suggestive of a small nodular lesion with high grade dysplasia or early-stage EC, a staging ER is encouraged.^{16,28} An EUS-guided fine-needle aspiration can be performed for suspicious lymph nodes if they can be sampled without traversing the tumor or major blood vessels and if the result will change management.¹⁶ Most patients with stenotic tumors are likely to have locally advanced disease where an EUS may be unnecessary.²⁹ If at all an EUS is indicated in stenotic tumors, a smaller caliber wire-guided probe or mini-probe can be used; however, availability and cost may be an issue. **►Fig. 2(A–C)** shows EC staging on EUS with malignant regional node.

Role of CT

CECT thorax and abdomen with oral contrast is recommended for EC staging. CT of the pelvic region should be included for esophagogastric junction tumors or if clinically indicated. Upper third EC including cervical EC requires additional evaluation with CECT neck. CT thorax protocol for EC is shown in **►Table 2**.¹⁹

On CECT, differentiation of T1 and T2 is not possible.^{21,22} T3 stage on CT presents as mural thickening (> 3mm) and periesophageal fat infiltration without any loss of fat plane/invasion of adjacent structures.² CT

most accurately provides the craniocaudal length of the tumor (along with the corresponding vertebral level) that is essential for deciding upon the surgical resection margins.^{2,3} CT plays a significant role in T4 staging of tumor. Involvement of pleura, pericardium, azygous vein, diaphragm, or peritoneum (for esophagogastric junction EC) is considered as T4a stage, whereas, aorta, vertebral body, or tracheal involvement upgrades the lesion to T4b stage.^{2,4} Specific signs of tracheobronchial involvement by EC on CT are fistula formation with the airway, intraluminal extension of tumor within the airway, and tracheobronchial mural thickening.^{3,22} Focal loss of fat plane of the EC with the airway with preserved fat planes proximal and distal to it also likely suggests tracheobronchial involvement.²² More than 90-degree contact of EC with aorta, loss of triangular fat between esophagus, aorta, and spine, suggests aortic involvement on CECT.^{2,3,22} Pericardial involvement may be suggested by pericardial thickening/effusion.^{3,22} CECT helps in assigning Siewert category to esophagogastric junction AC tumors that have management and prognostic implications.¹⁶ Besides, CECT is important for the detection of metastasis to liver and lungs.²² **►Fig. 3 (A–E)** shows EC staging on CECT.

Role of FDG-PET/CT

Following intravenous injection of 18F-FDG-PET-CT images are acquired from skull base to mid-thigh. Both oral and intravenous contrast is used for the acquisition of CT images. The predominant role of FDG-PET/CT is to detect distant metastases including metastasis to bones and distant nodal metastasis when no metastasis is detected on CECT scan.¹⁶ PET-CT is the modality of choice

Table 2 CT thorax protocol for EC

Modality	Typical protocol
CT thorax	-Noncontrast and CECT are performed -On table positive oral contrast (500 mL water + 30 mL nonionic contrast), or plain water, to distend the esophagus. -For CECT, 100 cc of intravenous nonionic contrast (300 mg iodine per mL) at 2.5–3 mL/sec

Abbreviations: CECT, contrast-enhanced computed tomography; EC, esophageal cancer.

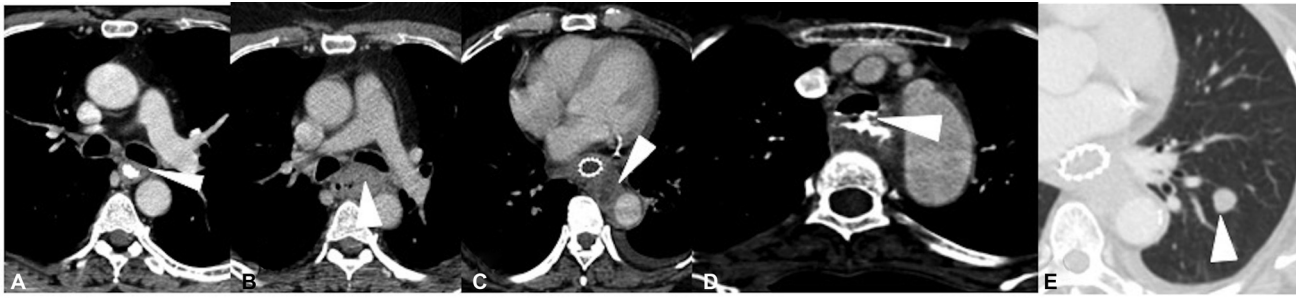

Fig. 3 Esophageal carcinoma staging on axial contrast-enhanced computed tomography. (A) Mild asymmetric mid-esophageal wall thickening (arrowhead), with no peri-adventitial infiltration and maintained fat planes with the adjacent structures (T2). (B) Mid-esophageal growth with periadventitial fat infiltration (T3) without any tracheobronchial or aortic invasion. The mass is seen to indent upon posterior wall of left mainstem bronchus (arrowhead); however, invasion was ruled out by bronchoscopy. (C) More than 90-degree arc of contact between the esophageal mass and aorta with involvement of aortic wall (arrowhead), along with soft tissue extension into the triangular fat pad indicating aortic invasion (T4b). (D) Irregular circumferential thickening involving the upper thoracic esophagus with frank fistulous communication with the tracheal lumen (arrowhead), and passage of oral positive contrast into the trachea (T4b). (E) Well defined left lower lobe nodule (arrowhead) on lung window, in a case of esophageal cancer, suggestive of lung metastasis (M1).

to diagnose occult metastasis to various organs that thus help in avoiding futile surgeries.^{30–32} Besides, PET-CT is also useful to detect second primary tumor and studies have indicated that FDG-PET/CT is superior to conventional anatomical imaging to evaluate synchronous tumors (especially head and neck cancers and colon neoplasm) during primary staging of esophageal SCC.³³ PET/CT also plays an important role in radiation therapy treatment planning of EC.^{34,35} PET-CT-based intensity-modulated radiation therapy offers several advantages that includes (1) dose escalation to target (tumor), (2) minimizes dose delivery to normal tissue, (3) decrease acute toxicity, (4) lessens long-term toxicity by optimizing treatment delivery to target tissue, thereby achieving better therapy outcome. **Fig. 4 (A and B)** shows EC staging on FDG-PET/CT.

Role of Other Modalities

Magnetic resonance imaging (MRI) plays a pertinent role in detecting the status of spinal cord, when there is

intraspinal extension of the tumor with involvement of vertebrae. Also, when there is doubt on CT regarding pericardial and aortic wall involvement, MRI can come to the rescue. One of the studies has shown that PET-MR has comparable sensitivity with EUS in staging primary esophageal involvement, and offers higher diagnostic accuracy compared with EUS and PET/CT.³⁶ However, due to limited availability and cost factor, PET-MR is not routinely used.

Table 3 enlists the role of each modality in staging of EC.^{2–4,16,22,30–32}

d) Response Assessment

A retrospective multicenter study demonstrated that use of short axis diameter (instead of the usual longest diameter) in the Response Evaluation Criteria in Solid Tumors (RECIST) for EC after neoadjuvant chemotherapy correlates well with pathological response and is significantly associated with survival.³⁷ On comparison with

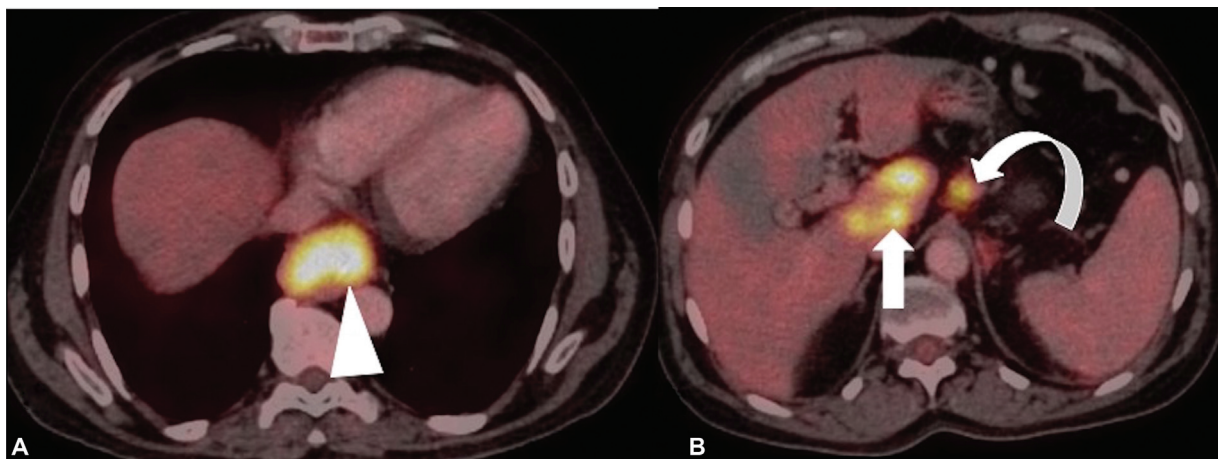


Fig. 4 (A and B) Staging of esophageal cancer on fluorodeoxyglucose-positron emission tomography/computed tomography (FDG-PET/CT) images reveals moderately FDG-avid primary esophageal mass lesion (arrowhead) with extensive FDG-avid metastatic abdominal nodes (curved arrow) and multifocal hypermetabolic hepatic (metastatic) lesions (arrow) implying M1 stage.

Table 3 Role of various modalities in staging of EC^{2-4,16,22,30-32}

Modality	Role in staging
Endoscopic resection	-Differentiating T1a from T1b -Biopsy from lesion
EUS	-T staging -N staging -EUS-guided FNA of regional nodes
CECT thorax and abdomen with oral contrast -Additional CECT neck if upper third (including cervical) EC -Additional CECT pelvis (if pelvic symptoms or EGJ tumors)	-T3 stage -T4a and T4b stages -Craniocaudal dimension of the tumor -Helps to assign Siewert category for adenocarcinoma of EGJ as follows: a. Siewert type I: tumor epicenter within 1 to 5 cm above EGJ b. Siewert type II: tumor epicenter within 1 cm above and 2 cm below EGJ c. Siewert type III: tumor epicenter between 2 and 5 cm below EGJ (included under gastric carcinoma) -Metastasis to liver and lungs
FDG-PET/CT	-Distant metastasis (including bone and distant nodal metastasis) when CECT is negative for metastasis -Occult metastasis to various organs -Synchronous tumors
MRI	-Status of spinal cord in case of intraspinal extension of the tumor with involvement of vertebrae. -Pericardial involvement when doubtful on CT -Aortic involvement when doubtful on CT

Abbreviations: CECT, contrast-enhanced computed tomography; EC, esophageal cancer; EGJ, esophagogastric junction; EUS, endoscopic ultrasound; FDG-PET/CT, fluorodeoxyglucose-positron emission tomography/computed tomography; MRI, magnetic resonance imaging.

pre-therapy CECT, new onset enhancing mural thickening anywhere in esophagus, significant increase in lymph nodal size as per RECIST or new onset metastatic lesions, all are suggestive of disease progression on CECT. FDG-PET/CT parameters like maximum standard uptake value (SUVmax) or metabolic tumor volume (MTV), aid in predicting prognosis and response assessment of patients treated after concurrent chemoradiation therapy.³⁸ Im-

mune-modified Response Evaluation Criteria in Solid Tumors (iRECIST) is used for assessing response in advanced EC receiving immunotherapy to take into account the phenomenon of pseudoprogression.^{39,40}

► **Fig. 5 (A and B)** shows pre-treatment and post-radiotherapy response on PET/CT. ► **Table 4** shows post-therapy response evaluation for EC.^{37,38}

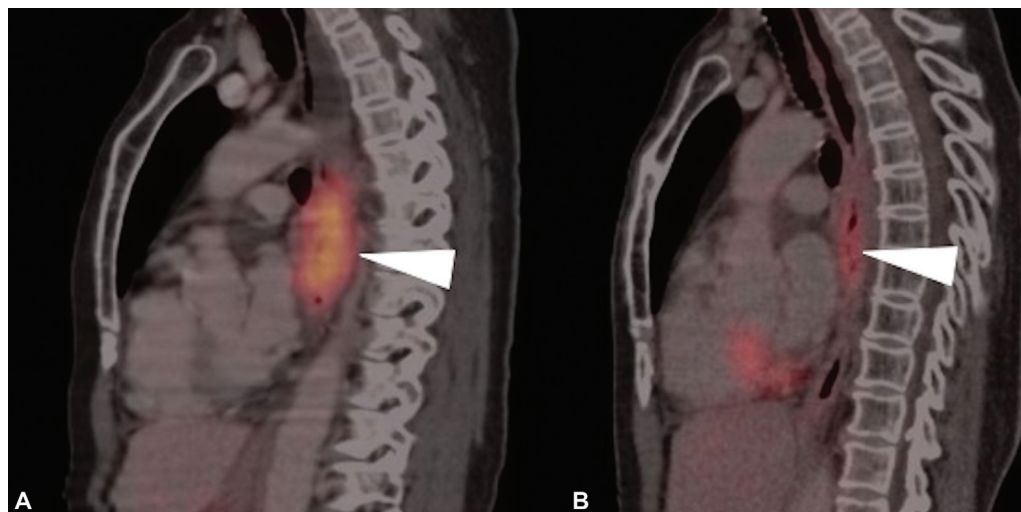


Fig. 5 (A and B) Fluorodeoxyglucose-positron emission tomography/computed tomography (FDG-PET/CT) images of a 50-year-old patient diagnosed as metastatic carcinoma esophagus treated with radiotherapy (RT). (A) Sagittal pretreatment PET/CT image depicts the metabolically active primary neoplastic mass lesion (arrowhead). (B) Sagittal post therapy PET/CT image after 3 months of RT reveals significant reduction in metabolic activity of primary lesion, suggestive of significant metabolic remission.

Table 4 Post-therapy response assessment for EC

Modality	Response assessment after therapy
CECT	≥ 30% decrease in esophageal mural thickening (short axis) or the lymph node (short axis), post-therapy suggests partial response ≥ 20% increase in esophageal mural thickening (short axis) or the lymph node (short axis), post-therapy suggests disease progression
FDG-PET/CT	SUVmax and MTV after concurrent chemoradiation therapy help in assessing response as well as prognosis. No definite cutoff value has been mentioned

Abbreviations: CECT, contrast-enhanced computed tomography; EC, esophageal cancer; FDG-PET/CT, fluorodeoxyglucose-positron emission tomography/computed tomography; MTV, metabolic tumor volume; SUVmax, maximum standard uptake value.

Table 5 Guidelines on follow-up of EC patients

Follow-up method	Frequency
CECT thorax and abdomen	<ul style="list-style-type: none"> • First 2 years: Every 6 months • 2–5 years: Annual • After 5 years: Only if indicated
Upper GI endoscopy	<ul style="list-style-type: none"> • At 3 months • 1 year • Then 3 yearly
Clinical (history and physical examination)	<ul style="list-style-type: none"> • First 2 years: 3 monthly • 2–5 years: 6 monthly • After 5 years: Annual

Abbreviations: CECT, contrast-enhanced computed tomography; EC, esophageal cancer; GI, gastrointestinal.

bimodality therapy (definitive chemoradiotherapy) and first 3 years after trimodality therapy (chemoradiotherapy and surgery).⁴¹ There are no well-established guidelines for follow-up; however, CT scan of chest and abdomen with contrast is recommended every 6 months for first 2 years at least.¹⁶ Along with this, 3 monthly follow-up with history and physical examination, upper GI tract endoscopy at 3 months, followed by at 1 year, and then every 3 yearly are recommended. From 2 to 5 years, follow-up can be 6 monthly (clinical) with annual imaging, and after 5 years annual clinical follow-up with imaging only if indicated clinically.¹⁷ **Table 5** shows the follow-up guidelines for EC.^{16,17}

e) Follow-Up

In the post-treatment setting, most of the recurrences (95%) are known to occur within the first 2 years after

Principles of Management

For mucosal tumors, treatment options include ER and/or ablation (high-grade dysplasia, AC limited to mucosa, small

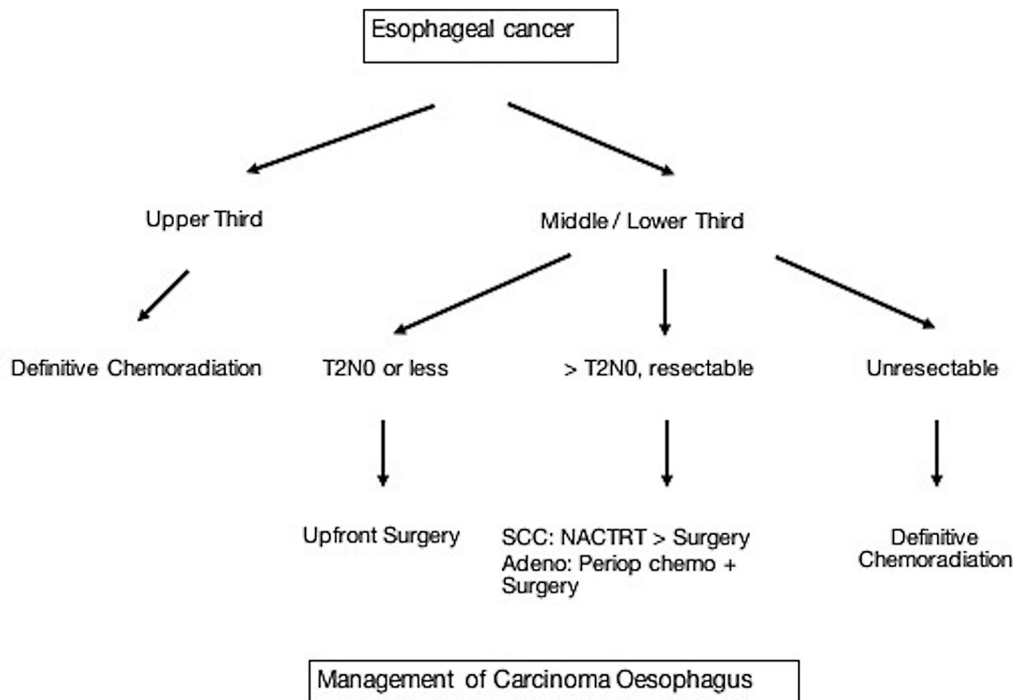


Fig. 6 Algorithm for the management of esophageal carcinoma. NACTRT, neoadjuvant chemoradiotherapy; Periop, perioperative; SCC: Squamous cell carcinoma.

Table 6 Location/stage-wise treatment of esophageal cancer

Location/stage of EC	Treatment
Upper third EC (including cervical)	Definitive chemoradiation
Tis, T1a	Endoscopic mucosal resection
Middle and lower third T1b, T2N0 or less	Upfront surgery
Middle and lower third localized disease greater than T3N0	NACTRT with CROSS protocol for SCC and perioperative chemotherapy with FLOT regimen for AC
T4b stage	Definitive chemoradiation
Involvement of trachea, great vessels, vertebra or heart	Palliative chemotherapy
Metastatic disease	Systemic therapy (chemotherapy and/or immunotherapy)

Abbreviations: EC: Esophageal cancer, NACTRT: neoadjuvant chemoradiotherapy, SCC: Squamous cell carcinoma, FLOT: Fluorouracil, Leucovorin, Oxaliplatin, Docetaxel, AC: Adenocarcinoma

Synoptic reporting format 1

Staging (pre-treatment) Esophageal and esophagogastric junction Cancer Imaging - Reporting and Data System (ECI-RADS) based on CECT or FDG-PET/CT

Demographics (Information provided by RIS and DICOM headers)

Name of the facility where examination was provided

- Name of the patient
- Patient's gender
- Patient's date of birth and age
- Name(s) of referring physician(s) or other health care provider(s)
- Name of type of examination
- Date and time of the examination
- Date and time of dictation and final transcription

Relevant clinical information

- Clinical symptoms
- Addictions – Smoking/Alcohol/ Chewing tobacco
- Co-existing health morbidities – Gastroesophageal reflux disease (GERD)/achalasia/ H. pylori status/COPD/ Diabetes Mellitus/ Immunocompromised status
- Occupational history for any relevant occupational exposures
- Previous cancer
- Previous surgery
- Previous chemotherapy or radiation
- Endoscopy findings (if done): distance of tumor from incisors, proximal and distal tumor extent, luminal obstruction, Barrett's esophagus
- Endoscopic ultrasound findings (if done): T staging, regional nodal status
- Current working diagnoses (if any)
- Recent most relevant laboratory tests including biomarkers (if available):

Body of the report:

- Type of study and the technical protocol
- Quality of examination

T Category

Esophagus

Location/epicenter: Cervical/upper third thoracic/middle third thoracic/lower third thoracic including esophagogastric junction

Size: Thickness* and craniocaudal dimension (including vertebral levels)

SUVmax (FDG-PET/CT):

Luminal obstruction: Present/Absent

Local invasion: Present/absent

Local invasion (for cervical esophageal cancer): Larynx, hypopharynx, thyroid gland, vertebrae

Local invasion (T4a) (for thoracic esophagus and esophagogastric junction cancer)

Pleura: Involved/indeterminate/uninvolved

Pericardium⁵: Involved/indeterminate/uninvolved

Azygous vein: Involved/indeterminate/uninvolved

Peritoneum (for esophagogastric junction): Involved/indeterminate/uninvolved

Diaphragm: Involved/indeterminate/uninvolved

Local invasion (T4b)

Aorta⁵:

Loss of fat plane: Yes/no

Angle of contact: $\leq 90^\circ$ / $> 90^\circ$ degree

Involved/indeterminate/uninvolved

Vertebra⁵:

Involved/indeterminate/uninvolved

Trachea/bronchus:

Abutment/mass within airway lumen/fistula formation with airway
Involved/indeterminate/uninvolved
Siewert type (for esophagogastric junction tumors): I/II/III

N Category

Nodes:

Number of regional nodes (if involved): 1–2/ 3–6/ 7 or more

Size and station of node (if involved):

SUVmax (FDG-PET/CT):

Involved/indeterminate/uninvolved #

M Category

Distant metastasis:

Site:

SUVmax (FDG-PET/CT):

Other findings

Synchronous tumor: Yes/ No

Any other finding:

*Needs additional imaging: EUS

\$ Needs additional imaging: MRI

Needs FNAC correlation

Synoptic reporting format 2

Post-therapy Esophageal and esophagogastric junction Cancer Imaging - Reporting and Data System (pECI-RADS) based on CECT or FDG-PET/CT

Demographics (information provided by RIS and DICOM headers)

Name of the facility where examination was provided

- a. Name of the patient
- b. Patient's gender
- c. Patient's date of birth and age
- d. Name(s) of referring physician(s) or other health care provider(s)
- e. Name of type of examination
- f. Date and time of the examination
- g. Date and time of dictation and final transcription

Relevant clinical information

- a. Clinical symptoms
- d. Recent most relevant laboratory tests and/or imaging findings

Indication: [Post surgery/ post neoadjuvant chemotherapy/chemoradiotherapy/post definitive radiotherapy]

Body of the report:

- a. Type of study and the technical protocol
- b. Quality of examination
- c. Comparison to previous study and date

Findings:

1. No evidence of residual disease/recurrence
2. No evidence of residual pathological lymph nodes/no new pathological lymph nodes.
3. Post-treatment changes are noted including:
 - [a] Post-surgery anastomotic stricture/leak: Yes/no
 - [b] Post-RT mucosal edema/stricture/pneumonitis: Yes/no
4. There are no findings to suggest a second primary in the oropharynx/head and neck/lungs
5. Evaluation of the visualized portions of liver, adrenals, lungs and bones show no aggressive lesions suspicious for metastatic involvement.

IMPRESSION:

1. Expected post treatment changes
2. Category of disease*.

***CECT or FDG-PET/CT Surveillance Legend:**

Category 1: No evidence of residual disease/recurrence.

Category 2: Low volume residual disease/low suspicion of recurrence.

SUVmax on FDG-PET/CT:

Category 3: High volume residual disease/ high suspicion of recurrence

SUVmax on FDG-PET/CT:

Category 4: No change in tumor volume/definitive recurrence

SUVmax on FDG-PET/CT:

Synoptic reporting format 3

Endoscopic ultrasound reporting format for esophageal cancer

- Tumor—T stage, maximal tumor thickness (mm)
- Nodes—Size, echogenicity, shape, borders, location, N stage, whether FNAC done
- Metastases (if seen)
- Incomplete staging due to stenotic tumors (when present)

Abbreviations: CECT, contrast enhanced computed tomography; COPD, chronic obstructive pulmonary disease; DICOM, digital imaging and communications in medicine; EUS, endoscopic ultrasonography; FDG-PET/CT, fluorodeoxyglucose positron emission tomography computed tomography; FNAC, fine-needle aspiration cytology; MRI, magnetic resonance imaging; RIS, radiology information system; SUVmax, maximum standardized uptake value.

tumor [$<2\text{cm}$] that are asymptomatic and non-circumferential).⁴² Upper third EC are best treated with definitive chemoradiation (CTRT). In middle and lower third, patients with T2N0 or less may be operated upfront without any neoadjuvant therapy.¹⁶ Any localized disease greater than T3N0 mandates neoadjuvant therapy despite being upfront resectable. As of today, the best evidence is for neoadjuvant chemoradiotherapy (NACTRT) with CROSS protocol for SCC and perioperative chemotherapy with Fluorouracil, Leucovorin, Oxaliplatin, Docetaxel (FLOT) regimen for AC.⁴³

For early-stage resectable tumors, either transhiatal or transthoracic (Ivor-Lewis) total esophagectomy or extended-3 field lymphadenectomy is performed depending upon the location or extent of tumor.⁴⁴ CTRT is given for T4b stage, except when trachea, great vessels, vertebra or heart, are involved, in which case, palliative chemotherapy is the only option. Depending on HER 2 overexpression and PD-L1 expression, targeted therapy or immunotherapy respectively, are given.¹⁶

Overall EC is very aggressive disease with poor prognosis. Five-year overall survival for localized disease is 39 and 4% for metastatic disease. SCC histology has poor outcome as opposed to AC histology.⁴⁵ Nutritional rehabilitation and cardiopulmonary evaluation are vital components in the overall management of EC patients.

►Fig. 6 depicts an algorithm for the management of EC. Location/stage-wise treatment of EC is presented in ►Table 6.^{16,43}

Follow-Up Imaging and Management of Recurrent Disease

Anastomotic leak is suspected in presence of fever, tachycardia, tachypnea, or arrhythmia in immediate postoperative period. Also, a close watch needs to be kept on the neck wound (for erythema /swelling) and nature of drain output (bilious/

purulent) in the postoperative period. CECT detects immediate post-surgical complications like fistulization of neoesophagus with airway and anastomotic leaks, and is also useful for the detection of esophageal edema after definitive concurrent chemoradiotherapy.^{2,46} CECT thorax assists in diagnosis by showing oral contrast extravasation and or air fluid level in pleural/mediastinum. CECT thorax also helps in draining out the collection by guiding pigtail.

Esophagogram on fluoroscopy can also be used in the immediate postoperative period to detect fistula or leaks, and a negative test warrants CECT, if clinical suspicion is high.²⁰ Delayed post-therapy imaging includes detection of recurrence and post-surgery/RT stricture. ►Fig. 7 (A and B) CECT images show post-NACTRT stricture formation in mid-esophagus (in supplement). Mantziari et al found FDG-PET/CT parameters (SUVmax, total lesion glycolysis and MTV) to be quite useful in predicting tumor recurrence and disease-free survival in patients with EC.⁴⁷ CECT may show new onset enhancing esophageal mural thickening suggestive of recurrence. Post-RT esophageal stricture occurs 3 to 8 months later and can be seen as esophageal luminal narrowing with proximal dilatation and air-fluid levels.^{2,48}

Localized recurrences after surgery are best treated with CTRT. Residual or recurrent disease after CTRT is considered for salvage surgery. Various systemic therapy options exist for both histologies. For palliation of dysphagia, local radiation (external beam or brachytherapy), feeding procedures (nasojejunal/gastric tube), or esophageal or airway stenting (for tracheobronchial infiltration) are feasible options.

Summary of Recommendations

1. Differentiation of T1a and T1b is best achieved by ER.¹⁶
2. EUS is the modality of choice for T staging of EC and for regional lymph node assessment.¹⁶

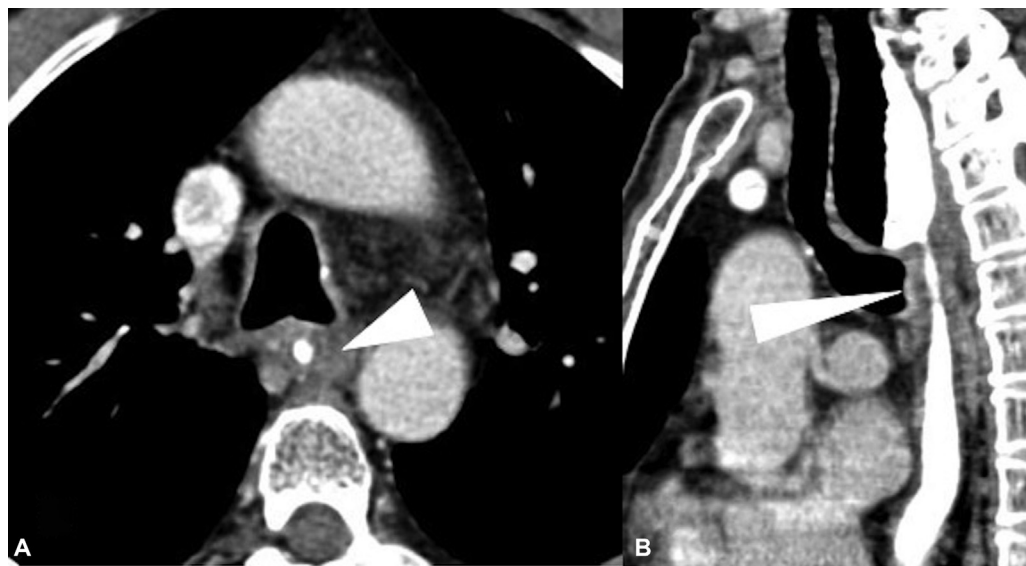


Fig. 7 (A and B) Case of squamous cell carcinoma of the middle third of the esophagus, postneoadjuvant chemoradiotherapy, presented with increasing dysphagia. Brush cytology was negative for malignancy. Axial (A) and sagittal (B) computed tomographic images show a short segment smooth circumferential wall thickening (arrowhead), with proximal esophageal dilatation.

3. Invasion of surrounding structures (T4 stage) is best depicted on CECT scan. Metastasis to liver and lungs and post-therapy complications are well visualized on CECT scan.^{2–4,22,46}
4. FDG-PET/CT is the modality of choice for detecting distant metastasis, occult metastasis, and synchronous tumors. Besides, detection of post-therapy recurrence and response evaluation is best achieved with FDG-PET/CT.^{16,30–33}

Synoptic reporting formats for pre-treatment (ECI-RADS) and post-therapy assessment (pECI-RADS),⁴⁹ along with EUS staging reporting format, are provided in the supplement.

The manuscript has been read and approved by all the authors and the requirements for authorship have been met, and each author believes that the manuscript represents honest work.

Author's Contributions

Nivedita Chakrabarty was involved in conceptualization, designing, definition of intellectual content, literature search, manuscript preparation, manuscript editing, Abhishek Mahajan was involved in manuscript editing and review.. Kumar Prabhash, Prachi Patil, Manoranjan Chowhan, Naveen Munmmudi, Devayani Niyogi, Deepak Dabkara, Suryaveer Singh, Ajaykumar Singh, Sanjana Devarmani, and Varun Singh Dhull contributed to manuscript preparation.

Ethical Committee Clearance

Not required as patient data not revealed.

Conflicts of Interest

None declared.

References

- 1 Sung H, Ferlay J, Siegel RL, et al. Global cancer statistics 2020: GLOBOCAN estimates of incidence and mortality worldwide for 36 cancers in 185 countries. *CA Cancer J Clin* 2021;71(03): 209–249
- 2 Jayaprakasam VS, Yeh R, Ku GY, et al. Role of imaging in esophageal cancer management in 2020: update for radiologists. *AJR Am J Roentgenol* 2020;215(05):1072–1084
- 3 Kim TJ, Kim HY, Lee KW, Kim MS. Multimodality assessment of esophageal cancer: preoperative staging and monitoring of response to therapy. *Radiographics* 2009;29(02):403–421
- 4 Rice TW, Patil DT, Blackstone EH. 8th edition AJCC/UICC staging of cancers of the esophagus and esophagogastric junction: application to clinical practice. *Ann Cardiothorac Surg* 2017;6(02): 119–130
- 5 Daly JM, Fry WA, Little AG, et al. Esophageal cancer: results of an American College of Surgeons patient care evaluation study. *J Am Coll Surg* 2000;190(05):562–572, discussion 572–573
- 6 Hoebein A, Polak J, Van De Voorde L, Hoebers F, Grabsch HI, de Vos-Geelen J. Cervical esophageal cancer: a gap in cancer knowledge. *Ann Oncol* 2016;27(09):1664–1674
- 7 Lee DJ, Harris A, Gillette A, Munoz L, Kashima H. Carcinoma of the cervical esophagus: diagnosis, management, and results. *South Med J* 1984;77(11):1365–1367
- 8 Domper Arnal MJ, Ferrández Arenas Á, Lanás Arbeloa Á Esophageal cancer: Risk factors, screening and endoscopic treatment in Western and Eastern countries. *World J Gastroenterol* 2015;21(26):7933–7943
- 9 Huang FL, Yu SJ. Esophageal cancer: Risk factors, genetic association, and treatment. *Asian J Surg* 2018;41(03):210–215
- 10 Watanabe M. Risk factors and molecular mechanisms of esophageal cancer: differences between the histologic subtypes. *J Cancer Metastasis Treat* 2015;1:1–7
- 11 Choksi D, Kolhe KM, Ingle M, et al. Esophageal carcinoma: an epidemiological analysis and study of the time trends over the last 20 years from a single center in India. *J Family Med Prim Care* 2020;9(03):1695–1699
- 12 Sekar A, Rajendra A, Noronha V, et al. The epidemiological trend of esophageal cancer in Mumbai, India over the past two decades. *Journal of Clinical Oncology* 2021;39(15_suppl)e16095–e16095
- 13 Accessed December 10, 2022, at: <https://gco.iarc.fr/today/data/factsheets/populations/356-india-fact-sheets.pdf>
- 14 Accessed December 10, 2022, at: <https://gco.iarc.fr/today/data/factsheets/cancers/6-Oesophagus-fact-sheet.pdf>
- 15 Accessed December 10, 2022, at: <https://www.msmanuals.com/en-in/professional/gastrointestinal-disorders/tumors-of-the-gastrointestinal-tract/esophageal-cancer>
- 16 Accessed December 10, 2022, at: https://www.nccn.org/professionals/physician_gls/pdf/esophageal.pdf
- 17 Lordick F, Mariette C, Haustermans K, Obermannová R, Arnold DESMO Guidelines Committee. Oesophageal cancer: ESMO Clinical Practice Guidelines for diagnosis, treatment and follow-up. *Ann Oncol* 2016;27(suppl 5):v50–v57
- 18 Accessed December 10, 2022, at: https://tmc.gov.in/ncg/docs/PDF/DraftGuidelines/ThoacicGuidelinesAndResearch/NCG_Esophageal_Cancer_Guidelines.pdf
- 19 Accessed December 10, 2022, at: <https://iria.org.in/oncologic-imaging-protocols-and-reporting-checklist/>
- 20 Accessed December 10, 2022, at: <https://acsearch.acr.org/docs/69471/narrative/>
- 21 Elsherif SB, Andreou S, Virarkar M, et al. Role of precision imaging in esophageal cancer. *J Thorac Dis* 2020;12(09):5159–5176
- 22 Iyer R, Dubrow R. Imaging of esophageal cancer. *Cancer Imaging* 2004;4(02):125–132
- 23 Enzinger PC, Mayer RJ. Esophageal cancer. *N Engl J Med* 2003;349(23):2241–2252
- 24 Shah MA, Kennedy EB, Catenacci DV, et al. Treatment of locally advanced esophageal carcinoma: ASCO guideline. *J Clin Oncol* 2020;38(23):2677–2694
- 25 Convie L, Thompson RJ, Kennedy R, Clements WD, Carey PD, Kennedy JA. The current role of staging laparoscopy in oesophagogastric cancer. *Ann R Coll Surg Engl* 2015;97(02):146–150
- 26 Dhakras P, Uboha N, Horner V, Reinig E, Matkowskyj KA. Gastrointestinal cancers: current biomarkers in esophageal and gastric adenocarcinoma. *Transl Gastroenterol Hepatol* 2020;5:55
- 27 DaVee T, Ajani JA, Lee JH. Is endoscopic ultrasound examination necessary in the management of esophageal cancer? *World J Gastroenterol* 2017;23(05):751–762
- 28 Mannath J, Ragnath K. Role of endoscopy in early oesophageal cancer. *Nat Rev Gastroenterol Hepatol* 2016;13(12):720–730
- 29 Bang JY, Ramesh J, Hasan M, et al. Endoscopic ultrasonography is not required for staging malignant esophageal strictures that preclude the passage of a diagnostic gastroscope. *Dig Endosc* 2016;28(06):650–656
- 30 Erasmus JJ, Munden RF. The role of integrated computed tomography positron-emission tomography in esophageal cancer: staging and assessment of therapeutic response. *Semin Radiat Oncol* 2007;17(01):29–37 s.
- 31 Mamede M, Abreu-E-Lima P, Oliva MR, Nosé V, Mamon H, Gerbaudo VH. FDG-PET/CT tumor segmentation-derived indices of metabolic activity to assess response to neoadjuvant therapy and progression-free survival in esophageal cancer: correlation with histopathology results. *Am J Clin Oncol* 2007;30(04): 377–388

- 32 Rustgi AK, El-Serag HB. Esophageal Carcinoma. *New England Journal of Medicine* 2014;371(26):2499–2509
- 33 Chen SH, Chan SC, Chao YK, et al. Detection of synchronous cancer by flurodeoxy glucose positron emission tomography/CT during primary staging work up for esophageal squamous cell carcinoma in Taiwan. *PLoS One* 2013;8(11):e82812
- 34 Metzger JC, Wollschläger D, Miederer M, et al. Inclusion of PET-CT into planning of primary or neoadjuvant chemoradiotherapy of esophageal cancer improves prognosis. *Strahlenther Onkol* 2017; 193(10):791–799
- 35 Zhong X, Yu J, Zhang B, et al. Using 18F-fluorodeoxyglucose positron emission tomography to estimate the length of gross tumor in patients with squamous cell carcinoma of the esophagus. *Int J Radiat Oncol Biol Phys* 2009;73(01):136–141
- 36 Lee G, Hoseok I, Seong-Jung K, et al. Clinical implication of PET-CT, MR in preoperative esophageal carcinoma staging compared with PETCT, EUS and CT. *JNM* 2014;55(08):1242–1247
- 37 Taniyama Y, Murakami K, Yoshida N, et al. Evaluating the effect of Neoadjuvant chemotherapy for esophageal cancer using the RECIST system with shorter-axis measurements: a retrospective multicenter study. *BMC Cancer* 2021;21(01):1008. Doi: 10.1186/s12885-021-08747-y
- 38 Lee S, Choi Y, Park G, et al. ¹⁸F-FDG PET/CT parameters for predicting prognosis in esophageal cancer patients treated with concurrent chemoradiotherapy. *Technol Cancer Res Treat* 2021;Jan-Dec;20–15330338211024655
- 39 Hodi FS, Ballinger M, Lyons B, et al. Immune-modified response evaluation criteria in solid tumors (imRECIST): refining guidelines to assess the clinical benefit of cancer immunotherapy. *J Clin Oncol* 2018;36(09):850–858
- 40 Chakrabarty N, Mahajan A, Baheti AD, et al. A radiologist's perspective on treatment-related pseudo progression: clues and hues. *Indian J Med Paediatr Oncol* 2022;43(01):52–59
- 41 Sudo K, Xiao L, Wadhwa R, et al. Importance of surveillance and success of salvage strategies after definitive chemoradiation in patients with esophageal cancer. *J Clin Oncol* 2014;32(30): 3400–3405
- 42 Malik S, Sharma G, Sanaka MR, Thota PN. Role of endoscopic therapy in early esophageal cancer. *World J Gastroenterol* 2018; 24(35):3965–3973 cited 2022Mar2 [Internet]
- 43 Al-Batran SE, Homann N, Pauligk C, et al; FLOT4-AIO Investigators. Perioperative chemotherapy with fluorouracil plus leucovorin, oxaliplatin, and docetaxel versus fluorouracil or capecitabine plus cisplatin and epirubicin for locally advanced, resectable gastric or gastro-oesophageal junction adenocarcinoma (FLOT4): a randomised, phase 2/3 trial. *Lancet* 2019;393(10184):1948–1957 cited 2022Feb11 [Internet]
- 44 Allum WH, Bonavina L, Cassivi SD, et al. Surgical treatments for esophageal cancers. *Ann N Y Acad Sci* 2014;1325(01):242–268 cited 2022Mar2 [Internet]
- 45 Cancer E. Statistics | Cancer.Net [Internet]. [cited 2022 Mar 2]. Accessed December 10, 2022, at: Available from: <https://www.cancer.net/cancer-types/esophageal-cancer/statistics>
- 46 Zeng C, Zhai T, Chen J, et al. Imaging biomarkers of contrast-enhanced computed tomography predict survival in oesophageal cancer after definitive concurrent chemoradiotherapy. *Radiat Oncol* 2021;16(01):8
- 47 Mantziari S, Pomoni A, Prior JO, et al. ¹⁸F- FDG PET/CT-derived parameters predict clinical stage and prognosis of esophageal cancer. *BMC Med Imaging* 2020;20(01):7
- 48 Park J-H, Kim KY, Song H-Y, et al. Radiation-induced esophageal strictures treated with fluoroscopic balloon dilation: clinical outcomes and factors influencing recurrence in 62 patients. *Acta Radiol* 2018;59(03):313–321
- 49 Chakrabarty N, Mahajan A. Esophageal cancer imaging - reporting and data system (ECI-RADS) and post-therapy ECI-RADS (pECI-RADS): Comprehensive synoptic reporting formats for esophageal cancer imaging: A narrative review. *Cancer Research, Statistics, and Treatment* 2022;5(03)