



Imaging Recommendations for Diagnosis, Staging, and Management of Lung Cancer

Aparna Irodi¹ Ashu Seith Bhalla² Leena Robinson Vimala¹ Taruna Yadav³ Subathra Adithan⁴
Harish Bhujade⁵ Parang Sanghavi⁶ Alok Kale⁸ Mandeep Garg⁵ Abhishek Mahajan⁷
Yvette Kirubha Jaykar David Livingstone⁸ Sudha Kiran Das⁹ Geethi M. H.¹⁰
Balukrishna Sasidharan¹¹ Balamugesh Thangakunam¹² Simon Pavamani¹³ Rajesh Isiah¹³
Anjana Joel¹⁴ Tameem Ahmad Bhat¹⁵

¹Department of Radiology, Christian Medical College, Vellore, Tamil Nadu, India

²Department of Radiodiagnosis and Interventional Radiology, AIIMS, New Delhi, India

³Department of Diagnostic and Interventional Radiology, All India Institute of Medical Sciences (AIIMS) Jodhpur, Rajasthan, India

⁴Department of Radiodiagnosis, Jawaharlal Institute of Postgraduate Medical Education and Research, Puducherry, India

⁵Department of Radiodiagnosis and Imaging, PGIMER, Chandigarh, India

⁶Department of Radiology, Picture this by Jankharia, Mumbai, Maharashtra, India

⁷Department of Radiodiagnosis, The Clatterbridge Cancer Centre NHS Foundation Trust, Liverpool, United Kingdom

⁸Radiology and Imaging Science Department, Apollo Main Hospital, Chennai, Tamil Nadu, India

⁹JSS Medical College, JSSAHER, Mysore, Karnataka, India

Address for correspondence Aparna Irodi, MD, FRCR, Department of Radiology, Christian Medical College, Vellore, Tamil Nadu 632004, India (e-mail: aparnashyam@gmail.com).

¹⁰Division of Radiation Oncology, RCC, Thiruvananthapuram, Kerala, India

¹¹Department of Radiation Oncology, Ida B. Scudder Cancer Centre Christian Medical College, Vellore, Tamil Nadu, India

¹²Department of Pulmonary Medicine Christian Medical College, Vellore, Tamil Nadu, India

¹³Department of Radiation Oncology, Ida B. Scudder Cancer Centre Christian Medical College, Vellore, Tamil Nadu, India

¹⁴Department of Medical Oncology, Christian Medical College, Vellore, Tamil Nadu, India

¹⁵Radiology, Shri Mata Vaishno Devi Narayana Superspeciality Hospital, Jammu, India

Ind J Med Paediatr Oncol 2023;44:181–193.

Abstract

Globally and in India, lung cancer is one of the leading malignancies in terms of incidence and mortality. Smoking and environmental pollution are the common risk factors for developing lung cancer. Traditionally, lung cancer is divided into small cell and nonsmall cell types, with nonsmall cell carcinomas including squamous cell carcinoma, adenocarcinoma, and large cell carcinoma.

Keywords

- ▶ cancer
- ▶ imaging
- ▶ lung
- ▶ recommendations

In this review article, we describe the imaging recommendations and findings in the diagnosis, staging, and management of lung cancer, including the imaging of treatment-related complications.

Introduction

Epidemiology

Globally, lung cancer is one of the leading malignancies in terms of incidence and mortality. It is the second most common malignancy in both the genders.¹ In India, lung cancer is one of the leading malignancies in men and fifth most common cancer in women. Its incidence varies between

numerous regions of India. The projected incidence of lung cancer in men in India in 2020 was 9.9 per 100,000 people.

Risk Factors

Smoking (80–90%) and environmental pollution are the leading risk factors for lung cancer in India.² Exposure to carcinogens in genetically susceptible individuals may cause

DOI <https://doi.org/10.1055/s-0042-1759572>.
ISSN 0971-5851.

© 2023. The Author(s).

This is an open access article published by Thieme under the terms of the Creative Commons Attribution License, permitting unrestricted use, distribution, and reproduction so long as the original work is properly cited. (<https://creativecommons.org/licenses/by/4.0/>)
Thieme Medical and Scientific Publishers Pvt. Ltd., A-12, 2nd Floor, Sector 2, Noida-201301 UP, India

activation of oncogenes and/or inactivation of tumor suppressor genes, resulting in neoplastic proliferation of cells.

Etiopathogenesis

Traditionally, lung cancer is classified into small cell lung cancer (SCLC) and nonsmall cell lung cancer (NSCLC) types, with nonsmall cell carcinomas including squamous cell carcinoma, adenocarcinoma, and large cell carcinoma. There is an increasing incidence of NSCLC in women and non-smokers. Following the worldwide trend, some studies in India are also reporting adenocarcinoma to be the most common pathological type in recent times, unlike squamous cell carcinoma that was more common previously.² However, other studies report no such change and still consider squamous cell carcinoma as the most common histopathological type.³

Clinical Presentation

Most patients with lung cancer in India are men (up to 82.9%); this disease is more commonly observed in the age range of 46 to 70 years, with a mean age of 58 years. The most commonly reported symptoms include cough, loss of weight and appetite, dyspnea, fatigue, chest pain, and hemoptysis. Patients may also present with paraneoplastic syndromes. Examination findings include digital clubbing, lymphadenopathy, superior vena cava obstruction, and neurological deficits in metastatic disease.⁴ Although in countries which have adopted lung cancer screening could potentially be detecting lung cancers at an earlier stage, 44 to 47.6% of patients with lung cancer in India present at an advanced stage with metastatic disease.²

Imaging plays an important role not only in the initial workup of patients with lung cancer but also in their regular follow-ups. It is also important to be aware of the changing profile of imaging appearances in patients with utilization of newer cancer treatments like immunotherapy.⁵

Imaging Referral Guidelines

General practitioners and other primary healthcare providers should refer a patient for a chest radiograph (CXR) when there are symptoms and signs suggestive of lung cancer like hemoptysis, loss of weight and appetite, persistent cough or dyspnea, chest pain, and abnormal chest signs. If the CXR is abnormal or if there is high index of clinical suspicion, even if CXR is normal, patient should be referred for a computed tomographic (CT) scan and to a specialist.⁶

On CXR, lung cancer may present as a nodule, irregular mass, nonresolving consolidation, lobar collapse, effusion, hilar or mediastinal enlargement. But, usually when these are observed on CXR, the disease stage is advanced. In early stages, CXR may appear to be normal.

AJCC, NCCN Guidelines for Imaging in Lung Cancer⁷⁻⁹

The first imaging test to be performed in a suspected case of lung cancer is CXR. Contrast-enhanced CT (CECT) of chest and upper abdomen (including adrenal glands) is recommended

for further evaluation. ¹⁸F-FDG PET-CT (positron emission tomography with 2-deoxy-2-[fluorine-18]fluoro-D-glucose integrating CT) is indicated in patients with no signs of metastatic spread on CT who are candidates for curative intent treatments.

Contrast-enhanced magnetic resonance imaging (MRI) of brain (or CECT of brain, if MRI not available) is recommended in patients with NSCLCs (stages Ib and higher) and small cell carcinomas (any stage) even if there are no relevant symptoms.

Contrast-enhanced MRI of thoracic inlet, spine, and brachial plexus is indicated to check for Pancoast tumor for the sake of local tumor extension assessment.

Indian Radiological and Imaging Association Guidelines for Imaging in Lung Cancer¹⁰

¹⁸F-FDG PET-CT scan is the most accurate investigation method for the staging of lung cancer. If a PET scan is not available, then a CECT scan of thorax, abdomen, pelvis, and whole-body bone scan needs to be done.

American College of Radiology Appropriateness Criteria for Imaging in Lung Cancer (–Table 1)¹¹

Ultrasound (US) of the abdomen may help in the evaluation of liver lesions that are observed to be ambiguous on CT scans.

According to most of the above-mentioned guidelines,⁷⁻⁹ once lung cancer is detected, a whole body ¹⁸F-FDG PET-CT scan would be the ideal modality to initially stage the disease. Gadolinium-enhanced MRI brain is recommended in all patients with SCLC or NSCLC except those with peripheral stage I (T1abc, N0). If PET-CT and MRI brain scans are not available, then CECT scan of the brain, thorax, abdomen, pelvis, and bone is recommended to be done for stage evaluation.

Clinical and Diagnostic Workup Excluding Imaging

Workup of lung carcinoma is dependent on the clinical presentation. The multipronged approach to complete diagnosis comprises three steps—histological diagnosis, staging, and functional evaluation. Additional tests are reserved for those who present with paraneoplastic syndromes.

Tests such as complete hemogram, liver function, calcium, electrolytes, blood urea nitrogen, and creatinine are performed as part of the initial assessment.

Tissue sample can be obtained via CT or endobronchoscopic-guided biopsy.^{7,9} Histology of the provided sample with light microscopy and immunohistochemical staining aids in the detection of subtypes of lung carcinoma. Molecular profiling serves as a biomarker to predict response to targeted therapies and immunotherapies.¹² Sampling of mediastinal nodes by endoscopic or endobronchial US or mediastinoscopy is recommended for histopathological analysis in all cases, with the exception of early-stage peripheral disease or if nodes are negative on PET-CT.

Table 1 ACR appropriateness criteria for imaging in lung cancer

CT thorax	CECT is preferred. NCCT can be done if contrast cannot be administered for any reason
¹⁸ F-FDG PET-CT	PET imaging from skull base to upper thigh is recommended for evaluation of extrathoracic disease
CT abdomen and pelvis	To look for extrathoracic disease if PET-CT is not available
Bone scan	To look for skeletal metastasis if PET-CT is not available
MRI brain	With gadolinium in NSCLC stage II, III, or IV even in the absence of neurological symptoms Any stage of NSCLC with neurological symptoms All small cell carcinoma (irrespective of stage)
CT head	With contrast, only if MRI brain cannot be performed
MRI thorax	For superior sulcus tumors or in equivocal findings on chest CT, to better evaluate for chest wall or mediastinal infiltration
MRI abdomen	Chemical shift imaging of adrenal gland lesions to see if they are adenomas or metastases (may not be necessary if PET-CT is performed)

Abbreviations: ACR, American College of Radiology; CECT, contrast-enhanced computed tomography; ¹⁸F-FDG PET-CT, fluorine-18 fluorodeoxyglucose positron emission tomography-computed tomography; NCCT, noncontrast computed tomography; MRI, magnetic resonance imaging; NSCLC, nonsmall cell lung cancer.

Variable sensitivity and specificity ranging from 77.4 to 81.3% and 79.4 to 90.1%, respectively, have been reported for PET-CT in mediastinal nodal staging in lung cancer.¹³

Additional diagnostic tests can be performed in patients with comorbidities or paraneoplastic symptoms; for example: a comprehensive paraneoplastic antibody panel for those with neurological syndromes, serum and urine osmolality in a suspected case of Syndrome of inappropriate antidiuretic hormone secretion, serum cortisol levels for Cushing's syndrome.⁷

If the patient has signs and symptoms suggestive of chronic obstructive pulmonary disease and has been scheduled for surgery or radiotherapy (RT), functional assessment with spirometry and 6-minute walk test and cardiac evaluation with electrocardiogram as well as echocardiogram is performed. Radionuclide lung perfusion scintigraphy can also be performed to measure the perfusion to the lung being resected during surgery and to predict postoperative lung function.¹⁴

Imaging Guidelines

Screening

It has been proven that if lung cancer is detected early, its 5-year survival rate can be significantly improved.¹⁵ National Comprehensive Cancer Network (NCCN) was the first major organization to develop lung cancer screening using low-dose CT (LDCT). It was based on the National Lung Screening Trial which showed that LDCT screening reduced the relative risk of death from lung cancer by 20%.¹⁶ The International Early Lung Cancer Action Program showed annual CT screening allows at least 80% of lung cancer cases to be diagnosed early, that is, in clinical stage I.¹⁷ The Nelson trial showed that 65 to 70% of cancers diagnosed in the screening arm were in stage IA and II, while 70% were in stage III/IV in the control arm.¹⁸

The Korean Lung Cancer Screening Project showed that lung cancer screening in a tuberculosis-endemic country may be less effective because of high incidence of false-

positive results.¹⁹ The TALENT lung cancer screening study in Taiwan showed a high detection rate of 2.6% for early lung cancer with more than 96.5% of them being operable.²⁰ A recent study by Parang and Bhavin showed high effectiveness of LDCT to detect or diagnose lung nodules and carcinoma in smokers even in a tuberculosis-endemic country like India.²¹

The American College of Radiology has developed Lung imaging Reporting and Data System to standardize the reporting and data management from LDCT examination.²²

Eligibility Criteria for Lung Cancer Screening

Various societies have proposed eligibility criteria for annual LDCT lung cancer screening that is given in ►Table 2.²³⁻²⁶

Proposed protocol for LDCT in lung cancer screening is provided in ►Table 3.

Most societies recommend yearly LDCT for lung cancer screening in eligible individuals.

Diagnosis

As most of the cases with lung carcinoma present with advanced stages, diagnosis is usually not difficult by utilizing both modalities: CXR and CECT thorax. However, one-third of lung carcinoma cases have a solitary pulmonary nodule that may be difficult to differentiate from a benign nodule.²⁷ Some of the imaging features may help to differentiate lung malignancy from benign lung lesions that are given in ►Table 4.

The Fleischner Society has formulated the guidelines for the assessment of an incidentally detected lung nodule based on appearance, growth rate, patient age, and history of smoking.²⁸

Other features to be assessed on CT scans include invasion/ infiltration into surrounding structures like intercostal muscles and mediastinum, presence of lymphangitis (irregular nodular septal thickening adjacent to the tumor mass), adenopathy, erosion of ribs or vertebrae, and distant metastases. Central mass lesions may show either encasement and occlusion of segmental or lobar bronchus/endobronchial

Table 2 Eligibility criteria for lung cancer screening by various specialty societies

Organization	Patient age/symptoms	Smoking history (pack-years)	Other factors
ACCP, ASCO, ATS, ACS, and ALS	55–74, asymptomatic	≥ 30	Less than 15 years since smoking cessation
NCCN	55–74, asymptomatic or ≥ 50 asymptomatic	≥ 30 ≥ 20	Less than 15 years since smoking cessation or one or more additional risk factors like pulmonary disease, family history of lung cancer, personal cancer history, radon exposure
ESR	55–80 years	At least 30 pack-years	Current smoker or exsmoker who has quit smoking within the last 15 years
USPSFT	55–80 asymptomatic	≥ 30	Less than 15 years since smoking cessation

Abbreviations: ACCP, American College of Chest Physicians; ACS, American Cancer Society; ALA, American Lung Association; ASCO, American Society of Clinical Oncology; ATS, American Thoracic Society; ESR, The European Society of Radiology; NCCN, National Comprehensive Cancer Network; USPSFT - U.S. Preventive Services Task Force.

Table 3 LDCT protocol

kV	120
mAs	50
Pitch	1.2
Slice thickness	1 mm
Slice interval	0.5 mm
Scan region	Thoracic inlet to costophrenic angles
Respiration	Suspended end-inspiration
Reconstructions	Lung (e.g., B70) and soft tissue (e.g., B35) reconstructions and window setting
Effective radiation dose	< 1.2 mSv

Abbreviation: LDCT, low-dose computed tomography.

component or encasement of adjacent vessels. The imaging signs indicating invasion are tumor-mediastinal/pleural contact of more than 3 cm length, absence of the fat plane between the mass and mediastinum, thickening of the pleura, increased density of the extra-pleural fat adjacent to the tumor, angle of contact of tumor being more than 90 degrees with the aorta.

Short-axis dimension more than 10 mm is generally considered to be indicative of abnormal mediastinal or hilar lymph node. Malignant nodes can be necrotic, but infections like tuberculosis also can show necrotic nodes.

Sampling of Lung Lesions

Tissue sampling is required during these scenarios: new or growing solitary mass, multiple nodules without known malignancy, and biopsy or re-biopsy of malignancy for targeted therapy. Various methods for sampling of lung nodule are available that include fiberoptic bronchoscopy, endobronchial ultrasound (EBUS) guided sampling, transthoracic needle biopsy, and video-assisted thoracoscopic surgery.

¹⁸F-FDG PET-CT helps to locate the site of biopsy, especially in larger tumor masses, where biopsy should be done

from FDG-avid areas. For central lesions, bronchoscopic or EBUS-guided approach is preferred. Transthoracic US or CT-guided approach may be used depending upon the location and ease of access to the lung lesion. Coaxial system should be used to take multiple samples and to increase yield and safety.²⁹ As per the recent advances in molecular targeted therapy in lung cancers, larger sample volume is needed for necessary molecular testing. Therefore, core biopsy is preferred over fine needle aspirations.

Abnormalities detected by ¹⁸F-FDG PET scan have to be confirmed radiologically or pathologically. CT staging alone is not adequate for nodal involvement, as CT-based criteria of short axis dimension of more than 10 mm size of the lymph nodes has been shown to have a sensitivity of 55%, and specificity of 81%.³⁰ A higher sensitivity of 83% and specificity of 92% are reported when high FDG uptake on PET is taken as a criterion for diagnosing nodal metastasis.³¹ Invasive sampling of suspicious nodes is recommended using EUS/EBUS/mediastinoscopy/ CT guidance. If pleural or pericardial effusion is present, US-guided thoracentesis or pericardiocentesis is undertaken. Thoracoscopy can be performed when repeated pleural fluid analysis (at least 3 times) is inconclusive.

Staging

The aim of imaging with CT (→Figs. 1 and 2) and PET-CT (→ Fig. 3) scans is that to assign appropriate clinical staging of lung cancer. Eighth edition American Joint Committee on Cancer Tumor, Node, and Metastasis (AJCC TNM) staging for lung cancer was implemented in 2018 (→Tables 5 and 6).³² All aspects towards staging should be carefully looked for in the imaging.

Combined approach using TNM and veterans administration classification of SCLCs into³³:

- Limited (where disease is confined to a single hemithorax and adjacent nodes which can be safe to include in an RT field) and
- Extensive stage (extends beyond the hemithorax including malignant pleural or pericardial effusion) is used to make treatment decisions

Table 4 CT features in favor of benign and malignant lung nodule

Imaging features	Benign	Malignant	Comments
Size ^{23,24}	Less than 1 cm	More than 3 cm	Average of two orthogonal measurements is taken Smaller lesions can also be malignant
Margins ^{23,25}	Sharp, smooth, or well-defined	Spiculated, irregular, ill-defined, "pleural tail"	20% of malignant nodules may show smooth and well-defined margins
Internal morphology			
Density ^{26,27}	Pure ground glass density nodules <5 mm in size could represent atypical adenomatous hyperplasia	<ul style="list-style-type: none"> - Pure ground glass density nodule 6–30 mm could represent adenocarcinoma in situ - Part-solid nodule with solid component < 5 mm could represent minimally invasive adenocarcinoma - Part-solid nodule with solid component > 5 mm could represent invasive adenocarcinoma - Solid nodules or consolidation could represent mucinous adenocarcinoma in situ, invasive mucinous adenocarcinoma 	Based on density nodules can be solid or subsolid. Subsolid nodules can be pure ground glass density or part-solid
Calcifications	Diffuse, central, popcorn, laminated	Amorphous, punctate	
Fat ²⁸	Presence of fat (–40 to –120 HU) favors benign lesion like hamartoma	Fat is usually absent in malignancy	
Cavitation	Smooth, thin walls. Usually less than 4 mm wall thickness	Thick, irregular walls. Usually more than 16 mm wall thickness	
Growth rate ²⁹	More than 400 days or very short in infections	Doubling time 20 to 400 days (average 240)	The serial volumes instead of diameters and computer-aided doubling of volume of small nodules have been proposed to be an accurate way to evaluate growth Small and large cell cancers may show a faster growth
Contrast enhancement ³⁰	Less than 15 HU	More than 20 HU	Larger malignant lesions tend to show more heterogeneous contrast enhancement due to presence of necrosis within the lesion
Metabolism ³¹	Less than 2.5 SUV	More than 2.5 SUV	Note that infective and inflammatory conditions also can show high SUV. PET can help in guiding biopsy to the areas with increased FDG avidity

Abbreviations: CT, computed tomography; FDG, fluorodeoxyglucose; HU, Hounsfield unit; PET, positron emission tomography; SUV, standardized uptake value.

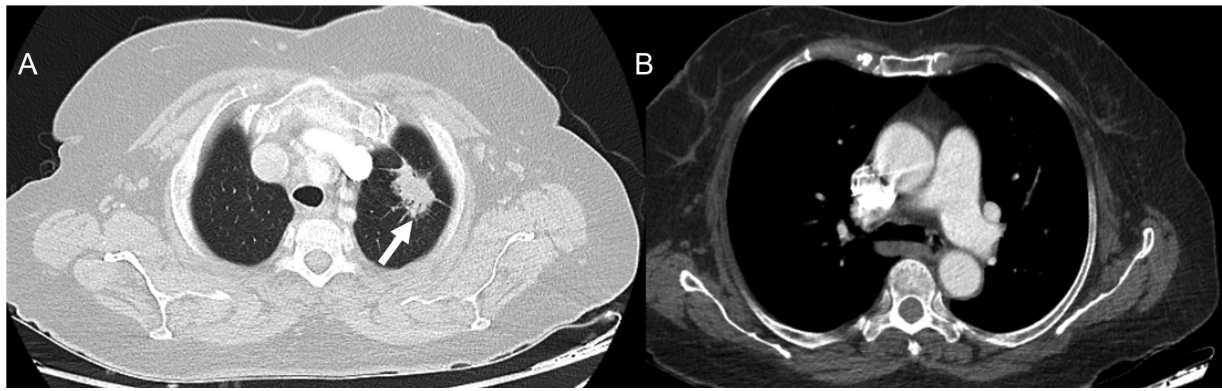


Fig. 1 (A) Axial computed tomographic (CT) thorax section in lung window shows a spiculated mass (white arrow) of longest dimension 2.8 cm in the apicoposterior segment of the left upper lobe. (B) Axial CT thorax section in mediastinal window reveals that there are no enlarged mediastinal or hilar nodes. TNM (tumor, nodes, and metastases) stage: T1cN0M0.

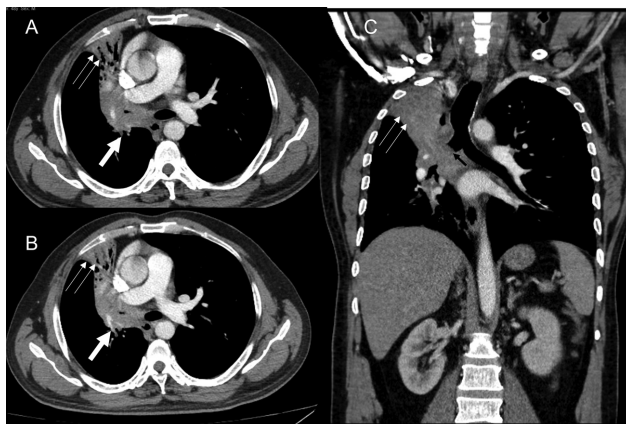


Fig. 2 (A and B) Axial computed tomographic (CT) thorax sections demonstrate central hilar mass having convex margin (white arrow) causing occlusion of right upper lobe bronchus, bronchus intermedius, right middle lobe bronchus with the resultant collapse, with mild peripheral bronchiectasis of right upper and right middle lobe having retained secretions in the peripheral bronchi (double thin white arrow). The lesion infiltrates and merges with the ipsilateral mediastinal, hilar, and subcarinal nodes. (C) The coronal CT thorax section also reveals the medial extension into the right main bronchus (black arrow). No distant metastases. TNM stage: T4N2.

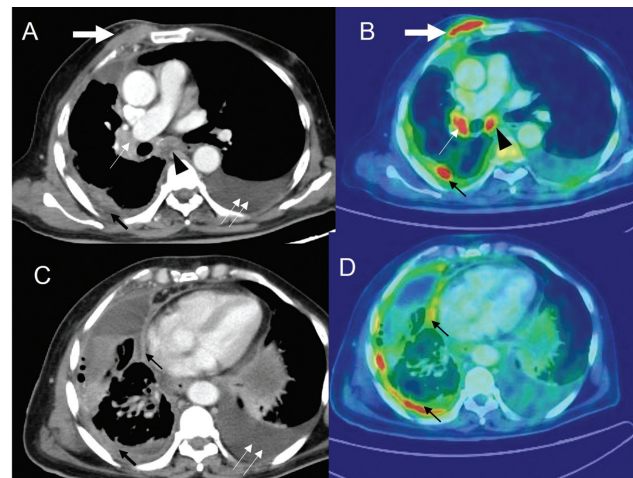


Fig. 3 Patient with adenocarcinoma of the lung with positron emission tomography-computed tomography (PET-CT) imaging. CT thorax (A and C) and corresponding fluorine-18 fluorodeoxyglucose positron emission tomography (^{18}F -FDG PET) images (B and D) demonstrate chest wall extension (thick white arrow), having standardized uptake value (SUV) of 9.4, enlarged right hilar (thin white arrow) and 7.6, respectively. Pleural effusion with nodular pleural thickening (thin black arrow) with SUV of 6.6. Moderate amount of pleural effusion (double thin white arrows) on the left side.

Management (Response Assessment Imaging in Neoadjuvant, Adjuvant, and Palliative Settings)

Tumor Response Assessment

The major attribute of RECIST 1.1 that is widely used for tumor response assessment is given in **Table 7**.^{34,35}

Limitations of RECIST 1.1:

- (i) RECIST 1.1 is based on anatomical unidimensional measurement. The appropriateness of moving to three-dimensional volumetric measurement or functional measurement using PET/MRI scan was considered but not incorporated, due to insufficient standardization and evidence.
- (ii) RECIST 1.1 also does not contemplate morphological changes such as tumor cavitation.

- (iii) Interreader variability can be present in reporting new lesions and non-target lesions
- (iv) RECIST 1.1 does not consider pseudoprogression.

Immune-Related Response Criteria

Following immunotherapy, there may be an appearance of new lesions or an increase in size of existing lesions before eventual regression and partial or complete response. This may be due to infiltration by T cells and is called “pseudoprogression.” An increase in the size of lesions associated with rapid clinical decline is termed as “hyperprogression.”

The iRECIST criteria have been proposed for use in clinical trials for patients treated with immunotherapy.³⁶ (Flowchart 1) iRECIST has not been validated for treatment decisions. An important limitation of using iRECIST is that if the original progression was a true progression, effective salvage therapy gets delayed by several weeks.

Table 5 AJCC TNM 8th staging of lung cancer

T staging	N staging	M staging
T0—No primary tumor Tis—Carcinoma in situ T1—Tumor < 3 cm (T1mi—minimally invasive adenocarcinoma; T1a—Superficial spreading tumor in central airways) T1a—Tumor < 1 cm T1b—Tumor > 1 cm but < 2 cm T1c—Tumor > 2 cm but < 3 cm T2—Tumor > 3 cm but < 5 cm or tumor involving visceral pleura/main bronchus (not carina)/atelectasis up to hilum T2a—Tumor > 3 cm but < 4 cm T2b—Tumor > 4 cm but < 5 cm T3—Tumor > 5 cm but < 7 cm or invading chest wall, pericardium, phrenic nerve; or separate tumor nodule(s) in the same lobe T4—Tumor > 7 cm or tumor invading mediastinum/diaphragm/heart/great vessels/recurrent laryngeal nerve/carina/trachea/esophagus/spine or tumor nodule(s) in a different lobe in same lung	N0—No regional node metastasis N1—Metastasis in ipsilateral pulmonary or hilar nodes N2—Metastasis in ipsilateral mediastinal or subcarinal nodes N3—Metastasis in contralateral mediastinal, hilar, or supraclavicular nodes	M0—No distant metastasis M1a—Malignant pleural or pericardial effusion or pleural or pericardial nodules or separate tumor nodule(s) in the contralateral lung M1b—Single extrathoracic metastasis M1c—Multiple extrathoracic metastases (in 1 or >1 organ)

Abbreviation: AJCC TNM, American Joint Committee on Cancer Tumor, Node, and Metastasis.

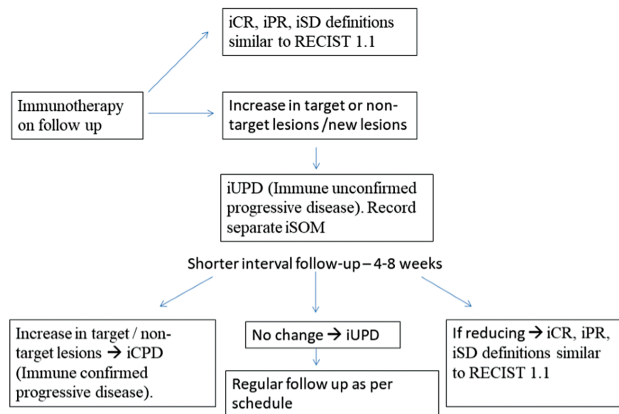
Table 6 Stage grouping according to AJCC 8th ed TNM staging of lung cancer

T/M	Subcategory	N0	N1	N2	N3
T1	T1a	IA1	IIB	IIIA	IIIB
	T1b	IA2	IIB	IIIA	IIIB
	T1c	IA3	IIB	IIIA	IIIB
T2	T2a	IB	IIB	IIIA	IIIB
	T2b	IIA	IIB	IIIA	IIIB
T3	T3	IIB	IIIA	IIIB	IIIC
T4	T4	IIIA	IIIA	IIIB	IIIC
M1	M1a	IVA	IVA	IVA	IVA
	M1b	IVA	IVA	IVA	IVA
	M1c	IVB	IVB	IVB	IVB

Abbreviation: AJCC TNM, American Joint Committee on Cancer Tumor, Node, and Metastasis.

Table 7 RECIST 1.1 criteria for tumor response assessment

Measurable and target lesions	A maximum of 5 total target lesions (a maximum of 2 per organ) are quantitatively assessed The lesion must be at least 10 mm in size The sum of the longest diameters is recorded as the sum of measurable lesions (SOM) Pathological lymph nodes with a short axis diameter of 15 mm or more can be considered as target lesions. For lymph nodes, a short axis dimension is taken for SOM
Nontarget and nonmeasurable lesions	May be recorded qualitatively Lesions less than 10 mm; nodes between 10 and 15 mm Nonmeasurable lesions like pleural or pericardial effusion or lymphangitis
Progressive disease (PD)	At least 20% increase in size over the nadir (smallest measured tumor burden during the course of the disease). The minimum increase should be at least 5 mm “Unequivocal” progression in nonmeasurable or other non-target lesions (effusions, bone lesions) is recorded as PD Any new lesions are considered as PD
Partial response (PR)	When there is more than 30% decrease in size from baseline
Complete response (CR)	When there is complete disappearance of the lesion and pathological lymph nodes are reduced to less than 10 mm
Stable disease (SD)	



Flowchart 1 iRECIST criteria for follow-up of patients who are on immunotherapy. iCR, immune complete response; iPR, immune partial response; iSD, immune stable disease.

Complications of Treatment

Complications of Radiotherapy

Conformal RT is typically used for patients with advanced stage lung cancer and the treatment course is over 6 to 7 weeks. In contrast, stereotactic body radiotherapy (SBRT) is used for early-stage lung cancer; precise high dose fractions are given over a period of 2 weeks.

Intensity-modulated RT (IMRT) is a technique in which radiation is delivered using multiple RT fields of varying influence; both conventional RT and SBRT can be delivered using this technique. Use of IMRT reduces the radiation delivered to the normal lung tissue around the tumor. Thus, treatment with IMRT can result in unusual patterns

of pneumonitis in the patient, since radiological pneumonitis changes correlates with the shape of the RT field/plan.³⁷

Acute radiation pneumonitis (**Fig. 4**) can manifest as consolidation with air-bronchogram and straight borders and occurs 1 to 6 months after RT. Radiation fibrosis sets in at 6 to 12 months and stabilizes at 1 year period. Radiation fibrosis manifests as traction bronchiectasis, volume loss, kinking of airways, and pleural thickening/effusion.

Post RT changes in the lung can be FDG-avid for up to 2 years. In previously irradiated patients, treatment with immune checkpoint inhibitors (ICI) can cause RT recall pneumonitis (pneumonitis in the irradiated regions of the lung), years after completion of RT. Besides pneumonitis, pulmonary artery thrombosis, esophagitis, fistulas, cardiac disease have been reported as complications of RT. Unlike radiation fibrosis, if the lesion is progressively increasing in size in real time or after 1 year of treatment, when the margins are convex and bulging, there is opacification of previously seen bronchograms, or development of new adenopathy of pleural effusion, then recurrence or disease progression needs to be suspected.³⁸

Immune-Related Adverse Events^{5,39,40}

Because of their unique mechanism of action, ICI can cause toxicities in several organs in the body, which can occur earlier or later during therapy. RT recall pneumonitis, described in post RT patients on ICI, occurs in previously irradiated tissue after weeks, months, or even years of radiation therapy.

Hypophysitis, sarcoid-like granulomatosis, lymphadenopathy, pneumonitis, hepatitis, colitis, adrenalitis, and inflammation in other parts of the body have been described

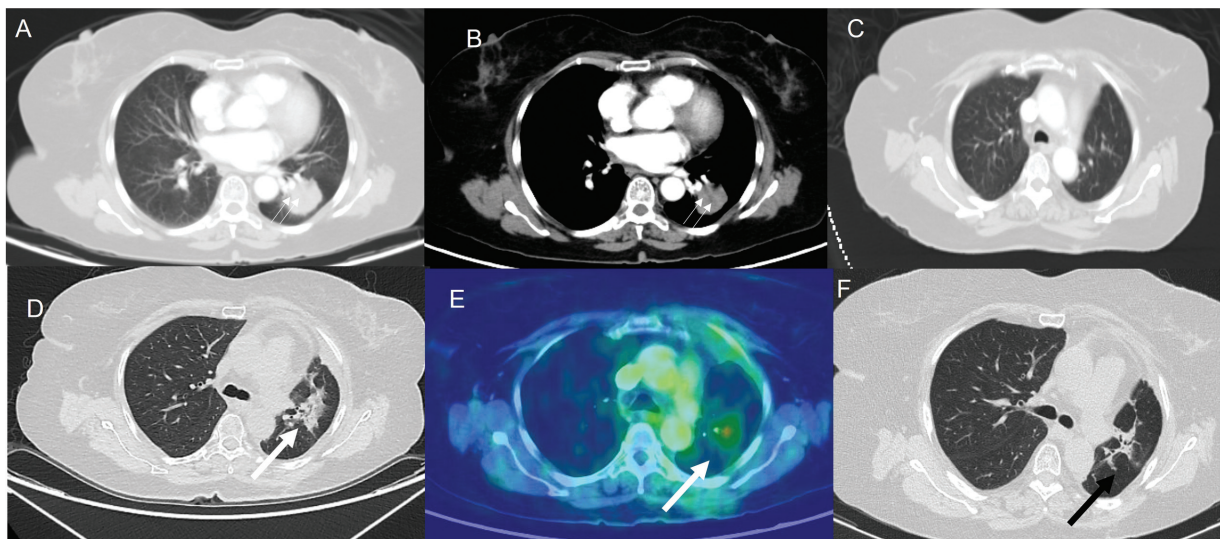


Fig. 4 (A and B) Computed tomographic (CT) thorax lung and mediastinal sections, respectively, demonstrate a lobulated mass (double thin white arrow) of 3.3 cm in the left lower lobe. No enlarged nodes. The patient underwent a left lower lobectomy. Histopathological examination revealed pleomorphic carcinoma with adenocarcinomatous component. Final stage was pT2aN2Mx. The patient had four cycles of adjuvant cisplatin and pemetrexed. (C) Post-chemotherapy and prior to radiotherapy, the CT thorax performed demonstrates no lesion in the left upper lobe. (D and E) CT thorax and corresponding fluorine-18 fluorodeoxyglucose positron emission tomography images demonstrate an irregular lesion (thick white arrow) in the left upper lobe having an standardized uptake value of 4.6. As the lesion appeared after starting radiotherapy and as there was no evidence of infection clinically, radiation pneumonitis was considered the most likely diagnosis. The patient was treated with steroids and follow-up CT thorax (F) demonstrates the replacement of the irregular parenchymal lesion with small residual fibrotic changes (black arrow).

Table 8 Radiological patterns in immune checkpoint inhibitor-related pneumonitis

Cryptogenic organizing pneumonia (COP) pattern	Peripherally distributed multifocal bilateral parenchyma consolidation and ground glass opacity (GGO)	This is the most common pattern
Diffuse alveolar damage pattern (DAD) (AIP/ARDS) (diffuse alveolar damage/acute interstitial pneumonia/acute respiratory distress syndrome)	Diffuse/multifocal; GGO/consolidation with lung volume loss and traction bronchiectasis	This is clinically the most serious type
NSIP (nonspecific interstitial pneumonitis) pattern	Peripherally distributed reticular opacities and GGO ± volume loss/traction bronchiectasis	These patients have relatively mild clinical manifestations
HP (hypersensitivity pneumonitis) pattern	Diffuse centrilobular nodules and GGO ± air trapping	

in association with ICI toxicity. They must be differentiated from metastasis, infection, or progressive disease.

ICI pneumonitis is relatively rare but clinically serious with different patterns described. (► **Table 8**).^{41,42} Treatment generally consists of corticosteroid therapy and delaying/stopping immunotherapy. After an initial response to corticosteroids, “Pneumonitis flare” can occur even without restarting immunotherapy.⁴³

Complications of Targeted Therapy

A recently published position paper by the Fleischner Society⁴⁴ recommends that radiological patterns be used to evaluate drug related pneumonitis which may be:

- a. Acute diffuse alveolar damage (DAD)
- b. Transient (simple pulmonary eosinophilia)
- c. Subacute—Organizing pneumonia and hypersensitivity pneumonitis (OP and HP)
- d. Chronic—Nonspecific interstitial pneumonitis.

A single drug may cause multiple radiological patterns. Epidermal growth factor receptor tyrosine kinase inhibitors

therapy has been associated with all the above patterns. ALK inhibitor therapy has been associated with OP and DAD patterns. The diagnosis is made based on the occurrence of new changes in the lungs, their temporal association with the drug, and exclusion of other causes. Management of these complications is by cessation of the drug course, immunosuppressive therapy, and supportive treatment.

Follow-Up Surveillance Imaging Guidelines

American Society of Clinical Oncology Guidelines⁴⁵

American Society of Clinical Oncology guidelines can be used for patients with curatively treated stage I to III NSCLC and SCLC in absence of clinical symptoms of recurrence as described in ► **Table 9**. These guidelines apply for all patients treated with any modality including surgery, SBRT, and chemoradiation.

NCCN Surveillance Guidelines

NCCN guidelines are described in ► **Tables 10** (NSCLC) and **11** (SCLC).^{7,9}

Table 9 ASCO guidelines for follow-up of curatively treated stage I–III NSCLC and SCLC PCI. Adapted from ASCO 2019 guidelines⁴⁵

ASCO 2019, lung cancer surveillance guidelines after definitive curative-intent therapy (stage I–III)			
	NSCLC	SCLC	Imaging modality
1. Frequency of imaging	Every 6 months for 2 years	Every 6 months for 2 years	Chest CT including adrenals ± contrast (contrast preferred)
	Annually after 2 years	Annually after 2 years	Low-dose screening chest CT
2. Role of brain MRI	No	First 2 years—every 3 months during first year and every 6 months during second year in patients with or without PCI	
3. Role of circulating biomarkers or FDG-PET-CT	No	No	
4. Any patient factors precluding surveillance?	May be omitted in clinically unsuitable patients or those unwilling to undergo further treatment. Age should not preclude surveillance imaging. Overall performance status, medical history, and patient preferences are to be considered.		

Abbreviations: ASCO, American Society of Clinical Oncology; CT, computed tomography; FDG-PET-CT, fluorodeoxyglucose positron emission tomography-computed tomography; NSCLC, nonsmall cell lung cancer; PCI, prophylactic cranial irradiation.

Table 10 NCCN surveillance guidelines: nonsmall cell lung cancer, Version 3.2020

Stage	Primary treatment	Imaging modality	Frequency of imaging
I–II	Surgery ± chemotherapy	H&P and chest CT ± contrast	Every 6 months for 2–3 years
		Low dose noncontrast chest CT	Annually after 2–3 years
I–II or III or IV (oligometastatic with all sites treated with definitive intent)	Primary treatment included RT	H&P and chest CT ¹ ± contrast	Every 3–6 months for 3 years, then
		H&P and chest CT ¹ ± contrast	Every 6 months for 2 years, then
		H&P and a low dose noncontrast CT chest	annually
		Any residual or new radiographic abnormalities	More frequent imaging may be required
Any stage	Chemotherapy ± RT—any residual or new radiographic abnormalities—more frequent imaging may be required.		
PET/CT or brain MRI	Not routinely indicated. PET-CT may be useful where CT scan shows a mass to differentiate between malignancy versus radiation fibrosis, atelectasis, or other benign conditions ²		
Smoking cessation	Smoking cessation advice, counselling, and pharmacotherapy		
Long term follow-up—cancer survivorship care	Cancer surveillance as above, immunizations, health monitoring, counselling for health promotion, and wellness		

Abbreviations: FDG, fluorodeoxyglucose; H&P, history and physical; NCCN, National Comprehensive Cancer Network; PET-CT, positron emission tomography-computed tomography; RT, radiotherapy.

1—Timing of CT scans within Guidelines parameters is a clinical decision. 2—Previous areas treated with RT may show FDG avidity till 2 years; so, histologic confirmation of apparent “recurrent” disease is mandatory. Adapted from NCCN Guideline: Non-Small Cell Lung Cancer. Version 3.2020 (2).

Table 11 NCCN surveillance guidelines: SCLC, Version 2.2022

Frequency and modality of imaging	H&P, blood work as clinically indicated. Chest CT ± abdomen/pelvis - Every 2–6 months (more frequently) for 2 years and less frequently thereafter
Brain MRI (preferred) or brain CT with contrast	Every 3–4 months during 1st year for all patients and then every 6 months during 2nd year, regardless of the PCI status
New pulmonary nodule	Workup for a potential new primary lesion should be initiated
FDG-PET-CT	Not recommended for routine follow-up
Smoking cessation intervention	For all patients with SCLC to decrease the occurrence of second primary tumors
Cancer survivorship care	Cancer surveillance as above, immunizations, health monitoring, counseling for health promotion and wellness

Abbreviations: FDG-PET-CT, fluorodeoxyglucose positron emission tomography-computed tomography; MRI, magnetic resonance imaging; NCCN, National Comprehensive Cancer Network; PCI, prophylactic cranial irradiation; SCLC, small cell lung cancer. Adapted from NCCN Guidelines: Small Cell Lung Cancer. Version 2.2022.

Principles of Management

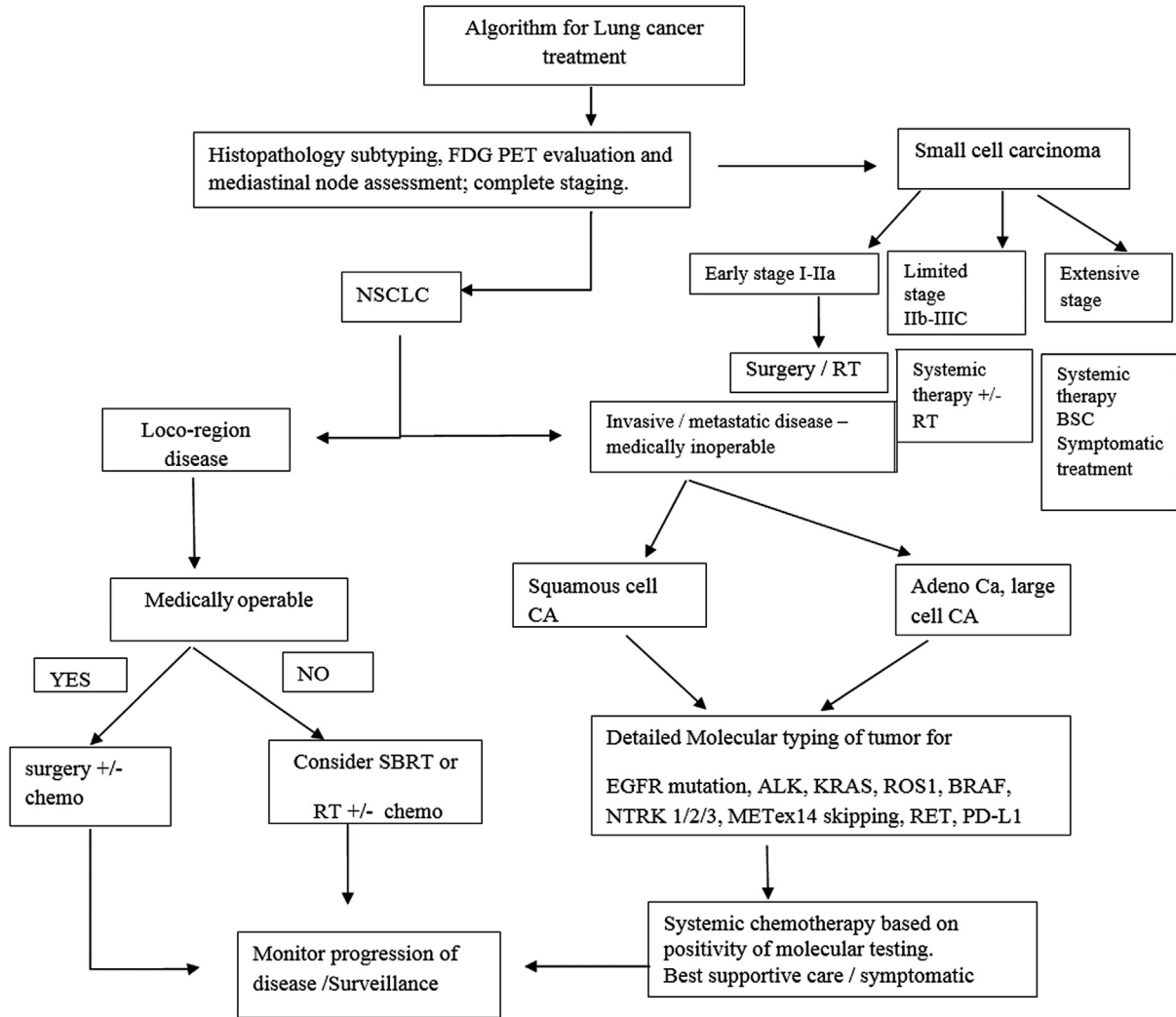
Multiple international guidelines for treatment of lung cancer exist, that is, NCCN and NICE.^{9,46} Surgery, RT, and systemic therapy are used either individually or in combination. Therapy type is determined by the histological type (NSCLC or SCLC), extent of disease, and fitness of the patient for curative surgery following multidisciplinary team assessment.⁴⁷ **Flowchart 2** highlights the main points in this complex management algorithm.

Image-guided thermal ablation treatment (IGTA) is a local ablative therapy that can be undertaken by interventional radiologist after an multidisciplinary team meeting decision is made to treat the patient with

IGTA. Most often this treatment is reserved for localized disease with tumor size less than 3 cm in size and potentially operable, but other comorbidities preclude surgery. Various electromagnetic energies like radio frequency, microwave, or cryoablation are used to thermally ablate the lesion without affecting the adjacent normal lung tissue. One of the common complications of IGTA is pneumothorax.

Follow-Up Imaging and Management of Recurrent Disease Including Specific Interventional and Palliative Measures

—**Tables 12 and 13** highlight the salient points in follow-up and management of recurrent disease.⁹



Flowchart 2 Highlights of principles of management of lung cancer. FDG PET, flourine-18 fluorodeoxyglucose positron emission tomography; NSCLC, nonsmall cell lung cancer; SBRT, stereotactic body radiotherapy; EGFR, epidermal growth factor receptor.

Table 12 NCCN recommendations for treatment and follow-up of loco-regional recurrence found on surveillance imaging

Symptoms/site of recurrence	Treatment options	Follow-up imaging (depends on initial recurrence and any newly developing symptoms)
Hemoptysis	RT/surgery/embolization	Contrast-enhanced chest CT Contrast-enhanced MRI brain PET-CT
SVC obstruction	SVC stenting, chemoradiation	
Endobronchial obstruction	Radiotherapy/stenting/laser / photodynamic therapy	
Resectable local recurrence	Resection	
Nodal recurrence	Chemoradiation/systemic therapy	

Abbreviations: MRI, magnetic resonance imaging; NCCN, National Comprehensive Cancer Network; PET-CT, positron emission tomography-computed tomography; SVC, superior vena cava.

Summary of Recommendations (Flowchart 3)

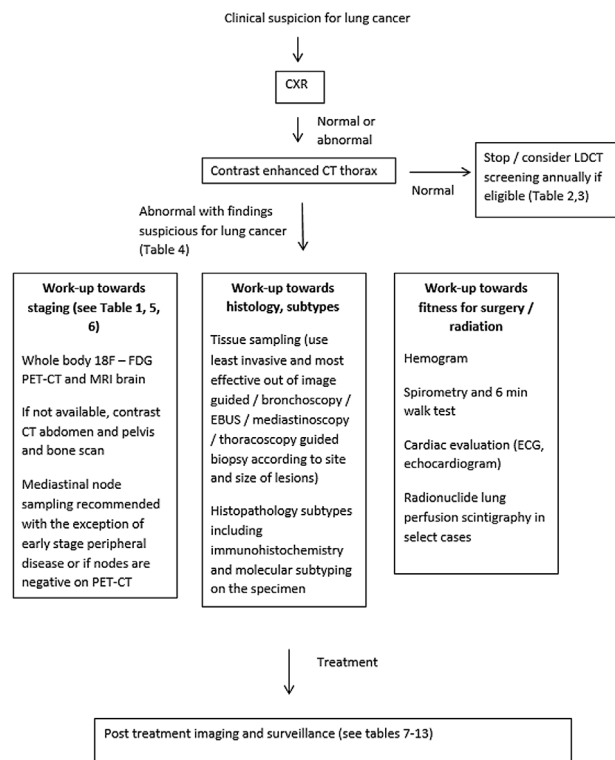
- Initial imaging in lung cancer includes CECT thorax and ¹⁸F-FDG PET-CT aiming for accurate clinical staging both locoregionally and extrathoracic metastases.

- Invasive lymph node sampling is recommended for suspicious nodes detected on CT or PET scans.
- Contrast-enhanced brain MRI scan is recommended in advanced stage NSCLCs and in all stages of SCLCs.
- Different surveillance protocols are available and radiologists should be aware of pseudoprogression that can

Table 13 NCCN recommendations for the treatment of distant metastases found on surveillance imaging

Symptoms/site of recurrence	Treatment options	Follow-up imaging
Localized symptoms	Palliative RT	No specific imaging recommended
Diffuse brain metastases	Palliative RT	
Skeletal metastases	Surgical stabilization/palliative RT/bisphosphonates	
Limited metastases	Resection	
Disseminated metastases	RT/ systemic therapy	

Abbreviations: NCCN, National Comprehensive Cancer Network; RT, radiotherapy.



Flowchart 3 Summary of recommendations in workup and follow-up of patients with lung cancer. CXR, chest X-ray; LDCT, low-dose computed tomography; EBUS, endobronchial ultrasound; ECG, electrocardiogram; 18F-FDG PET-CT, fluorine-18 fluorodeoxyglucose positron emission tomography computed tomography.

occur with ICI and therapy-related toxicities in the lungs and elsewhere in the body.

Conflict of Interest
None declared.

References

- 1 Thandra KC, Barsouk A, Saginala K, Aluru JS, Barsouk A. Epidemiology of lung cancer. *Contemp Oncol (Pozn)* 2021;25(01):45–52
- 2 Mohan A, Garg A, Gupta A, et al. Clinical profile of lung cancer in North India: a 10-year analysis of 1862 patients from a tertiary care center. *Lung India* 2020;37(03):190–197
- 3 Noronha V, Pinninti R, Patil VM, Joshi A, Prabhash K. Lung cancer in the Indian subcontinent. *South Asian J Cancer* 2016;5(03): 95–103
- 4 Mathur P, Sathishkumar K, Chaturvedi M, et al; ICMR-NCDIR-NCRP Investigator Group. Cancer statistics, 2020: report from

- 5 National Cancer Registry Programme, India. *JCO Glob Oncol* 2020; 6:1063–1075
- 6 Nishino M, Hatabu H, Hodi FS. Imaging of cancer immunotherapy: current approaches and future directions. *Radiology* 2019;290 (01):9–22
- 7 Del Giudice ME, Young SM, Vella ET, et al. Guideline for referral of patients with suspected lung cancer by family physicians and other primary care providers. *Can Fam Physician* 2014;60(08): 711–716, e376–e382
- 8 Ganti AKP, Loo BWJ, Bassetti M, et al. Small cell lung cancer, Version 2.2022, NCCN Clinical Practice Guidelines in Oncology. *J Natl Compr Canc Netw* 2021;19(12):1441–1464
- 9 Ettinger DS, Wood DE, Aisner DL, et al. Non-small cell lung cancer, Version 3.2022, NCCN Clinical Practice Guidelines in Oncology. *J Natl Compr Canc Netw* 2022;20(05):497–530
- 10 Ettinger DS, Wood DE, Aisner DL, et al. NCCN guidelines insights: non-small cell lung cancer, Version 2.2021. *J Natl Compr Canc Netw* 2021;19(03):254–266
- 11 Accessed November 15, 2022, at: <https://iria.org.in/radiology-imaging-guidelines>
- 12 de Groot PM, Chung JH, Ackman JB, et al; Expert Panel on Thoracic Imaging. ACR Appropriateness Criteria® noninvasive clinical staging of primary lung cancer. *J Am Coll Radiol* 2019;16(5S): S184–S195
- 13 Melosky B, Blais N, Cheema P, et al. Standardizing biomarker testing for Canadian patients with advanced lung cancer. *Curr Oncol* 2018;25(01):73–82
- 14 Schmidt-Hansen M, Baldwin DR, Hasler E, Zamora J, Abaira V, Roqué I Figuls M. PET-CT for assessing mediastinal lymph node involvement in patients with suspected resectable non-small cell lung cancer. *Cochrane Database Syst Rev* 2014;(11):CD009519. Doi: 10.1002/14651858.CD009519.pub2
- 15 Brunelli A, Kim AW, Berger KI, Addrizzo-Harris DJ. Physiologic evaluation of the patient with lung cancer being considered for resectional surgery: diagnosis and management of lung cancer, 3rd ed: American College of Chest Physicians evidence-based clinical practice guidelines. *Chest* 2013;143(5, Suppl): e166S–e190S
- 16 American Cancer Society. Cancer facts & figures 2020. Accessed November 15, 2022, at: <https://www.cancer.org/research/cancer-factsstatistics/all-cancer-facts-figures/cancer-facts-figures-2020.html>
- 17 Aberle DR, Adams AM, Berg CD, et al; National Lung Screening Trial Research Team. Reduced lung-cancer mortality with low-dose computed tomographic screening. *N Engl J Med* 2011;365 (05):395–409
- 18 Henschke CI, McCauley DI, Yankelevitz DF, et al. Early Lung Cancer Action Project: overall design and findings from baseline screening. *Lancet* 1999;354(9173):99–105
- 19 De Koning H, Van Der Aalst C, Ten Haaf K, et al. Effects of volume CT lung cancer screening: mortality results of the NELSON randomized-controlled population-based trial. Paper presented at: 2018 World Conference on Lung Cancer. Abstract PLO2.05; 2018

- 19 Kim H, Kim HY, Goo JM, Kim Y. Lung cancer CT screening and lung-RADS in a tuberculosis-endemic country: The Korean Lung Cancer Screening Project (K-LUCAS). *Radiology* 2020;296(01):181–188
- 20 Yang P. MS16.04 National Lung Screening Program in Taiwan. *IASLC 19th World Conf. Lung Cancer* 2018;13(10, Supplement):S274–S275
- 21 Parang S, Bhavin J. LDCT screening in smokers in India—a pilot, proof-of-concept study. *Indian J Radiol Imaging* 2021;31(02):318–322
- 22 McKee BJ, Regis SM, McKee AB, Flacke S, Wald C. Performance of ACR lung-RADS in a clinical CT lung screening program. *J Am Coll Radiol* 2016;13(2, Suppl):R25–R29
- 23 Wiener RS, Gould MK, Arenberg DA, et al; ATS/ACCP Committee on Low-Dose CT Lung Cancer Screening in Clinical Practice. An official American Thoracic Society/American College of Chest Physicians policy statement: implementation of low-dose computed tomography lung cancer screening programs in clinical practice. *Am J Respir Crit Care Med* 2015;192(07):881–891
- 24 Wood DE, Kazerooni EA, Baum SL, et al. Lung Cancer Screening, Version 3.2018, NCCN clinical practice guidelines in oncology. *J Natl Compr Canc Netw* 2018;16(04):412–441
- 25 Kauczor HU, Baird AM, Blum TG, et al; European Society of Radiology (ESR) and the European Respiratory Society (ERS) ESR/ERS statement paper on lung cancer screening. *Eur Radiol* 2020;30(06):3277–3294
- 26 Nitz JA, Erkmen CP. New 2021 USPSTF lung cancer screening criteria—an opportunity to mitigate racial disparity. *JAMA Oncol* 2022;8(03):383–384
- 27 Kishi K, Homma S, Kurosaki A, et al. Small lung tumors with the size of 1 cm or less in diameter: clinical, radiological, and histopathological characteristics. *Lung Cancer* 2004;44(01):43–51
- 28 Bueno J, Landeras L, Chung JH. Updated Fleischner Society Guidelines for Managing Incidental Pulmonary Nodules: common questions and challenging scenarios. *Radiographics* 2018;38(05):1337–1350
- 29 Lacasse Y, Wong E, Guyatt GH, Cook DJ. Transthoracic needle aspiration biopsy for the diagnosis of localised pulmonary lesions: a meta-analysis. *Thorax* 1999;54(10):884–893
- 30 Silvestri GA, Gonzalez AV, Jantz MA, et al. Methods for staging non-small cell lung cancer: diagnosis and management of lung cancer, 3rd ed: American College of Chest Physicians evidence-based clinical practice guidelines. *Chest* 2013;143(5, Suppl):e211S–e250S
- 31 Birim O, Kappetein AP, Stijnen T, Bogers AJ. Meta-analysis of positron emission tomographic and computed tomographic imaging in detecting mediastinal lymph node metastases in non-small cell lung cancer. *Ann Thorac Surg* 2005;79(01):375–382
- 32 Amin MB, Ed. *AJCC Cancer Staging Manual* 8th ed. Cham, Switzerland: Springer; 2017:431–455
- 33 Kalemkerian GP, Gadgeel SM. Modern staging of small cell lung cancer. *J Natl Compr Canc Netw* 2013;11(01):99–104
- 34 Eisenhauer EA, Therasse P, Bogaerts J, et al. New response evaluation criteria in solid tumours: revised RECIST guideline (version 1.1). *Eur J Cancer* 2009;45(02):228–247
- 35 Schwartz LH, Litière S, de Vries E, et al. RECIST 1.1-update and clarification: from the RECIST committee. *Eur J Cancer* 2016;62:132–137
- 36 Seymour L, Bogaerts J, Perrone A, et al; RECIST working group. iRECIST: guidelines for response criteria for use in trials testing immunotherapeutics. *Lancet Oncol* 2017;18(03):e143–e152
- 37 Strange CD, Shroff GS, Truong MT, Nguyen Q-N, Vlahos I, Erasmus JJ. Imaging of the post-radiation chest in lung cancer. *Clin Radiol* 2022;77(01):19–30
- 38 Huang K, Senthil S, Palma DA, et al. High-risk CT features for detection of local recurrence after stereotactic ablative radiotherapy for lung cancer. *Radiother Oncol* 2013;109(01):51–57
- 39 Berghmans T, Dingemans AM, Hendriks LEL, Cadranel J. Immunotherapy for nonsmall cell lung cancer: a new therapeutic algorithm. *Eur Respir J* 2020;55(02):1901907. Doi: 10.1183/13993003.01907-2019
- 40 Nishino M, Tirumani SH, Ramaiya NH, Hodi FS. Cancer immunotherapy and immune-related response assessment: the role of radiologists in the new arena of cancer treatment. *Eur J Radiol* 2015;84(07):1259–1268
- 41 Nishino M, Sholl LM, Hodi FS, Hatabu H, Ramaiya NH. Anti-PD-1-related pneumonitis during cancer immunotherapy. *N Engl J Med* 2015;373(03):288–290
- 42 Nishino M. Imaging of oncologic treatment-related pneumonitis: a focused review on emerging issues of immune checkpoint inhibitor pneumonitis, from the *AJR* special series on inflammation. *AJR Am J Roentgenol* 2022;218(01):19–27
- 43 Nishino M, Ramaiya NH, Awad MM, et al. PD-1 inhibitor-related pneumonitis in advanced cancer patients: radiographic patterns and clinical course. *Clin Cancer Res* 2016;22(24):6051–6060
- 44 Johkoh T, Lee KS, Nishino M, et al. Chest CT diagnosis and clinical management of drug-related pneumonitis in patients receiving molecular targeting agents and immune checkpoint inhibitors: a position paper from the Fleischner Society. *Radiology* 2021;298(03):550–566
- 45 Schneider BJ, Ismaila N, Aerts J, et al. Lung cancer surveillance after definitive curative-intent therapy: ASCO guideline. *J Clin Oncol* 2020;38(07):753–766
- 46 Maconachie R, Mercer T, Navani N, McVeigh GG. Guideline Committee. Lung cancer: diagnosis and management: summary of updated NICE guidance. *BMJ* 2019;364:l1049. Doi: 10.1136/bmj.l1049
- 47 Choi JI. Medically inoperable stage I non-small cell lung cancer: best practices and long-term outcomes. *Transl Lung Cancer Res* 2019;8(01):32–47