



Eponychial Flap: A Simpler Way to Achieve Better Aesthetic Outcome in a Fingertip Amputation

Srikant Aruna Samantaray¹  Kader Kalathingal¹  Hafiz Muhammed¹  Subin Joseph¹ 

¹ Department of Plastic Surgery, Baby Memorial Hospital, Kozhikode, Kerala, India

Address for correspondence Srikant Aruna Samantaray, DNB, Department of Plastic Surgery, Baby Memorial Hospital, Kozhikode 673004, Kerala, India (e-mail: srikant.arun@gmail.com).

Indian J Plast Surg 2022;55:391–395.

Abstract

Background There are numerous flaps described for the treatment of fingertip amputation. Shortened nail length resulting from amputation is an ignored area. Eponychial flap is a simple procedure that helps to lengthen the nail plate and correct this deformity.

Methods This case–control study was conducted between April 2016 and June 2020 aimed at comparing the outcome of nail defects in a fingertip amputation treated with eponychial flap and those treated without an eponychial flap.

Results Among 165 patients treated for fingertip injury, 78 were treated with eponychial flap (group A) and 87 without eponychial flap (group B). In group A, the nail length was 72.54% (standard deviation [SD]: 14.4) and the nail plate area was 74.35% (SD: 13.96) compared with the contralateral uninjured nail. These results were significantly better ($p = 0.000$) compared with group B where the values were 36.49 (SD: 8.45) and 35.8% (SD: 8.4), respectively. The aesthetic outcome score was also significantly higher in group A patients ($p = 0.002$). The patient satisfaction was superior in group A compared with group B.

Conclusion The eponychial flap is a simple and reliable technique that can be used to restore the visible nail length in traumatic fingertip defects. Compared with fingers treated without nail lengthening with eponychial flap gives excellent aesthetic results.

Keywords

- ▶ fingertip amputation
- ▶ eponychial flap
- ▶ fingertip injury

Introduction

Fingertip injuries with the involvement of the nail bed are fairly common. Various flaps have been described for fingertip reconstruction.^{1–3} Although these flaps provide a functional and aesthetic reconstruction in fingertip amputation injuries, the associated shortening of the nail complex remains unaddressed. This short nail, being a tell-tale sign of an amputated finger, is a psychological burden for the patient. We often come across patients asking for prosthetics

to hide it. In such cases, the reconstruction cannot be considered completely satisfactory.

Fingernail is not only important for the aesthetic appearance of a finger but is essential for pulp stability. It helps the hand to manipulate and pick up fine objects, enhances fingertip perception, contributes to tactile sensation, and helps in the regulation of peripheral circulation. It also serves as rigid protection for the fingertip.⁴ In a fingertip amputation, the distal phalanx length as well as the visible nail

article published online
December 30, 2022

DOI <https://doi.org/10.1055/s-0042-1759552>.
ISSN 0970-0358.

© 2022. Association of Plastic Surgeons of India. All rights reserved. This is an open access article published by Thieme under the terms of the Creative Commons Attribution-NonDerivative-NonCommercial-License, permitting copying and reproduction so long as the original work is given appropriate credit. Contents may not be used for commercial purposes, or adapted, remixed, transformed or built upon. (<https://creativecommons.org/licenses/by-nc-nd/4.0/>)
Thieme Medical and Scientific Publishers Pvt. Ltd., A-12, 2nd Floor, Sector 2, Noida-201301 UP, India

length is shortened. The exposed bone can be covered by variously described flaps.

Nail bed has a sterile and a germinal matrix. The proximal end of the nail is known as the nail fold/onychodermal band and proximal to this lies the eponychium. It covers the germinal matrix and the nail root. There is a part of the nail hidden under the eponychial fold, which can be used to increase the nail length when exposed. The eponychial flap is a backward cutaneous plication or transposition flap based on the proximal hypodermal-subdermal vascular plexus, that can increase the length of the nail, restoring a good appearance of the nail apparatus.⁵ It is a suitable alternative to microsurgical replantation or onychocutaneous transfer flap from toes.^{6,7} This study was conducted to find the length and area gain that can be achieved with eponychial flap.

Patients and Methods

This prospective case–control study was conducted between April 2016 and June 2020. Patients with fingertip injuries underwent flap cover for volar defects with or without eponychial flap based on the presence or absence of eponychial injury. Informed consent was obtained from each patient pertaining to the procedures beforehand.

Patients of all age groups and sex were included in the study. Those unwilling to participate in the study or with complete loss of nail plate and nail bed were excluded from the study.

After an initial evaluation of the injured digit, a thorough examination was done under analgesia and tourniquet. Pulp reconstruction of all injured fingers was done using various flaps. Then nail injury was assessed and an eponychial flap was done to increase nail length as described by Bakhach et al and Adani et al^{5,8} (►Fig. 1).

Operative Steps

The required length of the nail is calculated by subtracting the present length from the total nail length of the contralateral digit. If required all of the available nail is exposed to achieve maximum length. The desired length rectangle was

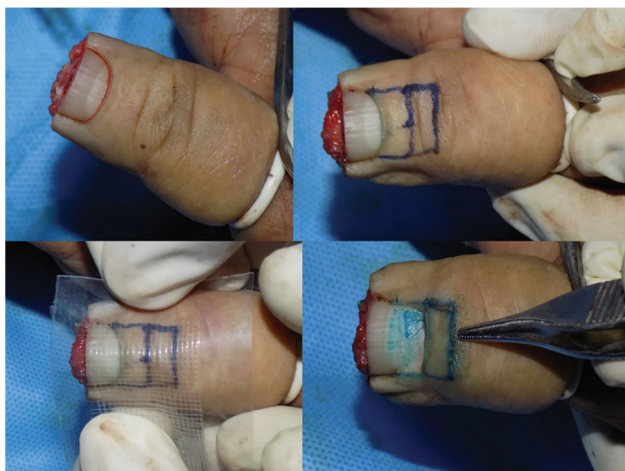

Fig. 1 Surgical steps of eponychial flap.

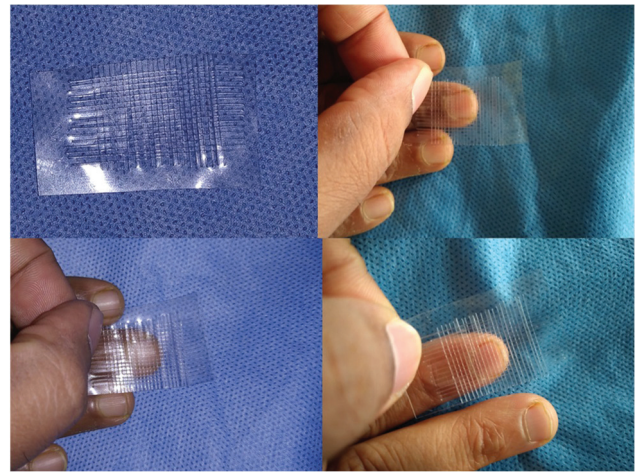


Fig. 2 The graph used to measure nail length and area.

drawn 0.5 cm proximal to the cuticle, the same width as the nail. This part was de-epithelized and lateral incisions were made. The eponychium was separated from the nail and the flap was slid proximally to expose the nail. The eponychium was then plicated backward and proximal and lateral margins were sutured.

All the patients who underwent eponychial flap were categorized as study group/group A. The patients who did not undergo eponychial flap cover were used as control group/group B. The outcome of the study was assessed by using both objective and subjective scores. Objectively, we measured the nail length and area of nail plate. Subjective assessment of the quality of the nail was done by a different surgeon. Patient satisfaction was measured by the visual analogue scale.

We used a transparent plastic sheet to measure the length and area of the nail. The smallest square was 1 mm². Graph markings were made over it and measurements were taken by placing this sheet over the nail plate by counting the small squares as shown in the picture (►Fig. 2).

The final assessment was done after complete nail growth in the injured finger at 1 year. The postoperative results of injured digits are compared against the contralateral non-injured digit.

We utilized a scoring system to assess the outcome of our study similar to the one used by Wang et al.⁹ The outcomes were scored 0, 1, and 2 as described in the table. The patient assessment included a patient satisfaction visual analogue scale. The assessor evaluates all other parameters. The outcome of surgery is assessed as excellent for scores of 13 to 16, good for scores of 9 to 12, fair if scores are between 5 and 8, and poor if scores are below 4 (►Table 1).

Statistical Analysis

The collected data were entered into Microsoft Excel. Statistical analysis was done using IBM statistical package and social science (SPSS) software version 25. Pearson chi-squared test, paired and unpaired students test were used for correlation. Statistical significance of *p*-value was taken as *p* < 0.05

Table 1 Evaluation of outcome of the study

Evaluation of eponychial flap			
	2	1	0
Ratio of length of affected finger to opposite finger	>75%	75–50%	<50%
Ratio of area of affected finger to opposite finger	>75%	75–50%	<50%
Roughness of nail plate surface	None	Slight	Obvious
Luster of nail plate	Normal	Slight lusterless	Obvious lusterless
Translucency of nail	Present	Less	Obscure
Patient satisfaction	Satisfied	Adequate	Unsatisfied
Appearance of the nail: dehiscence of nail or growth failure	None	Either	Both
Overhanging cuticle	No		Yes

Results

During the study period, 186 patients were treated for complete amputation of the fingertip. Excluding patients who did not turned for follow-up and whose case records were incomplete, 78 had undergone eponychial flap for nail lengthening group A, and 87 were taken as control group B. The demography of patients is shown in ►Table 2.

The average loss of finger-nail length in fingertip amputation was found to be 63.75% (38.46–87.5) with a standard deviation (SD) of 11.27 in our study. The average gain in nail length achieved by eponychial flap was 214% (160–400) with an SD of 40.98. In group A, the final length of amputated fingernail postreconstruction was 72.54% (46.15–100) with an SD of 14.31 compared with contralateral finger. In group B, the final length of the injured finger was 36.49% (54.54–14.29) of the contralateral finger with an SD of 8.39.

The average loss of finger nail plate area in fingertip amputation was 61.86% (37.1–83.78) in our study. The final nail plate area of amputated finger postreconstruction in group A was 74.35% (44.95–102.7) with an SD of 13.87 compared with the contralateral finger. In the group B, the final nail plate area of the injured finger was 35.79%

(13.79–57.27) of the contralateral finger with an SD of 8.39. The outcome scores are as per ►Table 3 (►Fig. 3).

Discussion

Loss of nail in a fingertip injury does affect the functionality of the hand. The nail should protrude from the eponychium by at least 2 mm for precision grip and a good cosmetic appearance. Otherwise, its use in normal day-to-day activities is compromised.⁴

Although nail shortening was an issue long ignored, various authors had described various methods for improving the aesthetic outcome of a finger after a fingertip amputation. It included nail bed graft and proximal mobilization of the nail and nail plate matrix. These procedures had unfavorable outcomes in majorities of cases.^{10–12} Foucher et al described a backward transposition of the nail like that for correction of hook nail deformity.¹³ To elongate the distal portion of the nail bed, Dumontier et al have suggested using a Tranquilli-Leali V-Y advancement flap, de-epithelialized on its distal portion. But these techniques could not be done in large nail losses.¹⁴ In large nail plate loss, microsurgical procedures such as partial, total toenail transfer and partial

Table 2 Demography of patients in the study

	Group A	Group B
Total cases	78	87
Male/female	63/13	77/10
Hand involvement: right/left	37/41	45/42
Type of injury: cut/crush injury	12/65	15/72
Fingers involved: index/middle/ring/little/thumb	22/22/12/8/14	21/26/20/7/13
Injury: transverse/volar oblique/dorsal oblique/lateral oblique	61/6/7/4	56/14/14/3
Treatment: V-Y flap/Kuttler/cross finger flap/stump/thenar flap	53/2/10/13	29/1/37/19/1
Nail length compared with contralateral (range)	72.54 (46.15–100) SD: 14.4	36.49 (14.29–54.54) SD: 8.45
Nail area compared with contralateral (range)	74.35 (50–102.7) SD: 13.96	35.8 (13.79–57.27) SD: 8.4
Patient Satisfaction: excellent/good/fair/poor	51/27/0/0	1/69/17/0

Abbreviation: SD, standard deviation.

Table 3 Outcome of both group of patients

	Group A (score with SD)	Group B (score with SD)	Significance
Subjective outcome score	8.45, SD: 1.0	9.02, SD: 0.8	0.002
Objective outcome score	2.9, SD: 1.0	0.2, SD: 0.55	0.000
i. Nail length compared with contralateral	72.54, SD: 14.4	36.49, SD: 8.45	0.000
ii. Nail plate area compared with contralateral	74.35, SD: 13.96	35.8, SD: 8.4	0.000
Total outcome score	13.09, SD: 1.68	9.41, SD: 1.22	0.004
i. Excellent	51	1	
ii. Good	27	69	
iii. Fair	0	17	
iv. Poor	0	0	

Abbreviation: SD, standard deviation.

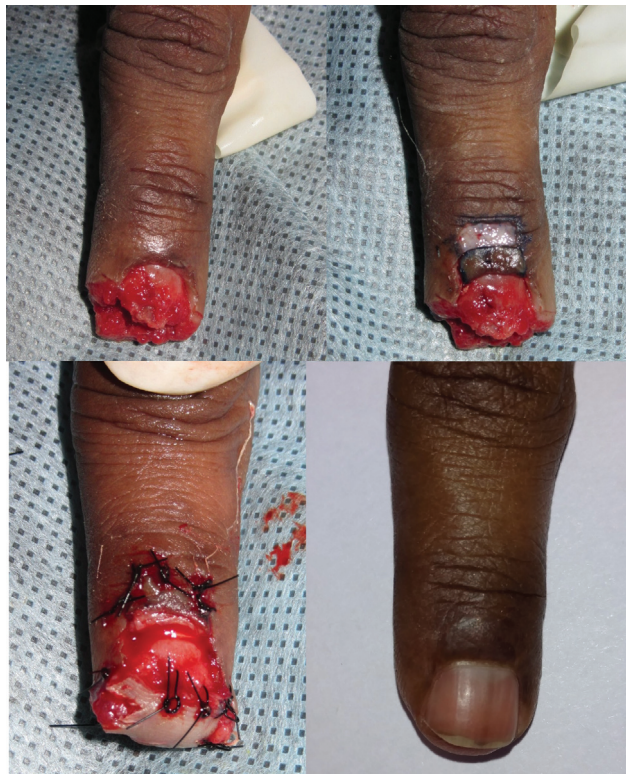

Fig. 3 Intraoperative and postoperative picture of left index finger amputation treated with eponychial flap.

toe transfer have been described to achieve a normal looking nail.¹⁵ But toe transfer has its complications such as flap failure, donor morbidity, and aesthetic mismatch.

Bakhach in 1998 described the anatomical basis of eponychial flap.¹⁶ He published his results of nail lengthening by eponychial flap.⁵ In this series, the average backward transposition achieved was 3.75 mm, and he achieved a nail lengthening of the injured finger that was on average 95.68% (SD: 6.2) to contralateral uninjured digits. Comparing the results to our study, the average nail lengthening achieved was 3.88 mm and the injured nail length compared with contralateral ones was 72.54 (SD: 14.4). This can be attributed to the factor that in our study the average loss of

nail length postamputation was 63.75% (SD: 11.27) and to the fact that in their case series Bakhach et al used eponychial flap only for amputation of nail distal to the lunula.

The rate of nail growth is not compromised by the application of the eponychial flap. In our patients, the consistency of the nail posteponychial flap was comparable to the other side of the hand. None of them had an overhanging cuticle. Two patients from group A and six from group B had growth failure. This disturbance in growth can be attributed to injury to the germinal matrix of the nail. Others also have described similar growth failure in their case series.¹⁷ Nail has longitudinal ridges on the dorsal surface that are barely palpable; in a rough nail these ridges are more prominent. In our study, only two patients in group A had rough nails posteponychial flap and none in group B had a rough nail. The transparency of the nail that is related to the roughness was present in most of the patients in our study group. It was scored based on visible clarity of lunula, which is the junction of germinal matrix and sterile matrix of the nail. From group A, 44.87% of patients and 55.17% of patients from group B had normal transparency. In 47.43% of patients in group A and 42.52% of patients in group B, the lunula was slightly obscure. Only in 7.7% of patients in group A and 2.3% of patients in group B, the lunula was completely obscured leading to an unaesthetic looking nail. (► Fig. 4).

Over some time after the eponychial flap, the exposed nail does change in color and become dull like an exposed nail. The luster of the nail was maintained in most of the patients in our study. Only two patients one from each group had an obvious lusterless nail. The majority of patients (65.38% from group A and 68.97% from group B) had normal luster in their nails. The shining nature of the nail as well as the longitudinal ridges is a function of the volar layer of the eponychium. Injury to this part leads to a dull-looking nail that is rough and lusterless. The injury might be during the primary fingertip injury or surgery. As per Adani et al, the final result depends not only on the proper and precise use of the surgical technique of eponychial flap but also on the procedures for pulp reconstruction.⁸ Our study results were similar to that of Fakin et al who denied role of the volar flap in the aesthetic outcome of eponychial flap.¹⁷

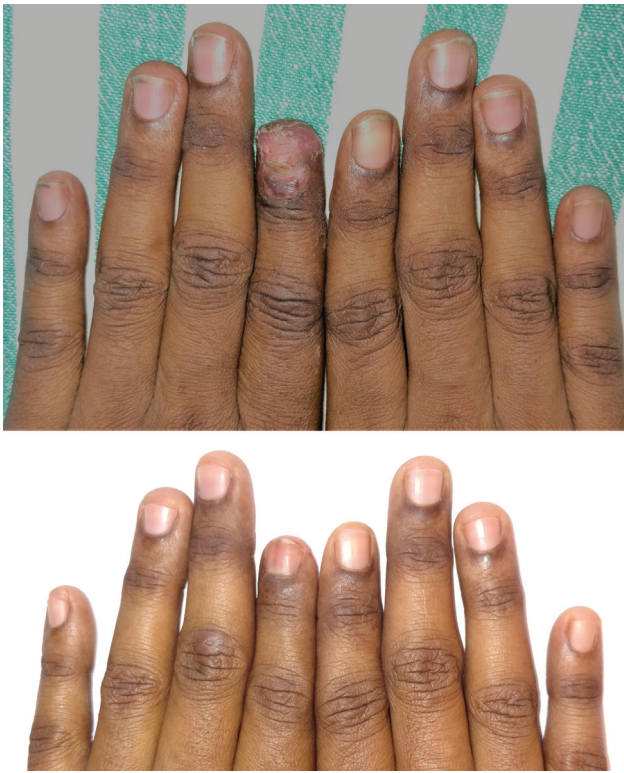

Fig. 4 Results of the same patient at 3 months postoperatively and 1 year postoperatively.

In all our cases, the eponychial flap healed without any complications, there were no flap necrosis or infection, and the resulting scar was unremarkable. There were no resulting nail deformities as hook nails. The overall outcome was excellent in 51 (65.38%) patients and good in the rest. These results are significantly better compared with the patients without eponychial flap where the excellent outcome was present only in 1 patient (1.15%) and good in 69 patients (79.31%). When offered a nail lengthening, 11 patients of group B underwent an eponychial flap.

Conclusion

The eponychial flap is a simple and reliable technique that can be used to increase the visible nail length in traumatic fingertip injuries. It allows to achieve an aesthetically acceptable digit.

Ethics Approval

All procedures performed in studies involving human participants were in accordance with the ethical standards of the institutional and/or national research committee and with the 1964 Helsinki Declaration and its later amendments or comparable ethical standards. The Institutional Ethical Committee approval was obtained for this study.

Informed Consent

Informed consent was obtained from all individual participants included in the study.

Authors' Contributions

All the authors had significantly contributed toward the study design, collection of data, and writing of this manuscript.

Conflict of Interest

None declared.

References

- 1 Venkataswami R, Subramanian N. Oblique triangular flap: a new method of repair for oblique amputations of the fingertip and thumb. *Plast Reconstr Surg* 1980;66(02):296–300
- 2 Atasoy E, Lokimidis E, Kasdan M, Kutz J, Kleinert H. Reconstruction of the amputated finger tip with a triangular volar flap—a new surgical procedure. *Plast Reconstr Surg* 1971;48(05):215
- 3 Hueston J. Local flap repair of fingertip injuries. *Plast Reconstr Surg* 1966;37(04):349–350
- 4 Zook EG, Van Beek AL, Russell RC, Beatty ME. Anatomy and physiology of the perionychium: a review of the literature and anatomic study. *J Hand Surg Am* 1980;5(06):528–536
- 5 Bakhach J, Demiri E, Guimberteau JC. Use of the eponychial flap to restore the length of a short nail: a review of 30 cases. *Plast Reconstr Surg* 2005;116(02):478–483
- 6 Hirasé Y, Kojima T, Matsui M. Aesthetic fingertip reconstruction with a free vascularized nail graft: a review of 60 flaps involving partial toe transfers. *Plast Reconstr Surg* 1997;99(03):774–784
- 7 Koshima I, Etoh H, Moriguchi T, Soeda S. Sixty cases of partial or total toe transfer for repair of finger losses. *Plast Reconstr Surg* 1993;92(07):1331–1338, discussion 1339–1341
- 8 Adani R, Marcoccio I, Tarallo L. Nail lengthening and fingertip amputations. *Plast Reconstr Surg* 2003;112(05):1287–1294
- 9 Wang AY, Gao WY, Wu LM, Li ZJ, Chen XL, Li XY. Nail fusion plasty: nail cosmetic results and assessment criteria of nail reconstruction. *Ann Plast Surg* 2015;75(03):290–294
- 10 Sommer NZ “The Perionychium.” In: Wolfe SW, Hotchkiss RN, Perdererson WC, Kozin SH, Cohen MS, eds. *Green’s Operative Hand Surgery*. 7th ed. Philadelphia, PA: Elsevier Churchill Livingstone; 2017:318–337
- 11 Shepard G. Treatment of nail bed avulsions with split-thickness nail bed grafts. *Plast Reconstr Surg* 1985;76(03):488
- 12 Shepard GH. Perionychial grafts in trauma and reconstruction. *Hand Clin* 2002;18(04):595–614
- 13 Foucher G, Lenoble E, Goffin D, Sammut D. Le lambeau “escalator” dans le traitement de l’ongle en griffe. [Escalator flap in the treatment of claw nail] *Ann Chir Plast Esthet* 1991;36(01): 51–53
- 14 Dumontier C, Tilquin B, Lenoble E, Foucher G. Reconstruction des pertes de substance distales du lit ungueal par un lambeau d’avancement pulpaire désépidermisé. [Reconstruction of distal loss of substance in the nail-bed by a de-epithelialized flap from the digital pulp] *Ann Chir Plast Esthet* 1992;37(05): 553–559
- 15 Rai A, Jha MK, Makhija LK, Bhattacharya S, Sethi N, Baranwal S. An algorithmic approach to posttraumatic nail deformities based on anatomical classification. *J Plast Reconstr Aesthet Surg* 2014;67(04):540–547
- 16 Bakhach J. Le lambeau d’éponychium. [Eponychial flap] *Ann Chir Plast Esthet* 1998;43(03):259–263
- 17 Fakin RM, Biraima A, Klein H, Giovanoli P, Calcagni M. Primary functional and aesthetic restoration of the fingernail in distal fingertip amputations with the eponychial flap. *J Hand Surg Eur Vol* 2014;39(05):499–504